

# Vlaams Diergeneeskundig Tijdschrift


FACULTEIT  
DIERGENEESKUNDE  
accredited by FAEVE

JANUARI - FEBRUARI 2019  
VOL. 88 - NR. 1

VERSCHIJNT TWEEMAANDELIJKS  
PUBLISHED BIMONTHLY  
ISSN 0303 9021  
WWW.VDT.UGENT.BE  
GENT X

Afgiftekantoor 9099 Gent X  
v.u. Luc Peelman  
Salisburylaan 133 - B-9820 Merelbeke

UNIVERSITEIT  
GENT

- 
- Medicamenteuze behandeling van incontinentie bij de teef
  - Langetermijnresultaten van tenoscopie bij paarden
    - Spontane repositie van een premolaar bij twee paarden
  - Stenotische myelopathie door vacuümfenomeen bij een hond
    - Intra-abdominale bloeding bij een paard
    - *Dirofilaria repens* in een hematoom bij een hond
    - IAVD geassocieerd met tachycardie bij een hond
  - CanIFreeze: de eerste open spermabank voor honden



# VLAAMS DIERGEENEESKUNDIG TIJDSCHRIFT

2019, vol. 88, nr. 1

## INHOUD

### Overzichtsartikel

- 3 J. TIMMERMANS, B. VAN GOETHEM, H. DE ROOSTER, D. PAEPE  
Medicamenteuze behandeling van urinaire incontinentie bij de teef

### Review

- J. TIMMERMANS, B. VAN GOETHEM, H. DE ROOSTER, D. PAEPE  
Medical treatment of urinary incontinence in the bitch

### Retrospectieve studie

- 9 F. THÜNKER, M. OOSTERLINCK, K. VANDERPERREN, A. MARTENS  
Langtermijnresultaten van tenoscopische behandeling van letsels in de sesamschede: een retrospectieve studie van vijftig paarden

### Retrospective study

- F. THÜNKER, M. OOSTERLINCK, K. VANDERPERREN, A. MARTENS  
Long-term results of tenoscopic treatment of lesions in the digital flexor tendon sheath: a retrospective study of fifty horses

### Casuïstieken

### Case reports

- 19 E. POLLARIS, K. VANDERPERREN, G.A.M. DE PAUW, L. VLAMINCK  
Spontane repositie van een equiene premolaar na extractie van een aanpalende polydonte tand – twee casussen

- E. POLLARIS, K. VANDERPERREN, G.A.M. DE PAUW, L. VLAMINCK  
Spontaneous realigning of a displaced equine premolar post extraction of an adjacent supernumerary tooth – two cases

- 29 S. VERMEIRE, V. RONDAHL, M. RAPP  
Vacuümfenomeen geassocieerd met een drievoudige cervicale wervelboog- en ligamentum flavum-anomalie resulterend in erge stenotische myelopathie bij een hond

- S. VERMEIRE, V. RONDAHL, M. RAPP  
Vacuum phenomenon associated with triple cervical vertebral arch and ligamentum flavum anomaly resulting in severe stenotic myelopathy in a dog

- 34 L. DE LANGE, A. DUFOURNI, L. LEFÈRE, L. SONCK, G. VAN LOON  
Intra-abdominale bloeding bij een paard, niet altijd het gevolg van trauma

- L. DE LANGE, A. DUFOURNI, L. LEFÈRE, L. SONCK, G. VAN LOON  
Intra-abdominal bleeding in a horse: not always of traumatic origin

- 39 H. DE BOSSCHERE, E. KINDERMANS  
Toevalsbevinding van *Dirofilaria repens* in een hematoom bij een hond in België

- H. DE BOSSCHERE, E. KINDERMANS  
Accidental diagnosis of *Dirofilaria repens* in a hematoma in a dog in Belgium

- 44 A. VAN LOON, V. LIEKENS, D. BINST, D. PAEPE, B. HOUELLIER, P. SMETS  
Supraventriculaire tachycardie met isoritmische atrioventriculaire dissociatie bij een labrador-retriever

- A. VAN LOON, V. LIEKENS, D. BINST, D. PAEPE, B. HOUELLIER, P. SMETS  
Supraventricular tachycardia with isorhythmic atrioventricular dissociation in a Labrador retriever

### Permanente vorming

### Continuing education

- 55 G. DOMAIN, E. WYDOOGHE, B. BROECKX, M. HOOGEWIJS, A. VAN SOOM  
Spermadonatie en de start van een open spermabank voor honden: een nieuw hulpmiddel om inteelt bij rashonden te voorkomen

- G. DOMAIN, E. WYDOOGHE, B. BROECKX, M. HOOGEWIJS, A. VAN SOOM  
Semen donation and establishment of an open canine semen bank: a novel tool to prevent inbreeding in pedigree dogs

### Vraag en antwoord

- 62 Sedatie van agressieve honden vóór euthanasie

### Oproep

- 54, 63, 64 **Uit het verleden**

#### Coverfoto: Geert Roels (Boekentoren, UGent).

Sinds 12 november 2018 zit er een bronzen foxterriër op de Boekentoren. Hij is goed zichtbaar vanop het Sint-Pietersplein. Op zich is dat niet van belang. Gewoon de gedachte dat hij daar zit, is voldoende. De hond heeft ook geen naam. Iedereen staat vrij er zijn eigen verhaal mee te vertellen. Voor de ene bewaakt hij de toren, voor de andere relateert hij de opgeslagen kennis onder hem, voor de Van de Velde-erven is het Chippa, de meester zijn laatste hond. Op een blog over esoterie staat het dier zelfs voor de Perzische god Ahriman die volgens Rudolf Steiner in onze tijd vooral optreedt als schrijver.

Tekst: Geert Roels

# VLAAMS DIERGENEESKUNDIG TIJDSCHRIFT

ISSN 0303-9021

<http://vdt.UGent.be>

**Hoofdredacteur en verantwoordelijke uitgever:** Luc Peelman  
**Coördinator en eindredacteur:** Nadia Eeckhout  
**Redacteur rubriek "Uit het verleden":** Luc Devriese

## Redactiecomité:

P. Bols, B. Broeckx, C. Burvenich, E. Cox, S. Daminet, P. Deprez, W. De Spiegelaere, M. Devreese, L. Devriese, R. Ducatelle, M. Haspeslagh, M. Hesta, K. Houf, J. Laureyns, I. Polis, J. Saunders, L. Van Ham, F. Van Immerseel, A. Van Soom

## Druk:

Graphius  
Eekhoudriesstraat 67, B-9041 Oostakker

## Publiciteit:

Boerenbond – Media-Service, Diestsevest 40, B-3000 Leuven  
Tel. 016 28 63 33

## Inlichtingen (voor auteurs) en Abonnementen:

Nadia Eeckhout  
Salisburylaan 133, B-9820 Merelbeke  
Tel. 09 264 75 13  
[nadia.eeckhout@UGent.be](mailto:nadia.eeckhout@UGent.be)

Het Vlaams Diergeneeskundig Tijdschrift verschijnt 6 maal per jaar en wordt uitgegeven door de Faculteit Diergeneeskunde, Universiteit Gent.

Voor intekening dient U contact op te nemen met het secretariaat van het tijdschrift: [nadia.eeckhout@UGent.be](mailto:nadia.eeckhout@UGent.be); tel. 09 264 75 13; fax 09 264 77 99. Er zal u een factuur toegestuurd worden van 60 euro (+6% BTW) (abonnees in België) of 80 euro (+6% BTW) (abonnees in het buitenland). Studenten en faculteitspersoneel kunnen genieten van een gunsttarief.

De verantwoordelijkheid voor alle gepubliceerde methoden, materialen en aanbevelingen berust bij de auteurs van de betreffende bijdragen. De redactie en uitgever zijn niet verantwoordelijk voor eventuele letsels of schade als gevolg van toepassingen die daaruit voortvloeien.

## Beknpte richtlijnen voor auteurs

Ieder manuscript zal qua inhoud en vorm beoordeeld worden door 2 onafhankelijke personen.

De samenvatting mag niet langer zijn dan 5% van het artikel met een max. van 150 woorden.

De literatuuaraangave **in de tekst** dient als volgt te gebeuren: de naam van de auteur(s) en het jaar van publicatie (Voorbeeld: "... werd vroeger aangetoond (Brown, 1975; Brown en Ellis, 1975; Brown *et al.*, 1975)" ofwel "Brown (1975) toonde vroeger aan dan ...". Er is dus geen cijferaanuiding in de tekst.

In de **literatuurlijst** dienen achtereenvolgens vermeld: namen van auteur(s), initialen van voornamen, jaartal, titel van artikel, naam van tijdschrift, volume, paginering. Voorbeeld: Allan W.R., Rowson L.B., (1973). Control of the mare's oestrus cycle by prostaglandins. *Journal of Reproduction and Fertility* 33, 539-543.

De referenties zijn alfabetisch gerangschikt. Artikels van dezelfde auteur(s) dienen per jaartal gerangschikt en in de tekst aangeduid te worden als: (1975a, 1975b)... Bij boeken dienen plaats en naam van uitgever vermeld te worden.

**Editor-in-chief and publisher:** Luc Peelman  
**Editorial office:** Nadia Eeckhout  
**Editor "History":** Luc Devriese

## Editorial board:

P. Bols, B. Broeckx, C. Burvenich, E. Cox, S. Daminet, P. Deprez, W. De Spiegelaere, M. Devreese, L. Devriese, R. Ducatelle, M. Haspeslagh, M. Hesta, K. Houf, J. Laureyns, I. Polis, J. Saunders, L. Van Ham, F. Van Immerseel, A. Van Soom

## Printed by:

Graphius  
Eekhoudriesstraat 67, B-9041 Oostakker

## Advertisements:

Boerenbond – Media-Service, Diestsevest 40, B-3000 Leuven  
Tel. 016 28 63 33

## Information (for authors) and Subscriptions:

Nadia Eeckhout  
Salisburylaan 133, B-9820 Merelbeke  
Tel. 09 264 75 13  
[nadia.eeckhout@UGent.be](mailto:nadia.eeckhout@UGent.be)

The 'Vlaams Diergeneeskundig Tijdschrift' is published six times per year by the Faculty of Veterinary Medicine, Ghent University. For subscriptions, please contact the administrative offices of the journal: [nadia.eeckhout@UGent.be](mailto:nadia.eeckhout@UGent.be); tel. 0032 9 264 75 13; fax 0032 9 264 77 99. An invoice of 80 euros (+6% VAT) will be sent.

The responsibility for all methods, materials and recommendations published herein rests solely with the authors of the various contributions. No responsibility is assumed by the editorial staff or publisher for any resulting injury or damage.

More detailed information is available on  
[www.vdt.ugent.be](http://www.vdt.ugent.be)

**Figuren en tabellen** dienen contrastrijk te zijn en op afzonderlijke bijlagen te worden ingediend. De figuren moeten een grootte hebben van minstens 200 kb.

Het aantal tabellen en figuren wordt tot een noodzakelijk minimum beperkt.

Voor de figuren dienen titels en teksten gezamenlijk op een apart blad aangebracht te worden.

**Overzichtsartikelen** mogen niet te uitgebreid zijn (norm: max. 20 getypte bladzijden) en het aantal referenties wordt beperkt gehouden.

De auteurs gaan ermee akkoord dat hun gepubliceerd artikel hergebruikt kan worden, mits vermelding van de bron.

Verdere details kunnen verkregen worden op de redactie of op [www.vdt.ugent.be](http://www.vdt.ugent.be)

## Medical treatment of urinary incontinence in the bitch

### *Medicamenteuze behandeling van urinaire incontinentie bij de teef*

J. Timmermans, B. Van Goethem, H. de Rooster, D. Paepe

Small Animal Department, Faculty of Veterinary Medicine, Ghent University,  
Salisburylaan 133, 9820 Merelbeke, Belgium

bart.vangoethem@ugent.be

## ABSTRACT

Urinary incontinence, an uncontrolled urine leakage during the storage phase of micturition, is a common condition in female dogs. In intact bitches, the reported prevalence is only 0.2-0.3%, but in spayed bitches it varies between 3.1-20.1%. Most commonly, dogs with acquired urinary incontinence suffer from urethral sphincter mechanism incompetence. This condition seems to be multifactorial, and although the exact pathophysiology remains unclear, potential risk factors include gender, gonadectomy, breed, body weight, urethral length and bladder neck position. In daily practice, the diagnosis of urethral sphincter mechanism incompetence is usually made after eliminating other potential causes of urinary incontinence. Incontinent bitches are primarily treated with medications, such as alpha-adrenergic drugs, e.g. phenylpropanolamine and oestrogens. Surgery is recommended when patients become refractory to medical treatment.

## SAMENVATTING

Urinaire incontinentie, het ongecontroleerd verlies van urine tijdens de vullingsfase van het urineren, is een veelvoorkomende aandoening bij vrouwelijke honden. De gerapporteerde prevalentie bij intacte teven is slechts 0,2-0,3%, maar dit varieert tussen de 3,1-20,1% bij gesteriliseerde teven. Honden met verworven urine-incontinentie lijden meestal aan urethrale sfinctermechanisme-incompetentie. Deze aandoening lijkt door meerdere factoren veroorzaakt te worden en, alhoewel de exacte pathofysiologie niet volledig bekend is, zijn potentiële risicofactoren geslacht, gonadectomie, ras, lichaamsgewicht, urethrale lengte en positie van de blaashals. In de praktijk is de diagnose van urethrale sfinctermechanisme-incompetentie doorgaans gebaseerd op uitsluiting van andere potentiële oorzaken van urine-incontinentie. Incontinentie teven worden hoofdzakelijk medicamenteus behandeld met onder andere alfa-adrenerge geneesmiddelen, bijvoorbeeld fenylpropanolamine en oestrogenen. Chirurgie is aangeraden als de patiënt refractair wordt ten opzichte van de medicamenteuze behandeling.

## INTRODUCTION

Normal micturition in dogs is composed of a complex interaction between the storage of urine in the bladder and emptying of the bladder (Fischer and Lane, 2011; Byron, 2015). Urinary incontinence (UI) is defined as an uncontrolled leakage during the storage phase (Abrams et al., 2003). This can be categorized in two main groups: neurogenic or non-neurogenic induced UI, of which, in dogs, the latter can either occur congenitally or acquired (Applegate et al., 2018) (Table 1).

The prevalence of UI in intact bitches is as low as 0.2-0.3% (Holt and Thrusfield, 1993). In spayed bitch-

es, this prevalence has historically been reported up to 20.1% (Arnold et al., 1989), but in more recent studies by Forsee et al. (2013) and O'Neill et al. (2017), numbers closer to 3-5% have been reported.

In this review, the most common cause of UI, the diagnostic procedure and medical treatment options are highlighted.

## ANATOMY

The lower urinary tract consists of the bladder, comprised of an apex, body and bladder neck, and the urethra, containing the external urethral sphinc-



**Table 1. Main differential diagnoses of urinary incontinence. Adapted from: Fischer and Lane (2017).**

Urinary incontinence	
Neurogenic	Non-neurogenic
<ul style="list-style-type: none"> <li>• Lower motor neuron disorders</li> <li>• Upper motor neuron disorders</li> <li>• Detrusor urethral dyssynergia</li> <li>• Dysautonomia</li> <li>• Primary bladder atony</li> </ul>	<ul style="list-style-type: none"> <li>• Urethral sphincter mechanism incompetence (USMI)</li> <li>• Congenital disorders</li> <li>• Detrusor hyperreflexia</li> <li>• Anatomical or functional urethral obstruction leading to secondary bladder atony</li> <li>• Bladder atony due to muscle weakness or medications</li> </ul>

ter (Fischer and Lane, 2011). The external urethral sphincter could also be described as part of the sphincter mechanism and not as a separate structure. Micturition is coordinated through sympathetic, parasympathetic and somatic innervation, combined with actions regulated from central control centers (DiBartola and Westropp, 2014) (Figure 1). The sympathetic hypogastric nerve, originating from spinal segment L1-L4, is mainly important during the storage phase because norepinephrine release during nerve stimulation results in detrusor relaxation, filling of the urinary bladder and prevention of subsequent urinary leakage (Fischer and Lane, 2011; DiBartola and Westropp, 2014; Byron, 2015). This is accomplished through activation of beta-receptors in the bladder and alpha-1-adrenergic receptors in the smooth muscle within the urethral sphincter mechanism (DiBartola and Westropp, 2014). The pelvic nerve, which originates from spinal segment S1-S3, supplies parasympathetic innervation (Fischer and Lane, 2011). It ensures excitatory input to the bladder (bladder contraction) and inhibitory input to the urethra (urethral relaxation), resulting in urination (DiBartola and Westropp, 2014).

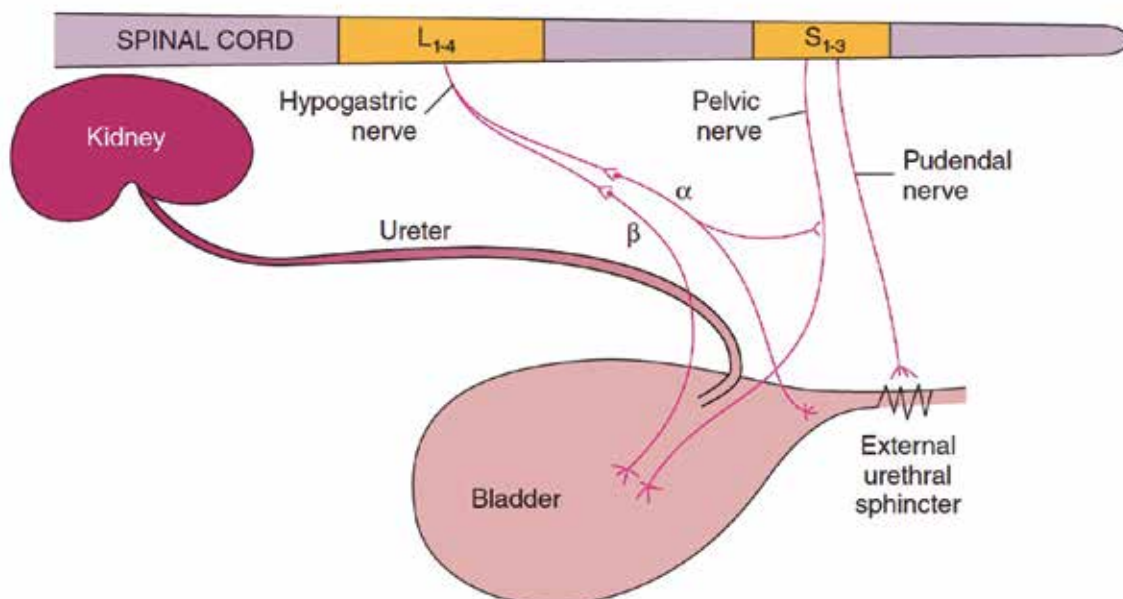
Lastly, the pudendal nerve also originates from spinal segment S1-S3, supplies somatic innervation and stimulates the external urethral sphincter (Fischer and Lane, 2011; DiBartola and Westropp, 2014).

### URETHRAL SPHINCTER MECHANISM INCOMPETENCE

Dogs with acquired UI most commonly suffer from urethral sphincter mechanism incompetence (USMI) (Byron et al., 2017). The pathophysiology of USMI remains incompletely elucidated. Most likely, this condition is multifactorial, resulting from hormonal, as well as structural and functional changes (Applegate et al., 2018). Several risk factors have been described for the development of USMI.

### Gender

USMI can develop in both male and female dogs, but the condition is rare in males with a reported risk of up to 1% (Holt, 1990; Reichler and Hubler,



**Figure 1. Simplified representation of the innervation of the lower urinary tract. Adapted from: DiBartola and Westropp (2014).**

2014). Extensive studies have been conducted in bitches to support the prevalence, which is not the case in males (Aaron et al., 1996; Forsee et al., 2013).

### Gonadectomy

Spaying in dogs increases the risk of USMI (Holt and Thrusfield, 1993; Thrusfield et al., 1998; Reichler and Hubler, 2014). According to Holt (1985), approximately 90% of dogs with USMI have a history of prior gonadectomy. In about 75% of the bitches, the onset of UI occurs within three years after gonadectomy, but it is not uncommon that clinical signs occur directly after the surgery or as late as ten years after (Arnold et al., 1989; Reichler and Hubler, 2014).

So far, no consensus has been reached about the link between the age of the dog at spaying and the concurrent risk of USMI (Arnold et al., 1989; Arnold, 1997; Thrusfield et al., 1998; Stöcklin-Gautschi et al., 2001; de Bleser et al., 2011; Beauvais et al., 2012; Forsee et al., 2013; Reichler and Hubler, 2014). In earlier studies, an increased risk of developing incontinence has been mentioned when spaying was performed before three months of age (Thrusfield et al., 1998; Stöcklin-Gautschi et al., 2001), or when dogs have had their first oestrus (Arnold et al., 1989). On the other hand, in more recent publications, no evidence to support a relationship between age at which gonadectomy is performed and the development of USMI in bitches has been found (de Bleser et al., 2011; Beauvais et al., 2012; Forsee et al., 2013).

The suggestion has been made that the severity of UI might be different depending on the age the animal was spayed (Reichler and Hubler, 2014). In a study by Arnold (1997), it was shown that gonadectomy before puberty resulted in UI after an increased abdominal pressure, as expected, but also during walks or when the animal was awake. Dogs neutered after puberty are mainly dribbling when recumbent with less intensity (Stöcklin-Gautschi et al., 2001).

Recently, Byron et al. (2017) described a relationship between gonadectomy and body weight, which will be discussed below.

The extent of surgery, ovariectomy versus ovariohysterectomy, does not result in different continence rates (Van Goethem et al., 2006). Likewise, the incidence of USMI is not different in dogs with elective versus emergency procedure (Forsee et al., 2013).

### Breed and body weight

Urinary incontinence is more common in medium to large-breed dogs (de Bleser et al., 2011). Previous studies have demonstrated that dogs weighing more than 10 kg have a 3.7-times higher risk of developing USMI than smaller dogs (de Bleser et al., 2011), and dogs weighing more than 15 kg have a 7.2-times higher risk (Forsee et al., 2013). Additionally, Byron et al. (2017) found a relationship between age at the time

of ovariohysterectomy and body weight in developing USMI. According to this study, the risk of developing USMI for dogs with an expected adult weight of more than 25 kg decreases for every month gonadectomy is postponed during their first year. In the same study, dogs weighing less than 15 kg were reported not to be susceptible to this risk, making it reasonable to spay these dogs prior to the first heat to reduce the risk of unwanted pregnancy or developing mammary neoplasia and pyometra (Byron et al., 2017). Some breeds are clearly overrepresented in the literature and have an increased risk of USMI, such as Doberman pinscher, Old English sheepdog, Springer spaniel, boxer, rottweiler, Weimaraner, Giant schnauzer and Irish setter (White, 2001; Reichler and Hubler, 2014). Based on an investigation in 928 entire or neutered male and female Dobermans, a prevalence of 15.8% was found (Mandigers et al., 2006). Nevertheless, developing USMI is not restricted to these breeds; all breeds can be affected.

### Urethral length and bladder neck position

Holt (1985c) documented that incontinent bitches are more likely to present with intrapelvic bladder neck than continent bitches that usually have intra-abdominal bladder neck (Holt, 1985b). Radiographically, spayed bitches also tend to have a shorter urethra than intact bitches, although it is unknown how decisive these radiographic findings are in the occurrence of UI (Holt, 1985c; Wang et al., 2006).

## DIAGNOSIS

Diagnosing USMI may be challenging and typically relies on elimination of other potential causes of UI (Applegate et al., 2018) (Table 1). Congenital conditions, e.g. ectopic ureter and patent urachus, must be evaluated in case an animal is incontinent since birth or at least before spaying (Byron, 2015). Affected dogs may present with either intermittent or continuous UI (Holt, 1985c), and observing micturition increases the chance of correct diagnosis (Byron, 2015). It is important to monitor for conscious or unconscious urination, stranguria and to palpate the bladder afterwards for residual volume (Byron, 2015). Findings on general physical examination are unfortunately not specific for the presence of USMI (Applegate et al., 2018). Neurological examination is indicated with particular interest for the urogenital system to evaluate the perineal reflex (pudendal nerve), as well as a vaginal and rectal examination to diagnose anatomical abnormalities (Labato, 2018).

Additional diagnostic procedures are necessary to diagnose USMI (Applegate et al., 2018). The ideal diagnostic work-up to support the presumptive diagnosis of USMI includes a complete blood count, biochemistry panel, urinalysis (including urine specific

gravity and urine culture), abdominal radiographs and abdominal ultrasound. Although most of these diagnostics are within normal limits when USMI is present in a dog, these tests should be performed to rule out concurrent diseases (Applegate et al., 2018). Performing abdominal radiographs and/or ultrasound allows excluding the presence of urinary calculi and neoplasia including possible metastatic disease. Urodynamic studies should be performed to make the definitive diagnosis of USMI (Applegate et al., 2018). When a minimum database is obtained but the specialized equipment for urodynamic studies is not available, it is acceptable to start empirical treatment and confirm the diagnosis of USMI as a result of treatment success (Applegate et al., 2018). However, diagnostics should be repeated in case of a recurrence of UI (Reichler and Hubler, 2014).

## MEDICAL TREATMENT

Medical management is always the first treatment option because it is not invasive and successful in up to 97% of cases (Applegate et al., 2018). Alpha-adrenergic drugs are the preferred initial treatment in dogs with USMI (Richter and Ling, 1985; Applegate et al., 2018). It is important to know the potential side effects and contraindications of the medications described below to decide on the best choice of drugs and alter treatment accordingly.

### Alpha-adrenergic drugs

Phenylpropanolamine, a sympathomimetic alpha-adrenergic drug, increases urethral sphincter tone by tensioning smooth muscles in both the bladder neck and urethra (Richter and Ling, 1985; Scott et al., 2002; Applegate et al., 2018). The reported efficacy of this drug varies between 86-97% (Scott et al., 2002; Claeys et al., 2011). One mg/kg body weight is administered two to three times a day (Scott et al., 2002), or alternatively 1.5 mg/kg body weight can be administered once daily (Claeys et al., 2011). Improvement should be noticed within three to four weeks after starting treatment (Applegate et al., 2018). Side effects of phenylpropanolamine include anxiety, excitement and aggression, which may result in an increased sympathetic tone (Burgherr et al., 2007). Other alpha-adrenergic drugs, such as ephedrine or pseudoephedrine, illustrate more adverse effects, e.g. panting, hyporexia and lethargy, result in lower urethral closure pressure and have a lower efficacy of 25-75% only (Byron et al., 2007; Applegate et al., 2018). Phenylpropanolamine or other alpha-adrenergic drugs are contraindicated when hypertension could have disastrous consequences, e.g. in heart and kidney disease or glaucoma (Burgherr et al., 2007).

The effect of alpha-adrenergic drugs decreases over time (Richter and Ling, 1985; White and Pomeroy, 1989; Reichler and Hubler, 2014). Unfortunately,

there is no cut-off period available from previously published studies as to when to expect decreased effect of medications or refractory incontinence.

## Oestrogens

Estriol, a short-acting oestrogen, increases urethral closure pressure by stimulating urethral mucosal tissue (Mandigers and Nell, 2001). The reported efficacy is 65–83% (Arnold, 1997; Mandigers and Nell, 2001). A dose of 2 mg, irrespective of the dog's bodyweight, is administered orally once daily for the first seven to fourteen days (Byron, 2018). Clinical improvement may be expected within this time frame (Mandigers and Nell, 2001). The recommended dose is reduced after improvement by 0.5 mg per week until the minimum effective dose is reached, which can be continued every other day (Mandigers and Nell, 2001; Fischer and Lane, 2017). If no response to treatment is achieved after the first two weeks, it may be beneficial to continue dosing 2 mg/dog until clinical improvement is appreciated (Mandigers and Nell, 2001). Potential adverse effects include vulvar hyperplasia, vaginal discharge, attractiveness to males and pyometra in entire and ovariectomized bitches (Byron et al., 2007; Schotanus et al., 2008; Applegate et al., 2018). Alternatively, diethylstilbestrol can be administered, which is a long-acting oestrogen. However, this could induce more adverse effects than estriol, such as myelosuppression (Hoeijmakers et al., 2003; Sontas et al., 2009).

## Multidrug therapy

When monotherapy does not provide satisfactory results, multidrug therapy may be initiated (Aaron et al., 1996; Reichler et al., 2003). For example, combining alpha-adrenergic drugs with oestrogens would theoretically result in a synergistic effect because of their different mechanism of action (Aaron et al., 1996; Applegate et al., 2018). No recommendations have been published regarding altered dosing schedules or the consequences of this drug combination protocol on potential side effects. Hamaide et al. (2006) used the doses described above for phenylpropanolamine and estriol to investigate urodynamic and morphologic changes, but multidrug therapy did not appear beneficial compared to monotherapy.

Reichler et al. (2003) described a combination therapy of gonadotropin-releasing hormone (GnRH) analogues and phenylpropanolamine 1.5 mg/kg three times a day in dogs. Leuprolide, deslorelin and buserelin, examples of GnRH analogues, are injected subcutaneously and result in a suppression of follicle stimulating hormone and luteinizing hormone. The doses used include 11.25 mg, 5-10 mg, and 6.3 mg, respectively. These formulations are effective between one to six months (Reichler et al., 2003). Although the consequences to the urethral sphincter tone are incompletely elucidated, these GnRH analogues seem



to have temporary positive effects in almost 50% of dogs with USMI (Reichler et al., 2003, 2006). Long-term results of GnRH solo treatment are disappointing, with only a few dogs still continent after a mean of 247 days even after repeated injections. So far, no side effects of this treatment have been mentioned (Reichler et al., 2003).

### Refractory patients

Refractory patients are dogs that do not respond or tolerate medical treatment, or initially respond to medications and ultimately show clinical symptoms suggestive for USMI. It has been reported that up to 56% of dogs develop refractory incontinence (Currao et al., 2013). Treatment options for these patients include surgical treatment, such as urethral bulking, colposuspension, urethropexy and an artificial urethral sphincter (Applegate et al., 2018).

### CONCLUSION

Approximately 3-5% of spayed bitches are affected with UI. USMI is the most common cause of acquired UI in spayed bitches and the frequency is influenced by gender, breed, body weight, gonadectomy, urethral length and bladder neck position. Diagnosing USMI is usually based on excluding other causes of incontinence and can be confirmed after performing urodynamic studies. USMI is primarily treated with medications, such as phenylpropanolamine and estriol, of which the former is the treatment of choice. Additional scientific research and a longer follow-up period are required to further investigate what causes refractory incontinence, the benefits of multidrug therapy including the dosing schedules required in practice, and when refractory incontinence is likely to occur. Surgery is recommended when bitches become refractory to medical treatment of UI.

### REFERENCES

Aaron, A., Eggleton, K., Power, C., Holt, P.E. (1996). Urethral sphincter mechanism incompetence in male dogs: a retrospective analysis of 54 cases. *Veterinary Record* 139, 542–546.

Abrams, P., Cardozo, L., Fall, M., Griffiths, D., Rosier, P., Ulmsten, U., Van Kerrebroeck, P., Victor, A., Wein, A. (2003). The standardisation of terminology in lower urinary tract function: Report from the standardisation sub-committee of the International Continence Society. *Urology* 61, 37–49.

Applegate, R., Olin, S., Sabatino, B. (2018). Urethral sphincter mechanism incompetence in dogs: an update. *Journal of the American Animal Hospital Association* 54, 22–29.

Arnold, S. (1997). Urinary incontinence in castrated bitches. 2. Diagnosis and treatment. *Schweizer Archiv für Tierheilkunde* 139, 319–324.

Arnold, S., Arnold, P., Hubler, M., Casal, M., Rüschi, P. (1989). Urinary incontinence in spayed female dogs: frequency and breed disposition. *Schweizer Archiv für Tierheilkunde* 131, 259–263.

Beauvais, W., Cardwell, J.M., Brodbelt, D.C. (2012). The effect of neutering on the risk of urinary incontinence in bitches - a systematic review. *Journal of Small Animal Practice* 53, 198–204.

Burgherr, T., Reichler, I., Hung, L., Hubler, M., Arnold, S. (2007). Efficacy, tolerance and acceptability of Incontex in spayed bitches with urinary incontinence. *Schweizer Archiv für Tierheilkunde* 149, 307–313.

Byron, J.K. (2015). Micturition disorders. *Veterinary Clinics of North America - Small Animal Practice* 45, 769–782.

Byron, J.K. (2018). Diseases of Abnormal Micturition, in: Ettinger, S.J., Feldman, E.C., Côté, E. (editors), *Textbook of Veterinary Internal Medicine: Diseases of the Dog and the Cat*. Eighth edition, Elsevier, St. Louis, Missouri, USA, p. 4852.

Byron, J.K., March, P.A., Chew, D.J., DiBartola, S.P. (2007). Effect of phenylpropanolamine and pseudoephedrine on the urethral pressure profile and continence scores of incontinent female dogs. *Journal of Veterinary Internal Medicine* 21, 47–53.

Byron, J.K., Taylor, K.H., Phillips, G.S., Stahl, M.S. (2017). Urethral sphincter mechanism incompetence in 163 neutered female dogs: diagnosis, treatment, and relationship of weight and age at neuter to development of disease. *Journal of Veterinary Internal Medicine* 31, 442–448.

Claeys, S., Rustichelli, F., Noël, S., Hamaide, A. (2011). Clinical evaluation of a single daily dose of phenylpropanolamine in the treatment of urethral sphincter mechanism incompetence in the bitch. *Canadian Veterinary Journal* 52, 501–505.

Currao, R.L., Berent, A.C., Weisse, C., Fox, P. (2013). Use of a percutaneously controlled urethral hydraulic occluder for treatment of refractory urinary incontinence in 18 female dogs. *Veterinary Surgery* 42, 440–447.

de Bleser, B., Brodbelt, D.C., Gregory, N.G., Martinez, T.A. (2011). The association between acquired urinary sphincter mechanism incompetence in bitches and early spaying: A case-control study. *Veterinary Journal* 187, 42–47.

DiBartola, S.P., Westropp, J.L. (2014). Disorders of micturition. In: Nelson, R.W., Couto, C.G. (editors), *Small Animal Internal Medicine*. Fifth edition, Elsevier, St. Louis, Missouri, USA, p. 704–705.

Fischer, J., Lane, I.F. (2011). Micturition disorders, in: Bartges, J., Polzin, D.J. (editors), *Nephrology and Urology of Small Animals*. Wiley-Blackwell, Ames, Iowa, USA, p. 755–756.

Fischer, J., Lane, I.F. (2017). Urinary incontinence and urine retention, in: Elliott, J., Grauer, G.F., Westropp, J.L. (editors), *BSAVA Manual of Canine and Feline Nephrology and Urology*. Third edition, British Small Animal Veterinary Association, Gloucester, UK, p. 24–36.

Forsee, K.M., Davis, G.J., Mouat, E.E., Salmeri, K.R., Bastian, R.P. (2013). Evaluation of the prevalence of urinary incontinence in spayed female dogs: 566 cases (2003–2008). *Journal of the American Veterinary Medical Association* 242, 959–962.

Hamaide, A.J., Grand, J.G., Farnir, F., Le Couls, G., Snaps, F.R., Balligand, M.H., Versteegen, J.P. (2006). Urodynamic and morphologic changes in the lower portion of

- the urogenital tract after administration of estriol alone and in combination with phenylpropanolamine in sexually intact and spayed female dogs. *American Journal of Veterinary Research* 67, 901–908.
- Hoeijmakers, M., Janszen, B., Coert, A., Horspool, L. (2003). Pharmacokinetics of oestriol after repeated oral administration to dogs. *Research in Veterinary Science* 75, 55–59.
- Holt, P.E. (1985a). Urinary incontinence in the bitch due to sphincter mechanism incompetence: surgical treatment. *Journal of Small Animal Practice* 26, 237–246.
- Holt, P.E. (1985b). Importance of urethral length, bladder neck position and vestibulovaginal stenosis in sphincter mechanism incompetence in the incontinent bitch. *Research in Veterinary Science* 39, 364–372.
- Holt, P.E. (1985c). Urinary incontinence in the bitch due to sphincter mechanism incompetence: prevalence in referred dogs and retrospective analysis of sixty cases. *Journal of Small Animal Practice* 26, 181–190.
- Holt, P.E. (1990). Urinary incontinence in dogs and cats. *Veterinary Record* 127, 347–350.
- Holt, P.E., Thrusfield, M. V. (1993). Association in bitches between breed, size, neutering and docking, and acquired urinary incontinence due to incompetence of the urethral sphincter mechanism. *Veterinary Record* 133, 177–180.
- Labato, M.A. (2018). Pollakiuria, stranguria, and urinary incontinence. In: Ettinger, S.J., Feldman, E.C., Côté, E. (editors), *Textbook of Veterinary Internal Medicine: diseases of the dog and the cat*. Eighth edition, Elsevier, St. Louis, Missouri, USA, p. 670.
- Mandigers, P.J., Senders, T., Rothuizen, J. (2006). Morbidity and mortality in 928 Dobermanns born in the Netherlands between 1993 and 1999. *Veterinary Record* 158, 226–229.
- Mandigers, R.J., Nell, T. (2001). Treatment of bitches with acquired urinary incontinence with oestriol. *Veterinary Record* 149, 764–767.
- O'Neill, D.G., Riddell, A., Church, D.B., Owen, L., Brodbelt, D.C., Hall, J.L. (2017). Urinary incontinence in bitches under primary veterinary care in England: prevalence and risk factors. *Journal of Small Animal Practice* 58, 685–693.
- Reichler, I.M., Hubler, M. (2014). Urinary incontinence in the bitch: an update. *Reproduction in Domestic Animals* 49, 75–80.
- Reichler, I.M., Hubler, M., Jöchle, W., Trigg, T.E., Piché, C.A., Arnold, S. (2003). The effect of GnRH analogs on urinary incontinence after ablation of the ovaries in dogs. *Theriogenology* 60, 1207–1216.
- Reichler, I.M., Jöchle, W., Piché, C.A., Roos, M., Arnold, S. (2006). Effect of a long acting GnRH analogue or placebo on plasma LH/FSH, urethral pressure profiles and clinical signs of urinary incontinence due to Sphincter mechanism incompetence in bitches. *Theriogenology* 66, 1227–1236.
- Richter, K.P., Ling, G. V. (1985). Clinical response and urethral pressure profile changes after phenylpropanolamine in dogs with primary sphincter incompetence. *Journal of the American Veterinary Medical Association* 187, 605–611.
- Schotanus, B.A., De Gier, J., Van Der Lugt, J.J., Okkens, A.C. (2008). Estriolum treatment in the bitch: A risk for uterine infection? *Reproduction in Domestic Animals* 43, 176–180.
- Scott, L., Leddy, M., Bernay, F., Davot, J.L. (2002). Evaluation of phenylpropanolamine in the treatment of urethral sphincter mechanism incompetence in the bitch. *Journal of Small Animal Practice* 43, 493–496.
- Sontas, H.B., Dokuzeylu, B., Turna, O., Ekici, H. (2009). Estrogen-induced myelotoxicity in dogs: A review. *The Canadian Veterinary Journal* 50, 1054–1058.
- Stöcklin-Gautschi, N.M., Hässig, M., Reichler, I.M., Hubler, M., Arnold, S. (2001). The relationship of urinary incontinence to early spaying in bitches. *Journal of Reproduction and Fertility, Supplement* 57, 233–236.
- Thrusfield, M. V, Holt, P.E., Muirhead, R.H. (1998). Acquired urinary incontinence in bitches: its incidence and relationship to neutering practices. *Journal of Small Animal Practice* 39, 559–566.
- Van Goethem, B., Schaeffers-Okkens, A., Kirpensteijn, J. (2006). Making a rational choice between ovariectomy and ovariohysterectomy in the dog: A discussion of the benefits of either technique. *Veterinary Surgery* 35, 136–143.
- Wang, K.Y., Samii, V.F., Chew, D.J., McLoughlin, M.A., DiBartola, S.P., Mast, J., Lehman, A.M. (2006). Vestibular, vaginal and urethral relationships in spayed and intact normal dogs. *Theriogenology* 66, 726–735.
- White, R.A., Pomeroy, C.J. (1989). Phenylpropanolamine: an alpha-adrenergic agent for the management of urinary incontinence in the bitch associated with urethral sphincter mechanism incompetence. *Veterinary Record* 125, 478–480.
- White, R.N. (2001). Urethropexy for the management of urethral sphincter mechanism incompetence in the bitch. *Journal of Small Animal Practice* 42, 481–486.

## Long-term results of tenoscopic treatment of lesions in the digital flexor tendon sheath: a retrospective study of fifty horses

*Langetermijnresultaten van tenoscopische behandeling van letsels in de sesamschede: een retrospectieve studie van vijftig paarden*

<sup>1</sup>F. Thünker, <sup>1</sup>M. Oosterlinck, <sup>1</sup>K. Vanderperren, <sup>1</sup>A. Martens

<sup>1</sup>Department of Veterinary Medical Imaging and Small Animal Orthopedics, Faculty of Veterinary Medicine, Ghent University, Salisburylaan 133, 9820 Merelbeke

Franziska.Thuenker@gmx.de

### ABSTRACT

**Injuries to the structures within the digital flexor tendon sheath (DFTS) can be the primary cause of non-infectious tenosynovitis, for which diagnostic and therapeutic tenoscopy can be performed. In this retrospective study, the medical records of fifty horses that underwent tenoscopic treatment of non-infectious tenosynovitis of the DFTS from 2008 to 2016 at the Faculty of Veterinary Medicine (Ghent University), were evaluated. Telephonic follow-up information was obtained for forty horses.**

**In jumping horses, front limbs were significantly more often involved, whereas in non-jumping horses, the hind limbs were affected more frequently ( $P=0.01$ ). Lesions of the deep digital flexor tendon (DDFT) were observed in 45% of the cases and lesions of the manica flexoria (MF) in 39% of the cases. Ultimately, 27.7% of horses with lesions of the DDFT and 53% of horses with lesions of the MF returned to their original level of performance, with a mean follow-up period of  $4.6 \pm 2.5$  years.**

### SAMENVATTING

Letsels ter hoogte van structuren in de sesamschede kunnen de primaire oorzaak zijn van niet-infectieuze tenosynovitis, waarbij tenoscopie zowel diagnostisch als therapeutisch aangewend kan worden. In deze studie werden de gegevens van vijftig paarden uit de databank van de Faculteit Diergeneeskunde (UGent) verzameld, die in de periode van 2008 tot 2016 een tenoscopische behandeling van niet-infectieuze tenosynovitis van de sesamschede ondergingen. Telefonische follow-up informatie kon van veertig paarden worden bekomen.

Bij springpaarden waren de voorbenen significant vaker aangetast dan de achterbenen, terwijl letsels bij paarden die niet voor jumping gebruikt werden, frequenter ter hoogte van de achterbenen werden vastgesteld ( $P=0,01$ ). Letsels van de diepe buigpees vertegenwoordigden 45% van de gevallen terwijl er in 39% van de gevallen letsels ter hoogte van de manica flexoria waren. Uiteindelijk konden 27,7% van de paarden met laesies van de diepe buigpees en 53% paarden met laesies van de manica flexoria terug op hun oorspronkelijk niveau worden ingezet met een gemiddelde follow-upperiode van  $4,6 \pm 2,5$  jaar.

### INTRODUCTION

The digital flexor tendon sheath (DFTS) is a synovial structure at the palmar/ plantar aspect of the fetlock region, surrounding the superficial digital flexor tendon (SDFT) and the deep digital flexor tendon (DDFT) (Stanek, 2006; König and Liebich, 2008). The DFTS starts at the distal third of the metacarpus/

metatarsus and ends just proximal of the navicular bursa (König and Liebich, 2008). Three annular ligaments are incorporated into the palmar/ plantar wall of the DFTS (Stanek, 2006; König and Liebich, 2008; Schramme and Smith, 2010). The proximal annular ligament (lig. anulare palmare/plantare) (PAL) surrounds the flexor tendons at the level of the fetlock/ proximal sesamoid bones and may appear as a con-

strictive band when distension of the DFTS is present. This distension is commonly caused by a lesion within the DFTS. A primary desmitis of the proximal annular ligament is more rarely observed (König and Liebich, 2008; Dyce et al., 2010; Jordana et al., 2013) and may lead to constriction of structures within, and subsequently lead to distension of the DFTS. Distal to the fetlock, the quadrilateral proximal digital annular ligament (lig. anulare digitale proximale) attaches laterally and medially to the proximal phalanx by two bands (Wissdorf et al., 1998; Schramme and Smith, 2010). The middle part of this ligament covers the SDFT and partially adheres to it (Wissdorf et al., 1998; König and Liebich, 2008). The distal digital annular ligament (lig. anulare digitale distale) is located more distally in the pastern and adheres to the terminal portion of the DDFT (König and Liebich, 2008; Schramme and Smith, 2010).

At the level of the fetlock, the SDFT encircles the DDFT with a circular, tendinous structure, known as the manica flexoria (MF) (Schaller et al., 2007; König and Liebich, 2008).

Trauma to structures within the DFTS may result in non-infectious tenosynovitis (Nixon 2002; Stanek, 2006; Schramme and Smith, 2010; Arensburg et al., 2011), which can cause various degrees of lameness and distension of the DFTS, but which can also be subclinical. In acute cases, the distended DFTS may be warm and painful on palpation (Stashak, 2002; Stanek, 2006; Bertone, 2011). In chronic cases, fibrosis and adhesions may hinder adequate palpation of the flexor tendons (Stashak, 2002; Stanek, 2006; Schramme and Smith, 2010; Bertone, 2011).

Intrathecal anesthesia of the DFTS is the most specific anesthesia for localizing injuries to structures within the DFTS (Fortier, 2005; Schramme and Smith, 2010; Fiske-Jackson et al., 2013). However, not all lesions respond similarly to intrathecal anesthesia. Tears of the DDFT typically present a more positive response after intrathecal anesthesia than tears of the MF, and in many cases, only partial improvement is observed after intrathecal anesthesia (Fiske-Jackson et al., 2013). From a diagnostic point of view, it is also important to realize that the effects of intrathecal anesthesia may not be specific. Depending on the injection technique used, leakage of local anesthetic solution may result in inadvertent desensitization of other structures, mainly the foot (Schneider et al.,

2003; Jordana et al., 2012, 2013, 2014). Diffusion to the palmar/ plantar digital nerves causes desensitization at the level of the heel bulbs (Jordana et al., 2014). Jordana et al. (2012) also showed that lower leakage scores were obtained using the injection technique described by Hassel et al. (2000) at the axial aspect of the lateral proximal sesamoid bone. Moreover, this injection technique has been shown to result in the highest number of successful injections compared with three other approaches: at the distal aspect of the DFTS (pastern approach), at the proximal aspect of the DFTS, and at the base of the lateral sesamoid bone (Jordana et al., 2012).

In case of distension, ultrasound examination of the DFTS is very useful to detect underlying pathology and in these cases, all structures related to the DFTS should be evaluated. Ultrasonographic abnormalities may include fluid accumulation within the DFTS, synovial proliferations, adhesions or masses, tears in the flexor tendons or the MF, desmitis of the annular ligaments and tendinitis of the SDFT and DDFT (Edinger et al., 2005; Schramme and Smith, 2010; Bertone, 2011). Distension of the DFTS typically results in an accumulation of synovial fluid between the DDFT and the proximal annular ligament (Arensburg et al., 2011).

False positive and false negative results have been reported on ultrasonographic examination depending on the type of lesion, with exact numbers differing between authors (Edinger et al., 2005; Arensburg et al., 2011; Fiske-Jackson et al., 2013). Lesions of the MF are more often underestimated than lesions of the DDFT, but there are more false positive results for lesions of the DDFT (Fortier, 2005; Arensburg et al., 2011; Fiske-Jackson et al., 2013; Cauvin and Smith, 2014). In different studies, data have been reported on diagnostic sensitivity and specificity of ultrasound examination for lesions of the MF and the DDFT, which are summarized in Table 1.

Contrast radiography has been reported to have an excellent sensitivity for lesions of the MF (96%), whereas the sensitivity for lesions involving the DDFT is lower (57%) (Fiske-Jackson et al., 2013). Therefore, this technique has been recommended in combination with ultrasound (Fortier, 2005; Fiske-Jackson et al., 2013; Cauvin and Smith, 2014).

As ultrasound and contrast radiography do not always result in a final diagnosis, tenoscopy offers addi-

**Table 1. Published sensitivities and specificities of ultrasound examination for lesions of the MF and the DDFT.**

Reference	MF		DDFT	
	Sensitivity	Specificity	Sensitivity	Specificity
Erdinger et al. (2005)	-	-	90.5%	53.8%
Arensburg et al. (2011)	-	-	63%	75%
Smith and Wright (2006)	38%	92%	71%	71%



tional diagnostic perspectives (Cauvin, 2003; Edinger et al., 2005; Jordana et al., 2013). The basis of endoscopic approach to the DFTS has been described by Nixon (1990), with slight modifications of the technique described by Wilderjans et al. (2003) and McIlwraith et al. (2015). Tenoscopic surgery is minimally invasive and can be used to diagnose lesions on the surface of the flexor tendons, the MF and the wall of the DFTS (Cauvin 2003; Davis and Smith, 2006).

In case of injury to the DDFT, SDFT and/or MF, loose fibers are debrided, adhesions and synovial masses within the DFTS can be removed (Fortier, 2005; Arensburg et al., 2011; Jordana et al., 2013). In case of a MF lesion, this structure, depending to the extent of pathology, can be removed partially or completely during the tenoscopic intervention (Smith and Wright, 2006; Schramme and Smith, 2010; Findley et al., 2012; Jordana et al., 2013). When preoperative ultrasonographic examination reveals thickening of the PAL, or in case of a functional constriction of the fetlock canal formed by the PAL, a desmotomy of the PAL can be performed during the tenoscopic intervention (Nixon et al., 1993; Fortier et al., 1999; Wilderjans et al., 2003; Smith and Wright, 2006; Owen et al., 2008; Jordana et al., 2013).

Postoperatively, the limb is bandaged for two to four weeks (Wright and McMahan, 1999; Wilderjans et al., 2003; Cauvin, 2003; Smith and Wright, 2006). Some authors recommend hand-walking starting three to four days postoperatively (Nixon, 2002). Usually, horses are treated postoperatively with NSAIDs for seven to ten days (Nixon, 2002; Smith and Wright, 2006; Jordana et al., 2013). The use of an intrasynovial injection of hyaluronic acid two weeks after the surgery has been described to reduce adhesion formation (Amiel et al., 1989; Moro-oka et al., 2000; Nixon, 2002), although in many cases, intrathecal administration of any medication is postponed until four to six weeks postoperatively.

The duration and intensity of convalescence depend on the primary injury and can vary from some weeks to several months (Wright and McMahan, 1999; Davis and Smith, 2006; Jordana et al., 2013).

The prognosis depends on the primary pathology causing the tenosynovitis (Schramme and Smith, 2010), and it has been described that the prognosis is better for lesions of the MF than for lesions of the DDFT (Davis and Smith, 2006; Smith and Wright, 2006; Arensburg et al., 2011; Findley et al., 2012; Jordana et al., 2013). Smith and Wright (2006) concluded that 67% of horses with lesions of the MF returned to their original level of performance, whereas 42% of cases with lesions of the DDFT returned to their pre-injury level of exercise, with a mean follow-up period of 21 months. The cosmetic result is generally guarded because of frequent chronic distension of the DFTS (Arensburg et al., 2011; Bertone, 2011).

The aim of this retrospective study was to describe the long-term results of tenoscopic treatment of non-infectious injuries in the DFTS.

## MATERIAL AND METHODS

### Cases

The medical records of all horses and ponies with non-infectious tenosynovitis of the DFTS treated tenoscopically at the Faculty of Veterinary Medicine of Ghent University from April 2008 to March 2016 were evaluated. Affected horses were classified according to their activity into jumping horses (including jumping, combined dressage and jumping, and eventing) and non-jumping horses (dressage, recreation, carriage driving, and horses only kept at pasture without athletic pursuits).

### Information and follow-up

Relevant information derived from the patient records in the clinic database and telephone contact with the owner included date of consultation, age, sex, breed, primary level of training/competition, duration of lameness before the examination, previous problems with non-septic tenosynovitis or preceding treatment(s), affected limb(s), ultrasonographic, radiographic and tenoscopic findings, specific details regarding the tenoscopic intervention, postoperative treatment and rehabilitation, additional treatment(s), functional and cosmetic results, postoperative level of training/competition, and recurrent problems.

### Statistical analysis

Chi-square analysis was performed to evaluate the association between the affected limb (front versus hind, left versus right) and the use of the horse (jumping versus non-jumping horses). Moreover, considering the results of the ultrasonographic versus tenoscopic evaluation, the sensitivity and specificity of ultrasonographic examination for lesions of the DDFT and the MF were calculated. Chi-square analysis was used to investigate: (1) the association between the number of injured structures and the return to the original level of performance, (2) the association between whether or not section of the annular ligament was performed and the cosmetic and functional result, and finally (3) the association between persistent swelling and lameness.

All statistical analyses were performed using GraphPad InStat3, with  $P < 0.05$  considered statistically significant. Data are presented as mean  $\pm$  standard deviation (SD) unless stated otherwise.

## RESULTS

### Clinical results

Based on clinical records from the hospital database, fifty horses were included in this study. Ulti-



**Table 2. Prevalence of injuries in the right and left front and hind limbs in jumping and non-jumping horses.**

	Left	Jumping horses Right	Total
Front limb	46.7% (7/15)	53.3% (8/15)	57.7% (15/26)
Hind limb	54.5% (6/11)	45.5% (5/11)	42.3% (11/26)
<b>Non-jumping horses</b>			
Front limb	25% (1/4)	75% (3/4)	20% (4/20)
Hind limb	68.8% (11/16)	31.3% (5/16)	80% (16/20)

mately, follow-up information could be obtained from 40/50 (80%) cases, with a mean  $\pm$  SD follow-up period of  $4.6 \pm 2.5$  years.

Age ranged between 2 and 21 years (mean  $\pm$  SD  $10.5 \pm 4.6$  years). There were 60% mares (30/50), 38% geldings (19/50) and 2% stallions (1/50). The horses' main discipline was only known for 42 horses, of which 57.1% (24/42) were classified as jumping horses [jumping (17/42; 40.5%), dressage and jumping (6/42; 14.3%), eventing (1/42; 2.4%)] and 42.9% (18/42) were classified as non-jumping horses [dressage (5/42; 11.9%), recreation (10/42; 23.8%), carriage driving (1/42; 2.4%) or kept at pasture (2/42; 4.8%)].

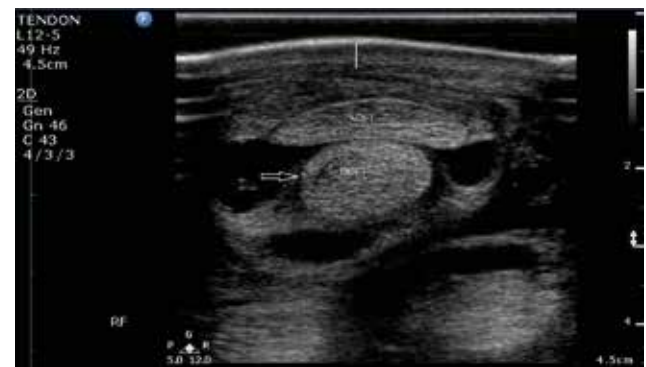In three of the fifty horses, bilateral tenoscopy was performed (in one horse, both hind limbs presented a MF lesion; in one horse, both hind limbs had a DDFT lesion; in the third horse, the left hind limb had a MF lesion and the right hind limb had both a MF and a DDFT lesion). In the third horse, the left limb was even treated a second time six years later, revealing an additional DDFT lesion that was not detected during the initial surgery. Only in one of the three horses with bilateral lesions, tenoscopy was performed in both hind limbs at the same time. Therefore, in total, there were 54 tenoscopies in fifty cases. In general, no significant difference was observed between the number of affected hind limbs, in horses (28/46 or 60.9%) and in ponies (6/8 or 75%) compared with front limb injuries (18/46 or 39.1% in horses and 2/8 or 25% in ponies) ( $P=0.445$ ). However, a significantly higher prevalence ( $P=0.01$ ) of the hind limb lesions was seen in non-jumping horses (80%; 16/20) compared with jumping horses (42.3%; 11/26). Thus, in jumping horses, the front limbs were affected more often (57.7%; 15/26).

In both jumping and non-jumping horses, there was no significant difference in prevalence of injuries to the left and right limb, as shown in Table 2.

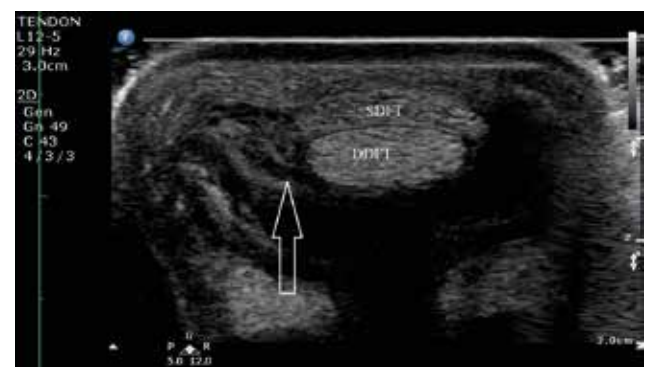### Ultrasonography

In 51/54 (94.4%) of cases, a complete ultrasonographic examination and corresponding report were available in the clinic database. In 23/51 (45.1%) of

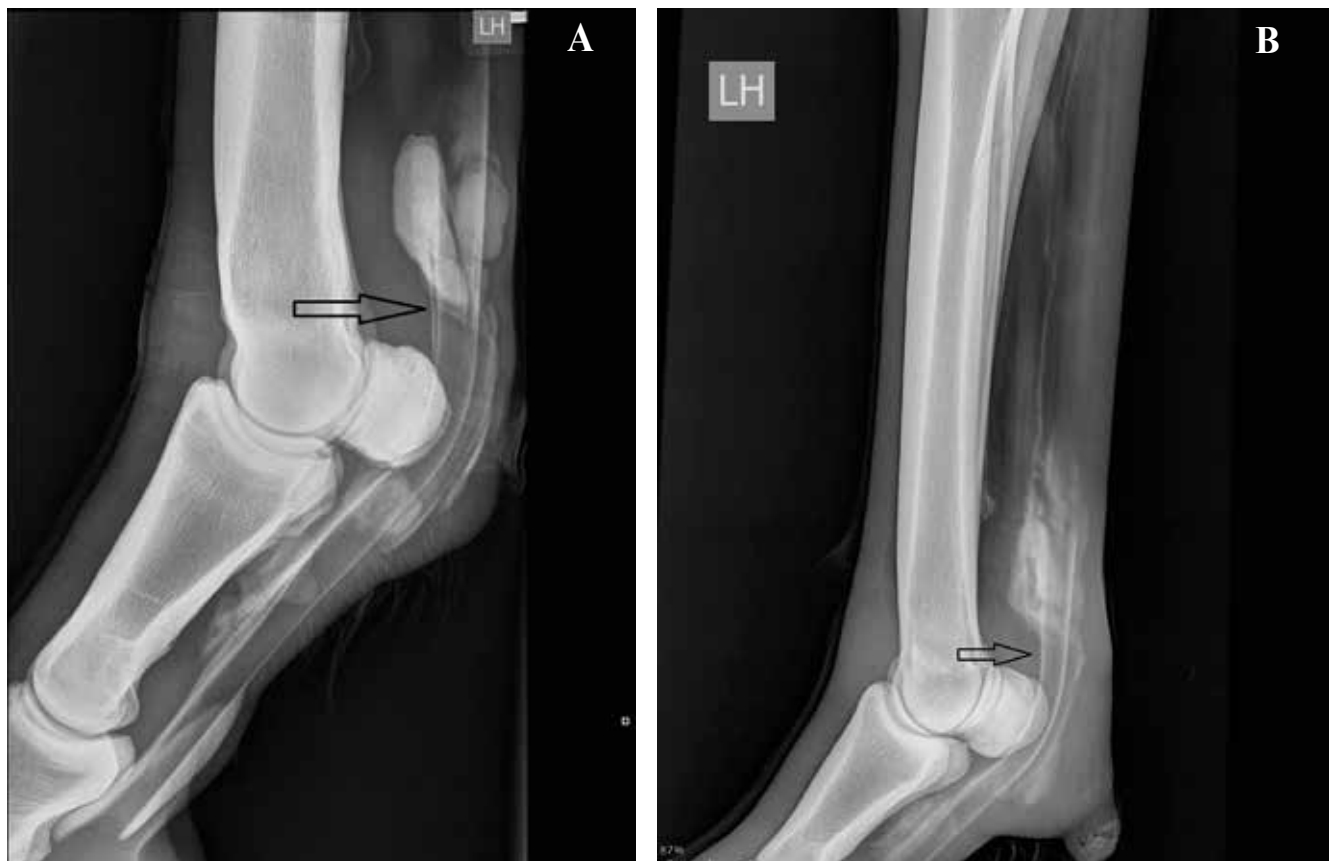cases, tenoscopy revealed a DDFT lesion of which 15/23 (65.2%) were accurately predicted by ultrasonography and 8/51 (15.7%) ultrasonographic examination were considered false negative (Figure 1). However, in 6/51 (11.8%) cases, the ultrasonography



**Figure 1.** Transverse ultrasound image (lateral is to the left) of the proximal portion of the DFTS distended by anechoic fluid. There is a lesion at the lateral border of the DDFT, evident as a slightly irregular outline of the tendon surface (arrow) with a hypoechoic area within the lateral aspect of the DDFT. Also note the thickening of the subcutaneous tissues (vertical white line) and the wall of the digital flexor tendon sheath. DFTS= digital flexor tendon sheath; DDFT= deep digital flexor tendon; SDFT= superficial flexor tendon.



**Figure 2.** Transverse ultrasound image, proximal to the fetlock at the level of the MF. Complete rupture of the MF with a complete lateral dislocation (arrow). Note the distention of the DFTS with anechoic fluid. DDFT= deep digital flexor tendon; SDFT= superficial digital flexor tendon; MF= manica flexoria.



**Figure 3. Contrast radiography of the DFTS. A. Normal DFTS with intact MF, visible as two parallel lines (arrow). The dorsal line is the MF and the palmar/plantar line is the dorsal limitation of the DDFT. B. Rupture of the MF. The MF is not visible, i.e. there is no double line visible (arrow), only the line at the dorsal aspect DDFT is visible. DFTS = digital flexor tendon sheath; MF = manica flexoria.**

resulted in a false positive diagnosis of a DDFT lesion. Tenoscopy revealed MF lesions in 20/50 (40%) cases, of which only 9/20 (45%) were identified by ultrasound preoperatively (Figure 2). For MF lesions, there were only two false positive diagnoses after ultrasonographic examination.

The ultrasonographic data resulted in a sensitivity of 74.2% and a specificity of 82.4% for the diagnosis

of lesions of the DDFT, whereas for lesions of the MF, the sensitivity of ultrasound was 64.5% and the specificity was 94%.

Tears in the SDFT and primary lesions of the PAL were rarely diagnosed by tenoscopy (8/54 (14.8%) and 2/54 (3.7%), respectively), while they were more often diagnosed by ultrasonographic examination (12/51 (23.5%) and 9/51 (17.6%), respectively).

**Table 3. In 20/50 horses, radiographic information was available. In eleven of these twenty horses, more than one radiographic abnormality was noted.**

Radiographic findings	Number	In combination with
Soft tissue swelling	7	1 Osteophytosis of the fetlock 3 Mineralization (annular ligament, second phalanse, collateral ligament)
Osteophytosis	4	1 Soft tissue swelling
Lesion MF	1	-
No findings	3	-
Tarsus – no findings	1	-
Contrast radiography:		
Lesion MF	2	-
Lesion DDFT	2	-
	20	

## Radiography

In 20/50 horses, radiographic information was available. In eleven of these horses, more than one radiographic abnormality was noted (Table 3).

In 7/20 (35%) cases, a soft tissue swelling could be seen at the palmar/plantar aspect of the fetlock or the pastern. In one (1/7) of these cases, degenerative changes (mild osteophytosis) at the level of the fetlock joint were also detected, and in 3/7 cases, soft tissue swelling in combination with mineralization of the soft tissues at the level of the second phalanx, the PAL or the lateral collateral ligament of the fetlock were observed. New bone formation (at the insertion of the PAL, the oblique sesamoidean ligaments, and the medial sesamoid bone) was also detected without other pathologies in 4/20 (20%) cases. In 3/20 (15%) cases, radiography did not reveal any abnormalities. In one case (5%), a MF lesion was suspected, which was confirmed tenoscopically. Contrast radiography was performed in 4/20 cases: a tear of the MF was visualized in 2/20 cases, whereas a lesion of the DDFT was detected in the other 2/20 cases (Figure 3). These findings were all confirmed tenoscopically.

## Tenoscopy

All unilateral tenoscopies (52/54) were performed in lateral recumbency with the affected limb uppermost. Bilateral surgeries (2/54) were performed in dorsal recumbency.

In 47/54 (87%) cases, only one structure within the DFTS was injured, whereas in 3/54 (5.6%) cases, multiple injuries were noticed (in particular DDFT lesions in combination with MF or SDFT lesions), and in 4/54 (7.4%) cases, tenoscopy could not reveal any gross pathology. Altogether, lesions of the DDFT were most frequently diagnosed (25/54; 46.3%) (Figure 4), while the MF was injured in 19/54 (35.2%) cases (Figure 5), SDFT injury was seen in 8/54 (14.8%) cases and PAL pathology was detected in 2/54 (3.7%) cases. DDFT and especially MF lesions were seen more frequently in the hind limbs than in the front limbs (13/25; 52% and 16/19; 84%, respectively). In all DDFT and SDFT tears, torn fibers were removed using a mechanical shaver (Dyonics Power, Smith and Nephew, Hamburg, Germany). Care was taken to debride torn fibers from the most proximal to the most distal aspect of the lesion.

The MF was partially removed in 9/19 (47.4%) cases and completely removed in 8/19 (42.1%) (Figure 6). The remaining two cases (10%) were only shaved, debrided and flushed.

In 23/54 (42.6%) cases, the PAL was sectioned. The main indication was in 6/23 (26.1%) cases a constriction or swelling of the annular ligament itself and in 16/23 (69.6%) cases, the annular ligament was sectioned in combination with the treatment of other lesions within the DFTS, in order to release the

tension within the fetlock canal. In 1/23 (4.3%) case, no lesion was diagnosed during tenoscopy, but ultrasonographically and also radiographically, an insertion desmopathy was visualized; new bone formation was noted at the level of the medial insertion of the PAL.

## Postoperative care and rehabilitation

Postoperatively, all patients were treated with NSAIDs for two to seven days (mean  $3.6 \pm 1.1$  days). Antibiotic therapy was only given in seven cases (6/7 penicillin, for two to three days and 1/7 doxycycline, for six days). These specific cases were more complex with severe tears of the DDFT and/or adhesions within the DFTS and/or section of the PAL or the MF. Routine postoperative care included regular bandage changes (every three to four days). Bandaging was continued until two or three days after removal of the skin sutures, which was performed 14 days after surgery.

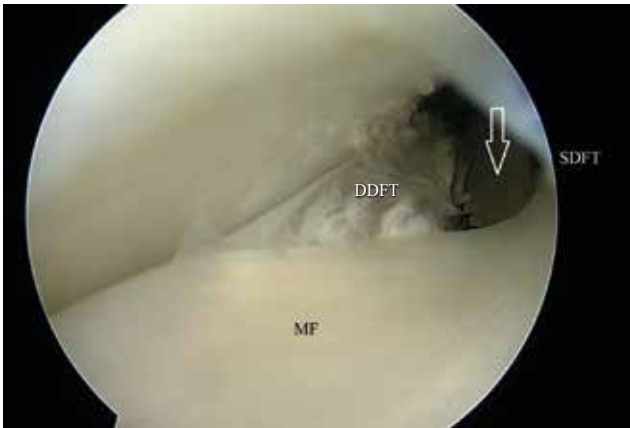
In 33/54 (61.1%) cases, injection of the DFTS with a corticosteroid, e.g. 12mg triamcinolone acetonide, with or without hyaluronic acid was advised, three to twelve weeks after surgery. Intrathecal injection of the DFTS was performed at the clinic in 16/33 (48%) cases, whereas the other cases were treated by the referring veterinarian; there was no detailed information about the products and dosages used in those cases.

After tenoscopy, all horses started with a period of absolute box rest, varying from two days (small lesions of MF) to four weeks (severe lesions, desmotomy of the PAL and/or MF). The duration and intensity of rehabilitation varied according to the primary lesion. In most cases, the horses received controlled walking (preferably hand-walking) for four to six weeks, followed by gradual increasing ridden walking exercise, depending on the severity of the injury.

A follow-up visit at the clinic was recommended three months after surgery, or sooner if the owner noticed any problems. When the check-up revealed a favorable clinical course (decreased distension of the DFTS, decreased lameness), light trotting exercise was introduced until the next evaluation between four and six months after surgery. In cases with a positive evolution at the second check-up, the workload was gradually increased. Follow-up ultrasound examination was performed in 8/25 cases of DDFT tears, but was not performed in any of the MF tear cases (0/19). Overall, 20/50 (40%) returned to the clinic for follow-up visits. Of these, 13/20 cases returned once, 4/20 cases returned twice and 3/20 returned three times to the clinic for follow-up.

Some owners (6/50; 12%) preferred an extended period of rest with the horse being used for breeding or kept at pasture; these horses did not follow the proposed schedule.

Additional therapeutic farriery was rarely performed; in most cases, the regular shoeing was con-



**Figure 4.** Tenoscopy of the DFTS with the scope positioned proximal of the annular ligament and directed distally. There is a tear at the lateral border of the DDFT. From a portal distal to the annular ligament, mechanical debridement of the lateral lesion of the DDFT is performed (arrow). This lesion extends under the MF. DFTS = digital flexor tendon sheath; DDFT = deep digital flexor tendon; MF = manica flexoria; SDFT = superficial digital flexor tendon.

tinued. Egg-bar shoes were used in one jumping horse with a DDFT lesion. No specific changes in the trimming or shoeing protocol were recommended in all other cases.

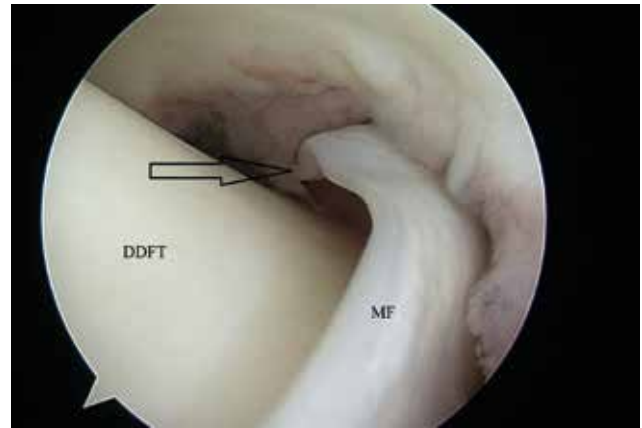
### Follow-up

Follow-up information was available for 42/54 tenoscopies (or 40/50 horses). Overall, 47.5% (19/40) of the horses treated tenoscopically returned to their original level of performance, although the proportion of horses without lameness was 65% (26/40). Thirty-five percent (14/40) of the horses remained lame and were not ridden anymore. There was no significant difference regarding the return to the original level of training or competition between cases with one (19/39; 48.7%) or multiple lesions (2/3; 66.7%) ( $P=0.592$ ).

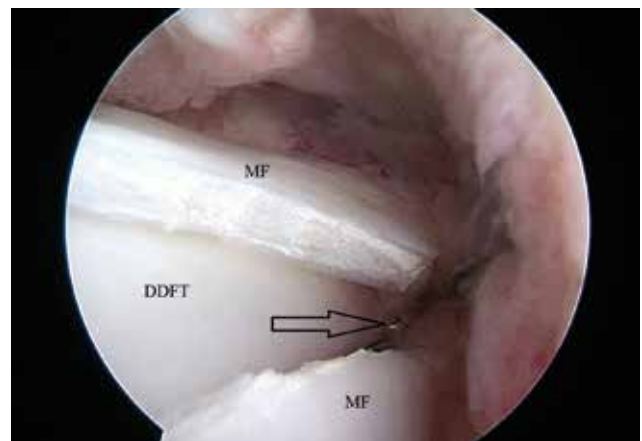
There were no significant associations between the functional and the cosmetic outcome after tears of the MF and DDFT: 66.7% (12/18) of the horses with tears in the DDFT became sound, which was not significantly different from 60% (9/15) of the horses with tears in the MF ( $P=0.692$ ). For lesions of the DDFT, there was no postoperative effusion of the DFTS in only 27.8% (5/18) of the cases, while 46.7% (7/15) of the cases with lesions of the MF were without effusion ( $P=0.216$ ).

In total, 27.7% (5/18) of the cases with lesions of the DDFT and 53% (8/15) of the cases with lesions of the MF returned to their original level of performance.

Tears in the SDFT and primary lesions of the PAL were rarely diagnosed (8/54 and 2/54, respectively), precluding statistical analysis. However, 80% (4/5) of the horses with SDFT lesions were sound and 60% of them presented without any palpable abnormalities.



**Figure 5.** Tenoscopy of the DFTS. The scope is positioned just distal to the annular ligament and is directed proximally. Rupture of the MF (arrow). The distal border of the MF is not in close contact with the DDFT as a result of a tear of its medial attachment to the SDFT. DFTS = digital flexor tendon sheath; DDFT = deep digital flexor tendon; MF = manica flexoria; SDFT = superficial digital flexor tendon.



**Figure 6.** Tenoscopy of the DFTS. A hook knife (arrow) is used for the transection of the lateral attachment of the MF onto the SDFT allowing a complete resection of the MF. After transection the DDFT becomes clearly visible. DFTS = digital flexor tendon sheath; MF = manica flexoria; DDFT = deep digital flexor tendon; SDFT = superficial flexor tendon.

One of the two cases with primary injury of the PAL was not lame and did not present any palpable abnormality.

In the study sample of fifty horses, 23 desmotomies of the PAL were completed in twenty of the horses. Follow-up information was only available for 15 of these horses. There was no significant association between desmotomy of the PAL and the final outcome (after desmotomy: 60% (9/15) without lameness; without desmotomy: 68% (17/35) without lameness). No postoperative effusion was noticed in 46.7% (7/15) of the horses with a desmotomy of the



PAL, while in cases without desmotomy, there was no effusion in 52% (13/25).

There was a significant association between lameness and distension ( $P=0.02$ ). Sixty-five percent (17/26) of the horses without lameness did not have any effusion postoperatively, whereas 78.6% (11/14) of the lame horses presented with distension of the DFTS after surgery.

As mentioned previously, there were more horses without lameness (26/40) than horses performing at their original level (20/40). When these horses (6/26) were trained more intensively, they presented with lameness, and therefore, owners decided to use them for hacking (2/6), leisure (1/6), dressage at a lower level (2/6) or for breeding purposes (1/6).

## DISCUSSION

This retrospective study documents the long-term results of tenoscopic treatment of fifty horses with non-infectious tenosynovitis. Through this study, it was possible to provide a mean follow-up period of 4.6 years, which is significantly longer than the period of 21 months reported in an earlier study by Smith and Wright (2006). Arensburg et al. (2011) reported a minimum follow-up of nine months but did not provide more details such as mean or median of the follow-up period.

In jumping horses, significantly more lesions were observed in the forelimbs than in the hind limbs, whereas in non-jumping horses, the hind limbs were affected more frequently. In a study by Smith and Wright (2006) and a study by Arensburg et al. (2011), lesions in the DDFT were seen more frequently in the fore limbs, and lesions in the MF were seen more frequently in the hind limbs. In contrast with Arensburg et al. (2011), who described a higher prevalence of DDFT lesions in the right forelimb in jumping horses, the current study revealed a higher frequency of lesions in the left fore limb. The reason for this difference remains unclear but may be linked to the smaller number of cases in this study and differences between the study samples.

Interestingly, the present study is the first to report a significant association between lameness and postoperative distension of the DFTS, highlighting the usefulness of a postoperative follow-up of these patients.

In agreement with the literature (Stashak, 2002; Fortier, 2005; Stanek, 2006), the present study sample confirms that tears in the DDFT (25/54; 46.3%) and the MF (19/54; 35.2%) are the most common injuries causing non-infectious tenosynovitis, and together, they make up more than 80% of the injuries encountered in this synovial structure.

In earlier studies, the prognosis of tears in the MF has been claimed to be better compared to DDFT lesions (Davis and Smith, 2006; Smith and Wright,

2006; Arensburg et al., 2011; Findley et al., 2012). In the study by Smith and Wright (2006), 67% of horses with tears of the MF and 42% of horses with tears of the DDFT returned to their original level of performance. The long-term results of the current study could not reveal a statistically significant difference in either the cosmetic result for MF versus DDFT tears (46.7%; 7/15 versus 27.8%; 5/18), or the functional result for MF versus DDFT tears (66.7%; 12/18 versus 60%; 9/15).

Although ultrasonography is very useful for visualizing the underlying pathology, this study supports the previously described limitations of ultrasonography regarding sensitivity and specificity, especially for tears in the MF (Fortier, 2005; Smith and Wright, 2006; Fiske-Jackson et al., 2013). The current study reported false positive and false negative results for lesions in the DDFT and the MF. To overcome some of these limitations, contrast radiography has been recommended as a useful adjunctive technique (Fortier, 2005; Smith and Wright, 2006; Fiske-Jackson et al., 2013; Cauvin and Smith, 2014), and is currently part of the routine protocol at the Faculty of Veterinary Medicine (Ghent University) for patients with suspected pathology within the DFTS.

Regarding the long-term outcome after desmotomy of the PAL, the current study revealed rather disappointing cosmetic and functional results. After desmotomy of the PAL, 60% of the horses were not lame and 47% did not present any effusion, whereas without desmotomy of the PAL, 68% were not lame and 52% did not present any effusion. This may be subject to treatment bias, because very chronic or severe cases were more likely to be treated by desmotomy of the PAL. In a study by Owen et al. (2008), the success rate of desmotomy was also lower (42%) than in other studies (McGhee et al., 2005), because of rather complicated cases with PAL desmopathy. Although previous studies have not identified an association between distension of the DFTS and clinical problems (Fortier et al., 1999; Stanek, 2006; Arensburg et al., 2011), this study has revealed a significant association between lameness and distension. Therefore, distension of the DFTS can be noted as a continuum of the pathology.

Interestingly, 65% of the horses were free of lameness after tenoscopy, but only 50% returned to their original level of training. The other horses (15%) only tolerated a lower level of performance. Regarding the return to the original level of training, there was no significant difference between cases with single (48.7%) or multiple lesions (66.7%), although it is difficult to draw final conclusions on this comparison. Unfortunately, it is not known how many of these horses could perform at a lower level without surgery.

There is potential for improvement regarding the recommendations for therapeutic trimming and shoeing, especially in cases of DDFT pathology; egg-bar shoes or other forms of palmar/plantar support, in combination with optimized break-over, may be bene-



ficial for these cases as recently reviewed by Oosterlinck et al. (2017).

The present retrospective clinical study suffers from the inherent limitations of a lack of control group, the lack of randomization of the treatment to individual cases and the heterogeneity of the study groups. Moreover, the long-term follow-up was obtained by telephone interview, relying on the owner's perception of each individual case.

## CONCLUSION

The most frequent primary pathologies within the DFTS are tears of the DDFT and tears of the MF. After a follow-up period of  $4.6 \pm 2.5$  years, 27.7% of the horses with DDFT injury and 53% of the horses with MF were able to return to their previous level of performance, which is a considerably poorer result than reported previously in studies with a shorter follow-up period. More research is needed to develop superior treatment strategies for horses with these lesions and provide evidence-based, long-term information on treatment efficacy.

## REFERENCES

- Amiel D., Kenneth I., Edmund B., Wiig M., van de Berg J., Akeson W.H., Gelberman R. (1989). Hyaluronan in flexor tendon repair. *The Journal of Hand Surgery* 14A, 837-843.
- Arensburg L., Wilderjans H., Simon O., Dewulf J., Bousauw B. (2011). Nonseptic tenosynovitis of the digital flexor tendon sheath caused by longitudinal tears in the digital flexor tendons: A retrospective study of 135 tenoscopic procedures. *Equine Veterinary Journal* 43, 660-668.
- Bertone A.L. (2011). The fetlock. In: Baxter G.M. (editor). *Adams and Stashak's Lameness in Horses*. Sixth edition, Wiley-Blackwell, West Sussex, pp. 594-620.
- Cauvin E.R.J. (2003). Tenoscopy and bursoscopy. In: Dyson S.J., Ross M.W. (editors). *Diagnosis and Management of Lameness in the Horse*. First edition, Elsevier Science, St. Louis, Missouri, pp. 230-235.
- Cauvin E.R.J., Smith R.K.W. (2014). Ultrasonography of the fetlock. In: Frazer K.L., Kidd J.A., Lu K.G. (editors). *Atlas of Equine Ultrasonography*. First edition, Wiley-Blackwell, West Sussex, pp. 45-72.
- Davis C.S., Smith R.K.W. (2006). Diagnosis and management of tendon and ligament disorders. In: Auer J.A., Stick J.A. (editors). *Equine Surgery*. Third edition, Saunders Elsevier, St. Louis, Missouri, pp. 1086-1111.
- Dyce K.M., Sack W.O., Wensing C.J.G. (2010). *Textbook of Veterinary Anatomy*. Fourth edition, Saunders Elsevier, St. Louis, Missouri, pp. 604-609.
- Edinger J., Möbius G., Fergusson J. (2005). Comparison of tenoscopic and ultrasonographic methods of examination of the digital flexor tendon sheath in horses. *Veterinary and Comparative Orthopaedics and Traumatology* 18, 209-214.
- Findley J.A., De Oliveira F., Bladon B. (2012). Tenoscopic surgical treatment of tears of the manica flexoria in 53 Horses. *Veterinary Surgery* 41, 924-930.
- Fiske-Jackson A.R., Barker W.H.J., Eliashar E., Foy K., Smith R.K.W. (2013). The use of intrathecal analgesia and contrast radiography as preoperative diagnostic methods for digital flexor tendon sheath pathology. *Equine Veterinary Journal* 45, 36-40.
- Fortier L.A., Nixon A.J., Ducharme N.G., Mohammed H.O., Yeager A. (1999). Tenoscopic examination and proximal annular ligament desmotomy for treatment of equine "complex" digital sheath tenosynovitis. *Veterinary Surgery* 28, 429-435.
- Fortier L.A. (2005). Indications and techniques for tenoscopic surgery of the digital flexor tendon sheath. *Equine Veterinary Education* 17, 218-224.
- Hassel D.M., Stover S., Yarbrough B., Drake C.M., Taylor K.T. (2000). Palmar-plantar axial sesamoidean approach to the digital flexor tendon sheath in horses. *Journal of the American Veterinary Medical Association* 217, 1343-1347.
- Jordana M., Oosterlinck M., Pille F., Valère A., Martens A. (2012). Comparison of four techniques for synoviocentesis of the equine digital flexor tendon sheath: A cadaveric study. *Veterinary and Comparative Orthopaedics and Traumatology* 25, 178-183.
- Jordana M., Martens A., Oosterlinck M., Vanderperren K., Pille F. (2013). Tenosynovitis van de sesamschede bij het paard: diagnostiek en behandeling. *Vlaams Diergeneeskundig Tijdschrift* 82, 225-233.
- Jordana M., Martens A., Duchateau L., Vanderperren K., Saunders J., Oosterlinck M., Pille F. (2011). Distal limb desensitisation following anaesthesia of the digital flexor tendon sheath in horses using four different techniques. *Equine Veterinary Journal* 46, 488-493.
- König H.E., Liebich H.-G. (2008). *Anatomie der Haus-säugetiere: Lehrbuch und Farbatlas für Studium und Praxis*. Vierte Auflage, Schattauer GmbH, Stuttgart, pp. 203-210.
- McGhee J.D., White N.A., Goodrich L.R. (2005). Primary desmitis of the palmar and plantar annular ligaments in horses: 25 cases (1990-2003). *Journal of the American Veterinary Medical Association* 226, 83-86.
- McIlwraith C.W., Nixon A.J., Wright I.M. (2015). Tenoscopy. In: McIlwraith C.W., Nixon A.J., Wright I.M. (editors). *Diagnostic and Surgical Arthroscopy in the Horse*. Fourth edition, Mosby, Elsevier, pp. 344-386.
- Moro-oka T., Hiromasa M., Mawatari T., Kawano T., Nakanishi Y., Higaki H., Iwamoto Y. (2000). Mixture of hyaluronic acid and phospholipid prevents adhesion formation on the injured flexor tendon in rabbits. *Journal of Orthopaedic Research* 18, 835-840.
- Nixon A.J. (1990). Endoscopy of the digital flexor tendon sheath in horses. *Veterinary Surgery* 19, 266-271.
- Nixon A.J., Sams A.E., Ducharme N.G. (1993). Endoscopically assisted annular ligament release in horses. *Veterinary Surgery* 22, 501-507.
- Nixon A.J. (2002). Arthroscopic surgery of the carpal and digital tendon sheaths. *Clinical Techniques in Equine Practice* 1, 245-256.
- Oosterlinck M., Dumoulin M., Van de Water E., Pille F. (2017). Biomechanische aspecten met betrekking tot hoefbeslag bij paarden. *Vlaams Diergeneeskundig Tijdschrift* 86, 256-265.
- Owen K.R., Dyson S.J., Parkin T.D.H., Singer E.R., Kristoffersen M., Mair T.S. (2008). Retrospective study of

- palmar/plantar annular ligament injury in 71 horses: 2001-2006. *Equine Veterinary Journal* 40, 237-244.
- Schaller, O., Simoens P., Constantinescu G.M. (2007). *Illustrated Veterinary Anatomical Nomenclature*. Second edition, Enke Verlag, Stuttgart, p. 118.
- Schneider R.K., Gavin P.R., Tucker R.L (2003). What magnetic resonance imaging is teaching us about navicular disease. In: *Proceedings of the American Association of Equine Practitioners* 49, 210-219.
- Schramme M.C., Smith R.K. (2010). The soft tissues: Diseases of the digital flexor tendon sheath, palmar annular ligament, and digital annular ligament. In: Dyson S.J., Ross M.W. (editors). *Diagnosis and Management of Lameness in the Horse*. Second edition, Elsevier Saunders, St. Louis, pp. 764-776.
- Smith M.R.W., Wright I.M. (2006). Noninfected tenosynovitis of the digital flexor tendon sheath: a retrospective analysis of 76 cases. *Equine Veterinary Journal* 38, 134-141.
- Stanek C. (2006). Erkrankungen der Fesselbeugensehnen-scheide. In: Dietz O., Huskamp B. (editors). *Handbuch der Pferdepraxis*. Dritte Auflage, Enke Verlag, Stuttgart, pp. 933-941.
- Stashak T.S. (2002). *Adam's Lameness in Horses*. Fifth edition, Lippincott Williams and Wilking, Philadelphia, pp. 630-640.
- Wilderjans H., Boussauw B., Madder K., Simon O. (2003). Tenosynovitis of the digital flexor tendon sheath and annular ligament constriction syndrome caused by longitudinal tears of the deep digital flexor tendon: a clinical and surgical report of 17 cases in Warmblood horses. *Equine Veterinary Journal* 35, 370-375.
- Wissdorf H., Gerhards H., Huskamp B. (1998). *Praxisorientierte Anatomie des Pferdes*. Erste Auflage, Verlag M. & H. Schaper Alfeld, Hannover, pp. 315-316.
- Wright I.M., McMahon P.J. (1999). Tenosynovitis associated with longitudinal tears of the digital flexor tendons in horses: A report of 20 cases. *Equine Veterinary Journal* 31, 12-18.

## Spontaneous realigning of a displaced equine premolar post extraction of an adjacent supernumerary tooth – two cases

*Spontane repositie van een equiene premolaar na extractie van een aanpalende polydonte tand – twee casussen*

E. Pollaris, K. Vanderperren, G.A.M. De Pauw, L. Vlamincx

Department of Surgery and Anesthesiology of Large Animals, Faculty of Veterinary Medicine, Ghent University, Salisburylaan 133, 8920 Merelbeke

Elke.pollaris@ugent.be

### ABSTRACT

Two horses were presented with problems during ridden exercise due to a firm, sensitive swelling at the level of the cheek adjacent to an upper Triadan 06. Oral, radiographic and computed tomographic examinations (n=1) identified the presence of a palatal supernumerary tooth being the causing factor of a buccally displaced 06. In both cases, the supernumerary tooth was extracted on the standing sedated horse. A couple of months following extraction, the buccally displaced tooth had spontaneously moved into a more physiological position due to orthodontic forces of the cheek and masticatory forces. Both horses uneventfully returned to ridden work without further problems.

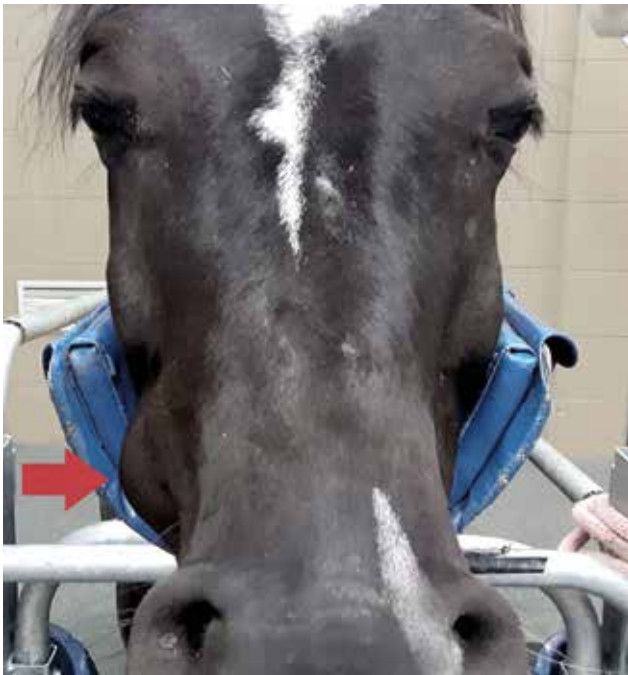### SAMENVATTING

Twee paarden met klachten tijdens het rijden omwille van de aanwezigheid van een harde, gevoelige zwelling van de wang ter hoogte van het niveau Triadan 06 in de bovenkaak werden aangeboden op de kliniek Heelkunde (Faculteit Diergeneeskunde, UGent). Mondonderzoek, radiografie en computertomografie (n=1) toonden de aanwezigheid van een polydonte tand aan, aan de palatale zijde van element 06, waardoor deze naar buccaal verplaatst werd. In beide gevallen werd de polydonte tand getrokken op het staande gesedeerde dier. Enkele maanden na de extractie vertoonde de buccaal verplaatste tand een repositie naar zijn fysiologische positie door de orthodontische kracht van de wangen en het kauwen. Beide paarden werden nadien opnieuw bereden zonder verdere problemen.

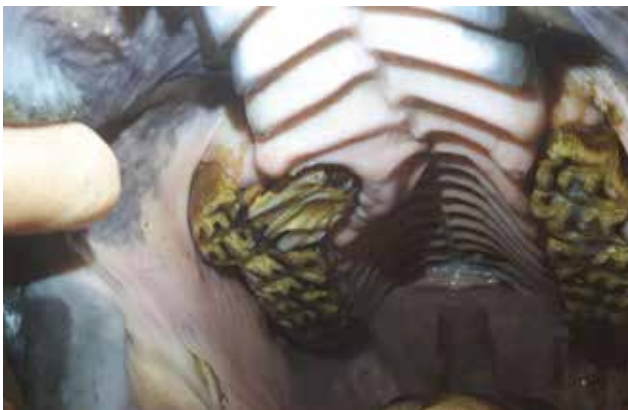### INTRODUCTION

A supernumerary tooth is defined as an additional tooth to the normal number of teeth. Their crown and root morphology as well as their position and eruption pattern can vary substantially from normal to aberrant (Garvey et al., 1999; Dixon et al., 2005b). They are more commonly located distal to the last maxillary cheek teeth although lingual/palatal, buccal and mesial positions have also been reported (Dixon et al., 1999b; Dixon et al., 2005b; Anthony et al., 2010; Rodrigues et al., 2013; Parés and Lozano, 2014). Epidemiological data are not available, but reported prevalences range from 0.6-9.1% to 0.2-2.9% at the level of the incisors and cheek teeth, respectively (Dixon, et al., 1999b; Dixon et al. 1999a; Dixon et al., 2005b; Anthony et al., 2010).

Malocclusion, resulting in abnormal occlusal morphology due to areas of reduced wear, and periodontal disease secondary to impacted food between the supernumerary and adjacent teeth are well-known consequences of polydontia. Treatment options include regular corrective odontoplasty, diastema cleaning, packing and/or widening and tooth extraction (Dixon et al., 2005b; Quinn et al., 2005; Dixon, 2011). A supernumerary tooth can additionally cause displacement of adjacent teeth (Garvey et al., 1999; Dixon et al., 2005b). Individually malpositioned teeth in humans can be realigned within the dental arch by applying orthodontic techniques using anchoring points (Reitan, 1967; Magkavali-Trikka et al., 2018). Indications for the use of comparable techniques in small animals have been reported for incisor and canine orthodontic problems (Ross, 1986; Emily, 1992).



**Figure 1.** A clear swelling (arrow) is present at the right cheek in the premaxillary region (case 1).



**Figure 2.** Intraoral view of the horse's mouth (case 1). At Triadan position 106, a buccally displaced tooth with normal crown morphology (106b) and a more irregularly shaped tooth in a more palatal position (106p) can be observed. The surrounding mucosa of the hard palate is thickened but not inflamed.

To date, orthodontic treatment in horses primarily focuses on correction of brachygnathia (Klugh, 2004; Easley and Schumacher, 2011; Easley et al., 2016), although limited literature about principles of equine orthodontics has been published (Fletcher, 2008; Galloway, 2008; Earley et al., 2013).

Physiologic tooth position is determined by interactions between the periodontal tissues and occlusal, tongue and lip forces. Disruption of this equilibrium is known to cause pathologic tooth migration (Weinstein et al., 1963; Proffit, 1978; Ruan et al. 2005). Therefore, post-extraction drift forces initiated by the angulated position of cheek teeth and their continued eruption are capable of closing an extraction gap over time (Vlaminck et al., 2006; Vlaminck et al., 2008).

In this case report, the spontaneous repositioning of a buccally displaced 106 following extraction of an adjacent supernumerary tooth in two horses is described.

## CASE 1

### History

A six-year-old Arabian gelding was presented for examination of a slowly enlarging localized swelling of the right cheek. This resulted in a progressive expression of riding difficulties over the last year due to interference with the bridle's nose band. Masticatory problems were not observed.

### Clinical and oral examination

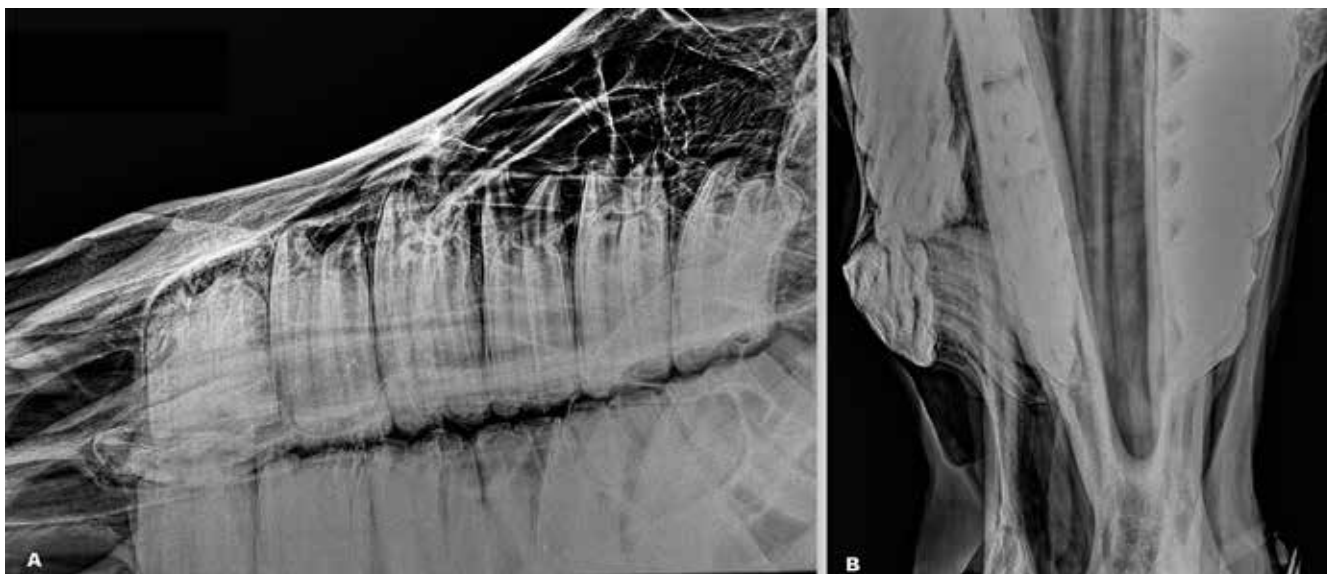
There was marked asymmetry of the head due to an out-bulging of the cheek overlying the right maxillary premolar region, which was hard and sensitive on palpation (Figure 1). Oral examination revealed the presence of an additional tooth at the Triadan 106 position. A buccally displaced tooth crown (106b) demonstrated normal occlusal surface features, apart from a slightly prominent mesial tip. There was evidence of excessive previous floating on the buccal side of this tooth. An adjacent, palatally positioned cheek tooth crown (106p) with a highly irregular occlusal oriented side seemed to have developed in a more horizontal plane (Figure 2). A small diastema between both crowns and between 106p and 107 were minimally impacted with food. Endoscopic examination of the right nasal passage showed a slightly constricted ventral nasal meatus at a distance coinciding with the position of the cheek tooth anomaly.

### Medical imaging

Radiographic examination (right30° ventral–left-dorsal oblique, dorsoventral with offset mandible) was performed of the right maxillary region and demonstrated the buccally displaced 106b with a deviation and interruption of the maxillary bone at this level and an additional tooth-like structure palatal to 106b. A mild blunting of the tooth roots was observed, but there were no other radiographic signs of apical changes (Figure 3).

Subsequently, a computed tomographic (CT) examination of the head with a 4-slice scanner (Light-Speed QX/i, GE Medical Systems, Milwaukee, Wisconsin, USA) was performed with the gelding under general anesthesia in dorsal recumbence. Acquisition variables were 120kV, 160mA, 2.5 mm slice thickness, a pitch of 3, 1.25s rotation time, 275 mm field of view, and matrix size of 512 × 512. Images were evaluated using DICOM viewing software (Osirix v5.6 64 bit, Open Source, <http://www.osirix-viewer.com>). CT examination confirmed the presence of





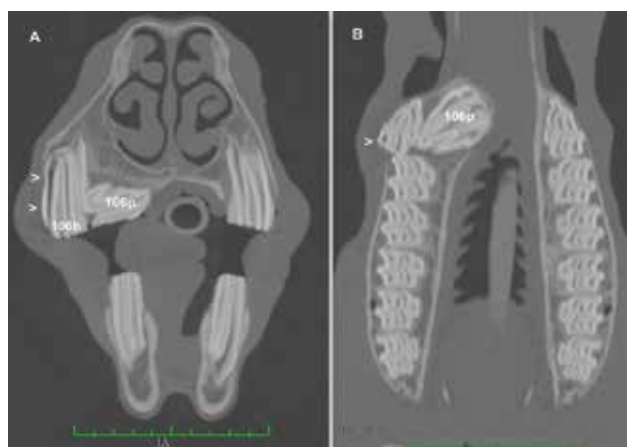
**Figure 3. A. Rt30°V-LeD-O and B. Dorsoventral with offset mandible radiographic projections (case 1). A. Mild blunting of the tooth roots is visible. A superimposed tooth structure is visible at the level of the clinical crown of Triadan 106. B. The Triadan 106 tooth is buccally displaced causing deviation of the maxillary bone. A more horizontally positioned tooth structure is visible at the palatal aspect of Triadan 106. This structure contacts both 106 and 107. Left is right.**

two separate teeth. Element 106b erupted in a vertical but significant more buccal position than Triadan 206 (Figure 4). The buccal cortical and alveolar bone was not distinguishable at the level of the reserve crown. The palatal alveolar bone was only present in the apical third of the tooth. Element 106p, which was considered the supernumerary tooth, was more horizontally positioned with its apical area located near the midline and rostral to the most mesial edge of 106b. Its crown was directed slightly distoventral and contacted the distopalatal aspect of 106b causing an indentation of the tooth at that level. Element 106p was embedded in dense bone tissue. Narrowing of the ventral nasal meatus at the level of the position of 106p was evident. Both teeth displayed a normal internal architecture with five pulp horns and two infundibula. The distopalatal root of 106b was absent and at this level there was a mildly widened periapical space and thickening of the cortical bone. Pulp horn 2 (Du Toit et al., 2008) of 106b showed a low density along its entire length and at the most apical aspect of this pulp chamber, there appeared to be a partial mineralization (Figure 4).

### Treatment

Mild apical changes observed around element 106b were considered secondary as a result of apical inflammation due to abnormal forces exerted at this level by the presence of the supernumerary tooth (Ketcham, 1929; Newman, 1975) or due to excessive floating at this level (thermal pulpar insult) (Spierings et al., 1985; Zach and Cohen, 1965; O'leary et al., 2013). Specific treatment was not considered necessary at this stage. Treatment was directed at extraction of 106p. In the second stage after allowing sufficient

healing time for the extraction site, an orthodontic procedure was planned to realign 106b with the other cheek teeth in that arch. The intention was to perform an orthodontic procedure to displace the tooth 106b to its normal position after healing of the extraction site with using temporary anchorage device (TAD). TAD's are biocompatible screws or mini-implants fixed to bone for the purpose of moving teeth in humans for a certain period of time, with the devices being subsequently removed after orthodontic treatment. The plan was to insert lag screws in the cortical



**Figure 4. A. Transverse and B. Dorsal reconstructed computed tomographic images of the horse's head in bone algorithm (case 1). A. Transverse image taken at the level of pulp horn 2 of Triadan 106b. The right side of the horse's head is clearly deformed due to the abnormal position of the premolar teeth. Low density of the pulp canal indicate the presence of pulp pathology (arrow heads). B. The supernumerary 106p has substantially displaced 106b. Pulp canal 2 of 106b shows a low density (arrow head).**





**Figure 5.** Cast models of the right maxillary premolar region (case 1). Left: four days after extraction. Triadan 106b is clearly buccally positioned and the extraction defect is visible. Middle: six months post extraction. The 106b clinical crown has moved into alignment with the dental arcade. A small open diastema has developed between 106b and 107. The hard palate defect is decreased in size. Right: nineteen months post extraction. The Triadan 106b has slightly rotated causing the diastema to close on the palatal aspect of the interproximal space. The hard palate defect has further decreased in size and depth.



**Figure 6.** Dorsal view of the horse's head after six months illustrating the disappearance of the external swelling (case 1).

bone of the palate. Then, an elastic chain could be attached from the screw heads around the tooth to deliver a light continuous force on the tooth that would be capable of producing a tooth movement without tissue damage. Orthodontic tooth displacement uses the potential of the periodontal ligament for bone remodeling (Cope, 2005; Papadopoulos and Tarawneh, 2007; Schatzle et al., 2009; Magkavali-Trikka et al., 2018).

Preoperatively, the horse received sodium benzylpenicillin (penicillin 20.000 IU/kg i.v., Kela Veterinaria NV, Sint Niklaas, Belgium), benzylpenicilinum procainum (Peni-kel, 21.000 IU/kg i.m., Kela Veterinaria NV, Sint Niklaas, Belgium) and flunixin meglumine (Emdoflunin 50,1.1 mg/kg i.v., Emdoka BVBA, Hoogstraten, Belgium). A standing oral tooth extraction of the palatal tooth was performed under i.v. sedation with detomidine (Detogesic, Ballinskelligs Veterinary Products, Ballinskelligs, Kerry, Ireland) (15 µg/kg) combined with butorphanol (Torbugesic, 25 µg/kg, zoetis Manufacturing & Research Spain, S.L., Girona, Spain) initially. Further increments of sedatives were administered as required. Regional anesthesia of the right maxillary nerve was performed with 10 ml mepivacaine (scandicaine 2%, Dornier Medtech Europe, Wessling, Germany) as described by Staszuk et al. (2008). Following placement of a full mouth speculum, additional local anesthetic (Procaine hydrochloride 4%, 15 ml, VMD vetsupport Benelux, Arendonk, Belgium) was infiltrated in the mucosa of the right cheek at the level of 106b and in the mucosa of the hard palate surrounding 106p. The gingiva surrounding the tooth was separated from 106p using a dental pick and the tooth was loosened with elevators. A screw extraction technique was used to remove the tooth because the specific position and shape of the tooth did not allow use of extraction forceps (Stoll, 2007). Due to the tooth's rostral location, a transbuccal approach was not necessary as all instruments could be introduced directly through the mouth. A 6 mm-diameter hole was drilled 2 cm into the tooth. This hole was tapped, which allowed firm anchorage of the extraction pin. Removal of the tooth followed using a slotted hammer system. After extraction, the alveolus was rinsed and gauzes soaked in chlorhexidine digluconate 0.1% (Hibitane, Molnlycke Health Care, Goteborg, Sweden) were placed inside to be removed two days postextraction. The alveolus was subsequently left open to heal by second intention. The horse received phenylbutazone (butagran Equi2.2 mg/kg btw p.o., Dopharma Research B.V., Raamsdonksveer, the Netherlands) once daily for seven days. Four days after extraction, a dental impression of the right upper premolars was made using polyvinylsiloxane (president putty, Coltène-Whaledent, Altstätten, Switzerland) and a dental cast was subsequently obtained for orthodontic treatment planning (Figure 5). Seven days post surgery, the horse was discharged from the clinic.

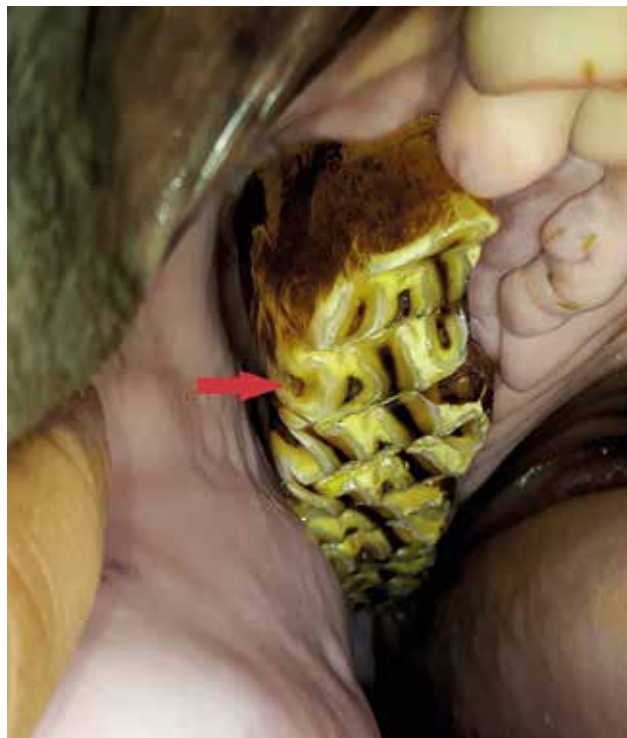## Follow-up

Bitless riding activities were started four weeks after surgery and a bit was reintroduced two weeks later, which was well accepted by the horse. The external swelling progressively decreased in time, which resulted in absence of any riding difficulties at the time of resuming ridden activities.

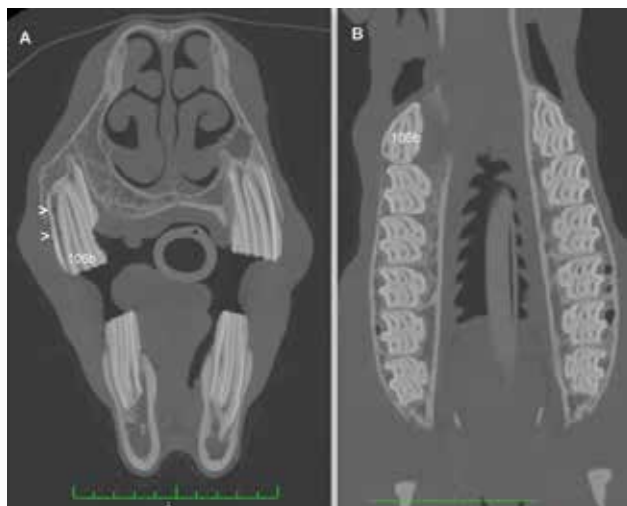
Four months after extraction, an oral inspection was performed at the horse's property. The horse showed no clinical symptoms and could be ridden without problems. The external swelling was much reduced. The extraction site was covered with healthy gingiva. Tooth 106b was slightly mobile and had moved palatally, more in line with the other cheek teeth. A small open diastema was found between 106b and 107 without any further periodontal problems.

Six months after surgery, the horse was readmitted to the clinic. The original external swelling was not visible anymore (Figure 6). A small, non-painful bony swelling could be palpated at the level of the apical region at the Triadan 106 position. On oral examination, a more palatal position of 106b was evident with its buccal side almost parallel to the buccal plane of the right upper dental arcade. Digital manipulation of the tooth revealed a slightly increased mobility. Gingival attachment around the tooth was firm. The open diastema that developed between 106-07 remained uncomplicated by any periodontal changes. A defect in the occlusal secondary dentin was detected at the level of pulp horn 2 of 106b (Figure 7). A new dental cast was made after taking another dental impression (Figure 5). CT examination was repeated under general anesthesia as described above. The positional change of Triadan 106b was caused by a palatally directed tilting action, which in turn caused outward repositioning of the apical region with secondary cortical bone remodeling (Figure 8). Inside the number 2 pulp canal, two small, circular zones with a low density could be identified, indicative of ongoing pulp disease. The extraction site had healed and was filled by complex bony tissue. On the oral side of the hard palate, dense cortical bone had developed from the midline to halfway the distance to Triadan 106b. A palatal alveolar bony lining had not been restored, but the buccal alveolar lining had advanced more occlusally.

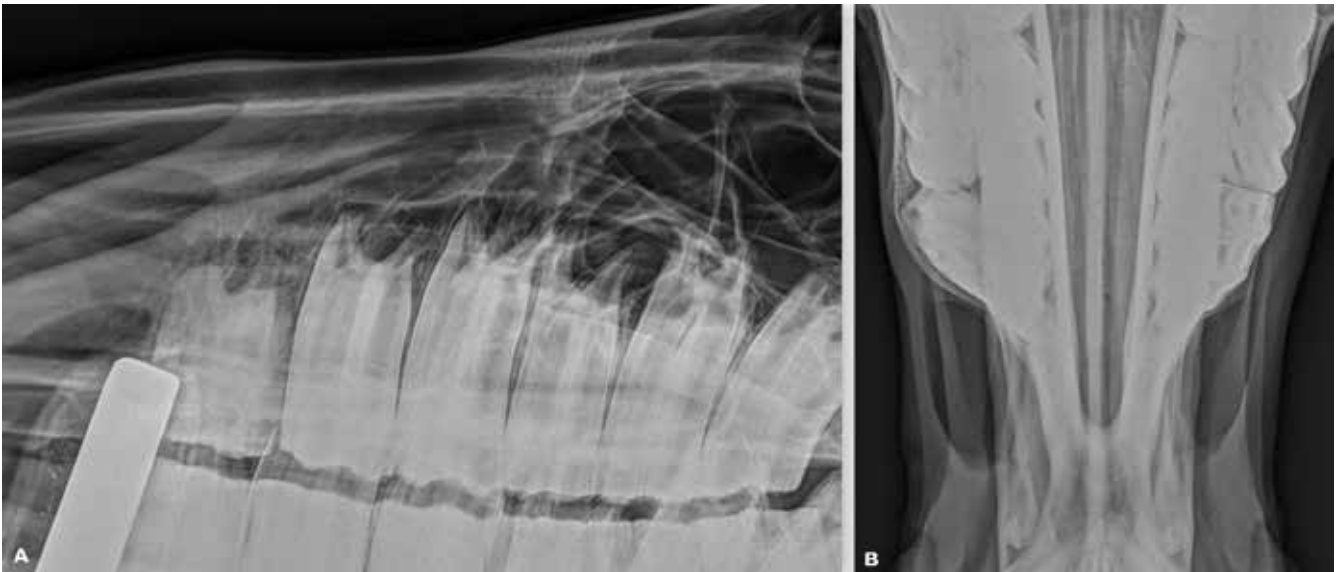
Three days later, an orthograde endodontic procedure was performed in the standing, sedated horse using the same sedation/regional analgesia protocol and intraoperative medical treatment as used for the extraction procedure (Lundstrom and Wattle, 2016). Access to pulp canal 2 was achieved using a water cooled high-speed hand piece mounted with a round bur. The pulp canal contained food and necrotic material and was subsequently debrided with different sizes Hedström files. The files could be advanced until the root, where a hard bottom was encountered. Due to the absence of evidence of insult to the other pulp horns on CT, the other pulp canals were not opened.



**Figure 7.** Intraoral view of the right maxillary arcade (case 1). Triadan 106b has moved to a better alignment with the other teeth. A defect is noted in the secondary dentine at the level of pulp horn 2 (arrow). There is clear evidence of excessive previously floating (at home) and a mesial overgrowth at the level of 106.



**Figure 8.** A. Transverse and B. Dorsal reconstructed computed tomographic images six months after extraction in bone algorithm (case 1). A. Transverse image taken at the level of pulp horn 2 of Triadan 106b. The extraction site is characterized by new bone formation. Triadan 106b has tipped towards the palatal side. The maxillary cortical bone adjacent to the apical region is irregular and thickened. Two zones with a low density in pulp horn 2 illustrate ongoing pulp disease (arrowheads). B. Better alignment of 106b with the dental arcade is visible. The palatal alveolar bone has not been restored yet.



**Figure 9. A. Rt30°V-LeD° and B. Dorsoventral radiographic projections (case 1). A. No gross radiographic changes indicative of apical disease are evident. The tooth roots are mildly blunted and the periodontal space is irregularly outlined. B. The tipped position of Triadan 106b is illustrated on this view. Deformation and thickening of the maxillary cortical bone on the buccal side of 106b are observed. Left is right.**

Pulp horn 2 was disinfected with sodium hypochlorite 3%, rinsed with sterile saline and dried. The pulp canal was filled with a cement (Provicol QM, VOCO, Cuxhaven, Germany) and a final restoration of the occlusal surface was performed with a dual cure, flowable composite material (Rebilda DC, VOCO, Cuxhaven, Germany). Two days later, the horse was discharged from the clinic.

Eighteen months after surgery, the horse was re-examined by the authors at home. He was performing without any clinical complaints, although he had suffered from a limb related lameness problem. The external residual swelling at the apical region had remained unchanged. Oral examination and a new dental cast showed that Triadan 106b had started to rotate palatal along its axis causing the distopalatal side to contact the mesiopalatal side of 107 (Figure 5). The surrounding gingival attachment was healthy. The occlusal restoration of pulp horn 2 was intact. Buccal gingival health and attachment were normal. A mesial overgrowth was present at the level of 106, which was reduced with motorized equipment to promote distal movement of element 106 (Collins and Dixon, 2005). The diastema between 106b and 107 had evolved to a valve diastema with food impaction on the palatal side, which caused a low degree of periodontal inflammation. The occlusal plateau opposite the diastema had developed a single accentuated transverse ridge on the mesial aspect of Triadan 407. The ridge was reduced with motorized equipment (Collins and Dixon, 2005). The diastema was debrided and packed with impression material (president putty, Coltène-Whaledent, Altstätten, Switzerland) to avoid recurrence of food impaction. Repeated radiographs of the right premolar area showed an irregular, outlined, periodontal space, but no gross indications for ongo-

ing apical inflammatory process. The tilted position of Triadan 106b and the subsequent bone remodeling at the apical region were evident on the dorsoventral projection (Figure 9).

## CASE 2

### History

An eight-year-old warmblood gelding was referred to the clinic for an abnormally sized premolar pushing against the cheek and causing an external swelling and riding difficulties (head tilt) of long duration. The swelling at the cheek was observed at the age of six. Masticatory problems were not observed.

### Clinical and oral examination

Clinical examination revealed no abnormal clinical parameters. On palpation of the head, there was a firm, sensitive swelling at the left cheek at the level of Triadan 206. On oral examination, a supernumerary tooth was observed on the mesiopalatal side of 206 (206m). This tooth showed a normal anatomical appearance (five areas of occlusal secondary dentin, two infundibula), but had an abnormally large size compared to the other cheek teeth. Tooth 206 (206b) was buccally displaced on its mesial side causing bruising of the cheek mucosa (red, inflamed). There was a diastema present between 206m and 206b with food impaction, but without signs of gingival inflammation. Except for some labial zones of increased wear on the mandibular and maxillary 02-03 incisors, no other dental anomalies were found.



## Medical imaging

Radiographic examination (laterolateral, left 30° ventral–rightdorsal oblique and dorsoventral projection) was performed of the left maxillary region, which showed no anomalies in the apical area. The dorsoventral projection illustrates the rotated position of 206b with a deformation and slight thickening of the maxillary cortical bone on the buccal side of the tooth (Figure 10).

## Treatment

A standing oral tooth extraction of supernumerary tooth (206m) was performed. Preoperatively, sedation and local analgesia protocol were performed as described in the first case. A dental impression of the left upper premolars was made using polyvinylsiloxane (president putty, Coltène-Whaledent, Altstätten, Switzerland). After extraction, the alveolus was rinsed and gauzes soaked in chlorhexidine digluconate 0.1% (Hibitane, Molnlycke Health Care, Göteborg, Sweden) were placed inside to be removed two days post extraction. The alveolus was subsequently left open to heal by second intention. The horse received phenylbutazone (butagran Equi, 2.2 mg/kg btw p.o., Dopharma Research B.V., Raamsdonksveer, the Netherlands) once daily for three days. Three days post surgery, the horse was discharged from the clinic with the advice to flush the mouth twice daily over a period of two weeks.

## Follow-up

The owner reported that three to four weeks after the extraction, the swelling was significantly reduced and the ridden work was progressively resumed. The horse's behavior during ridden work was significantly improved, with no recurrence of the previously reported head tilt.

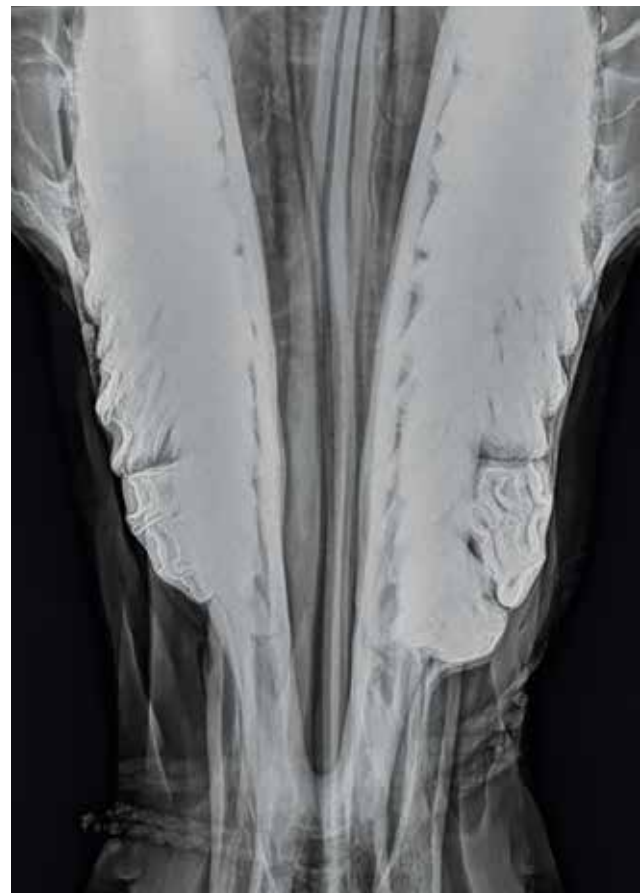Four months after extraction, the horse was readmitted to the clinic. On oral examination, element 206 showed a physiological position in line with the other cheek teeth, but had developed a mesial overgrowth, which was subsequently reduced with motorized equipment. The extraction site of element 206m was covered with healthy gingiva.

## DISCUSSION

Polydontia is a developmental dental abnormality that occurs in many species. The few studies that report on supernumerary cheek teeth in horses demonstrate the rarity of this pathology (Dixon et al., 1999a; Dixon et al., 1999b; Quinn et al., 2005). Some supernumerary cheek teeth are incidental findings on routine dental examinations. Disto-molars (a supernumerary cheek teeth triadan 12) are more frequently

encountered in the maxilla than in the mandible, often bilaterally (Dixon et al., 2005b; Quinn et al., 2005; Dixon, 2011; Pasicka et al., 2017). Clinical signs of oral discomfort appear as dental overgrowths and periodontal disease secondary to food impaction develop (Dixon et al., 2005b; Quinn et al., 2005; Parés and Lozano, 2014). Cases causing mild clinical symptoms can be conservatively managed by repeated reduction of overgrown teeth, and diastema cleaning, widening and/or filling (Baker, 1970; Carmalt, 2007). In unmanageable cases, extraction of the supernumerary tooth is the preferred treatment (Dixon et al., 1999b; Tremaine, 2004; Dixon et al., 2005a; Dixon et al., 2005b; de Mira et al., 2007).

The supernumerary tooth described in the first case seemed abnormally shaped based on its intraoral appearance. Further CT examination illustrated the presence of all three dental components arranged in a structured manner, but identified the tooth to be positioned in a more horizontal plane with the clinical crown touching the palatal side of Triadan 106b. Analysis of the acquired images allowed identification of this tooth as the supernumerary element. The characteristics of the intraorally visible tooth surface



**Figure 10.** Dorsoventral radiographic projection (case 2). The rotated position of 206b is illustrated. The mesial aspect of the tooth is buccally displaced. There is deformation and slight thickening of the maxillary cortical bone on the buccal side of the tooth. Right is left.



can be attributed in part by wear induced by direct and indirect contact with opposing teeth during mastication, although incomplete maturing of this tooth, its aberrant position of development and eruption pattern might also have contributed to its final shape. In the second case, the tooth showed a normal morphology, except for its larger size. Palatally positioned supernumerary teeth are known to be associated with displacement of the adjacent teeth (Dixon et al., 1999b; Quinn et al., 2005). Whether the palatal side of this tooth was attached to the hard palate by a functional periodontal membrane was not verified by histological processing. The presence of a functional periodontal attachment might have contributed to the abnormal position of the buccally displaced 106 in both cases.

Conservative management was not an option for these horses because the development of both adjacent teeth resulted in a localized swelling and abnormal riding behavior due to interference with the horse's bridle. The specific position and shape of the tooth precluded the use of molar spreaders or extraction forceps to complete a simple oral extraction procedure in the first case (Tremaine, 2004). The rostral position of the tooth allowed the use of the screw extraction technique (Stoll, 2007; Langeneckert et al., 2015) without the need to work transbuccally. Preoperative analysis of CT images allowed precise measurement of screw insertion depth to avoid inadvertent damage of the hard palate, which resulted in a straightforward extraction of the tooth.

The observed root resorption and hypoattenuation within pulp canal 2 seen on CT images of element 106 in the first case were attributed to the displacement of this tooth caused by abnormal forces executed by the presence of a supernumerary tooth. In human dentistry, it has been suggested that root resorption can be the result of heavy occlusal forces and/or malpositioning (Hemley, 1941; Ando et al., 1967). Another possible explanation could be an iatrogenic pulp insult due to excessive floating causing thermal pulpal damage with consequent later pulp exposure (Spierings et al., 1985; Zach and Cohen, 1965; O'leary et al., 2013).

Root resorption secondary to orthodontic treatment is well known (Ketcham, 1929; Newman, 1975; Hollender et al., 1980; Mirabella and Artun, 1995). Although element 106b was not subjected to an orthodontic treatment, it did undergo orthodontic forces due to the presence of 106p, which was considered etiological for the encountered apical changes. The hypoattenuation within pulp canal 2 most likely demonstrated the presence of a compromised pulp due to changes in the vascular supply. Six months after the initial presentation, this resulted in communication of this pulp canal with the oral environment, which necessitated an orthograde endodontic treatment.

The literature about the use of orthodontic appliances in horses to align individual malpositioned teeth is very limited (Fletcher, 2008; Galloway, 2008). Functional orthodontic correction of overjet or over-

bite in foals has been well described although this technique addresses growth retardation of the jaw bone rather than focusing on individual tooth position (Klugh, 2004; Easley and Schumacher, 2011; Easley et al., 2016). Unlike in equine dentistry, orthodontic principles are routinely used in humans and have also been reported in dogs and cats (Reitan, 1967; Ross, 1986; Emily, 1992; Surgeon, 2005; Nanci, 2013; Polkowska et al., 2014; Lothamer and Soukup, 2016; Magkavali-Trikka et al., 2018). It is generally known that the position of teeth and its supporting tissues can be easily modified by orthodontic therapy. The general principle is to exert controlled forces to induce tooth movement, which is based on the adaptive changes in surrounding bone and periodontal tissues (Roberts, 2012). For the first case, postulated orthodontic treatment included the insertion of two miniscrews in the bony hard palate, serving as anchoring points for the attachment of an elastic band encircling the crown of Triadan 106b at a level just above the gum line. This appliance should be able to induce a translational repositioning of the tooth. Six months follow-up CT images of the horse showed that good quality bone had developed at the extraction site, which would have allowed proper miniscrew placement. However, sufficient spontaneous tooth repositioning had occurred by that time, which resolved the original discomfort during ridden exercise and excluded the necessity to continue with the planned treatment.

CT analysis at six months postoperatively in the first case also showed the tooth to have repositioned by a palatally directed tipping displacement of the crown with associated buccal tipping of the roots causing local cortical bone remodeling and a residual, small, external deformation. Considering the starting position of this tooth, the observed positional changes could not be attributed to its eruption pattern but external forces applied to the clinical crown should have contributed substantially. Forces exerted by the cheek are known to be counterbalanced by tongue pressure, which creates an equilibrium that influences tooth position in humans (Weinstein et al., 1963; Weinstein, 1967; Proffit, 1978). Disruption of this equilibrium can contribute to asymmetry in the dental arch in certain cases (Takada et al., 2011). Applying a moderate, continuous load is more efficient to cause orthodontic tooth movement than high loads of short duration (Roberts, 2012). Thus, in the present case report, cheek muscular activity might have been responsible for exerting continuous limited pressure on the tooth's clinical crown, contributing to the observed positional changes in time. Although a diastema persisted between Triadan 106 and 107, this problem was manageable with conservative measures and owner compliance. The authors hypothesize that the radiographic changes observed after 18 months at the level of 106 (irregular outlined periodontal space) can be explained due to the tilted position of the tooth and the high rate of remodeling of the periodontium and surrounding bone due to the orthodontic movement

(Reitkin, 1967). Changes that occur in the periodontium due to orthodontic forces are unknown in equids and care must be taken to interpret these findings. Regular and thorough dental checkups remain essential in this case to verify normal attrition and vitality of the tooth.

The use of dental casts in the present cases was complementary to the CT images to study the possibilities of orthodontic treatment strategies. Illustrations of the use of dental casts of equine tooth pathology can be found in text books (Becker, 1962; Galloway and Galloway, 2011). Deep sedation is a prerequisite to ensure that the equine patient accepts the application of a custom-made tray filled with dental impression material. Even minor chewing movements while the product sets, decreases the quality of the dental cast.

Treatment choice of a supernumerary tooth case is based on the individual dental situation and associated secondary clinical signs. The present case report illustrates the possibility of spontaneous repositioning of a malpositioned maxillary premolar due to an adjacent supernumerary tooth.

## REFERENCES

- Ando S., Kiyokawa K., Nakashima T., Shibo K., Sanka Y. (1967). Studies on the consecutive surgery of succedaneous and permanent dentition in Japanese children. 4. Behavior of short-rooted teeth in the upper bilateral central incisors. *The Journal of Nihon University School of Dentistry* 9, 67-82.
- Anthony J., Waldner C., Grier C., Laycock A. R. (2010). A survey of equine oral pathology. *Journal of Veterinary Dentistry* 27, 12-15.
- Baker G. J. (1970). Some aspects of equine dental disease. *Equine Veterinary Journal* 2, 105-110.
- Becker E. (1962). Zähne. In: Joest E. (editor). *Handbuch der Speziellen Pathologischen Anatomie der Haustiere*. Berlin, Verlag Paul Parey, 83-313.
- Carmalt J. L. (2007). Evidence-based equine dentistry: preventive medicine. *Veterinary Clinics of North America: Equine Practice* 23, 519-524.
- Collins N. M., Dixon P. M. (2005). Diagnosis and management of equine diastemata. *Clinical Techniques in Equine Practice* 4, 148-154.
- Cope J. B. (2005). Temporary anchorage devices in orthodontics: a paradigm shift. *Seminars in orthodontics* 11, 3-9.
- de Mira M. C., Ragle C. A., Gablehouse K. B., Tucker R. L. (2007). Endoscopic removal of a molariform supernumerary intranasal tooth (heterotopic polyodontia) in a horse. *Journal of the American Veterinary Medical Association* 231, 1374-1377.
- Dixon P. M., Tremaine W. H., Pickles K., Kuhns L., Hawe C., McCann J., McGorum B., Railton D. I., Brammer S. (1999a). Equine dental disease part 1: a long-term study of 400 cases: disorders of incisor, canine and first premolar teeth. *Equine Veterinary Journal* 31, 369-377.
- Dixon P. M., Tremaine W. H., Pickles K., Kuhns L., Hawe C., McCann J., McGorum B. C., Railton D. I., Brammer S. (1999b). Equine dental disease Part 2. a long-term study of 400 cases: disorders of development and eruption and variations in position of the cheek teeth. *Equine Veterinary Journal* 31, 519-528.
- Dixon P. M. (2011). Disorders of development and eruption of the teeth and developmental craniofacial abnormalities. In: Easley J., Dixon P. M., Schumacher J. (editors). *Equine Dentistry*. Third edition, Elsevier Saunders, Philadelphia, 99-114.
- Dixon P. M., Dacre I., Dacre K., Tremaine W. H., McCann J., Barakzai S. (2005a). Standing oral extraction of cheek teeth in 100 horses (1998--2003). *Equine Veterinary Journal* 37, 105-112.
- Dixon P. M., Easley J., Ekmann A. (2005b). Supernumerary teeth in the horse. *Clinical Techniques in Equine Practice* 4, 155-161.
- Du Toit N., Kempson S. A., Dixon P. M. (2008). Donkey dental anatomy. Part 1: Gross and computed axial tomography examinations. *Veterinary Journal* 176, 338-344.
- Earley E., Galloway S. and Dotzel A. R. (2013). Orthodontic principles applied with corrective odontoplasty. In: *Proceedings of the American Association of Equine Practitioners*. Charlotte, NC, USA, 111-118.
- Easley J., Dixon P. M., Reardon R. J. M. (2016). Orthodontic correction of overjet/overbite ("parrot mouth") in 73 foals (1999-2013). *Equine Veterinary Journal* 48, 565-572.
- Easley J., Schumacher J. (2011). Basic equine orthodontics and maxillofacial surgery. In: Easley J., Dixon P. M., Schumacher J. (editors). *Equine Dentistry*. Third edition, Elsevier Saunders, Philadelphia, 289-318.
- Emily P. (1992). Feline malocclusion. *Veterinary Clinics of North America: Small Animal Practice* 22, 1453-1460.
- Fletcher B. (2008). Orthodontic treatment, case report update. *Horse Dentistry and Bitting Journal* 1, 3.
- Galloway S. (2008). An expansion screw device to facilitate eruption of a mandibular premolar in a horse. In: *Proceedings of 22nd Annual Veterinary Dental Forum*, Jacksonville FL, 105.
- Galloway S., Galloway M. (2011). Dental materials. In: Easley J., Dixon P. M., Schumacher J. (editors). *Equine Dentistry*. Third edition, Elsevier Saunders, Philadelphia, 363-366.
- Garvey M. T., Barry H. J., Blake M. (1999). Supernumerary teeth - an overview of classification, diagnosis and management. *Journal Canadian Dental Association* 65, 612-616.
- Hemley S. (1941). The incidence of root resorption of vital permanent teeth. *Journal of Dental Research* 20, 141.
- Hollender L., Ronnerman A., Thilander B. (1980). Root resorption, marginal bone support and clinical crown length in orthodontically treated patients. *European Journal of Orthodontics* 2, 197-205.
- Ketcham A. (1929). A progress of an investigation of apical root resorption of vital permanent teeth. *International Journal of Orthodontics* 15, 310-328.
- Klugh D. O. (2004). Acrylic bite plane for treatment of malocclusion in a young horse. *Journal of Veterinary Dentistry* 21, 84-87.
- Langeneckert F., Witte T., Schellenberger F., Czech C., Aebischer D., Vidondo B., Koch C. (2015). Cheek tooth extraction via a minimally invasive transbuccal approach and intradental screw placement in 54 equids. *Veterinary Surgery* 44, 1012-1020.
- Lothamer C. W., Soukup J. W. (2016). Treatment of big-

- nathic malocclusions with multistage active force orthodontic movements in a cat. *Journal of Veterinary Dentistry* 33, 7-17.
- Lundstrom T., Wattle O. (2016). Description of a technique for orthograde endodontic treatment of equine cheek teeth with apical infections. *Equine Veterinary Education* 28, 641-652.
- Magkavali-Trikka P., Emmanouilidis G., Papadopoulos M. A. (2018). Mandibular molar uprighting using orthodontic miniscrew implants: a systematic review. *Progress in Orthodontics* 19, 1-12.
- Mirabella A. D., Artun J. (1995). Risk factors for apical root resorption of maxillary anterior teeth in adult orthodontic patients. *American Journal of Orthodontics and Dentofacial Orthopedics: Official Publication of the American Association of Orthodontists, its Constituent Societies, and the American Board of Orthodontics* 108, 48-55.
- Nanci A. (2013). Structure of the oral tissues. In: Nanci A. (editor). *Ten Cate's Oral Histology*. Elsevier Mosby, Canada, 1-13.
- Newman W. G. (1975). Possible etiologic factors in external root resorption. *American Journal of Orthodontics* 67, 522-539.
- O'leary J. M., Barnett T. P., Parkin T. D. H., Dixon P. M., Barakzai S. Z. (2013). Pulpal temperature changes during mechanical reduction of equine cheek teeth: comparison of different motorised dental instruments, duration of treatments and use of water cooling. *Equine Veterinary Journal* 45, 355-360.
- Papadopoulos M. A., Tarawneh F. (2007). The use of miniscrew implants for temporary skeletal anchorage in orthodontics: A comprehensive review. *Oral Surgery Oral Medicine Oral Pathology Oral Radiology and Endodontology* 103, E6-E15.
- Parés C.P.M., Lozano S. (2014). Four supernumerary distomolar dysmorphic cheek teeth in a horse: a case report. *Research* 1, 951.
- Pasicka E., Onar V., Dixon P. M. (2017). Supernumerary cheek tooth in a Byzantine horse from Theodosius Harbour, Istanbul, Turkey. *Equine Veterinary Education* 29, 266-269.
- Polkowska I., Golynska M., Sobczynska-Rak A., Putowska K., Matthews-Brzozowska T., Szyszkowska A., Golski M., Chelminski A., Capik I. (2014). Orthodontic treatment of dogs on the basis of modern knowledge and own experience. *Bulletin of the Veterinary Institute in Pulawy* 58, 645-650.
- Proffit W. R. (1978). Equilibrium theory revisited: factors influencing position of the teeth. *The Angle Orthodontist* 48, 175-186.
- Quinn G. C., Tremaine W. H., Lane J. G. (2005). Supernumerary cheek teeth (n = 24): clinical features, diagnosis, treatment and outcome in 15 horses. *Equine Veterinary Journal* 37, 505-509.
- Reitan K. (1967). Clinical and histologic observations on tooth movement during and after orthodontic treatment. *American Journal of Orthodontics and Dentofacial Orthopedics* 53, 721-745.
- Roberts W. E. (2012). Bone physiology, metabolism, and biomechanics in orthodontic practice. In: Graber L. W., Vanarsdall R. L., Vig K. W. L. (editors). *Orthodontics Current Principles and Techniques*. Elsevier, Mosby, Philadelphia, 287-344.
- Rodrigues J. B., Sanroman-Llorens F., Bastos E., San Roman F., Viegas C. A. (2013). Polyodontia in donkeys. *Equine Veterinary Education* 25, 363-367.
- Ross D. L. (1986). Orthodontics for the dog. Treatment methods. *Veterinary Clinics of North America: Small Animal Practice* 16, 939-954.
- Ruan W. H., Chen M. D., Gu Z. Y., Lu Y., JSu. M., Guo Q. (2005). Muscular forces exerted on the normal deciduous dentition. *The Angle Orthodontist* 75, 785-790.
- Schatzle M., Mannchen R., Zwahlen M., Lang N. P. (2009). Survival and failure rates of orthodontic temporary anchorage devices: a systematic review. *Clinical Oral Implants Research* 20, 1351-1359.
- Spierings T.A., Peters M.C., Plasschaert A.J. (1985) Thermal trauma to teeth. *Endodontic dental traumatology* 1, 123-129
- Staszuk C., Bienert A., Baumer W., Feige K., Gasse H. (2008). Simulation of local anaesthetic nerve block of the infraorbital nerve within the pterygopalatine fossa: Anatomical landmarks defined by computed tomography. *Research in Veterinary Science* 85, 399-406.
- Stoll M. (2007). How to perform a buccal approach for different dental procedures. In: *Proceedings American Association of Equine Practitioners* 53, 507-511.
- Surgeon T. W. (2005). Fundamentals of small animal orthodontics. *Veterinary Clinics of North America-Small Animal Practice* 35, 869.
- Takada J., Ono T., Miyamoto J. J., Yokota T., Moriyama K. (2011). Association between intraoral pressure and molar position and inclination in subjects with facial asymmetry. *European Journal of Orthodontics* 33, 243-249.
- Tremaine W. H. (2004). Oral extraction of equine cheek teeth. *Equine Veterinary Education* 16, 151-158.
- Vlaminck L., Hoegaerts M., Steenhaut M., Maes D., Saunders J., Gasthuys F. (2008). Radiographic evaluation of tooth drift after cheek tooth extraction and insertion of an intra-alveolar prosthesis in ponies. *Veterinary Journal* 175, 249-258.
- Vlaminck L., Huys L., Maes D., Steenhaut M. L. M., Gasthuys F. (2006). Use of a synthetic bone substitute to retard molariform tooth drift after maxillary tooth loss in ponies. *Veterinary Surgery* 35, 589-595.
- Weinstein S. (1967). Minimal forces in tooth movement. *American Journal of Orthodontics and Dentofacial Orthopedics* 53, 881-903.
- Weinstein S., Haack D., Morris L. Y., Snyder B. B., Ataway H. E. (1963). On an equilibrium theory of tooth position. *The Angle Orthodontist* 33, 1-26.
- Zach L., Cohen G. (1965) Pulp response to externally applied heat. *Oral Surgery* 19, 515-530.

## Vacuum phenomenon associated with triple cervical vertebral arch and ligamentum flavum anomaly resulting in severe stenotic myelopathy in a dog

*Vacuümfenomeen geassocieerd met een drievoudige cervicale wervelboog- en ligamentum flavum-anomalie resulterend in erge stenotische myelopathie bij een hond*

<sup>1</sup>S. Vermeire, <sup>2</sup>V. Rondahl, <sup>3</sup>H. Schmökel, <sup>1</sup>M. Rapp

<sup>1</sup>Department of Diagnostic Imaging, Evidensia Small Animal Referral Hospital Strömsholm, Djursjukhusvägen 11, 734 94 Strömsholm, Sweden

<sup>2</sup>Department of Pathology and Wildlife Disease, National Veterinary Institute, Ulls väg 2B, 751 89 Uppsala, Sweden

<sup>3</sup>Evidensia Spine Center, Evidensia Small Animal Referral Hospital Strömsholm, Djursjukhusvägen 11, 734 94 Strömsholm, Sweden

simon.vermeire@evidensia.se

### ABSTRACT

A six-year-old American Staffordshire terrier with proprioceptive deficits of the right thoracic and pelvic limb was referred for further work-up. Cervical computed tomography (CT) and magnetic resonance imaging (MRI) revealed a triple cervical canal stenosis with dorsal spinal cord compression and concomitant compressive myelopathy caused by vertebral arch and ligamentum flavum proliferation and hypertrophy. Vacuum phenomena were noticed within the ligamentum flavum tissue, a previously unreported location for vacuum phenomena, which are primarily reported within degenerative joints and intervertebral discs. Decompressive surgery and rehabilitation resulted in a complete clinical recovery.

### SAMENVATTING

Een zes jaar oude Amerikaanse staffordshireterriër met verminderde proprioceptie van de rechter voor- en achterpoot werd doorgestuurd voor verder onderzoek. Een drievoudige, cervicale stenose met dorsale ruggenmergcompressie en bijhorende myelopathie werden vastgesteld aan de hand van een computertomografisch en magneetcamera-onderzoek. Deze bevindingen waren secundair aan een proliferatie en hypertrofie van het ligamentum flavum en van de wervelboog. Vacuümfenomenen werden vastgesteld in de ligamentaire hypertrofie, een tot nu toe onbeschreven locatie. Chirurgische decompressie en revalidatie leidden tot volledig herstel.

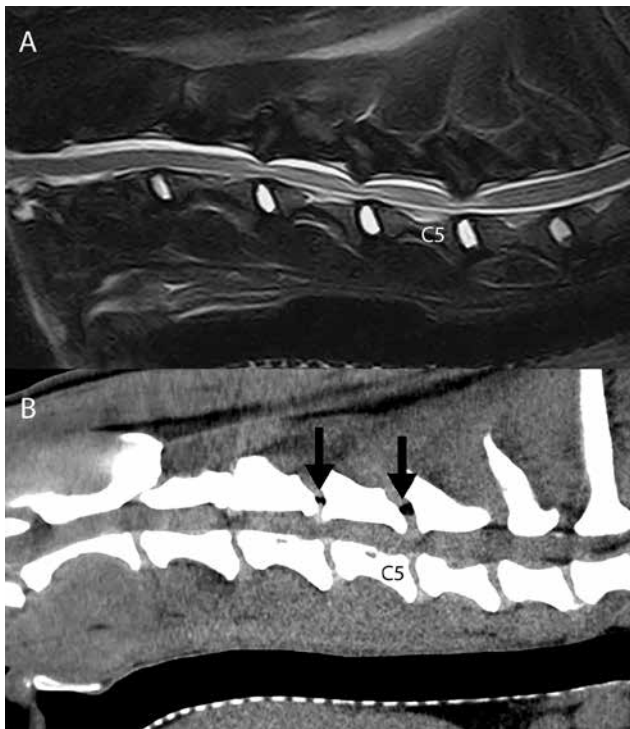### INTRODUCTION

The vacuum phenomenon, a radiological sign used to describe the abnormal accumulation of gas lucencies (Magnusson, 1937), has become a frequently identified entity in veterinary diagnostic imaging due to the widespread use of computed tomography, a modality more sensitive for detecting gas than conventional radiology (Hathcock, 1994). Most often seen in dogs with degenerative intervertebral disc and joint diseases (Weber et al., 1995; Shwarz et al., 2000; Müller et al., 2014), vacuum phenomena are mentioned in the human literature in additional locations, such as the vertebral body, e.g. Schmorl node or secondary

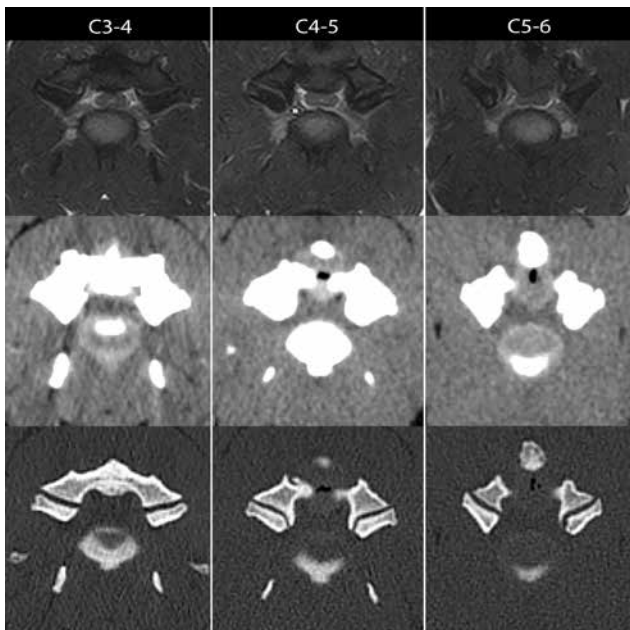
to vertebral collapse, and within the vertebral canal (Kumpan et al., 1986; Yoshida et al., 1997).

Although the gas accumulation itself is often considered benign, the distribution pattern or location may have clinical relevance. Research in human medicine has indicated that a linear intravertebral vacuum phenomenon most likely occurs secondary to a benign vertebral collapse, whereas a bubble-like intravertebral vacuum phenomenon is more suggestive of an infectious etiology (Gohil et al., 2014). While a vacuum phenomenon located in the intervertebral disc space in dogs is considered unreliable to presurgically identify herniated discs causing acute neurological signs (Müller et al., 2013), a human intraspinal





**Figure 1.** A. FSE T2 sagittal 0.25T MR image and B. soft tissue algorithm sagittal reconstructed CT images of the cervical spine. A. Intramedullary spinal cord T2 hyperintensities are seen at the level of C3-4, C4-5 and C5-6 associated with mild (C3-4) and moderate (C4-5, C5-6) dorsal, midline spinal cord compression. B. Multiple vacuum phenomena can be detected dorsally to the spinal cord at the level of C4-5 and C5-6 (arrows).



**Figure 2.** Transverse MR and CT images at the level of C3-4, C4-5 and C5-6 with the upper row representing the HYCE sequence, the middle row the CT soft tissue algorithm and the bottom row the CT bone algorithm acquisition. Dorsal midline spinal cord compression is present at the level of at all three sites, successively worsening caudally.

vacuum phenomenon may have a large clinical relevance by causing nerve root compression and subsequent radicular symptoms (Yoshida et al., 1997).

In the present case report, vacuum phenomena in the degenerative and hypertrophic ligamentum flavum of a dog with cervical stenotic myelopathy is described and a tentative theory of the origin of this phenomenon is proposed.

## CASE PRESENTATION

### Signalment, history and clinical findings

A six-year-old, intact, male American Staffordshire terrier with a six-week history of mild right thoracic and severe right pelvic limb proprioceptive deficits was presented for further examination. The neurological symptoms were acutely initiated during an incident involving another dog that tried to attack him. The owner pulled his dog back by the leash. The owner had not noticed any abnormalities prior to this event. Six weeks of strict rest and non-steroidal anti-inflammatory drug treatment revealed no clinical improvement.

On arrival at the referral hospital, the dog was alert with a normal posture but still mildly atactic on his pelvic limbs with mild to severe proprioceptive deficits of the right thoracic and right pelvic limb, respectively. The right thoracic limb also showed mild muscle atrophy, a missing radial reflex and worn claws. The cranial nerves and the other spinal reflexes were normal, as were the left thoracic and pelvic limbs. Except for a tense neck, no pain was observed on palpation or mobilization of the spine. Results of the neurological examination were mostly consistent with a disorder of the C1-C5 spinal cord segments. Complete blood count and biochemistry profile showed only mild leucopenia ( $3,6 \times 10^9/l$ ; reference 6-17). The most likely diagnosis was thought to be fibrocartilaginous embolism with secondary ischemic myelopathy. The absence of clear pain or forebrain signs made intervertebral disc disease, inflammatory central nervous system disease, such as meningomyelitis, or neoplasia less likely.

## IMAGING, DIAGNOSIS AND OUTCOME

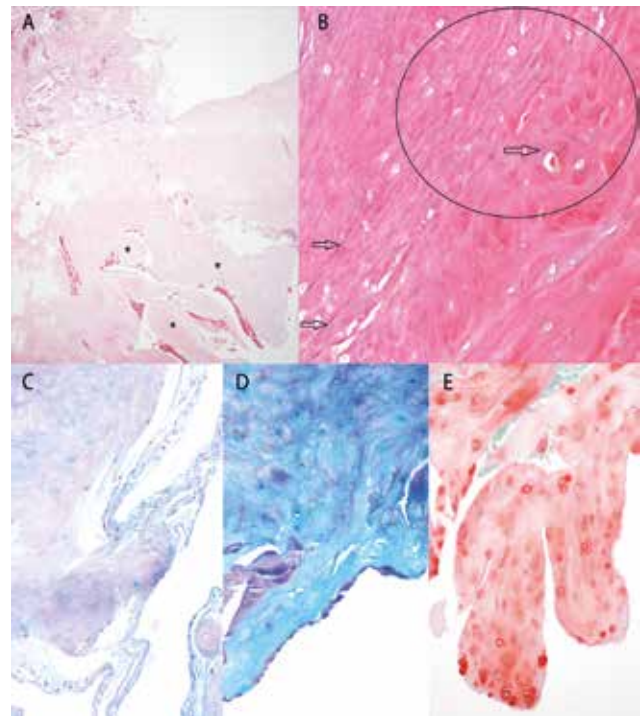
A native cervical CT (Philips Brilliance 40, Philips Medical Systems, the Netherlands) and MRI (Vet-MR Grande, 0.25 Tesla, Esaote, Italy) were performed under general anesthesia (Figures 1 and 2). The CT examination revealed cervical canal stenosis at the C3-4, C4-5, and C5-6 intervertebral levels with mild, moderate and severe dorsal midline spinal cord compression, respectively (Figures 1B and 2). This multifocal stenosis was caused by (1) a well-defined and smooth, bony proliferation of the cranial and caudal aspects of the dorsal laminae and spinous processes and (2) the

adjacent presence of a moderate amount of soft tissue between the vertebral arches. Changes were visible from the caudal aspect of the spinous process of C3 to the cranial aspect of the dorsal spinous process of C6. Vacuum phenomena, seen as round to oval areas of hypoattenuation (-450 to -580 Hounsfield units), were noticed within the soft tissue changes or adjacent to the bony proliferations of C3-4, C4-5 and C5-6. No signs of ventral or lateral spondylosis were observed. Small osteophytes were seen at both the C4-5 and right-sided C5-6 articular process joints.

The subsequently performed MRI provided evidence of myelopathy at the stenotic areas with thin and elongated intramedullary T2 hyperintense lesions (Figures 1A and 2). The proliferative tissues between the vertebral arches were T1 and T2 isointense to the surrounding musculature and caused the ventral displacement of the spinal cord and effacement of the T2 signal dorsal to the spinal cord, indicating dorsal spinal cord compression. The T2 signal on the ventral and lateral aspects of the spinal cord was maintained over the entire spinal cord. The intervertebral discs at all three stenotic areas showed no signs of degenerative diseases. The ligamentum flavum connecting the vertebral laminae of the adjacent vertebrae could not be identified or differentiated from the proliferative tissue.

To alleviate the neurological signs, decompressive surgery was performed at C3-4, C4-5 and C5-6 by means of a triple dorsal laminectomy and removal of the soft tissue proliferations. The dog was hospitalized for eleven days due to an initial deterioration of his neurological condition after surgery (nonambulatory tetraparesis). He regained an ambulatory state 28 days post surgery. During the follow-up consultations, the dog was considered fully recovered without any neurological deficit six months after surgery.

The extirpated tissue was fixed in 4 % buffered formalin, processed by standard procedures and embedded in paraffin blocks. Tissue sections (5 µm thick) were stained with Mayer's hematoxylin/eosin for routine examination and with special stains to identify acid mucins (Alcian blue-PAS), calcium deposits (Von Kossa), proteoglycans (Safranin O), and elastin (Van Gieson). The tissue consisted of thickened, dense, fibrous connective tissue with abundant intracellular collagen, mild fibroplasia and foci of loose vascular connective tissue along the dorsal edge (Figure 3A). In the dorsal parts, there were sparse multifocal fibroplasia and hemosiderophagocytosis, and small numbers of intact and fragmented elastin fibers (Figure 3B) with a mixture of neutral and acid mucins (Figure 3C). In the ventrally oriented projections, the stroma was basophilic with multifocal cartilage differentiation and a dominance of acid mucins (Figure 3D). The ventral proliferations and cartilaginous tissue contained moderate to high amounts of proteoglycans, and the dorsal as well as the more fibrous parts contained no or minimal amounts of proteoglycans (Figure 3E). Small, focal mineralizations were seen



**Figure 3. Histopathology results.** A. Overview with dorsal fibrovascular tissue in upper part of image and ventral fibrocartilaginous proliferations indicated by \* (HE, original magnification 40x). B. VG-Elastin stain showing elastin fibers (arrows) and fractured fibers in the circled area (original magnification 100x). C. Alcian blue-PAS showing a mixture of neutral and acid mucin (purple) staining (original magnification 100x). D. Alcian blue-PAS showing dominant acid (blue) staining (original magnification 100x). E. Safranin O staining showing moderate to strong (orange to red) proteoglycan staining in the ventral fibrocartilaginous proliferations (original magnification 100x).

in a few ventral proliferations, and a few dispersed individual cell mineralizations were seen in the cartilaginous tissue (not shown). The histopathological diagnosis was chronic degeneration, proliferation and hypertrophy of the fibrocartilaginous tissue consistent with ligamentum flavum.

## DISCUSSION

A multifocal ligamentum flavum degeneration and hypertrophy associated with proliferation of the vertebral arch of the four adjacent cervical vertebrae with concomitant vacuum phenomena were seen causing moderate-to-severe dorsal vertebral canal stenosis and associated compressive myelopathy in a middle-aged American Staffordshire terrier. To the best of the authors' knowledge, there are no published data describing this phenomenon within the ligamentum flavum tissue.

The vacuum phenomenon is a radiographic sign describing the abnormal accumulations of gas lucencies. Initially described within the intervertebral disc



by Magnusson (1937), vacuum phenomena have also been occasionally observed in other joint spaces as well as within vertebrae (Libicher et al., 2007; Ito et al., 2008). Intervertebral disc vacuum phenomena and those located within synovial joint spaces are often associated with degenerative joint disease or excessive distractive forces, e.g. in case of stress radiography, joint luxation (Knutsson, 1942; Weber et al., 1995; Gottschalk et al., 1999, Schwarz et al., 2000), whereas intravertebral vacuum phenomena may be associated with both benign, e.g., traumatic fracture, osteomyelitis, and malignant (neoplasia) processes (Knutson, 1942; Resnick et al., 1981; Gohil et al., 2014). These gas lucencies should be differentiated from the venous air embolisms routinely seen on computed tomography studies in both humans and small animals secondary to vessel catheterization and contrast administration (Heng et al., 2014).

The mechanism of vacuum phenomenon formation is still equivocal, with theories assigning important roles to local pressure changes, compromised tissue vascularity, and the composition of the vacuum gas consisting of 90-92% nitrogen (Ford et al., 1977; Gohil et al., 2014). The histopathological finding of fibrocartilaginous changes in the ligamentum flavum is of special interest and suggests an explanation for the unique localization of the vacuum phenomena seen in this case. Fibrocartilaginous tissue is a connective tissue mainly seen in intervertebral discs, intra-articular discs, such as the temporomandibular joint disc, and menisci (Almarza et al., 2004). With increasing age and degeneration, these discs change significantly with alterations in both morphology, e.g. concentric tears or loss of height, and biochemical distribution. The main biochemical change in disc degeneration is the loss of proteoglycan leading to, among other changes, decreased osmotic pressure of the disc tissue (Urban and Roberts, 2003; Adams and Roughley, 2006). As the osmotic pressure decreases, the tissue nitrogen might precipitate out of solution and accumulate as dissolved gas, i.e. create vacuum phenomena (Gohil et al., 2014). Whereas tissues with extensive blood flow can clear nitrogen relatively easily (Hall, 2011), less perfused tissues, such as synovial joints, combined with a compromised vascularity due to degeneration, could further facilitate the creation of vacuum phenomena. In the present case, the authors hypothesize that the fibrocartilaginous transformation of the ligamentum flavum has resulted in a similar drop of pressure and compromised tissue vascularity with subsequent vacuum phenomena formation.

Whether the ligamentum flavum hypertrophy occurred first with secondary osseous proliferations or vice versa remains unknown. However, the histopathological changes of the ligamentum flavum with fibrosis, i.e. an increase in collagen fibers and a loss of elastic fibers, and calcifications are typically seen in post-inflammatory repair processes (Yoshiiwa et al., 2016). This suggests that a primary osseous proliferation has caused mechanical stress on the ligamentum

flavum, and secondary repetitive inflammatory reactions and repair processes have resulted in chronic active ligamentum flavum hypertrophy and proliferation with minimal residual inflammation.

Osseous-associated cervical spondylomyelopathy (OA-CSM) is another condition of vertebral stenosis characterized by both osseous and ligamentum flavum hypertrophy, yet it differs both anatomically and demographically from the present case. First, the spinal cord compression in OA-CSM is most often secondary to osseous proliferation of the articular process joints causing lateralized compressions (da Costa et al., 2012), which is in contrast with the present case in which only mild osteoarthritis of these joints was observed, and the compressions were located dorsally. Secondly, OA-CSM has been reported in young dogs (median age: 2 years) of various large and giant breeds (Gasper et al., 2014). In a recent study by De Decker et al. (2012) in young Basset Hounds (median age: 1.4 years), a combined vertebral arch and ligamentum flavum hypertrophy was also noticed, yet limited to one or two sites of spinal cord compression. The authors suspect an underlying genetic defect based on the breed-specific characteristic of the observed changes, even though further investigation is warranted. Neither the last mentioned study nor studies investigating OA-CSM mention the presence of vacuum phenomena (da Costa et al., 2012; De Decker et al., 2012; Gasper et al., 2014).

In conclusion, this case presents a novel location for vacuum phenomena within the proliferative ligamentum flavum. A tentative theory of origin is proposed. Yet, further investigation is necessary to unravel the exact underlying formation process and to reveal its clinical relevance.

## ACKNOWLEDGEMENTS

This case report was funded by Stiftelsen Strömsholm Djursjukvård.

## REFERENCES

- Adams MA, Roughley PJ. (2006). What is intervertebral disc degeneration, and what causes it? *Spine* (Phila Pa 1976) *31*, 2151–2161.
- Almarza AJ, Athanasiou KA. (2004) Design characteristics for the tissue engineering of cartilaginous tissues. *Annals of Biomedical Engineering* *32*, 2-17.
- da Costa R, Echandi R, Beauchamp D. (2012). Computed tomography myelographic findings in dogs with cervical spondylomyelopathy. *Veterinary Radiology and Ultrasound* *53*, 64-70.
- De Decker S, De Risio L, Lowrie M, Mauler D, Beltran E, Giedja A, Kenny PJ, Gielen I, Garosi L, Volk H. (2012). Cervical vertebral stenosis associated with a vertebral arch anomaly in the Basset hound. *Journal of Veterinary Internal Medicine* *26*, 1374-1382.
- Ford LT, Gilula LA, Murphy WA, Gado M. (1977). Analy-

- sis of gas in vacuum lumbar disc. *American Journal of Roentgenology* 128, 1056-1057.
- Gasper JA, Rylander H, Stenglein JL, Waller KR. (2014). Osseous-associated cervical spondylomyelopathy in dogs: 27 cases (2000-2012). *Journal of the American Veterinary Medical Association* 244, 1309-1318.
- Gohil I, Vilensky J, Weber E. (2014). Vacuum phenomenon: clinical relevance. *Clinical Anatomy* 27, 455-462.
- Gottschalk RD, Kirberger RM, Fourie SL. (1999). Vacuum phenomenon in equine carpal, metacarpophalangeal and metatarsophalangeal joints. *Journal of South African Veterinary Association* 70, 5-8.
- Hall JE. (2011). Effect of high partial pressures of individual gases on the body. In: Hall JE. (editor). *Guyton and Hall Textbook of Medical Physiology*. Twelfth edition, Philadelphia, PA, Saunders Elsevier, 535-540.
- Hathcock J. (1994). Vacuum phenomenon of the canine spine: CT findings in 3 patients. *Veterinary Radiology and Ultrasound* 35, 285-289.
- Heng H, Ruth J, Lee K. (2014). Venous air embolism detected on computed tomography of small animals. *Journal of Small Animal Practice* 55, 420-423.
- Ito H, Yoshikawa T, Hayashi N, Ohtomo K. (2008). MDCT demonstration of intraarticular gas in the glenohumeral joint and sternoclavicular joint with reference to arm position. *Radiation Medicine* 26, 422-426.
- Knutsson F. (1942). The vacuum phenomenon in the intervertebral disc. *Acta Radiologica* 23, 173-179.
- Kumpan W, Salomonowitz E, Seidl G, Wittich G. (1986). The intravertebral vacuum phenomenon. *Skeletal Radiology* 15, 444-447.
- Libicher M, Appelt A, Berger I, Baier M, Meeder PJ, Grafe I, DaFonseca K, Nöldge G, Kasperk C. (2007). The intra-vertebral vacuum phenomenon as specific sign of osteonecrosis in vertebral compression fractures: results from a radiological and histological study. *European Radiology* 17, 2248-2252.
- Magnusson W. (1937). Über die Bedingungen des Hervortretens der wirklichen Gelenkspalte auf dem Röntgenbilde. *Acta Radiologica* 18, 733-741.
- Müller M, Ludewig E, Oechtering G, Scholz M, Flegel T. (2013). The vacuum phenomenon in intervertebral disc disease of dogs based on computed tomography images. *Journal of Small Animal Practice* 54, 253-257.
- Resnick D, Niwayama G, Guerra J Jr, Vint V, Usselman J. (1981). Spinal vacuum phenomena: anatomical study and review. *Radiology* 139, 341-348.
- Schwarz T, Owen M, Long S, Sullivan M. (2000). Vacuum disk and facet phenomenon in a dog with cauda equine syndrome. *Journal of the American Veterinary Medical Association* 217, 862-864.
- Urban J, Roberts S. (2003). Degeneration of the intervertebral disc. *Arthritis Research and Therapy* 5, 120-130.
- Weber W, Berry C, Kramer R. (1995). Vacuum phenomenon in twelve dogs. *Veterinary Radiology and Ultrasound* 36, 493-498.
- Yoshida H, Shinomiya K, Nakai O, Kurosa Y, Yamaura I. (1997). Lumbar nerve root compression caused by lumbar intraspinal gas. Report of three cases. *Spine* 22, 348-351.
- Yoshiiwa T, Miyazaki M, Notani N, Ishihara T, Kawano M, Tsumura H. (2016). Analysis of the relationship between ligamentum flavum thickening and lumbar segmental instability, disc degeneration, and facet joint osteoarthritis in lumbar spine stenosis. *Asian Spine Journal* 10, 1132-1140.



## Intra-abdominal bleeding in a horse: not always of traumatic origin

*Intra-abdominale bloeding bij een paard: niet altijd het gevolg van trauma*

<sup>1</sup>L. De Lange, <sup>1</sup>A. Dufourni, <sup>1</sup>L. Lefère, <sup>2</sup>L. Sonck, <sup>1</sup>G. van Loon

<sup>1</sup>Departement of Large Animal Internal Medicine

<sup>2</sup>Departement of Pathology, Bacteriology and Poultry diseases

Faculty of Veterinary Medicine, Ghent University, Salisburylaan 133, B-9820 Merelbeke, Belgium

Lisa.delange@ugent.be

### ABSTRACT

A nine-year-old warmblood mare was presented with clinical signs of mild colic and fever. On percutaneous ultrasound of the abdomen, a mass was identified on the left side of the abdomen between the spleen and the stomach. During examination the following day, intra-abdominal blood was observed. On rectal examination, a mass was palpated in the pelvis. The presumptive diagnosis of hematoma with intra-abdominal bleeding was made. On consecutive ultrasounds and radiographs, the mass evolved in shape and other masses were identified in the liver and the lungs. No change was noticed in the pelvic mass. Cytology and histology of a tru-cut liver biopsy revealed abnormal, most likely neoplastic cells, whereas cytology of the abdominal and thoracic fluid did not reveal any neoplastic cells. Due to the presence of several rapidly growing masses, a neoplastic process was most likely. Because of the malignant character of the disease and the persistence of the clinical signs, euthanasia was suggested but refused by the owner. Supportive treatment was instituted. Initially, the general condition remained stable, after which the horse suddenly collapsed and died. Post-mortem examination revealed a primary neoplasm located in the pelvic cavity, as well as multiple disseminated masses within several tissues. The mass found in the liver had ruptured with loss of probably 50 liters hemorrhagic fluid within the abdominal cavity. Based on gross pathology, cytological and histological findings, a hemangiosarcoma was suspected. This diagnosis was confirmed using immunohistochemistry for von Willebrand factor. In this case report, the importance of differentiating hematoma from hemangiosarcoma in the horse is highlighted.

### SAMENVATTING

Een negen jaar oude merrie werd aangeboden met klachten van milde koliek en koorts. Met behulp van echografie werd een mixed hypo- en hyperechogene massa gediagnosticeerd tussen de maag en de milt. Op het rectale onderzoek werd eveneens een massa waargenomen in de bekkenholte. Bij herhaling van deze onderzoeken een dag later werd intra-abdominaal bloed waargenomen. Er werd gedacht aan een hematoom met intra-abdominale bloeding van traumatische oorsprong. Gedurende de volgende dagen werden echografische en radiografische veranderingen waargenomen in de longen en de lever. De massa ter hoogte van het bekken bleef stabiel. Abnormale, vermoedelijk neoplastische cellen werden waargenomen op cytologisch en histologisch onderzoek van een biopt genomen ter hoogte van de massa aanwezig in de lever. Dergelijke cellen werden niet waargenomen in het abdominale en thoracale vocht. Door de aanwezigheid van een snel groeiende massa werd de diagnose van maligne neoplasie het meest waarschijnlijk. Euthanasie werd voorgesteld maar geweigerd door de eigenaar. Ondersteunende behandeling werd ingesteld, waardoor het paard stabiel bleef. Enkele dagen later is het paard plotseling gestorven. Tijdens het post-mortemonderzoek werd in het bekken een primaire neoplasie waargenomen met metastasen in de longen en de lever met lekkage van 50 liter hemorrhagisch vocht in het abdomen. Gebaseerd op de macroscopische bevindingen, cytologische en histologische kenmerken werd een hemangiosarcoma als meest waarschijnlijke diagnose vooropgesteld. Dit werd bevestigd via een immunohistochemische kleuring voor von Willebrand-factor. Deze casuïstiek toont aan dat differentiatie tussen hematoom en hemangiosarcoma belangrijk is.

## INTRODUCTION

Hemangiosarcoma, also known as angiosarcoma or malignant hemangioendothelioma, is a malignant neoplasm originating from the vascular endothelium (Pulley et al., 1990). It affects middle-aged horses and no apparent sex predilection has been reported (Southwood et al., 2000). Locally invasive or disseminated forms have been reported (Southwood et al., 2000; Johns et al., 2005; Ferrucci et al., 2012; Taintor et al., 2014). The respiratory and musculoskeletal systems are mostly affected (Johns et al., 2005). Cutaneous, ocular and cervical vertebral forms have also been described (Scherrer et al., 2017; Taintor et al., 2014). In horses, disseminated hemangiosarcoma is more commonly found in the lungs and pleura, skeletal muscle, spleen, heart, kidney and brain (Taintor et al., 2014). Kuipel et al. (2000) described an intrapelvic hemangiosarcoma involving the pelvis and hind limb musculature causing periodic episodes of colic and lameness. Due to the involvement of multiple organ systems, different clinical signs have been reported depending on the body systems involved. The main clinical signs include lethargy, depression, anorexia, weight loss and anemia. In addition, epistaxis, dyspnea, lameness caused by hematoma formation within the skeletal muscle and signs of abdominal pain associated with hemoabdomen may be observed (Southwood et al., 2000; Taintor et al., 2014). The duration of the clinical signs varies from one day to several years (Southwood et al., 2000). Anemia, neutrophilic leucocytosis and thrombocytopenia have been described as the most common hematologic abnormalities in horses with disseminated hemangiosarcoma (Southwood et al., 2000). Ultrasonographic examination or radiography of thorax and/or abdomen often reveals masses (Johns et al., 2005). Biopsy of the tissue and histological examination are useful for diagnosing neoplasia. However, immunohistochemistry for endothelial markers, e.g. von Willebrand factor, may be necessary for diagnosis (Bertazzolo et al., 2005). Due to the malignant character of the disease, euthanasia is often suggested.

## CASE REPORT

A nine-year-old warmblood mare weighting 497 kg was presented at the Department of Large Animal Internal Medicine of Ghent University with signs of mild colic and pyrexia (39.0°C). Two days prior to admission, the mare had been in Morocco for three weeks for a show jumping tournament; she was transported back to Belgium by truck. She had no previous history of illness.

Upon presentation, the horse showed clinical signs of abdominal discomfort but was alert. No abnormalities were found during heart and lung auscultation. The heart rate (40 beats/min) and respiratory rate (24 breaths/min) were within normal ranges. The mucous

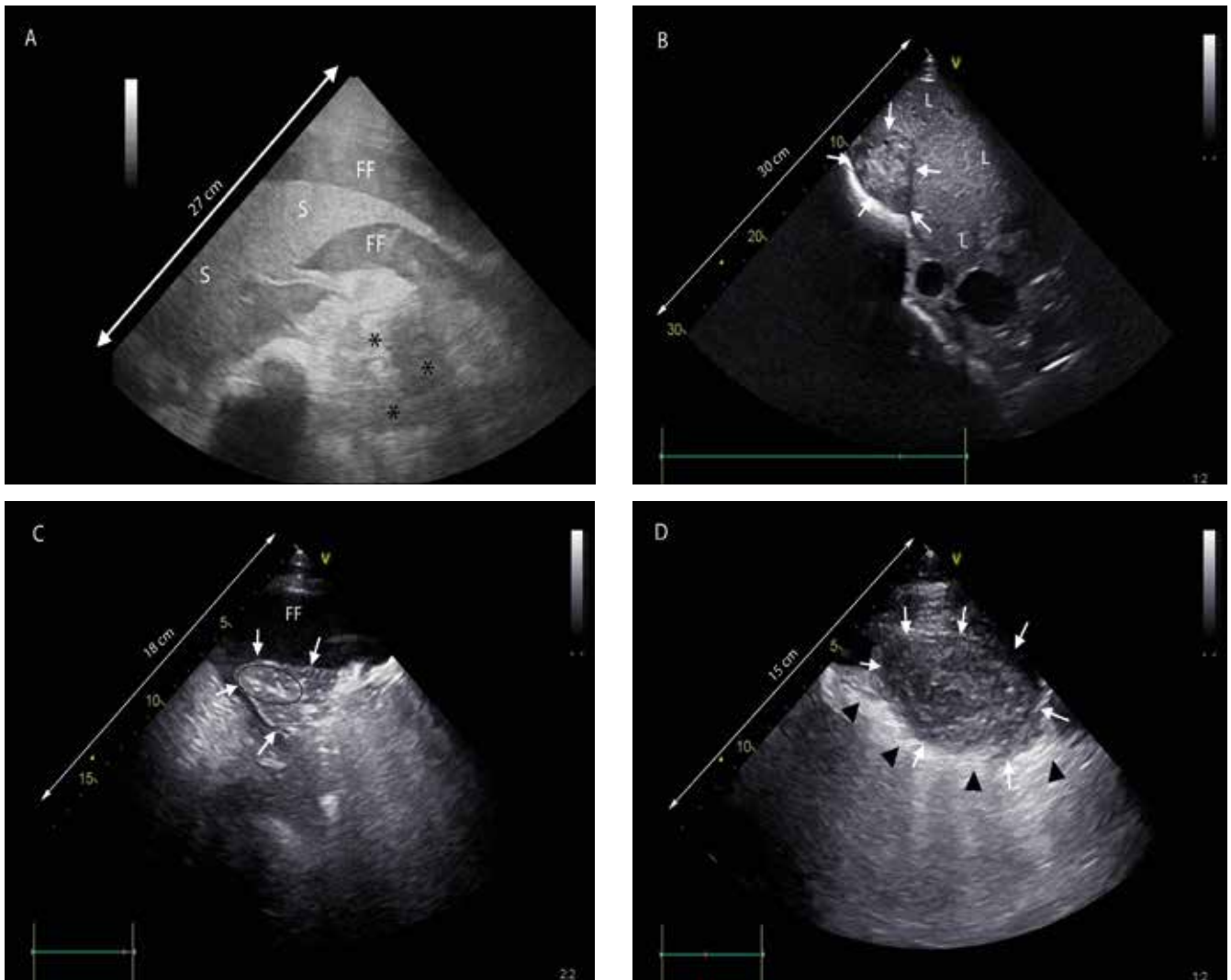
membranes were pale and the capillary refill time was two seconds. Rectal temperature was 38.3°C and gut sounds were reduced. No abnormalities were found on ultrasonography of the thorax. Abdominal ultrasound however showed a large heterogeneous mass situated between the stomach and the spleen with a diameter of 10 cm. A small amount of hypoechoic free fluid was present in the abdominal cavity. On rectal palpation, a 15 cm-diameter mass was found in the pelvic cavity. A heterogeneous, moderately echogenic mass with slightly hypochoic cavities was found on rectal ultrasound.

Blood analysis showed a decreased packed cell volume (PCV) (24%, ref: 35-45%) and a white blood cell count of  $13.0 \times 10^9$  cells/l (ref:  $3.5-9.0 \times 10^9$  cells/l), with 87% of neutrophils. The total serum protein concentration was within normal limits (59 g/l, ref: 56-72 g/l), but the albumin concentration was decreased (24 g/l, ref: 35-55 g/l). The total calcium concentration was low (2.40 mmol/l, ref: 2.60-3.22 mmol/l). Blood lactate was normal.

A presumptive diagnosis of hematoma with intra-abdominal bleeding as a result of trauma was made. Initial treatment consisted of tranexamic acid infusion (Exacyl® Sanofi, Belgium, 10 mg/kg bwt, in 1L NaCl 0.9% IV two times a day). Flunixin meglumine (Emdofluxin® Ecuphar, the Netherlands, 1.1 mg/kg bwt IV) one time a day and broad-spectrum anti-biotics, sodium penicillin (Penicilline®, Kela, Belgium, 10M IU IV) three times a day) and gentamycin (GentaEquine, Dechra®, Ireland, 6.6 mg/kg bwt IV one time a day) were instituted. No signs of colic or pyrexia were seen over the next days. The horse was kept on broad-spectrum antibiotics IV for seven days. After seven days, oral antibiotics (Trimethoprimium Sulfadiazinum, Emdotrim, Ecuphar®, Belgium, 30 mg/kg bwt, two times a day) were administered for ten days.

The day after admission, thoracic and abdominal ultrasound along with rectal palpation were repeated. In addition to the previous findings, the abdominal cavity was now filled with cloudy free fluid (Figure 1A). The infusion of tranexamic acid was continued (Exacyl® Sanofi, Belgium, 10 mg/kg bwt, in 1L NaCl 0.9% IV two times a day, for two consecutive days). The PCV remained 20-28% over the next days. Because the horse showed symptoms of intestinal obstruction due to the intrapelvic mass, laxative food was administered.

The general condition remained stable although the appetite remained poor. Ultrasound was repeated during the following twelve days after initial presentation, and ultrasonographic changes were noticed. The initial mass on the left side was still present but cloudy fluid gradually disappeared. On the right side of the horse, a mass could be identified within the liver (Figure 1B). In the right cranio-ventral thoracic cavity, hypochoic free fluid was noticed with atelectasis of the ventral lung tip (Figure 1C). Multiple masses were identified at the lung surface (Figure 1D). Thoracic radiographs revealed the presence of multiple



**Figure 1.** Ultrasonographic images taken from A. the left and B., C., D. right side of the horse using a phased array transducer (Esaote Mylab30gold and GE Vivid IQ) (dorsal is right on the screen). A. US image taken on the second day. B., C., D. US images taken during the follow-up examinations. A. Cloudy fluid is present lateral and medial to the spleen (FF). Medial to the spleen (S), a mass (asterix) is seen. B. A tissue structure (arrows) was identified within the liver (L) C. Atelectasis of the lungtip (arrows); an air-bronchogram (black circle) and free fluid (FF) are visible. D. An irregular mass (white arrows) is visualized at the lung surface.

nodular masses within the lungs. A rapid spreading and growing neoplastic process was suspected.

A transcutaneous ultrasound-guided (3.5 MHz convex probe) biopsy of the mass present adjacent to the liver was taken in the standing, sedated (Detomidine, Domosedan®, Dechra, the Netherlands, 0.1 mg/kg bwt IV and Butorfanol, Dolorex®, MSD, Germany, 0.1mg/kg bwt IV) horse. Care was taken to avoid puncturing large hepatic blood vessels within the mass. After aseptical preparation, local anesthetic (1.5 ml Procaine, Procainii Chloridum®, Kela, Belgium) was injected subcutaneously and in the intercostal muscles. A 5-mm incision was made with a No. 24 scalpel blade. A 16-gauge tru-cut biopsy needle (Quick-core, cook®) was inserted. An impression smear was made and the biopsy was fixed in 10%-neutral buffered formalin for 24 hours. The biopsy was paraffin-embedded, routinely processed

and 10 µm sections were made. Both impression and biopsy sample were stained with hematoxylin and eosin (H&E) for routine light microscopy.

Abdominocentesis and thoracocentesis were performed with a venoject 20G needle. The fluid obtained by thoracocentesis was serohemorrhagic fluid. The lactate concentration was below 2 mmol/l. The protein level was increased (total protein: 35g/l, ref <25 g/l) and a leukocyte count of  $6.37 \times 10^9$  cells/l (ref:  $<8 \times 10^9$  cells/l with neutrophilia: 76% neutrophils) was present. Cytologic examination revealed no neoplastic cells. Similar results were observed from the abdominal fluid with an even higher protein concentration (total protein: 45g/l, ref <25 g/l), a leukocyte cell count of  $9.34 \times 10^9$  cells/l (ref <  $7.5 \times 10^9$  cells/l) and a low lactate (< 2 mmol/l). No neoplastic cells were identified on cytological examination.

On microscopic evaluation of the impression



smear, large atypical cells were present with multiple nucleoli, a small amount of cytoplasm and marked anisokaryosis. This raised the suspicion of a neoplastic process.

Histopathologic examination of the biopsy revealed dense masses of moderate to big polygonal to spindle-shaped cells with clearly delineated pale cytoplasm. The nuclei were big, round to oval and had a small amount finely stippled chromatin. The nucleus/cytoplasm ratio was increased. Mitotic figures ranged from 1 to 3 per high power field. Moderate cellular atypia was present. There were some blood filled cavities present. The diagnosis of a malignant neoplasia was made.

Considering all above mentioned findings, a grave prognosis was given, euthanasia was proposed but the owner declined. The horse's condition remained stable for three more days, after which the horse suddenly collapsed and died. On necropsy, a large, friable but invasive retroperitoneal mass measuring 25 x 30 x 20 cm was found, strongly adherent to the ventral aspect of the pelvic bone, uterus and rectum. On cross section, cavernous cavities filled with blood and white fibrotic to soft necrotic spots were present. A huge amount of blood was present in the abdominal cavity. The lungs were pale and edematous, similar masses ranging from 1 to 10 cm in size were identified. One liter of serohemorrhagic fluid was present in the thoracic cavity. A soft tissue mass of 50 x 23 x 30 cm and multiple small masses were present in the liver, hemoabdomen was caused due to rupture of this mass. The pelvic mass was suspected to be primary while the others were probably metastatic.

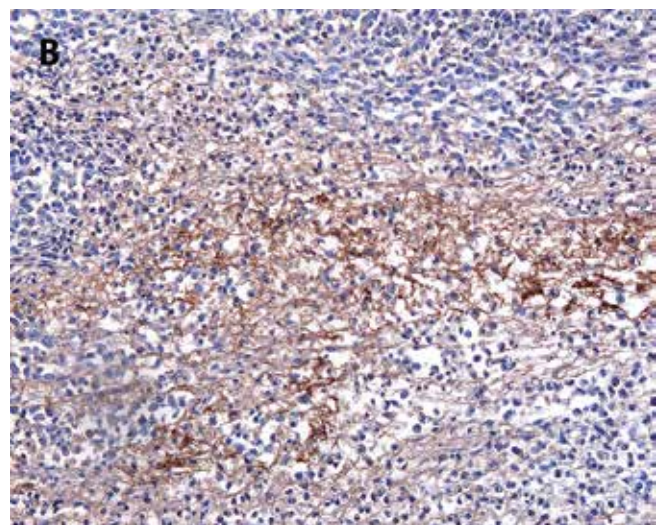
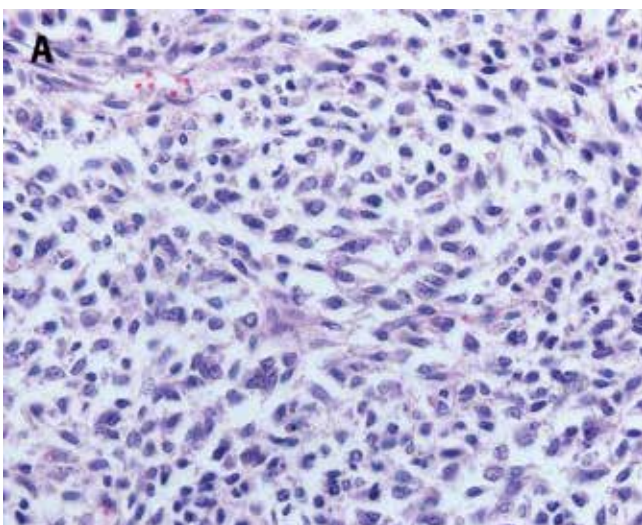
Histopathological examination of the masses revealed an invasively growing, densely cellular and non-encapsulated proliferation of a monomorphous cell population. The cells were organized in thick sheets with a scant amount of stroma and sporadic

organization into small blood-filled cavities. The cells were spindle-shaped to polyhedral with a small amount of eosinophilic cytoplasm and distinct cell borders (Figure 2A). The nuclei were round to oval with fine granular chromatin. Mitoses were frequent, ranging from 5 to 10 per high power field, often with atypical mitotic figures. There was pronounced anisocytosis and anisokaryosis. Edema was present and multifocal areas of necrosis and an influx of neutrophils were observed. Immunohistochemistry for von Willebrand factor was performed on multiple slides to confirm the endothelial origin of the neoplastic cells. Most slides from the pelvic mass showed large areas with positive immunoreaction, sometimes highlighting the small cavernous blood-filled spaces (Figure 2B). Other slides, like from the liver and lung metastases, revealed very faintly or no specific immunostaining.

These findings confirmed the diagnosis of a malignant neoplasia, more specifically a disseminated hemangiosarcoma.

## DISCUSSION

Hemangiosarcoma is relatively uncommon in horses. Affected patients often present a major diagnostic challenge. Kuipel et al. (2000) described an intrapelvic hemangiosarcoma involving the pelvis and hind limb musculature causing periodic episodes of colic and hind limb lameness. The infiltrative, multilobulated, dark red and yellow, mottled soft mass identified in that case report originated from the pelvis, dorsally to the pubic and ischiatic bones. The mass covered the whole floor of the pelvis, extended ventrally through the obturator foramina and invaded the pubic and ischiatic bones along the symphysis, causing severe bone lysis. The mass extended bilaterally



**Figure 2. A. Histopathological slide of the soft tissue mass showing spindle-shaped cells with ovoid nuclei (40x). B. Positive immunohistochemical staining of neoplastic cells for von Willebrand factor (brown pigment) confirms the diagnosis of hemangiosarcoma in this horse (20x).**



ally into the semimembranosus, adductor femoris, and medial quadriceps muscles causing diffuse hemorrhages and focally necrotic zones. In the present case, the suspected primary mass was found retroperitoneal, invading the ventral pubic bones. It was soft and cavernous areas filled with blood and white necrotic spots were present. Smaller metastatic masses were found in the lungs and liver.

In this case, hemoabdomen due to bleeding as result of trauma was first suspected. The horse did not show any chronic signs of systemic illness and was able to participate to show jumping until a few days before referral to the clinic. Due to the suspicion of hematoma formation after trauma, tranexaminic acid was administered. The treatment of acute abdominal hemorrhage depends on the severity of the clinical signs. In cases of acute hemorrhage and subsequent hypovolemic shock, rapid expansion of blood volume with isotonic crystalloids, hypertonic saline or colloids is appropriate (Magdesian, 2008). Indications for administration of whole blood include clinical and laboratory findings of hemorrhagic shock that persist after adequate restoration of hydration with crystalloid fluids. These signs include persistent hypotension, mucous membrane pallor, lethargy, cool extremities and tachycardia (Magdesian, 2008). The need for whole blood transfusion may be based on clinicopathological data, including packed cell volume less than 12%, acute blood volume loss of 30-40%, hyperlactatemia, an oxygen extraction ratio greater than 50% and decreased venous oxygen tension (Magdesian, 2008). Aminocaproic acid and tranexaminic acid, both inhibitors of fibrinolysis, are used to treat hemorrhage (Wong et al., 2009).

No neoplastic cells were found on the abdominocentesis and thoracocentesis. On the impression smear, neoplastic-like cells could be identified. Histopathologic examination of the biopsy also revealed neoplastic cells. During examination of fine needle aspirates of a hemangiosarcoma, neoplastic cells are rarely found (Taintor et al., 2014) and often, only red blood cells are identified (Bertazzolo et al., 2005). Cytology is usually more consistent with hemorrhage and not particularly useful for diagnosing hemangiosarcoma (Southwood et al., 2000; Johns et al., 2005). The neoplasms can be well or poorly differentiated and a variable number of mitotic figures might be seen (Bertazzolo et al., 2005). Spindle-shaped to enlarged ovoid, hyperchromatic nuclei located in blood filled vascular channels may be present in well-differentiated hemangiosarcomas (Bertazzolo et al., 2005). Poorly differentiated neoplastic cells can appear as solid sheets of spindle-shaped cells or pleomorphic cells, of which the vascular channels may not be obvious (Bertazzolo et al., 2005). In the present case, similar histopathological findings were present and immunohistochemical staining was necessary for diagnosis (Bertazzolo et al., 2005). Von Willebrand factor (factor VIII-related antigen) is expressed by normal and

neoplastic cells of both vascular and lymphatic origin, with the largest expression by the vascular endothelium (Bertazzolo et al., 2005; Jennings et al., 2012). The absence of (strongly) positive immunoreaction of the metastatic masses can be explained by loss of the expression of the von Willebrand factor antigen in very anaplastic and dedifferentiated cells.

The hemangiosarcoma in this case was not amenable to resection. Supportive treatment is often unrewarding (Southwood et al., 2000). In young horses (younger than three years old) however, the progression of the disease may be different. Euthanasia was proposed, but the owner declined. The horse collapsed probably due to the rupture of the well-vascularized mass present in the liver. In rare cases, early resection of the affected tissue may be successful (Johns et al., 2005).

## REFERENCES

- Bertazzolo, W., Dell'Orco, M., Bonfanti, U., Ghisleni, G., Caniatti, M., Masserdotti, C., Antoniazzi, E., Crippa, L., Roccabianca, P. (2005) Canine angiosarcoma: cytologic, histologic, and immunohistochemical correlations. *Veterinary Clinical Pathology* 34, 28-34
- Ferrucci, F., Vischi, A., Zucca, E., Stancari, G., Boccardo, A., Rondena, M., Riccaboni, P., Ferro, E. (2012). Multicentric hemangiosarcoma in the horse: A case report. *Journal of Equine Veterinary Science* 32, 65-71
- Jennings, R., Miller, M.A., Ramos-Vara, J.A. (2012). Comparison of CD34, CD31, and VVI-related antigen immunohistochemical expression in feline vascular neoplasm and CD34 expression in feline nonvascular neoplasms. *Veterinary Pathology* 49, 532-537
- Johns, I., Stephen, J., Del Piero, F., Richardson, D.W., Wilkins, P.A. (2005). Hemangiosarcoma in 11 young horses. *Journal of Veterinary Internal Medicine* 19, 564-570
- Kuipel, M., Frank, N., Stevenson, G.W., Siems, J., Snyder, P.W. (2000). Intrapelvic hemangiosarcoma in a horse. *Journal of Veterinary Diagnostic Investigation* 12, 91-95
- Magdesian, K.G. (2008). Acute blood loss. *Compendium Equine* 3, 80-90
- Pulley, L.T., Stannard, A.A. (1990). Tumors of the skin and soft tissues. In: Moulton JE (editor). *Tumors in Domestic Animals*. Third edition, Berkeley, CA: University of California Press, 23-87
- Scherrer, N.M., Lassaline, M., Engiles, J. (2017). Ocular and periocular hemangiosarcoma in six horses. *Veterinary Ophthalmology* 21(4), 432-437.
- Southwood, L.L., Schott II, H.C., Henry, C.J., Kennedy, F.A., Hines, M.T., Geor, R.J., Hassel D.M. (2000). Disseminated hemangiosarcoma in the horse: 35 cases. *Journal of Veterinary Internal Medicine* 14, 105-109
- Taintor J. (2014). Haemangiosarcoma in the horse. *Equine Veterinary Education* 26, 499-503
- Wong, D.M., Brockus, C., Alcott, C., (2009). Modifying the coagulation cascade: available medications. *Compendium Equine* 4, 224-236

## Toevalsbevinding van *Dirofilaria repens* in een hematoom bij een hond in België

### Accidental diagnosis of *Dirofilaria repens* in a hematoma in a dog in Belgium

H. De Bosschere, E. Kindermans

MedLab Bruyland – Diergeneeskunde, Beneluxpark 2, B-8500 Kortrijk, Belgium

hendrik.de.bosschere@bruyland.be

## SAMENVATTING

In deze casuïstiek wordt een tien jaar oude, vrouwelijke Mechelse herder beschreven die aangeboden werd met een grote zwelling caudaal van de mandibula en ter hoogte van de keelbasis. Op cytologisch onderzoek werd een hematoom gediagnosticeerd door middel van een fijnaaldaspiratie. Per toeval werden enkele *Dirofilaria repens* microfilariae aangetroffen in het uitstrijkje van deze zwelling. Naast de beschrijving van de casus wordt ook een literatuuroverzicht gegeven van *Dirofilaria repens*.

## ABSTRACT

A ten-year-old, female Malinois shepherd was presented with a large swelling caudally of the mandibula and at the base of the throat. On cytological examination, a hematoma was diagnosed by means of a fine needle aspiration. Coincidentally, some *Dirofilaria repens* microfilariae were observed in the slide-out. Next to the case description, a review of the literature of *Dirofilaria repens* is given.

## INLEIDING

*Dirofilaria repens* (*D. repens*) is een nematode die behoort tot het genus *Dirofilaria*, net als de meer bekende *Dirofilaria immitis*. De nematoden van dit genus hebben gedomesticeerde honden, katten en wilde carnivoren als voornaamste eindgastheer. Muggen behorende tot verschillende genera zijn de natuurlijke tussengastheer. *D. repens* veroorzaakt vaak subklinische, subcutane en oculaire dirofilariosis bij honden en katten. *D. immitis* daarentegen is wel van groot pathogeen belang in de diergeneeskunde omdat het de veroorzaker is van cardiopulmonaire dirofilariosis bij dieren. Beide *Dirofilaria* spp. hebben een bekend zoönotisch potentieel (Otranto et al., 2013; Fuehrer et al., 2016).

*Dirofilaria repens* (*D. repens*) komt voor in Europa, Afrika en Azië. Rusland is een van de belangrijkste gebieden waar *D. repens* endemisch is (Ermakova, 2014). In het zuiden en oosten van Europa is *D. repens* endemisch in Italië, Frankrijk, Griekenland, Kroatië en Spanje (Baneth et al., 2018). Miterpakova et al. (2008) hebben aangetoond dat *D. repens* ende-

misch is in Oost-Slovakije. Studies in Slovakije en Polen hebben aangetoond dat er een hoge prevalentie (34-60%) is van *D. repens* onder klinisch gezonde honden. Deze asymptomatische infecties worden niet gediagnosticeerd en bijgevolg ook niet behandeld (Bajer et al., 2014; Vichova et al., 2014). Recentelijk werden (vermoedelijk) autochtone besmettingen gerapporteerd in onder andere Oostenrijk (Duscher et al., 2009; Fuehrer et al., 2016) en Duitsland (Hermosilla et al., 2006; Pantchev et al., 2009). Het lijkt erop dat *D. repens* aan een opmars bezig is en zijn verspreidingsgebied aan het uitbreiden is naar Centraal-Europa (Genchi et al., 2011). Deze noordwaartse expansie zou het gevolg zijn van de klimaatwijziging en het toenemende verkeer van besmette honden binnen Europa (Genchi et al., 2011; Sassnau et al., 2014). De toename van de omgevingstemperatuur zorgt ervoor dat de ontwikkeling van de infectieuze L3-stadia van *Dirofilaria* spp. bij muggen noordelijker mogelijk wordt (Fortin en Slocombe, 1981).

*D. repens* is de belangrijkste veroorzaker van subcutane filariosis bij honden en katten in Europa (Genchi et al., 2013). De volwassen wormen vormen

nodules in het subcutane weefsel en de perimusculaire bindweefselfascii. Deze nodules kunnen over het volledige lichaam voorkomen (Genchi et al., 2013). Meestal verloopt een infectie met *D. repens* bij de hond asymptomatisch. De pijnloze subcutane nodules, met daarin de volwassen wormen, veroorzaken doorgaans geen klinische symptomen. Hierdoor worden veel infecties niet gediagnosticeerd. Als er wel klachten optreden zijn deze voornamelijk van dermatologische aard. Dermale zwelling, gegeneraliseerde dermatitis, lokale alopecie en jeuk worden beschreven (Rocconi et al., 2012; Baneth et al., 2018). Conjunctivitis wordt soms ook gezien (Genchi en Kramer, 2017). Allergische reacties kunnen voorkomen en zouden kunnen te wijten zijn aan allergische reacties door sensitisatie aan de microfilariae (Genchi et al., 2013). Bij honden met een zware systemische infectie kunnen histopathologische afwijkingen waargenomen worden in de lever, milt, nieren, longen, hart en hersenen (Baneth et al., 2018). Dergelijke systemische infecties zijn echter uitzonderlijk en mogelijk toe te schrijven aan immunosuppressie uitgelokt door een andere aandoening (Dzaja et al., 2008).

De vrouwelijke, volwassen wormen meten 13 tot 17 cm en hebben een diameter van 460-650  $\mu\text{m}$ . De mannetjes zijn met hun 5 tot 7 cm lengte een stuk korter (Anderson, 1952). Microfilariae (L1-stadium, 300-360  $\mu\text{m}$  lang en 6-8  $\mu\text{m}$  diameter) worden door de volwassen vrouwtjes na het paren met een mannetje uitgescheiden en komen zo in de circulatie van de eindgastheer terecht. In het muggenseizoen kan een hogere concentratie microfilariae in het perifere bloed gevonden worden, alwaar ze door een tussengastheer opgenomen worden. Vrouwelijke muggen (van de genera *Aedes*, *Anopheles*, *Culex*, *Armigeres* en *Mansonioides*) doen dienst als tussengastheer en vector voor transmissie. De microfilariae verlaten de darm van de mug en komen in de lichaamsholte terecht. Ze vervellen tweemaal in de tubuli van Malpighi, tot respectievelijk het L2- en het infectieuze L3-stadium, en migreren dan naar de proboscis (Baneth et al., 2018). De ontwikkelingsduur van *Dirofilaria* spp. in de mug is temperatuursafhankelijk en loopt gelijk voor *D. repens* en *D. immitis* (Otranto et al., 2013). Onder experimentele omstandigheden werd aangetoond dat de ontwikkeling tot de infectieuze L3-larve acht tot tien dagen in beslag neemt bij een temperatuur van 28°C tot 30°C. Hoe lager de omgevingstemperatuur, hoe langer dit duurt. Onder de 14°C valt ze stil (Morchon et al., 2012). Tijdens een bloedmaal verlaat de L3-larve de mug actief en treedt ze in de eindgastheer binnen. De L3-larve komt vervolgens in het nabijgelegen subcutane weefsel terecht en vervelt er tot een L4-larve. De prepatente periode, waarin de L4-larve zich verder ontwikkelt tot een volwassen worm, neemt ongeveer 6,5-9 maanden in beslag. Volwassen wormen kunnen in een geschikte eindgastheer 4 tot 7 jaar (patente periode) overleven en microfilariae produceren (Genchi

et al., 2013; Genchi en Kramer, 2017; Baneth et al., 2018). Honden blijken hiervoor het meeste geschikt en vormen het voornaamste reservoir voor microfilariae. Katten zijn meer resistent tegen de infectie (Genchi et al., 2013). Ook de mens kan besmet worden als accidentele eindgastheer. *D. repens* kan zich bij de mens doorgaans niet ontwikkelen tot de seksueel mature vorm en in de letsels bevinden zich preadulte stadia (Genchi en Kramer, 2017). *Dirofilariosis* door *D. repens* is de voornaamste oorzaak van humane subcutane (voornamelijk mammae en scrotum) en oculaire *dirofilariosis*; zelden worden pulmonaire of paranasale nodules gezien (Otranto et al., 2013; Baneth et al., 2018). Deze kunnen verward worden met sebunkliercysten of tumoren. Er zijn in de literatuur gegevens beschikbaar van meer dan 3500 gevallen van humane *dirofilariose* door *D. repens* in Europa, van 1977 tot 2016 (Genchi en Kramer, 2017). In Europa wordt *dirofilariosis* door *D. repens* beschouwd als een opkomende zoönose. Omdat *D. repens* bij zijn belangrijkste eindgastheer de hond, die ook het voornaamste reservoir vormt, vaak subklinisch verloopt, wordt aan deze parasitaire infectie in de diergeneeskunde weinig aandacht besteed. De diagnose berust doorgaans op een toevalsbevinding (Fuehrer et al., 2016). Herkenning, behandeling en preventie van besmettingen met *D. repens* bij de hond zullen zeker helpen om humane *D. repens*-infecties onder controle te houden (Simon et al., 2009). Alles begint bij het identificeren van honden die een reservoir vormen. Een diagnose wordt bij de hond gesteld door het vaststellen van microfilariae in een bloeduitstrijkje. Dit is een snelle methode, maar ze mist sensitiviteit en is dus niet aanbevolen. De huidige, aangeraden en betere methode is de Knott-test. Voor deze test wordt 1 ml EDTA-bloed gemengd met 9 ml 2 %-formoloplossing. Dit mengsel wordt gecentrifugeerd, het sediment wordt op een draagglasje gekleurd met methyleenblauw, bedekt met een dekglasje en onder de microscoop bekeken. Differentiatie van de microfilariae kan gebeuren met een zure fosfatasekleuring (EDTA-bloed gemengd met 10 ml gedeïoniseerd water – gecentrifugeerd en sediment op draagglasje – gedroogd en gekleurd met zure fosfatase en gefixeerd met aceton). De microfilaria zijn ongeveer 300 – 360  $\mu\text{m}$  lang en 6-8  $\mu\text{m}$  dik. Meestal zijn ze te herkennen aan een parapluhandvatvormig en puntig staarteinde en een stompe kop met 2-3 nucleï (Liotta et al., 2013). Er bestaan geen serologische testkits voor de detectie van circulerende antistoffen of antigenen van *D. repens* (Genchi et al., 2013). Een PCR-test is wel mogelijk maar beperkt beschikbaar en wordt niet routinematig toegepast (Sævik et al., 2014). Het onderscheid tussen microfilariae van *D. immitis* en *D. repens* wordt gemaakt op basis van verschillende morfologische kenmerken. De microfilariae van *D. repens* zijn significant groter dan die van *D. immitis*, al heeft die laatste wel een langere kop.

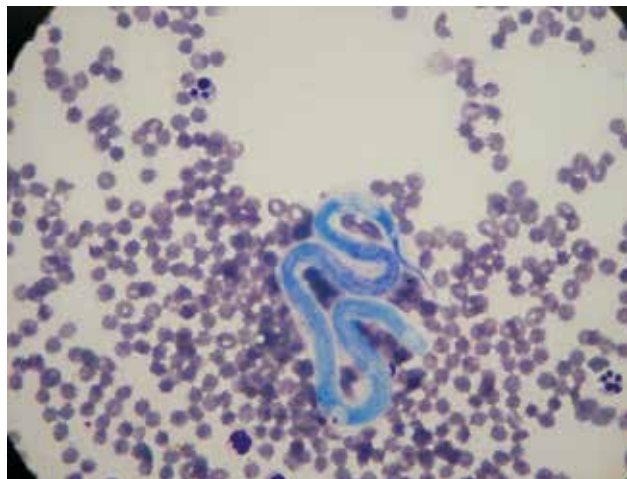## CASE REPORT

### Anamnese, algemeen onderzoek en analyses

Een tien jaar oude, vrouwelijke, intacte Mechelse herder werd aangeboden met een grote zwelling caudaal van de mandibula, ter hoogte van de keelbasis. De zwelling werd twee dagen voordien door de eigenaar opgemerkt. Deze hond leefde in een roedel en sinds kort was er een nieuwe teef bijgekomen. Hierdoor was er soms onrust en werd er onderling gevochten. Tot vier jaar voordien vergezelde de hond de eigenaar naar Zuid-Frankrijk. Op het moment van aanbieden verkeerde de hond in goede gezondheid. De eetlust was goed en stabiel, er was geen sprake van een afwijkend drinkgedrag. Urineren en defeceren verliepen normaal. Op het lichamelijk onderzoek was de hond alert, in goede algemene conditie en had ze een normale lichaamstemperatuur (38,8°C). Auscultatie van hart en longen en abdominale palpatie brachten geen afwijkingen aan het licht. Er werden geen opgezette lymfeknopen gevoeld, de gewrichten waren droog en de slijmvliezen roze met een normale capillaire vullingstijd (CVT). Aan de rechterzijde, vanaf de oorbasis tot tussen de kaaktakken, bevond zich een grote, niet-pijnlijke, fluctuerende, retromandibulaire zwelling van ongeveer 20cm op 10cm.

De dierenarts nam een fijneaaldaspiraats (FNA) van de zwelling. Het punctievocht was serohemoragisch van uitzicht en werd naar het labo gezonden voor verder onderzoek. Differentiaaldiagnostisch werd gedacht aan een abces, hematoom, sialadenitis en neoplasie.

In het labo werd de punctie geanalyseerd met de hematologie-analyzer XTvet (Sysmex, Etten-Leur, Nederland), uitgestreken op een draagglasje, aan de lucht gedroogd en gekleurd met Hemacolor® (Merck, Darmstadt, Duitsland). Celtelling door de XTvet leverde  $2,04 \times 10^3/\mu\text{l}$  leukocyten,  $1,34 \times 10^6/\mu\text{l}$  erythrocyten,  $18 \times 10^3/\mu\text{l}$  trombocyten op. Cytologisch werden zo goed als uitsluitend erythrocyten, een gering aantal leukocyten en sporadisch een trombocyt waargenomen. Daarnaast werden enkele microfilariae aangetroffen (Figuur 1). Deze waren ongeveer  $350 \times 6-7\mu\text{m}$  groot. De cytologische diagnose van hematoom met aanwezigheid van microfilariae werd gesteld. Bacteriologisch onderzoek van de punctie was negatief. De dierenarts werd van de bevindingen op de hoogte gesteld en na overleg met de eigenaar werd een bloedstaal genomen van deze en van de drie andere honden. Uit het hematologisch onderzoek van alle vier de honden kwamen geen afwijkingen naar voor. Bijkomend werd van alle honden een bloeduitstrijkje bekeken als screening voor *Babesia*, *Ehrlichia* en *Anaplasma*. Het resultaat hiervan was negatief. Er werd daarnaast gezocht naar microfilariae door middel van de Knott-test (Marcos et al., 2016). In het staal van de hond met de zwelling werden microfilariae aangetroffen. De stalen van de andere honden waren negatief.



**Figuur 1.** *Dirofilaria repens* tussen de erythrocyten van het hematoom. Vergroting 500x.

Een algemeen biochemisch onderzoek werd niet uitgevoerd uit financiële overweging. Gezien de voorgeschiedenis van reizen naar het buitenland en het endemisch zijn van verschillende andere aandoeningen in die regio's waar ook *D. repens* endemisch is, werd een SNAP 4dx-sneltest (IDEXX, Ludwigsburg, Duitsland) uitgevoerd. Deze test detecteert antigenen van *Dirofilaria immitis* en antistoffen tegen *Borrelia burgdorferi*, *Ehrlichia canis*, *Ehrlichia ewingii*, *Anaplasma phagocytophilum* en *Anaplasma platys*. De test was negatief, net als een sneltest voor *Angiostrongylus vasorum*-antigenen (IDEXX, Ludwigsburg, Duitsland).

Na deze onderzoeken en een literatuurstudie werd de diagnose van cutaan hematoom met de aanwezigheid van microfilariae gesteld. Gebaseerd op de afmetingen en karakteristieke kenmerken (Liotta et al., 2013) werd geconcludeerd dat het vermoedelijk om microfilariae van *D. repens* ging. Of de microfilariae of het migreren van de adulte wormen een rol hebben gespeeld in het ontstaan van het hematoom kan niet gezegd worden.

De hond werd behandeld met Advocate® (imidacloprid en moxidectin, Bayer, Leverkusen, Duitsland), één pipet per maand, toediening volgens aanwijzingen van de fabrikant gedurende drie opeenvolgende maanden.

Twee weken na de eerste consultatie was het hematoom gehalveerd in omvang en verder uitgezakt tussen de kaaktakken. De hond leek alerter dan bij het eerste bezoek. Het lichamelijk onderzoek was normaal en er werden geen nodules of andere afwijkingen gevonden tijdens het dermatologisch onderzoek. Nog twee weken later was de zwelling volledig verdwenen.

## DISCUSSIE

Er zijn geen literatuurgegevens bekend van een diagnose van *D. repens* bij de hond in België. In onze contreien is er een gebrek aan ervaring met deze para-



siet. De prevalentie zou laag zijn en de meeste infecties verlopen subklinisch. Waarschijnlijk heeft deze hond de besmetting opgelopen tijdens een verblijf in Zuid-Frankrijk, al kan dat niet met zekerheid gesteld worden.

Honden met een voorgeschiedenis van reizen naar of leven in een gebied waar *D. repens* endemisch is, worden niet routinematig gescreend. Er is geen serologische testkit voor de detectie van circulerende antistoffen of antigenen beschikbaar (Genchi et al., 2013). Een PCR-test bestaat maar is niet overal uitvoerbaar. Hierdoor worden de meeste gevallen waarschijnlijk niet gediagnosticeerd en kunnen besmette honden gedurende lange tijd een actief reservoir zijn voor infectie voor mens en dier.

Verskillende factoren, zoals de omgevingstemperatuur, de aanwezigheid en concentratie van de vector en microfilarische honden, spelen een rol in de overdracht en de verspreiding van *Dirofilaria* spp. Momenteel is *D. repens* niet endemisch in België. Vooraleer dit zou kunnen gebeuren, moet er aan verschillende voorwaarden voldaan worden. De vector is aanwezig maar in het geval van *D. repens* moet de parasiet er zich kunnen ontwikkelen tot het infectieuze stadium (Fuehrer et al., 2016). Hierbij spelen de klimatologische omstandigheden een belangrijke rol. De parameter “growing degree-day” (GDD) wordt gebruikt om de geografische distributie en seizoensgebondenheid te voorspellen van *Dirofilaria* spp. in verschillende delen van de wereld. Deze modellen zijn gebaseerd op een minimumtemperatuur van 14°C voor de ontwikkeling van *Dirofilaria* tot het L3-stadium in de tussengastheer. Voor de larvale transformatie tot dit infectieus stadium zijn er 130 GDD nodig (Genchi et al., 2011). Deze voorwaarden komen steeds meer noordelijker voor. Door het transport van honden uit endemische gebieden in Europa naar meer noordelijke streken neemt de prevalentie van microfilarische honden in Centraal- en Noord-Europa toe en zou de cyclus zich ook in Noord-Europa kunnen voltrekken (Genchi et al., 2009). Er moet een minimumpopulatie van de eindgastheer aanwezig zijn opdat de besmetting zich binnen de populatie onder de dragers kan handhaven (Fuehrer et al., 2016).

Vanuit een zoönotisch standpunt is het belangrijk om dragerschap bij honden te voorkomen. Dit kan gebeuren door honden die leven of reizen in endemische zones te behandelen met producten op basis van macrocyclische lactones gedurende de periode waarin de muggen actief zijn (Otranto et al., 2013). In Europa is dit voornamelijk tijdens de lente en de zomer (Morchon et al., 2012). Het European Scientific Council on Companion Animal Parasites (ESCCAP) raadt echter aan om deze periode uit te breiden tot 7-8 maanden of zelfs het hele jaar door. Deze producten doden de larven vooraleer ze zich in de eindgastheer kunnen ontwikkelen tot volwassen wormen. Verschillende formuleringen en combinatiepreparaten zijn commercieel beschikbaar in België. Er kan gekozen worden voor milbemycine oxime (toediening per os; hond:

0,5-1 mg/kg, kat: 2-4 mg/kg), moxidectine (topicaal; hond: 2,5-6,25 mg/kg, kat: 1-2 mg/kg) of selamectine (topicaal; hond: 6-12 mg/kg, kat: 6-12 mg/kg). Een preventieve behandeling moet begonnen worden voor het begin van het muggenseizoen, ze moet maandelijks herhaald worden en moet voortgezet worden tot een maand na het einde van het muggenseizoen.

De identificatie en behandeling van honden die volwassen wormen herbergen, is aangewezen omdat deze honden dienst doen als reservoir en aanleiding geven tot de verspreiding van de nematode. Recentelijk werd de werkzaamheid van imidaclopride 10% / moxidectine 2,5% aangetoond voor de behandeling van *D. repens* (Fok et al., 2010; Genchi et al., 2010; Rocconi et al., 2012). Een microfilaricide effect werd bevestigd en een adulticide effect werd verondersteld, gebaseerd op het feit dat microfilaria niet werden waargenomen zes maanden tot een jaar na behandeling van geïnfecteerde honden.

Cutane nodules met daarin de volwassen stadia van *D. repens* kunnen chirurgisch worden weggenomen indien nodig.

Het onder controle houden van *D. repens* in de omgeving kan ook gebeuren door muggenbestrijding, daar muggen fungeren als tussengastheer. Muggenbestrijding is echter controversieel omwille van de effecten op het ecosysteem.

Samenvattend kan gesteld worden dat de practicus rekening moet houden met het mogelijke voorkomen van *D. repens* in België. Er wordt in de huidige praktijkomstandigheden vaak gescreend op vector-overdraagbare aandoeningen, zoals *B. canis*, *D. immitis*, *E. canis* en *E. ewingii*, *A. phagocytophilum*, *B. burgdorferi* en *Leishmania infantum*. Dit gebeurt met name bij honden met een voorgeschiedenis van reizen naar gebieden waar deze ziekten endemisch zijn en bij honden die uit een dergelijk gebied geadopteerd worden. Bij deze honden is het raadzaam ook een Knott-test uit te voeren om *D. repens* op te sporen en een behandeling in te stellen indien nodig. Een goede samenwerking tussen dierenartsen en humane artsen is belangrijk om deze opkomende zoönose in de toekomst het hoofd te bieden.

## REFERENTIES

- Anderson R. C. (1952). Description and relationship of *Dirofilaria ursi* Yamaguty, 1941, and a review of the genus *Dirofilaria* Raillet and Henry, 1911. *Transactions of the Royal Canadian Institute* 29, 35-65.
- Bajer A., Mierzejewska E. J., Rodo A., Bednarska M., Kowalec M. Welc-Faleciak R. (2014). This risk of vector-borne infections in sled dogs associated with existing and new endemic areas in Poland: part I: A population study on sled dogs during the racing season. *Veterinary Parasitology* 202, 276-286.
- Baneth G., Duscher G., Joachim A. (2018). Vetstream Canis ISSN: 2398-2942 <https://www.vetstream.com/treat/canis/bug/dirofilaria-repens>
- Duscher G., Feiler A., Wille-Piazzai W., Bakonyi T., Les-

- chnik M., Miterpáková M., Kolodziejek J., Nowotny N., Joachim A. (2009). Detection of *Dirofilaria* in Austrian Dogs. *Berliner und Münchener Tierärztliche Wochenschrift* 122, 199-203.
- Dzaja P., Beck A., Kis G., Gudan Kurilj A., Zivicnjak T., Artukovic B., Beck R., Hohsteter M., Zuckermann Sostaric I. C., Grabarevic Z. (2008). *Dirofilaria repens* infection in a dog in Croatia – a case report. *Veterinarski Archiv* 78, 521-527.
- Ermakova L. A., Nagorny S. A., Krivorotova E. Y., Pshenichnaya N. Y., Matina O. N. (2014). *Dirofilaria repens* in the Russian Federation: current epidemiology, diagnosis, and treatment from a federal reference center perspective. *International Journal of Infectious Diseases* 23, 47-52.
- Fuehrer H. P., Auer H., Leschnik M., Silbermayr K., Düscher G., Joachim A. (2016). Review. *Dirofilaria* in humans, dogs, and vectors in Austria (1978-2014) – from imported pathogens to the endemicity of *Dirofilaria repens*. *PLoS Neglected Tropical Diseases* 10 (5), e0004547. doi:10.1371/journal.pntd.0004547.
- Fok E., Jacsó O., Szebeni Z., Györffy A., Sükösd L., Lukács Z., Schaper R. (2010). Elimination of *Dirofilaria* (syn. *Nochtiella*) *repens* microfilariae in dogs with monthly treatments of moxidectin 2.5%/imidacloprid 10% (Advocate®, Bayer) spot-on. *Parasitology Research* 106, 1-9.
- Fortin J. F., Slocombe J. O. (1981). Temperature requirements for the development of *Dirofilaria immitis* in *Aedes triseriatus* and *Ae. vexans*. *Mosquito News* 41, 625-626.
- Genchi C., Rinaldi L., Mortarino M., Genchi M., Cringoli G. (2009). Climate and *Dirofilaria* infection in Europe. *Veterinary Parasitology* 163, 286-292.
- Genchi C., Kramer L. H., Rivasi F. (2011). *Dirofilarial* infections in Europe. *Vector Borne Zoonotic Diseases* 11, 1307-1317.
- Genchi C., Mortarino M., Rinaldi L., Cringoli G., Traldi G., Genchi M. (2011). Changing climate and changing vector-borne disease distribution: The example of *Dirofilaria* in Europe. *Veterinary Parasitology* 176, 295-299.
- Genchi C., Genchi M., Petry G. (2013). Evaluation of the efficacy of Imidacloprid 10% / Moxidectin 2.5% (Advocate®, Advantage® Multi, Bayer) for the prevention of *Dirofilaria repens* infection in dogs. *Parasitology Research* 112, 81-89.
- Genchi C., Kramer L. (2017). Review. Subcutaneous dirofilariosis (*Dirofilaria repens*): an infection spreading throughout the old world. *Parasites & Vectors* 10 (Suppl 2), 517.
- Genchi M., Pengo G., Genchi C. (2010). Efficacy of moxidectin microsphere sustained release formulation for the prevention of subcutaneous filarial (*Dirofilaria repens*) infection in dogs. *Veterinary Parasitology* 170, 167-169.
- Hermosilla C., Pantchev N., Dyachenko V., Gutmann M., Bauer C. (2006). First autochthonous case of canine ocular *Dirofilaria repens* infection in Germany. *Veterinary Record* 158, 134-135.
- Liotta J. L., Sandhu G. K., Rishniw M., Bowman D. D. (2013). Differentiation of the microfilariae of *Dirofilaria immitis* and *Dirofilaria repens* in stained blood films. *Journal of Parasitology* 99, 421-425.
- Marcos R., Pereira C., Santos M., Luzzago C., Lauzi S., Maia J. P., Faustino A., Puente-Payo P. (2016). Buffy coat smear or Knott's test : which to choose for canine microfilaria screening in field studies? *Veterinary Clinical Pathology* 45, 201-205.
- Miterpáková M., Antolová D., Hurníková Z., Dubinský P. (2008). *Dirofilariosis* in Slovakia - a new endemic area in Central Europe. *Helminthologia* 45, 20-23.
- Morchon R., Carreton E., Gonzalez-Miguel J., Mellado-Hernandez I. (2012). Heartworm disease (*Dirofilaria immitis*) and their vectors in Europe – new distribution trends. *Frontiers in Physiology* 3, 196.
- Otranto D., Dantas-Torres F., Brianti E., Traversa D., Petric D., Genchi C., Capelli G. (2013). Vector-borne helminths of dogs and humans in Europe. *Parasites & Vectors* 6, 16. <https://doi.org/10.1186/1756-3305-6-16>.
- Pantchev N., Norden N., Lorentzen L., Rossi M., Rossi U., Brand B., Dyachenko V. (2009). Current surveys on the prevalence and distribution of *Dirofilaria* spp. in dogs in Germany. *Parasitology Research* 105, 63 - 74.
- Rocconi F., Di Tommaso M., Traversa D., Palmieri C., Pampurini F., Boari A. (2012). Allergic dermatitis by *Dirofilaria repens* in a dog: clinical picture and treatment. *Parasitology Research* 111, 493 - 496.
- Saevik B. K., Jörundsson E., Stachursk-Hagen T., Tynes K., Brun-Hansen H., Wikström H. C., Robertson L. (2014). *Dirofilaria repens* infection in a dog imported to Norway. *Acta Veterinaria Scandinavica* 56, 1-6.
- Sassnau R., Dauschies A., Lendner M., Genchi C. (2014). Climate suitability for the transmission of *Dirofilaria immitis* and *D. repens* in Germany. *Veterinary Parasitology* 205, 239-245.
- Simon F., Morchon R., Gonzalez-Miguel J., Marcos-Atxutegi C., Siles-Lucas M. (2009). What is new about animal and human dirofilariosis ? *Trends in Parasitology* 25, 404-409.
- Vichova B., Miterpakova M., Iglodyova A. (2014). Molecular detection of co-infections with *Anaplasma phagocytophilum* and / or *Babesia canis canis* in *Dirofilaria*-positive dogs from Slovakia. *Veterinary Parasitology* 203, 167-172.

## Supraventriculaire tachycardie met isoritmische atrioventriculaire dissociatie bij een labrador-retriever

*Supraventricular tachycardia with isorhythmic atrioventricular dissociation in a Labrador retriever*

<sup>1</sup>A. van Loon, <sup>1</sup>V. Liekens, <sup>2</sup>D. Binst, <sup>1</sup>D. Paepe, <sup>3</sup>B. Houdellier, <sup>1</sup>P. Smets

<sup>1</sup>Vakgroep Kleine Huisdieren, Faculteit Diergeneeskunde, Universiteit Gent, Salisburylaan 133, B-9820 Merelbeke, België

<sup>2</sup>FAVV, Administratief Centrum Kruidtuin, Food Safety Center, Kruidtuinlaan 55, B-1000 Brussel, België

<sup>3</sup>Vakgroep Medische Beeldvorming en Orthopedie, Faculteit Diergeneeskunde, Universiteit Gent, Salisburylaan 133, B-9820 Merelbeke, België

vanloon.acj@gmail.com

### SAMENVATTING

Een vrouwelijke, gesteriliseerde labrador-retriever van zeven jaar oud werd aangeboden met klachten van tachypneu, kokhalzen en abdominale distensie. Op het lichamelijk onderzoek werden een systolische hartruis met een intensiteit van 3/6 en punctum maximum links apicaal, tachycardie en zwak geslagen, femorale polsen opgemerkt. Een undulatieproef was positief. Na echocardiografisch en electrocardiografisch onderzoek werden dilatorische cardiomyopathie (primair of secundair) en supraventriculaire tachycardie (SVT) vastgesteld. Na instelling van een behandeling met digoxine werd tijdens de opvolging een isoritmische atrioventriculaire dissociatie (IAVD) waargenomen en bleek de SVT onvoldoende onder controle gebracht. Na het overschakelen op diltiazem werd op het ECG vastgesteld dat de tachycardie onder controle was. Echocardiografisch onderzoek toonde aan dat het hart zich hersteld had. De hond vertoonde de daaropvolgende twee jaar geen cardiale symptomen meer. In deze casus wordt de zeldzame aritmie IAVD in combinatie met SVT beschreven. Daarnaast wordt het belang aangetoond van SVT als mogelijk reversibele oorzaak van een DCM-fenotype op echocardiografie.

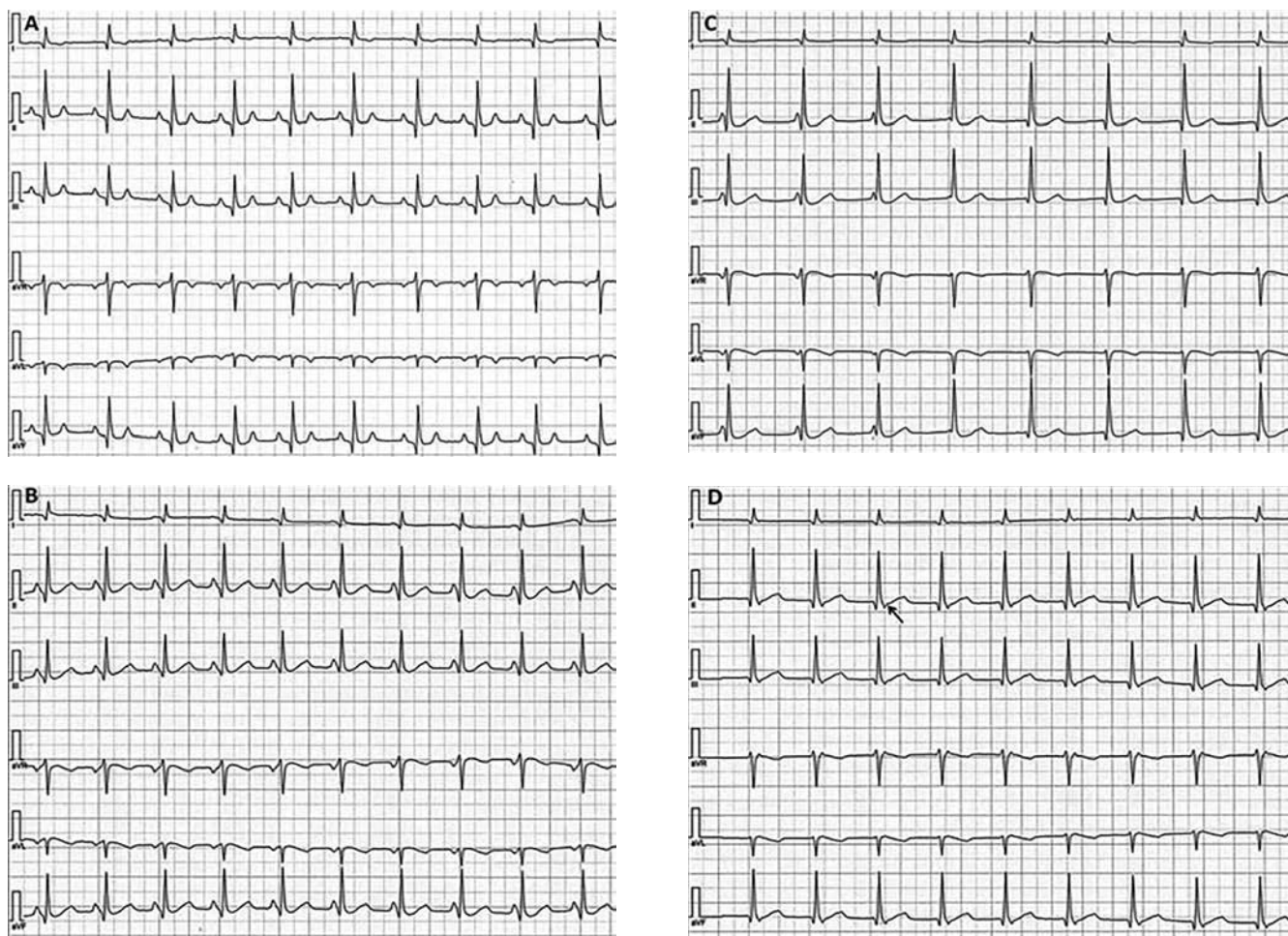
### ABSTRACT

A neutered, seven-year-old, female Labrador retriever was presented with complaints of tachypnea, gagging and abdominal distension. A left apical systolic murmur with an intensity of 3/6, tachycardia, weak femoral pulses and positive undulation were observed on physical examination. After echocardiographic and electrocardiographic examination, dilated cardiomyopathy (primary or secondary) and supraventricular tachycardia were diagnosed. At a later control visit, after initiation of treatment with digoxin, electrocardiography revealed isorhythmic atrioventricular dissociation (IAVD) and poor control of the SVT. After transition to diltiazem, the tachycardia was well-controlled. A full recovery of the heart was observed on echocardiographic examination. Twenty-four months later, the dog showed no more cardiac signs. In this case report, a rare arrhythmia, i.e. IAVD in combination with SVT is described. It shows the importance of SVT as a reversible cause of a DCM-like phenotype on echocardiography.

### INLEIDING

Een normale hartfrequentie bij de volwassen hond bevindt zich tussen de 70 en 160 slagen per minuut (bpm). Er wordt van tachycardie gesproken zodra

de hartfrequentie deze bovengrens overstijgt. Tachycardie kan zowel een supraventriculaire of ventriculaire oorsprong hebben (Ware, 2013a). Tot de supraventriculaire tachyaritmieën (SVTs) behoren zowel de echte supraventriculaire ofwel atriale, alsook de



**Figuur 1.** Elektrocardiogram met afleidingen I, II, III, aVR, aVL en aVF van labrador-retrievers. A. Sinusritme. B. FJT met IAVD type II. C. FJT met IAVD type I. D. FJT met ventriculo-atriale conductie (uit: Perego et al., 2012).

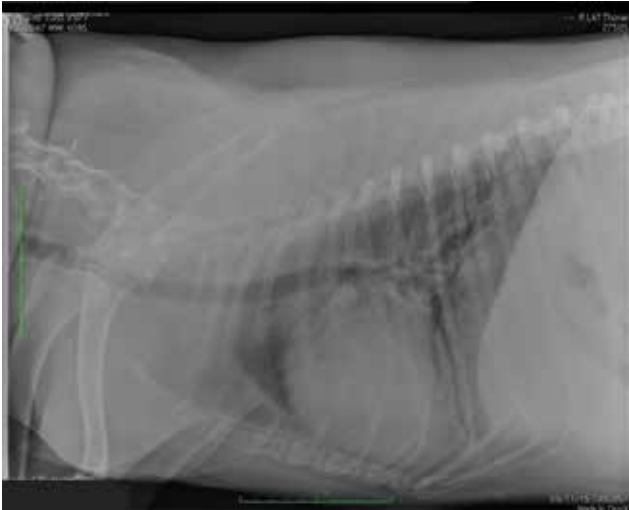junctionale of atrioventriculaire aritmieën. Dit zijn tachycardieën met een normale of supraventriculaire morfologie van de QRS-complexen op elektrocardiografie (ECG). De SVTs vinden hun oorsprong in de sinusknoop, het atriale myocard, de atrioventriculaire (AV) knoop en de bundel van His. De hartfrequentie van deze SVT bij de hond is vaak meer dan 180 bpm. Specifieke atriale SVTs zijn onder andere atriumfibrillatie (AF), atriale flutter (AFL) en focale atriale tachycardie (FAT). Onder de junctionale SVTs vallen orthodrome atrioventriculaire wederkerige (“reciprocating”) tachycardie (OAVRT) en focale junctionale tachycardie (FJT) (Ware, 2013a; Pariaut et al., 2014).

IAVD is een fenomeen dat kan worden waargenomen op een oppervlakte-ECG in combinatie met een SVT (Perego et al., 2012). Hierbij hebben de atria en ventrikels ieder een eigen gebied waar de prikkel ontstaat. Deze gebieden depolariseren onafhankelijk van elkaar maar in een bijna gelijk ritme. De gangmaker van de atriale contractie is de sinusknoop, de gangmaker van de ventriculaire depolarisatie kan ofwel uit het junctionale gebied afkomstig zijn of een ventriculaire oorsprong hebben. De contractie van de atria en de ventrikels gebeurt daardoor nagenoeg in hetzelfde ritme maar wel onafhankelijk van elkaar. Daarbij zijn

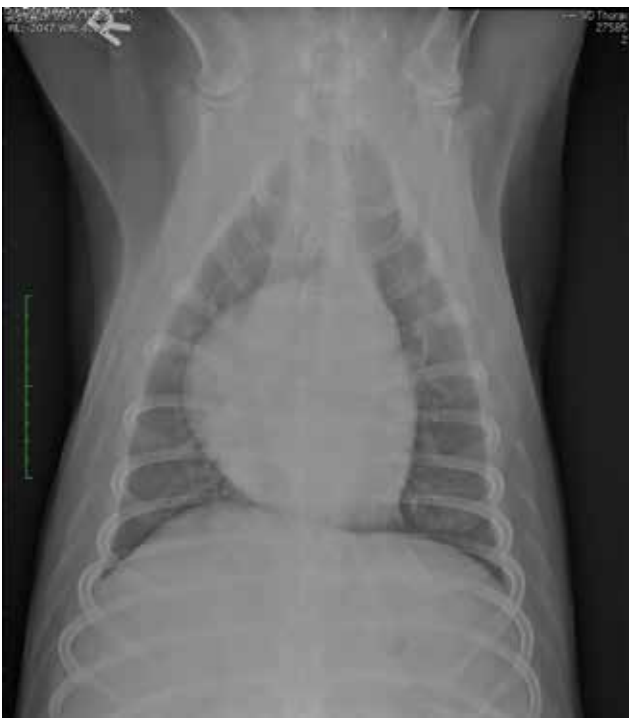er twee types van IAVD: bij type I beweegt de P-golf heen en weer doorheen het QRS-complex, waardoor het PQ-interval verschilt (Figuur 1B). Bij type II is er een vaste relatie tussen de P-golf en het QRS-complex en is er dus een relatief vast PQ-interval (Figuur 1C). Hierbij kan de P-golf zich voor, in of net achter het QRS-complex bevinden. Ter vergelijking wordt in Figuur 1A een sinusritme getoond. Bij een IAVD is er eveneens een diastolische dysfunctie, omdat het verdwijnen van de synchronisatie tussen de atria en de ventrikels resulteert in het verlies van de bijdrage van de atriale contractie in het eind-diastolisch volume van de ventrikel. Deze diastolische dysfunctie is het grootst wanneer de AV-kleppen gesloten zijn op het moment van de contractie van de atria (Perego et al., 2012).

De meest voorkomende SVT bij de hond is AF. AF ontstaat door de continue onafhankelijke activatie van multiële, ectopische gangmakers in het atriale myocard. Hierdoor verliest het atrium zijn gecoördineerde contractie. De AV-knoop geleidt de supraventriculaire prikkels at random met als resultaat een onregelmatig ritme met meestal een verhoogde frequentie (“ventricular response rate”) van 130-260 bpm. AF kan alleenstaand voorkomen (eerder zelden bij de hond)





**Figuur 2.** Rechts laterale radiografische opname van de thorax op het moment van aanbieden. Vermoeden van een rechtszijdige cardiomegalie door vergroot contact met het sternum. Geen abnormaliteiten in de pulmonaire vascularisatie.



**Figuur 3.** Ventrodorsale radiografische opname van de thorax op het moment van aanbieden. Vermoeden van een rechtszijdige cardiomegalie door de hartvorm als een omgekeerde D. Geen abnormaliteiten in de pulmonaire vascularisatie.

of meer frequent ten gevolge van een onderliggende, structurele hartaandoening (Menaut et al., 2005; Ware, 2013a; Pariaut et al., 2014). AFL is een atriale tachycardie met een hartfrequentie van meestal boven de 300 bpm en met een regelmatig ritme (Pariaut et al., 2014). De prikkel komt uit een gangmaker in het atrium die zichzelf herhaaldelijk depolariseert, wat “re-entry” wordt genoemd. Bij AFL is er in tegenstelling tot AF nog een gecontroleerde contractie van het

atriale myocard (Ware, 2013a; Pariaut et al., 2014). Bij atriale, premature complexen ontstaat de impuls vanuit een ectopische gangmaker in het atrium buiten de sinusknop, waarbij de meerderheid van de FAT uit een ectopische gangmaker in het rechteratrium komt (Pariaut et al., 2014). De FAT is een tachycardie met een hartfrequentie rond de 210-230 bpm en een meestal onregelmatig ritme. OAVRT zijn re-entry-tachyartimieën, waarbij de prikkel meestal vanuit de junctionale regio via de normale geleidingsweefsels naar de ventrikels wordt geleid, maar waar er via een “accessory pathway” een ventriculoatriale geleiding terug naar de AV-knoop is, waardoor deze opnieuw depolariseert. De hartfrequentie ligt bij deze aritmie vaak tussen de 180-300 bpm met een regelmatig R-R-interval (Santilli, 2000; Pariaut et al., 2014). Daarnaast wordt OARVT geassocieerd met een accessoire pathway beschreven bij de labrador-retriever (Wright et al., 1996; Santilli et al., 2006). FJT is een zeldzame hartritme stoornis die ontstaat door een snelle ontlading van de junctionale regio aan een regelmatig ritme van 120-200 bpm (Perego et al., 2012; Pariaut et al., 2014). FJT kan worden gekenmerkt door een 1:1 ventriculo-atriale conductie: de elektrische prikkel ontstaan in de junctionale regio wordt retrograad naar het atriale myocard geleid (Figuur 1D). Soms wordt deze 1:1 ventriculo-atriale conductie afgewisseld met IAVD. IAVD werd beschreven bij elf labrador-retrievers waarbij een associatie met FJT werd verondersteld (Perego et al., 2012).

Deze hogergenoemde SVT kunnen van elkaar gedifferentieerd worden aan de hand van hun karakteristieken op een oppervlakte-ECG (hartfrequentie, regelmaat, identificatie p'-golf, Rp'-interval, elektrische as van de p'-golf, QRS-complex alternans, abrupt of geleidelijk begin en einde) en hun respons op vagale manoeuvres (Santilli et al., 2008; Pariaut et al., 2014). Voor een definitieve diagnose is echter elektrofysiologisch onderzoek noodzakelijk.

Een mogelijk gevolg van een SVT is een zogenaamde tachycardie-geïnduceerde cardiomyopathie (TICM). Dit is meestal een systolische dysfunctie van het myocard met als onderliggende oorzaak een al dan niet op dat moment aanwezige tachyritmie (Umana et al., 2003; Khasnis et al., 2005; Ware, 2013b; Pariaut et al., 2014). Echocardiografisch vertoont het hart veranderingen die overeenkomen met het beeld dat wordt gezien bij dilatatorische cardiomyopathie (DCM), zoals linkeratrium- en linkerventrikeldilatatie en systolische dysfunctie (Umana et al., 2003; Khasnis et al., 2005; Ware, 2013b). Zowel supraventriculaire als ventriculaire tachyartimieën (VT) kunnen progressieve wijzigingen in het myocard teweegbrengen via verscheidene mechanismen, zoals energiedepletie in de mitochondriën, myocardiale ischemie en oxidatieve stress (Zupan et al., 1996). De wijzigingen in de myocyten, de extracellulaire matrix, de neurohumorale activatie en de elektrofysiologie leiden tot de morfologische en functionele veranderingen die met radiografie en echocardiografie worden waargenomen

(Shinbane et al., 1997; Umana et al., 2003; Khasnis et al., 2005). De veranderingen van het hart en de daarmee gepaard gaande disfunctie zijn voornamelijk afhankelijk van de duur van de tachycardie en de hartfrequentie. Hoe hoger de hartfrequentie, des te sneller er afwijkingen in het myocard ontstaan (Shinbane et al., 1997). Verder induceren continue tachycardieën meer schade dan intermitterende (Moe et al., 1995). Continue SVTs aan een hartfrequentie van 180 bpm kunnen in drie weken al aanleiding geven tot ventriculaire disfunctie (Zupan et al., 1996; Shinbane et al., 1997). In een studie van Riegger en Liebau (1981) traden ernstige ventriculaire disfunctie en sterfte op ten gevolge van fatale aritmie en congestief hartfalen bij een frequentie van 240-280 bpm gedurende veertien dagen. Daarnaast toonden Zupan et al. (1996) aan dat chronische VT een groter effect heeft op beschadiging van het hart dan chronische SVT. Bovendien is de kans op plotse sterfte door de verandering naar een maligne aritmie groter bij VT (Khasnis et al., 2005; Oyama en Reynolds, 2014). Indien de oorzakelijke aritmie laattijdig wordt opgemerkt of de ingestelde therapie inadequaat is, kunnen de structurele veranderingen zodanig vergevorderd en irreversibel zijn, dat volledig herstel van de dysfuncties niet meer mogelijk is (Gopinathannair et al., 2015).

Op echocardiografisch onderzoek hebben TICM en primaire DCM een gelijkaardig uitzicht. Bij beide aandoeningen is er een dilatatie van één of meerdere hartkamers met systolische disfunctie (Santilli, 2000; Ware, 2013b; Pariaut et al., 2014). Hierbij is de dilatatie van het linkerhart vaak het meest prominent, de ventrikels hebben een afgeronde vorm en de wanddikte kan normaal tot afgenomen zijn (Shinbane et al., 1997; Wess et al., 2010; Ware, 2013b; Gupta en Figueredo, 2014). Door annulaire dilatatie kan secundair mitralis- en tricuspidalisklepregurgitatie ontstaan (Shinbane et al., 1997; Khasnis et al., 2005; Gupta en Figueredo, 2014). Aldus moet bij een patiënt met de morfologische en functionele kenmerken van DCM en bij de aanwezigheid van een aritmie TICM in de differentiaaldiagnose worden opgenomen (Umana et al., 2003; Khasnis et al., 2005; Wright, 2015). De diagnose van TICM wordt vaak pas bevestigd na normalisatie van het hart door de ingestelde antiaritmische therapie (Umana et al., 2003; Gopinathannair et al., 2015).

Honden met TICM en de geassocieerde tachycardie zijn vaak asymptomatisch. In dat geval wordt de aandoening vaak per toeval ontdekt, bijvoorbeeld tijdens een lichamelijk routineonderzoek (Pariaut et al., 2014). Anderzijds worden sommige honden pas aangeboden met tekenen van linker en/of rechter congestief hartfalen. Symptomen van congestief hartfalen zijn onder andere tachypneu, dyspneu, hoesten, pleurale effusie, longoedeem en abdominale distensie (DeFrancesco, 2013). Soms worden eerdere tekenen, zoals inspanningsintolerantie, lethargie, een snelle hartslag en hijgen door de eigenaar opgemerkt (Pari-

aut et al., 2014; Wright, 2015). Tekenen van gastrointestinale origine, zoals braken, kokhalzen en partiële anorexie, kunnen ook voorkomen (DeFrancesco, 2013; Wright, 2015).

De therapie voor TICM is tweeledig en bestaat uit een ondersteunende behandeling en een antiaritmische behandeling (Gopinathannair et al., 2015). Met de ondersteunende therapie wordt getracht de systolische functie te verbeteren en de progressie naar hartfalen tegen te gaan of in het geval van hartfalen deze te behandelen (Ware, 2013b). De antiaritmische behandeling is eveneens zeer belangrijk omdat het tijdig instellen van een adequate antiaritmische therapie een volledig herstel van het hart kan betekenen (Umana et al., 2003; Ware, 2013b; Pariaut et al., 2014; Gopinathannair et al., 2015).

In de onderstaande casus wordt een labrador-retriever met een combinatie van SVT en IAVD en een geassocieerde TICM beschreven.

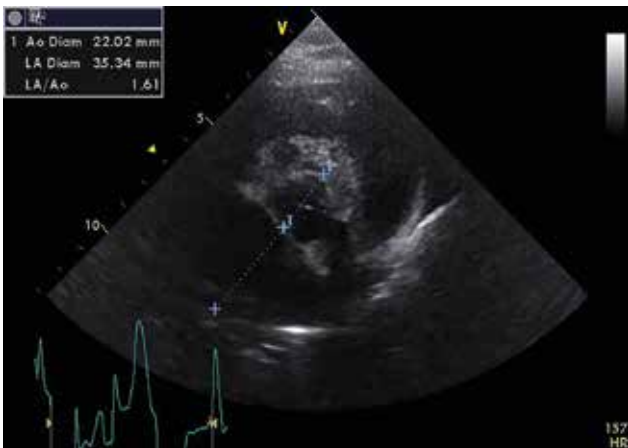
## CASUISTIËK

Een vrouwelijke, gesteriliseerde labrador-retriever van bijna zeven jaar oud werd aangeboden met klachten van kokhalzen sinds een maand. De hond kokhalste enkele keren per dag zonder aanleiding of tekenen van misselijkheid. Braken was afwezig. Sinds één week waren ook klachten ontstaan van een snellere ademhaling met een licht snuivend geluid, toegenomen buikomvang en had de eigenaar een hoge hartfrequentie opgemerkt.

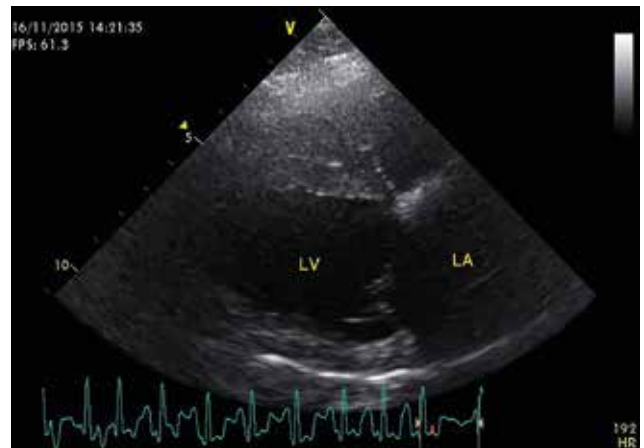
Op het algemeen lichamelijk onderzoek had de hond een body condition score van 6/9 en woog 33,6 kg. Ze vertoonde tachypneu (64 per minuut) en produceerde mild versterkte ademhalingsgeluiden. Het dier vertoonde eveneens tachycardie (180 tot 240 bpm) en er was bilateraal een systolische hartruis met een intensiteit van 3/6 hoorbaar met punctum maximum links apicaal. De femorale polsen waren zwak geslagen, wisselend gevuld en af en toe was een polsdeficit aanwezig. De hond vertoonde ook een matige abdominale distensie; een undulatieproef was positief.

Tijdens de eerste consultatie werd een radiografisch onderzoek van de thorax uitgevoerd om mogelijke oorzaken van de milde tachypneu op te sporen. Omwille van de hartruis en de tachycardie werden een echocardiografisch onderzoek en ECG uitgevoerd. Een volledig bloedonderzoek (hematologie, biochemie) werd uitgevoerd gezien de middelbare leeftijd van de hond en de elektrolyten werden bepaald omwille van de mogelijkheid van een aritmie.

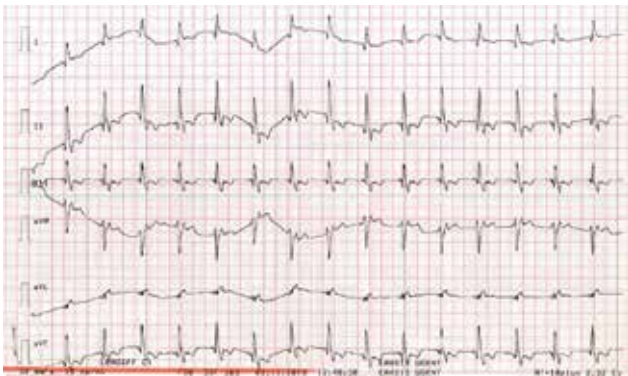Op de thoracale radiografieën werd op de rechts laterale opname een verhoogd contact tussen het hart en het sternum gezien en op de ventrodorsale opname had het hart de vorm van een omgekeerde D (Figuur 2 en 3), wijzend op een mogelijke, rechtszijdige cardiomegalie, met een "vertebral heart scale" van 11 (8,5-10,9); een echocardiografisch onderzoek werd gead-



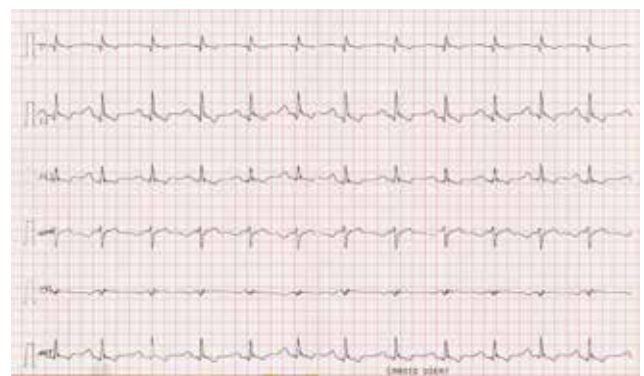**Figuur 4.** Aanwezigheid van een milde linkeratriumdilatatie (dwarse doorsnede linkerhartbasis) tijdens het eerste echocardiografisch onderzoek.



**Figuur 5.** Aanwezigheid van een milde linkeratriumdilatatie (overlangse doorsnede vier-kamerbeeld) tijdens het eerste echocardiografisch onderzoek.



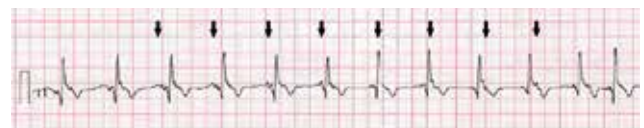**Figuur 6.** Het ECG afgenomen tijdens de eerste consultatie toont een hartfrequentie van 210 bpm, normaal uitzijende QRS-complexen en moeilijk te identificeren P-golven.



**Figuur 7.** ECG met een sinusritme met een eerstegraad-AV-blok en een hartfrequentie van 140 bpm.

visieerd. Er werden geen afwijkingen in de pulmonaire vasculatuur opgemerkt die indicatief konden zijn voor congestie. De grootte van het linkeratrium was tevens normaal. De slokdarm vertoonde evenmin afwijkingen. Door deze radiografische bevindingen konden de tachypneu en het kokhalzen dus niet verklaard worden. De vena cava caudalis kon niet worden beoordeeld op deze opnames.

Het echocardiografisch onderzoek toonde een milde linkeratriumdilatatie aan met een LA/Ao ratio van 1,6 (normaal <1,5) (Figuur 4 en 5; Tabel 1). Het rechteratrium was tevens vergroot en de rechterventrikel prominent. De “fractional shorting” (FS) was matig (Gugjoo et al., 2014). De linkerventriekeldiameter in diastole viel boven het rassetificke referentieinterval voor de labrador-retriever en de systolische diameter was hoog normaal (Gugjoo et al., 2014). De volumes van het linkerventrikel gemeten met de Simpson-methode en wanddiktes gemeten met de M-mode vielen binnen het referentiebereik (Gerlach en Wess, 2009; Gugjoo et al., 2014). Er was een milde regurgitatie ter hoogte van de tricuspidalisklep en van de mitralisklep, wat de matige hartruis kon verklaren.



**Figuur 8.** ECG met een hartfrequentie van 170-180 bpm. Detail met FJT en IAVD met synchronisatie type I; de P-golf beweegt heen en weer in het QRS-complex (pijlen). Dit ECG is afgenomen 13 weken na initiële presentatie. De hond werd in die periode behandeld met digoxine 0,22 mg/m<sup>2</sup> q12u en sotalolol 0,6 mg/kg q12u.

De ejectiefractie op basis van de LV-volumes bedroeg 32%, de “E-point-septal separation” (EPSS) bedroeg 7,8 en de sfericiteitsindex 1,09. Als differentiaaldiagnosen voor deze bevindingen komen in aanmerking: beginnende primaire dilatorische cardiomyopathie, secundaire dilatorische cardiomyopathie, beide met secundaire mitralisklepinsufficiëntie of mitralisklepdegeneratie in een vroege “stage B2” volgens de ACVIM-classificatie. Na het echocardiografisch onderzoek werd het abdomen eveneens kortstondig gescand. De lever en levervenen leken subjectief vergroot en er was een zeer milde hoeveelheid abdominale effusie aanwezig.



Het ECG toonde tachycardie met een hartfrequentie van 210 bpm (Figuur 6). De QRS-complexen hadden een supraventriculair uitzicht en er was geen duidelijk zichtbare P-golf waar te nemen, waardoor initieel werd gedacht aan AF. Het ritme was hiervoor echter te regelmatig en bovendien was er bij nadere inspectie een vermoeden van P-golven in afleiding II en aVL.

Het bloedonderzoek inclusief ionogram gaf geen significante afwijkingen weer. Omwille van de mogelijkheid van myocarditis werd het cardiaal troponine-I bepaald, die zeer mild verhoogd was met een waarde van 0,11 ng/ml (>0,08 ng/ml).

Naar aanleiding van het initiële vermoeden van primaire of secundaire cardiomyopathie of beginnende mitralisklependocardiose met AF werd voor de SVT een behandeling opgestart met digoxine (Lanoxin, Aspen Pharma, Ierland; 0,22 mg/m<sup>2</sup> q12u) en omwille van de milde cardiomegalie en de systolische dysfunctie werd pimobendan (Vetmedin, Boehringer Ingelheim, Duitsland; 0,25 mg/kg q12u) toegediend. Een lage dosis furosemide (Furosemide EG, Eurogenerics, België; 1,2 mg/kg q12u), benazepril en spironolactone (Cardalis, Ceva, België; 0,3 mg/kg en 2,5 mg/kg q24u) werden toegevoegd omwille van mogelijk beginnend rechter congestief hartfalen, alhoewel deze diagnose op dat moment niet vaststond en eerder preventief werd opgestart. Eén week na het opstarten van de digoxinebehandeling werd de digoxinespiegel gecontroleerd aangaande de nauwe toxisch-therapeutische marge. Deze spiegel werd normaal bevonden en er werd atenolol (Atenolol EG, Eurogenerics, België) toegevoegd. Deze werd geleidelijk opgebouwd tot een dosis van 0,4 mg/kg q12u om de hartfrequentie beter onder controle te krijgen omdat de tachycardie (170-240 bpm) tijdens de digoxinemonotherapie nog altijd aanwezig was.

Na telefonisch overleg met de eigenaar werd de toediening van atenolol stopgezet omdat de hond er

neveneffecten van ondervond, waaronder zwakte en lethargie. Na het stopzetten verdwenen deze klachten en werd een lage dosis sotalol (Sotalol Sandoz, Sandoz, België; 0,6 mg/kg q12u) opgestart ter vervanging van atenolol. De hartslag was zowel thuis als tijdens auscultatie en bij het ECG op consultatie rond de 150 bpm. Een echocardiografische controle gaf een normale grootte van het linkeratrium aan als ook linkerventrikeldiameters die binnen de referentiewaarden vielen (Tabel 1). De FS bedroeg 36% en was dus genormaliseerd (Gugjoo et al., 2014). De regurgitatie ter hoogte van de mitralisklep was onveranderd. Daar er verbeteringen werden waargenomen ten opzichte van de vorige echocardiografie werd de toediening van furosemide en pimobendan geleidelijk afgebouwd.

Dertien weken na initiële presentatie werden zowel een echocardiografische als ECG-controle en een nieuw bloedonderzoek uitgevoerd. Na de laatste consultatie werden geen klachten opgemerkt en maakte de hond het goed. De medicatie was digoxine 0,22 mg/m<sup>2</sup> q12u en sotalol 0,6 mg/kg q12u. Bij het lichamelijk onderzoek waren er geen afwijkingen, behalve de gekende hartruis. De hartfrequentie bedroeg initieel ongeveer 130 bpm. Op het hematologisch, biochemisch en ionografisch onderzoek waren er geen afwijkingen aanwezig. Op het echocardiografisch onderzoek vielen alle parameters binnen de normaalwaarden; de grootte van het linkeratrium was echter wat toegenomen (Tabel 1). De mitralisklepinsufficiëntie werd als mild tot matig beoordeeld met een normale drukgraad. De tricuspidalisklepinsufficiëntie was onveranderd. Tijdens dit controlebezoek werden meerdere ECGs afgenomen, waarbij in het eerste ECG een sinusritme (SR) met een eerstegraad-AV-blok en een hartfrequentie van 140 bpm aanwezig waren (Figuur 7). Bij de daaropvolgende ECGs was er een SVT (met een gemiddelde frequentie van 172-188 bpm) aanwezig met IAVD type I (Figuur 8). Het feit dat er op dat moment intermitterend een sinusritme aanwezig was,

**Tabel 1. Evolutie van enkele echocardiografische parameters.**

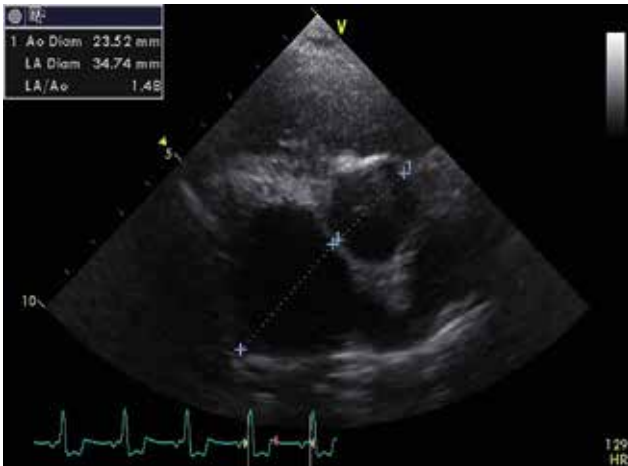Echocardiografisch onderzoek	1 (T0)	2 (4w)	3 (13w)	4 (52w)	Ref.
Grootte linkeratrium (mm) <sup>1</sup>	37,2	28,7	30,7	30,5	19,3-25,1
LA/Ao ratio	1,6	1,3	1,5	1,5	<1,5
Linkerventrikel diastolische diameter (mm) <sup>1</sup>	49,2	44,2	45,1	43,1	29,4-45,3
Linkerventrikel systolische diameter (mm) <sup>1</sup>	35,3	28,1	33,1	29,0	14,5-36,8
Linkerventrikelvolume in diastole (Simpson's method of discs) (mL/m <sup>2</sup> ) <sup>2</sup>	43,8	50,5	57,4	54,8	<100
Linkerventrikelvolume in systole (Simpson's method of discs) (mL/m <sup>2</sup> ) <sup>2</sup>	30,6	28,6	32,0	29,0	<53
FS (%) <sup>1</sup>	22,6	36,4	26,5	33	18,8-49,7

<sup>1</sup>Uit: Gugjoo et al., 2014.

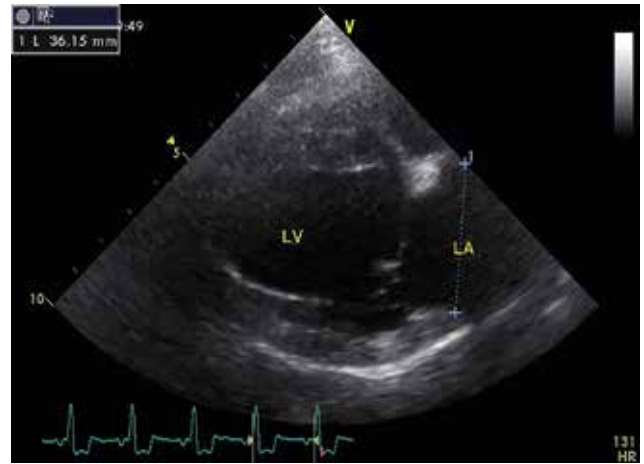
<sup>2</sup>Naar: Gerlach en Wess, niet-publiceerde data (2009). Referentiewaarden gebaseerd op een studie bij 300 gezonde honden van verschillende rassen, gezien er geen rasspecifieke referentiewaarden bestaan voor de labrador-retriever.

T0: tijdstip van aanbieden; 4w, 13w, 52w: aantal weken na initiële presentatie; Ref.: referentiewaarden





**Figuur 9.** Echocardiografisch controleonderzoek met normalisatie van de linkeratriumgrootte (dwarse doorsnede linkerhartbasis) 52 weken na initiële presentatie.



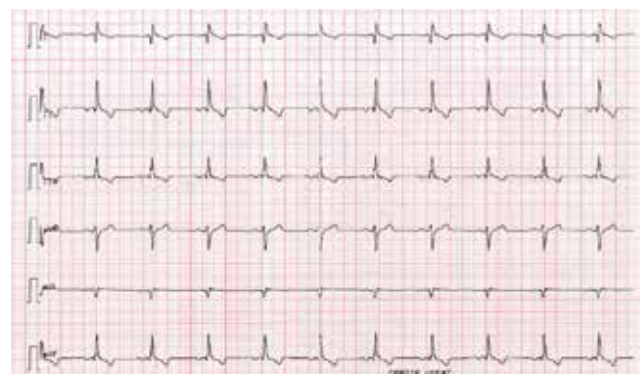**Figuur 10.** Echocardiografisch controleonderzoek met normalisatie van de linkeratriumgrootte (overlansge doorsnede vier-kamerbeeld) 52 weken na initiële presentatie.

afwisselend met een supraventriculaire tachycardie en IAVD, leidde tot een vergelijking met het eerste ECG. Er werd vastgesteld dat de initiële diagnose van AF niet correct was, gezien de RR-intervallen te regelmatig waren. Mogelijke differentiaaldiagnosen die voor het initiële ECG toen in acht werden genomen, waren OAVRT geassocieerd met een “accessory pathway”, FJT en FAT. De meest waarschijnlijke oorzaken van de IAVD en SVT bij deze controle waren FJT met IAVD, beschreven bij de Labrador-retriever of digoxinetoxiciteit, wat IAVD met een junctionaal ritme kan veroorzaken (Bonagura en Muir, 1992; Perego et al., 2012). Omdat de hartfrequentie intermitterend nog zeer hoog was en omwille van de mogelijkheid van digoxinetoxiciteit werd besloten om de antiaritmische therapie te wijzigen. De toediening van digoxine en sotalol werd afgebouwd en uiteindelijk gestopt. De hond werd gehospitaliseerd om de hartfrequentie te monitoren. Er werd overgeschakeld op diltiazem (Progor, SMB, België; 4,2mg/kg q12u) en pimobendan (0,25mg/kg q12u). Na de overschakeling op diltiazem werd op het ECG een SR met een hartfrequentie van 140-160 bpm waargenomen en de hond werd na drie dagen ontslagen.

Anderhalve week na de hospitalisatie werd een holter-monitoring uitgevoerd. In totaal werd er 23 uur gemonitord, waarbij de hoogst gemeten hartfrequentie 273 bpm was tijdens het eten en de laagste hartfrequentie 54 bpm tijdens de slaap. De gemiddelde hartfrequentie was 130 bpm in een sinusritme, hoewel er periodes aanwezig waren met supraventriculaire tachycardie, vermoedelijk FJT, met fasen van AV-dissociatie. Er werden geen significante pauzes, bradycardiën of ventriculaire ritmestoornissen waargenomen. Het resultaat van deze holter-monitoring bevestigde dat de tachycardie met de huidige medicatie over het algemeen goed onder controle was.

Sindsdien bleef de hond symptomeloos op alle volgende controleonderzoeken. De hartfrequentie werd thuis door de eigenaar regelmatig opgevolgd en

bleef stabiel rond 120 bpm. Ook op het lichamelijk onderzoek was de hartfrequentie rond 120 bpm en waren er geen afwijkingen aanwezig buiten de reeds gekende hartruis. Op het echografisch controleonderzoek waren de afmetingen stabiel gebleven (Figuur 9 en 10; Tabel 1). De grootte van het linkeratrium was op de grens van normaal. De mitralisklep was nodulair verdikt, maar de bijbehorende regurgitatie was stabiel gebleven ten opzichte van de vorige keren en werd als een myxomateuze mitralisklepdegeneratie ACVIM stage B1 gestageerd. Zolang de hond geen klachten vertoonde, werden er drie- tot zesmaandelijkse controleonderzoeken ingepland. De ECGs bij opvolging toonden dat de hartfrequentie onder controle was (gemiddeld 120-140 bpm), al was dit niet altijd een sinusritme, zoals weergegeven op het ECG in Figuur 11, waar negatieve p-golven waar te nemen zijn. Cardiologisch bleef de hond stabiel, maar 16 maanden na de eerste presentatie werd ze aangeboden



**Figuur 11.** ECG-controle tijdens de behandeling met diltiazem en pimobendan 52 weken na initiële presentatie. De hartfrequentie schommelt rond 120 bpm in een regelmatig ritme. Elk QRS-complex wordt voorafgegaan door een P-golf waarmee ze in relatie staat. De P-golf is negatief in afleiding II, III en aVF en dus niet afkomstig uit de sinusknoop.

op de dienst Endocrinologie van de Faculteit Diergeneeskunde (UGent) met klachten van polydipsie, vermageren en een slechte vachtkwaliteit. Daar werd een diagnose van hypercortisolisme gesteld, vermoedelijk ten gevolge van een bilaterale bijnierneoplasie. Trilostane (Vetoryl, Dechra, Verenigd Koninkrijk; 1,2 mg/kg q12u) werd opgestart waarna de symptomen verbeterden. Vierendertig maanden na initiële presentatie was de hond cardiologisch stabiel.

## DISCUSSIE

In deze casus wordt een SVT met IAVD bij een vrouwelijke labrador-retriever van middelbare leeftijd beschreven met TICM als gevolg. De hond werd aangeboden omwille van klachten van tachypneu, abdominale distensie en kokhalzen. Op lichamelijk onderzoek werden tachypneu, tachycardie, een systolische hartuis met punctum maximum links apicaal en een intensiteit van 3/6, zwak geslagen polsen en een zeer milde hoeveelheid abdominale effusie vastgesteld. Omdat aan een cardiologisch probleem werd gedacht, werden een radiografie van de thorax en een echocardiografie uitgevoerd, waarbij een milde linkeratrium- en ventrikeldilatatie, een rechteratriumdilatatie en een milde systolische dysfunctie werden vastgesteld. Differentiaal diagnostisch kwamen hiervoor een beginnende primaire DCM, een tachycardie-geïnduceerde DCM of een beginnende mitralisendocardiose AC-VIM stage B2 in aanmerking.

Voor het kokhalzen werd er geen verklaring gevonden. Het was ook onduidelijk of er wel degelijk sprake was van kokhalzen, vermits de auteurs zich enkel konden baseren op de beschrijving van de eigenaar. Mogelijke oorzaken van kokhalzen zijn sinusproblemen, morfologische of functionele problemen van de farynx, aandoeningen van de bovenste of onderste luchtwegen of van de slokdarm (Kook, 2017). Een groot deel van de luchtwegen en de slokdarm was zichtbaar op radiografie; er werden geen abnormaliteiten opgemerkt. Omdat er geen problemen aanwezig waren met eten of drinken en omdat de focus bij het aanbieden lag op de aanwezigheid van een uitgesproken tachycardie en het vermoeden van een cardiaal probleem, werd deze klacht niet verder opgevolgd. De klacht van kokhalzen verdween volgens de eigenaar na het instellen van de antiaritmische therapie.

Grote en reuzenrassen zijn gepredisponeerd voor het ontwikkelen van primaire idiopathische DCM die vaak tot uiting komt rond de middelbare leeftijd, waardoor het onderscheid tussen primaire DCM en TICM moeilijk wordt (Foster et al., 2006). In deze casus waren de echocardiografische veranderingen echter vrij subtiel voor een primaire DCM; derhalve moesten secundaire oorzaken voor een echocardiografisch DCM-beeld dan ook in acht worden genomen. Mogelijke oorzaken van secundaire DCM zijn myocarditis, nutritionele deficiënties van taurine of L-carnitine, endocriene ziekten, zoals hypothyroïdie, tachycardieën

en intoxicaties (Philips en Harkin, 2003; Sanderson, 2006; Ware, 2013b; Janus et al., 2014; Ware, 2014; Gallay-Lepoutre et al., 2016). Het bloedonderzoek gaf hematologisch, biochemisch en in het ionogram geen afwijkingen weer. T4 werd niet bepaald. De mild verhoogde serumcardiaal-troponine-I-concentratie was niet meteen indicatief voor acute myocarditis, een andere mogelijke oorzaak van cardiomyopathie.

Om de aanwezige tachycardie verder te onderzoeken werd een ECG afgenomen. Bij het eerste ECG, dat SVT aantoonde, werd door de zeer onduidelijke P-golven in afleiding II aanvankelijk gedacht aan AF. AF is een van de meest voorkomende SVTs bij middelgrote tot grote honden in combinatie met DCM (Ware, 2013b). Deze aritmie wordt bij de hond gekenmerkt door QRS-complexen met een supraventriculaire morfologie, de afwezigheid van P-golven, de mogelijke aanwezigheid van fibrillatiegolven, een onregelmatig R-R interval en een gemiddelde frequentie van 130-230 bpm. Daardoor stond AF vooraan in de differentiaaldiagnose. Het R-R-interval was echter te regelmatig; bovendien waren er mogelijk p-golven te herkennen, wat atriumfibrillatie zeer onwaarschijnlijk maakte (Ware, 2013a; Pariaut et al., 2014) (Figuur 6). Andere SVTs met een regelmatig ritme zijn AFL met regelmatige geleiding (dus zonder variabele block), OAVRT geassocieerd met een “accessory pathway”, FJT en soms FAT. Methoden om op een oppervlakte-ECG een onderscheid te maken tussen deze verschillende soorten SVTs zijn het vergelijken van hartfrequentie en regelmaat, de identificatie van atriale activatie (p'-golven, f-golven, F-golven) en het bepalen van de relatie tussen p'-golf en R-golf. Er waren meerdere differentiaaldiagnosen mogelijk voor het eerste ECG: als de p'-golf in het ST-segment verborgen zat, dan ging het om een korte R-P'-interval-tachycardie en waren FAT en OAVRT de meest waarschijnlijke differentiaaldiagnosen. Als ervan uit werd gegaan dat de p'-golf in AVR een positieve deflectie leek te hebben, dan was OAVRT de meest waarschijnlijke differentiaaldiagnose. Dit paste ook het beste bij de waargenomen hartfrequentie, gezien FAT ( $278 \pm 62$ /min) meestal sneller is dan OAVRT ( $229 \pm 42$ ) (Santilli et al., 2008). Zoals bij OAVRT is er bij FJT ook retrograde concentrische activatie van het atrium en zijn er zogenaamde pseudo-S-golven aanwezig, die ook herkenbaar zouden kunnen geweest zijn op het initiële ECG (Perego et al., 2012). Op basis van dit eerste oppervlakte-ECG leken OAVRT, FJT en FAT de meest waarschijnlijke differentiaaldiagnosen.

Bij een van de volgende ECG-controles werd echter IAVD opgemerkt. IAVD werd eerder al beschreven in combinatie met FJT specifiek bij labrador-retrievers (Perego et al., 2012). Echter, op het moment dat in de voorliggende casus IAVD werd vastgesteld, kreeg de hond digoxine en sotalol toegediend. IAVD met een versneld junctionaal ritme werd reeds eerder gedocumenteerd bij digoxinetoxiciteit (Bonagura en Muir, 1992). Na het instellen van de therapie met diltiazem werden negatieve p-golven vastgesteld in afleiding II,

III en aVF voorafgaand aan de QRS-complexen (gemiddelde HF 120/min) (Figuur 11). Normaal gezien zijn p-golven positief als de prikkelgeleiding uit de sinusknoop komt. Gezien negatieve p-golven geen sinus p-golven zijn, kunnen zij beschouwd worden als p'-golven. Deze komen vóór het QRS-complex voor, met in dit geval een lang RP'-interval. SVT die deze ECG-karakteristieken kunnen verklaren zijn FAT vanuit een laag gelegen regio uit het rechteratrium, waarbij de ventriculaire "response rate" bij de hond van de huidige casus toen vertraagd werd door de behandeling met diltiazem, of een andere lange RP'-tachycardie, zoals permanente junctionale reciproke tachycardie (PJRT) of OAVRT met verlengde ventriculo-atriale conductietijd (Santilli et al., 2008, 2013).

Deze casus illustreert de moeilijkheid om SVTs te differentiëren en te diagnosticeren aan de hand van een oppervlakte-ECG en toont aan dat er nood is aan meer centra waar elektrofysiologisch onderzoek van het hart kan uitgevoerd worden bij de hond. Zonder elektrofysiologisch onderzoek met een intracardiaal gemeten ECG blijven er meestal meerdere differentiaaldiagnosen bestaan voor complexere SVTs en is een definitieve diagnose vaak onmogelijk (Perego et al., 2012).

Voor de behandeling van de vermoedelijke AF werd initieel digoxine opgestart om de hartfrequentie te verlagen; dit is een zogenaamde "rate control"-strategie (Gelzer et al., 2009; Pariaut et al., 2014). Gezien de hartfrequentie middels deze enkelvoudige therapie onvoldoende onder controle was, werd een bijkomende behandeling met atenolol opgestart (Wright, 2015). De hond ondervond echter nevenwerkingen van deze  $\beta$ -blokker, waardoor op een lage dosis sotalol werd overgeschakeld. Sotalol is een Vaughn-Williams-klasse III anti-aritmicum en komt voor in een racemisch mengsel van D en L-sotalol waarvan de L-isomeer ook een  $\beta$ -blockade-effect heeft (Kato et al., 1986). Sotalol wordt meestal niet gebruikt als monotherapie bij een "rate control"-strategie voor atriumfibrillatie, maar werd hier gekozen ter vervanging van atenolol in combinatie met digoxine. Bij ECG-controle na de behandeling met digoxine en sotalol werd aangetoond dat de hartfrequentie nog steeds onvoldoende onder controle was op het moment dat IAVD werd gediagnosticeerd. Digoxinetoxiciteit is bovendien een mogelijke oorzaak van IAVD met een junctionale tachycardie (Bonagura en Muir, 1992). Antiaritmica die momenteel worden aangeraden voor FJT voor conversie naar en behoud van sinusritme bij de hond zijn atenolol en diltiazem (Pariaut et al., 2014). Zowel atenolol en diltiazem heeft een negatief chronotroop effect door een vertraagde AV-nodale conductie, respectievelijk door een  $\beta_1$ -blokkade en een blokkade van de calciumkanalen. Gezien de neveneffecten die de hond in de huidige casus ondervond van atenolol, was diltiazem de enige overblijvende keuze voor medicamenteuze behandeling. Door het tijdig instellen van een adequate antiaritmische behandeling kan een

TICM volledig reversibel zijn. Verbetering van de systolische functie wordt het vroegst één week na het instellen van een therapie gezien. De volledige normalisering van de systolische functie wordt meestal na vier tot zes weken therapie bekomen (Khasnis et al., 2005; Gopinathannair et al., 2015). Als er door de remodelering van het hart echter geen volledig herstel mogelijk is, blijft een ondersteunende medicamenteuze behandeling nodig om de hartfunctie te ondersteunen en hartfalen uit te stellen (Santilli et al., 2014; Gopinathannair et al., 2015).

Naast controle van de hartfrequentie werd in deze casus een behandeling met pimobendan opgestart om eventuele progressieve systolische dysfunctie gelinkt aan de IAVD te voorkomen. IAVD is immers een niet-fysiologisch verschijnsel, waarbij de atria contraheren tegen gesloten AV-kleppen, wat op lange termijn mogelijk schadelijk kan zijn (Perego et al., 2012). Dankzij het goed onder controle houden van de hartfrequentie middels de medicamenteuze toediening van diltiazem en pimobendan toonde de hond van deze casus geen klachten meer en waren de echocardiografische afmetingen genormaliseerd, wat illustreert dat de hond initieel hoogstwaarschijnlijk TICM heeft gehad. Het effect van diltiazem en het effect van pimobendan op herstel van het hart van de hond in huidige casus waren helaas niet van elkaar te onderscheiden. Wanneer de hond initieel een primaire DCM zou gehad hebben, kon er toen (34 maanden na de eerste presentatie) echocardiografisch echter een verslechtering verwacht worden, zelfs wanneer behandeld zou zijn geweest met pimobendan. Hierdoor werd TICM in deze casus meer waarschijnlijk. Er bleef echter een milde mitralis- en tricuspidaal-klepsufficiëntie aanwezig en de hond ontwikkelde ook een milde verdikking van de mitralisklep, passend bij ouderdomgerelateerde myxomateuze klepdegeneratie. Sinds het instellen van de laatste therapie werd de hond drie- tot zesmaandelijks opgevolgd en was ze tot op het moment van schrijven cardiologisch stabiel.

## CONCLUSIE

In deze casus wordt een zeldzame hartritmestoornis, i.e. IAVD geassocieerd met supraventriculaire tachycardie bij een labrador-retriever beschreven. Uit de casus kan besloten worden dat ondanks het uitzicht van DCM op echografie en een aanwezige aritmie niet direct geconcludeerd mag worden dat er sprake is van primaire idiopathische DCM. Omdat DCM en TICM echocardiografisch niet van elkaar onderscheiden kunnen worden, kan het onderscheid soms pas gemaakt worden tijdens een adequate behandeling van de onderliggende aritmie. Het tijdig stellen van de juiste diagnose is bij TICM echter van doorslaggevend belang omdat een (partiële) normalisatie van het hart kan worden bekomen mits de juiste antiaritmische behandeling.



## LITERATUUR

- Bonagura J.D., Muir W.W. (1992). Anti-arrhythmic treatment. In: Tilly L.P. (editor). *Essentials of Canine and Feline Electrocardiography*. Third edition, Lea and Febiger, Londen, 320-364.
- DeFrancesco T.C. (2013). Management of cardiac emergencies in small animals. *Veterinary Clinics of North America: Small Animal Practice* 43 (4), 817-842.
- Gallay-Lepoutre J., Bélanger M.C., Nadeau M.E. (2016). Prospective evaluation of doppler echocardiography, tissue doppler imaging and biomarkers measurement for the detection of doxorubicin-induced cardiotoxicity in dogs: a pilot study. *Research in Veterinary Science* 105, 153-159.
- Gelzer A.R., Kraus M.S., Rishniw M., Moise N.S., Pariaut R., Jesty S.A., Hemsley S.A. (2009). Combinatino therapy with digoxin and diltiazem controls ventricular rate in chronic atrial fibrillation in dogs better than digoxin or diltiazem monotherapy: a randomized crossover study in 18 dogs. *Journal of Veterinary Internal Medicine* 23 (3), 499-508.
- Gopinathannair R., Etheridge S.P., Marhlinski F.E., Spinale F.G., Lakkireddy D., Olshansky B. (2015). Arrhythmia-induced cardiomyopathies: mechanisms, recognition and management. *Journal of the American College of Cardiology* 66 (15), 1714-1728.
- Gupta S., Figueredo V.M. (2014). Tachycardia mediated cardiomyopathy: pathophysiology, mechanisms, clinical features and management. *International Journal of Cardiology* 172 (1), 40-46.
- Kook P.H. (2017). Gaggng. In: Ettinger S.J., Feldman E.C., Côté E. (editors). *Textbook of Veterinary Internal Medicine*. Eighth edition, Elsevier Mosby, St. Louis, 152-154.
- Foster S.F., Hunt G.B., Thomas S.P., Ross D.L., Pearson M.R.B., Malik R. (2006). Tachycardia-induced cardiomyopathy in a young Boxer dog with supraventricular tachycardia due to an acesyory pathway. *Australian Veterinary Journal* 84 (9), 326-331.
- Gerlach P.A., Wess G. (2009). Unpublished data.
- Janus I., Noszczyk-Nowak A., Nowaak M., Cepiel A., Ciaputa R., Paslawska U., Dziegiel P., Jablonska K. (2014). Myocarditis in dogs: etiology, clinical and histopathological features (11 cases: 2007-2013). *Irish Veterinary Journal* 67 (1), 1-8.
- Kato R., Ikeda N., Yabek S.M., Kannan R., Singh B.N. (1986). Elektrophysiological effects of the levo ad dextro-rotatory isomers of sotalol in isolated cardiac muscle and their in vivo pharmacokinetics. *Journal of the American College of Cardiology* 7 (1), 116-125.
- Khasnis A., Jongnarangsin K., Abela G., Veerareddy S., Reddy V., Thakur R. (2005). Tachycardia-induced cardiomyopathy: a review of literature. *Pacing and Clinical Electrophysiology* 28 (7), 710-721.
- Menaut P., Bélanger M.C., Beauchamp G., Ponzio N.M., Moise N.S. (2005). Atrial fibrillatino in dogs with and without structural of functional cardiac disease: a retrospective study of 109 cases. *Journal of Veterinary Cardiology* 7 (2), 75-83.
- Moe G.W., Howard R.J., Grima E.A., Armstrong P.W. (1995). How does intermittent pacing modify the response to rapid ventricular pacing in experimental heart failure? *Journal of Cardiac Failure* 1 (3), 223-228.
- Oyama M.A., Reynolds C.A. (2014). Ventricular arrhythmias in dogs. In: Bonagura J.D., Twedt D.C. (editors). *Kirk's Current Veterinary Therapy XV*. First edition, Elsevier Saunders, St. Louis, 745-747.
- Pariaut R., Santilli R.A., Moise N.S. (2014). Supraventricular tachyarrhythmias in dogs. In: Bonagura J.D., Twedt D.C. (editors). *Kirk's Current Veterinary Therapy XV*. First edition, Elsevier Saunders, St. Louis, 737-744.
- Perego M., Ramera S., Santilli R.A. (2012). Isorhythmic atrioventricular dissociation in labrador retrievers. *Journal of Veterinary Internal Medicine* 26 (2), 320-325.
- Philips D.E., Harkin K.R. (2003). Hypothyroidism and myocardial failure in two great Danes. *Journal of the American Animal Hospital Association* 39 (2), 133-137.
- Riegger A.J.G., Liebau G. (1981). The renin-angiotensin-aldosterone system, antidiuretic hormone and sympathetic nerve activity in an experimental model of congestive heart failure in the dog. *Clinical Science* 62 (5), 465-469.
- Sanderson S.L. (2006). Taurine and carnitine in canine cardiomyopathy. *Veterinary Clinics of North America: Small Animal Practice* 36 (6), 1325-1343.
- Santilli R.A. (2000). Orthodromic incessant atrioventricular reciprocating tachycardia in a dog. *Journal of Veterinary Cardiology* 2 (1), 25-29.
- Santilli R.A., Perego M., Crosara S., Gardini F., Bellino C., Moretti P., Spadacini G. (2008). Utility of 12-lead electrocardiogram for differentiating paroxysmal supraventricular tachycardias in dogs. *Journal of Veterinary Internal Medicine* 22 (4), 915-923.
- Santilli R.A., Ramera L., Perego M., Moretti P., Spadacini G. (2014). Radiofrequency catheter ablation of atypical atrial flutter in dogs. *Journal of Veterinary Cardiology* 16 (1), 9-17.
- Santilli R.A., Spadacini G., Moretti P., Perini A., Tarducci A., Crosara S., Salerno-Uriarte, J.A. (2006). Radiofrequency catheter ablation of concealed accessory pathways in two dogs with symptomatic atrioventricular reciprocating tachycardia. *Journal of Veterinary Cardiology* 8, 157-165.
- Shinbane J.S., Wood M.A., Jensen D.N., Ellenbogen K.A., Fitzpatrick A.P., Scheinman M.M. (1997). Tachycardia-induced cardiomyopathy: a review of animal models and clinical studies. *Journal of the American College of Cardiology* 29 (4), 709-915.
- Umama E., Solares C.A., Alpert M.A. (2003). Tachycardia-induced cardiomyopathy. *The American Journal of Medicine* 114 (1), 51-55.
- Ware W.A. (2013a). Overview of electrocardiography. *Cardiovascular Disease in Small Animal Medicine*. Fourth edition, Manson Publishing, Londen, 47-67.
- Ware W.A. (2013b). Myocardial diseases of the dog. *Cardiovascular Disease in Small Animal Medicine*. Fourth edition, Manson Publishing, Londen, 280-292.
- Ware W.A. (2014). Myocardial Disease of the Dog. In: Nelson R.W., Couto C.G. (editors). *Small Animal Internal Medicine*. Fifth edition, Elsevier Mosby, St. Louis, 130-144.
- Wess G., Mäurer J., Simak J., Hartmann K. (2010). Use of Simpson's method of disc to detect early echocardiographic changes in Doberman Pinschers with dilated cardiomyopathy. *Journal of Veterinary Internal Medicine* 24 (5), 1069-1076.
- Wright K.N., Atkins C.E., Kanter R. (1996). Supraventricular tachycardia in four young dogs. *Journal of the American Veterinary Medical Association* 208 (1), 75-80.
- Wright, K.N. (2015). Supraventricular tachyarrhythmias. In: Silverstein D.C., Hopper K. (editors). *Critical Care Medicine*. Second edition, Elsevier Saunders, St. Louis, 250-254.
- Zupan I., Rakovec P., Budihna N., Breclj A., Koželj M. (1996). Tachycardia induced cardiomyopathy in dogs; relation between chronic supraventricular and chronic ventricular tachycardia. *International Journal of Cardiology* 56 (1), 75-81.



Gent, 7 Juli 1947.

Aan den Heer Beheerder der Universiteit te Gent.

Hooggeachte Heer Beheerder,

De steunverlening aan de Universiteit te Utrecht in 1945, uitgaande van de Vlaamse dierenartsen, die daartoe een som geld hebben bijeengebracht, en uitgevoerd door de Veeartsenijschool te Gent, heeft een overschot opgebracht van 1835,60 fr.

De ondergetekenden, de uitvoerende leden van het comité, hebben gemeend thans een geschikte bestemming voor deze som te hebben gevonden in de kas van het Vlaamsch Diergeneeskundig Tijdschrift, dat hiermee enigszins geholpen zou zijn.

In vertrouwen, dat U met deze regeling instemt, zullen wij dit bedrag aan het Tijdschrift ~~overmaken~~ overmaken, en wij betuigen U nog onzen dank voor uw welwillende medewerking.

Met de meeste hoogachting tekenen wij,

L. Geurden,

M. Vandeplassche,

J. de Regt,

Gent, 7 Juli 1947.

## Semen donation and establishment of an open canine semen bank: a novel tool to prevent inbreeding in pedigree dogs

*Spermadonatie en de start van een open spermabank voor honden: een nieuw hulpmiddel om inteelt bij rashonden te voorkomen*

<sup>1</sup>G. Domain, <sup>1</sup>E. Wydooghe, <sup>2</sup>B.J.G. Broeckx, <sup>3</sup>M. Hoogewijs, <sup>1</sup>A. Van Soom

<sup>1</sup>Department of Reproduction, Obstetrics and Herd Health,

<sup>2</sup>Department of Nutrition, Genetics and Ethology,

Faculty of Veterinary Medicine, Ghent University, Salisburylaan 133, Merelbeke, Belgium

<sup>3</sup>Knocke Arabians, Hazegrasstraat 141, Knokke, Belgium

Voorplanting.gezelschapsdieren@ugent.be

### ABSTRACT

At present, only 5% of pedigree dogs is being used for breeding. To increase the number of breeding dogs, one solution could be to start a canine semen bank based on the principle of semen donation, like in humans. Many dog owners have no desire to become dog breeders but are willing to preserve the genetic material of their dog, if offered this possibility. However, not all canine ejaculates are suitable for cryopreservation as the initial quality may differ and the resistance of sperm cells to survive the freezing procedure is highly variable. In order to freeze the semen of as many male dogs as possible, it is important to optimize and individualize the cryopreservation protocol per ejaculate. Practically, frozen semen can be stored in the CanIFreeze-semen bank or in veterinary practices adjacent to the owner of the bitch and can be used for insemination at a later time.

### SAMENVATTING

Slechts 5 % van de rashonden wordt momenteel gebruikt voor de fok. Om dit aantal te verhogen, zou het opstarten van een spermabank voor honden, die gebaseerd is op donatie van sperma zoals bij de mens, een mogelijke oplossing kunnen bieden. Veel eigenaars willen niet per se met hun hond fokken, maar willen wel het genetisch materiaal van hun reu bewaren, indien deze mogelijkheid aangeboden wordt. Niet alle ejaculaten zijn geschikt om ingevroren te worden, omdat de kwaliteit van het staal kan verschillen en omdat de weerstand van het sperma om het invriesproces te overleven sterk variabel is tussen honden onderling. Om sperma van zoveel mogelijk verschillende reuen te kunnen invriezen, is het belangrijk om het invriesproces te verbeteren en te individualiseren. Het ingevroren sperma kan bewaard worden in de CanIFreeze-spermabank of in dierenartspraktijken dichtbij bij de eigenaar van de teef om op een later tijdstip gebruikt te kunnen worden voor inseminatie.

### INTRODUCTION

Dogs are popular pets in Belgium. With a current Belgian canine population of 1.34 million, they are considered as a family member in one out of four Belgian households (<https://www.fediaf.org>). Unfortunately, dogs exhibit a high number of recognized genetic diseases (Mellersh, 2008). At present, more than

700 different inherited conditions are reported in that species (<https://omia.org/home/>). Although the estimates tend to vary a little bit, for about 50% of these diseases, the mode of inheritance is known, a third being monogenic with a majority being autosomal recessive (Patterson, 2000; Leroy et al., 2011; <https://omia.org/home/>). The dissemination of these genetic disorders is therefore highly associated with a loss of

genetic variation within a breed and is a major concern, especially in purebred dogs. Important contributors to the loss of genetic diversity are two major population bottlenecks events: domestication and breed formation. Dog breeds have been generated over several centuries by selecting and mating a (sometimes very) small number of dogs with particular physical and/or behavioral characteristics, which were different from the large canine population. The propagation of breed-specific phenotypic traits has contributed to the high level of homogeneity within a breed and the high level of heterogeneity between breeds (Farrell et al., 2015). Nowadays, the Fédération Cynologique Internationale (FCI) recognizes more than 400 dog breeds (Wijnrocx et al., 2016) but the 20 most popular breeds represent 72% of the total number of registrations, whereas the rarest 100 represent only 2% (Farrell et al., 2015). As such, most breeds are represented by a small and closed population with no or at best a very limited gene flow. For example, in Belgium, genetic diversity in purebred dogs is very low in about half of the 23 studied breeds (Wijnrocx et al., 2016). Aside from the two bottlenecks mentioned earlier, this poor genetic variation can also be explained by breeding practices that are commonly used. These breeding practices are the so-called popular sire effect, line breeding and close inbreeding (Leroy et al., 2010; Leroy et al., 2011). The popular sire effect is used to describe the intense use of some sires (mainly champion dogs) and is considered to be the main reason of dissemination of genetic disorders. In an attempt to counteract this, the FCI recommends that the number of offspring per sire should not exceed 5% of the number of puppies born in this breed during a five-year period. Line breeding represents the mating of two individuals not too closely related but having a common ancestor. In a study by Leroy et al. (2007), it has been shown that half of the French dog breeders commonly used line breeding. Finally, close inbreeding represents the mating of even more closely related relatives (sibling or sire-daughter) in order to fix a trait present in an individual. Overall, (partially) as a resultant of these breeding practices, only 5% of the dog population is used for reproduction on average (KMSH, personal communication, 2019).

Due to the combination of the aforementioned breeding practices and because of the incorrect interpretation of genetic tests, e.g. exclusion of carriers of mutations responsible for autosomal recessive mutations, many potential breeding dogs have been excluded from breeding and unintentionally, the effective population size has decreased. The inadvertent decrease of genetic diversity and the negative impact this has on canine health have recently become one of the top priorities of the Belgian Kennel Club (KMSH). To tackle this problem, the KMSH has adopted a novel approach, based on the combination of limiting the popular mating practices, increasing the number of breeding dogs as much as possible and an

increase of the international exchange of genetic material. The number of reproducers can be increased by registration of dogs without pedigree but with the appropriate phenotype (or even genotype) (Wang et al., 2017) or by semen donation. If owners of purebred dogs who have no breeding plans, donate the semen of their dog, these dogs can also contribute to the next generations and increase the effective population size. In both cases, the goal is to include as many dogs as possible in the breeding program because every dog is valuable. The exchange of genetic material between canine populations of different countries should also be increased, since it has proven to be beneficial, especially for breeds with small or medium (effective) population sizes. An important tool to achieve this is the use of artificial insemination (AI) of frozen semen. Unfortunately, the resistance of semen to withstand the freezing procedure is highly variable between dogs and sometimes even between ejaculates (Rota et al., 2005; Farstad, 2009). This process must therefore be optimized and individualized to allow successful freezing of the semen of as many breeding sires as possible. Individualization of semen freezing refers to the testing of different freezing protocols and the subsequent selection of the optimal freezing protocol for each individual dog.

To follow this novel vision on breeding, a large collaboration involving the departments of Small Animal Reproduction and the laboratory of Animal Genetics of Ghent University, together with specialist veterinarians and the KMSH has been initiated. The goal of this project is the development of a semen bank as a tool to increase the number of dogs used in reproduction. Furthermore, to maximize the number of stud dogs, it aims to improve the cryopreservation protocol of canine semen. In this article, the current cryopreservation process will shortly be described before detailing how semen donation and the improvement of cryopreservation can help to produce healthier dogs in the future.

## CRYOPRESERVATION

Semen cryopreservation is a process, in which spermatozoa are preserved by freezing at very low temperature (either at  $-196^{\circ}\text{C}$  in liquid nitrogen or in dry ice at  $-78.5^{\circ}\text{C}$ ). As in other domestic animals, this is the best technique to preserve the semen for a longer period of time (Alamo et al., 2005). Since Seager reported the first pregnancy in dogs following AI with frozen-thawed semen in 1969, cryopreservation of dog semen has experienced an increased interest and became more and more requested by breeders, owners and institutions, e.g. police, military, guiding dogs (Futino et al., 2010; Hollinshead et al., 2017). This interest has led to the establishment of private canine semen banks (Farstad, 2000; Kim et al., 2010). Long-term storage of semen from valuable males and

easier exchange of genetic material between populations at distant locations are the main advantages of semen cryopreservation (Axner et al., 2016). The preserved genetic material can be used even when the sire is no longer fertile, unavailable or deceased (Kutzler, 2005). Moreover, as in other types of artificial inseminations in dogs, the cryopreserved semen can be used to overcome behavioral incompatibility between the male and the female and to protect them against venereal diseases (Farstad, 2000; Schäfer-Somi et al., 2006).

The main downside of cryopreservation is that it affects the fertility of the semen as it leads to detrimental structural and functional changes in spermatozoa (Kim et al., 2010; Brito et al., 2017; Khan et al., 2017). These changes are triggered by stress and may affect the sperm cells at any step of the procedure: the technique of semen collection, the dilution rate, the type and composition of the extender, the cooling rate, the time and temperature of equilibration, the packing method and the rate and method of freezing and thawing (Alamo et al., 2005; Schäfer-Somi et al., 2006; Barbas et al., 2009). All together, these factors are the reason why only 50% of spermatozoa survive the cryopreservation process (Alhaider et al., 2008; Amidi et al., 2016). Understanding the causes of cryoinjury is a key factor to develop new cryopreservation techniques with the goal to improve the survival of sperm cells (Alhaider et al. 2008; Barbas et al., 2009).

### Semen collection and evaluation

The most common method to collect semen from a dog is by digital manipulation. Before collection, it is important to eliminate or minimize any distraction and/or anxiety. Indeed, in case of fear or pain, a complete erection of the penis and ejaculation may not be reached. Ideally, a bitch in oestrus (called teaser bitch) is present to increase the libido of the male and the likelihood of a successful collection. If no teaser bitch is available at the time of collection, vaginal swabs from bitches in oestrus presented for cycle follow-up and preserved in the freezer (-20°C) can be used. The pheromones present on the swabs can help to stimulate the dog. The digital manipulation of the penis starts with a vigorous massage at the level of the bulbus glandis until a partial erection develops (light engorgement of the bulbus glandis). Then, the prepuce is retracted caudally behind the bulbus glandis and a constant pressure behind the bulbus glandis is applied. Dog ejaculates consist of three fractions and only the second and third fractions are collected in plastic vials. The first and the third fractions originate from the prostate (the sole secondary gland in dogs) while the second fraction, also called the sperm-rich fraction, originates from the epididymis and contains the spermatozoa (Kutzler, 2005; Rijsselaere et al., 2011).

Immediately after collection, the second fraction is placed in a 37°C environment and analyzed macro-

scopically (volume, color, admixtures and homogeneity) and microscopically (motility, concentration, morphology and membrane integrity). The motility (both total and progressive) can be assessed subjectively under light microscope, on a pre-warmed glass slide, on a scale ranging from 0 to 100% or objectively by computer-assisted sperm analysis (CASA). The concentration can be evaluated after a 1:40 dilution and fixation in tap water or diluted formol, with the use of a counting chamber, e.g. Bürker or Thoma chamber, or with an automated sperm cell counter. The morphology and membrane integrity can be assessed using eosin-nigrosin staining. Alternatively, morphology can also be determined with a Diff-Quick staining (Rijsselaere et al., 2011).

### Semen extenders

Spermatozoa are the endpoint of the spermatogenesis and have particular anatomic and metabolic characteristics. They have little biosynthetic activity and depend mostly on their extracellular environment to stay alive (Barbas et al., 2009). The seminal plasma, consisting of the epididymal fluid and the prostatic fluid, plays essential roles in the survival of the sperm cells. It provides metabolic support, energy and serves as a vehicle for the spermatozoa (Korochkina et al., 2014). However, canine seminal plasma does not appear to have the ideal composition to support cryopreservation of spermatozoa (Sirivaidyapong et al., 2001). The sperm-rich fraction should therefore be centrifuged (at 720g for 5 minutes) to separate the spermatozoa from the seminal plasma (Rijsselaere et al., 2002). Thereafter, sperm cells should be diluted in a proper extender to promote semen survival during the cryopreservation process. Several extenders for dog semen are available and commercialized. Even though their formulations differ slightly from each other, they all contain substrates to provide energy, e.g. glucose, lactose, raffinose, saccharose or trehalose, salts, e.g. sodium citrate or citric acid, buffers to maintain an adequate pH and suitable osmolality, e.g. TRIS, a non-permeating cryoprotectant, e.g. egg yolk, skim milk, a permeating cryoprotectant, e.g. glycerol, ethylene glycol, to protect the spermatozoa from cryogenic injury and antibiotics to prevent the growth of bacteria, e.g. penicillin or streptomycin. Cryoprotectants reduce the physical and chemical stress sperm cells undergo during cooling, freezing and thawing (Barbas et al., 2009; Rijsselaere et al., 2011). Egg yolk is a common compound present in extenders due to its cryoprotectant and buffering properties associated with the presence of phospholipids (lecithin) and low density lipoproteins. Its concentration varies from 10 to 20% (Bencharif et al., 2008; Barbas et al., 2009; Abe et al., 2008). Egg yolk is however a biologically hazardous compound with a risk of bacterial contamination. Moreover, its composition is not constant and may vary between batches making it dif-



difficult to standardize (Axner et al., 2016). These disadvantages have motivated researchers to find alternatives, e.g. vegetal lecithin, egg yolk-derived phospholipids, milk-based diluters, but egg yolk remains so far superior to its replacements (Abe et al., 2008; Farstad, 2009; Axner et al., 2016). In recent studies, a positive effect of adding a detergent (Equex STM paste) and antioxidative compounds, e.g. melatonin, glutathione peroxidase or superoxide dismutase, to the extender has been demonstrated on canine semen survival (Amidi et al., 2016; Axner et al., 2016). The detergent Equex STM paste is supposed to exert its positive effect by modifying the egg yolk and should therefore be exclusively used in extenders containing egg yolk.

In some protocols, spermatozoa are diluted with the extender in one step but in recent studies, a beneficial effect of a two-step dilution has been shown in extenders only differing by their concentration of glycerol. The second extender contains a higher glycerol concentration and is added just before freezing, to reach a final glycerol concentration of 5%, in order to avoid the detrimental toxic effect of glycerol on the spermatozoa during the equilibration period (Peña et al., 2000; Nugraha Setyawan et al., 2015). This method is however more tedious, as it requires more handling and carries more risk of error or contamination during manipulation (Brito et al., 2017).

### Cooling of the semen

After dilution, a leak proof container with the extended semen is closed and placed in a water bowl (at 37°C) and cooled in the fridge ('au bain marie') for 1 to 2 hours at 4°C (Peña et al., 2000; Rijsselaere et al., 2011). This cooling period, called equilibration, is an essential step during the cryopreservation procedure. It allows the different components of the extender to carry out several modifications on the spermatozoa in order to prepare them to survive at low temperatures (Barbas et al., 2009). The plasma membrane suffers, however, from different stressors and some harmful cellular modifications may lead to the death of the spermatozoa, especially because of the toxic effect of glycerol (Barbas et al., 2009; Belala et al., 2016; Alcantar-Rodriguez et al., 2017).

### Freezing-thawing of the semen

After cooling, the extended semen is deposited in straws of 0.5 ml, which have been shown to be the best storage device for dogs, and properly identified with date, name of the dog, breed, chip number and freezing centre (Nöthling et al., 2005; Rijsselaere et al., 2011). Freezing can be obtained with a static method consisting of a rack, in which the straws are placed, and located at about 4 cm above the liquid nitrogen (temperature of -130°C). By varying the distance between the straws and the liquid nitrogen and the time of exposure before plunging into liquid nitrogen, dif-

ferent freezing rates can be obtained. However, the repeatability of these freezing rates is not optimal. To improve this technique, an automated programmable computerized freezer, e.g. IceCube®, can be used. The semen is cooled from 4°C to -130°C and then plunged into the liquid nitrogen (-196°C) and stored until further use (Schäfer-Somi et al. 2006). When the semen is needed, straws can be thawed in a water bath at 37°C for 30-60 seconds or at 70°C for 6-7 seconds (Rijsselaere et al., 2011).

### Insemination of frozen semen

Intrauterine insemination is the method of choice for frozen-thawed canine semen insemination (Mason, 2017). Transcervical insemination or TCI is preferable over surgical insemination, which is subject to ethical issues and even illegal in many countries (Kim et al., 2007; England et al., 2008). Transcervical insemination can be performed under visual guidance with fibre optic endoscopy, or can be performed blindly (by palpation of the cervix) with a Norwegian catheter (Scandinavian method). However, TCI performed by endoscopy allows visualization of the cervix and minimizes the risk of trauma during the procedure. A semen concentration of minimum 150 million live, morphologically normal spermatozoa has been shown to maximize the pregnancy rate and is therefore the recommended dose for artificial insemination (Mason, 2018). Higher whelping rates and litter sizes are obtained when the bitch is inseminated twice, respectively two and three days after ovulation (Thomassen et al., 2006; Hollinshead et al., 2017). In many studies, a whelping rate has been described varying between 60% and 70% after intrauterine insemination with frozen-thawed semen, whereas it reaches 85% when fresh semen is used (Alamo et al. 2005; Thomassen et al., 2006; Hollinshead et al., 2017; Mason, 2017). If the frozen-thawed semen cannot be deposited inside the uterus for any reason but intravaginally, the whelping rates drop dramatically to 10% (Thomassen et al., 2006).

### SEMEN DONATION

To broaden the genetic diversity in purebred dogs, the availability of stud males in the dog population needs to be increased. As only 5% of the entire Belgian canine population is used to produce puppies for the next generations, the idea of semen donation and the start of a public semen bank for dogs has emerged to counteract this unavoidable loss of genetic diversity. Since most owners of purebred dogs do not have the intention to breed with their dogs, persuading them to let their dog do a semen donation could be a tool to keep this valuable genetic material in the pool of reproducers. Semen donation can be somehow compared to blood donation in dogs. In semen donation however, the gift has an effect on the entire population

and not only on the individual.

After collection, the donated semen is analyzed and if of sufficient quality, is cryopreserved to be part of the first open canine semen bank (CanIFreeze). Information concerning the semen donors present in the bank is then shared publicly in a new software program developed by the KMSH, which is called the Mate Select Program. This program lists all registered dogs available for breeding and allows owners to simulate mating of their dog with another one. The inbreeding and kinship coefficients resulting from this mating are calculated based on the input of pedigrees and based on the results, the owner receives an advice to use this combination for breeding or not. Advice to breed is given for all combinations resulting in low levels of inbreeding and kinship coefficients.

The concept of an open canine semen bank is very simple: as for blood donation, specific criteria need to be fulfilled to become a canine semen donor. The dog needs to be a purebred dog or should have the breed-specific phenotype. For the start-up of the semen bank, the weight of the dog needs to be minimum 15 kg because the total sperm output is correlated to the size of the dog and small dogs will not give enough semen that can be cryopreserved for several insemination doses. At later stages, when cryopreservation techniques will have been optimized, smaller dogs might be included too. Finally, the dog needs to be minimum one year old because semen in younger dogs can be of lesser quality. The semen collection needs to be performed on different occasions, until enough semen has been collected for a minimum of two and a maximum of ten insemination doses. The lower limit is set at two to include at least one insemination dose in the semen bank, the second one being reserved for the owner of the donor dog. The upper limit is set at ten to avoid overuse of the sire.

To motivate the owner to come with his dog for semen donation, a free health check-up is performed and advice is given to the owner in case of any abnormality. Also, a free semen evaluation is performed and if the semen is suitable for cryopreservation, the owner of the stud dog is entitled to a free intrauterine insemination with a bitch of his choice in agreement with the owner of the bitch. This free insemination has to be done with the semen of their own stud and within 5 years following the collection. After this time, they can either remain the owner of this insemination dose but will have to pay a fee for the storage and the further insemination(s) or they can donate the insemination dose to the semen bank.

## CANIFREEZE

CanIFreeze is the name of the first public semen bank for dogs established worldwide and based primarily at the Faculty of Veterinary Medicine of Ghent University. However, every practicing veterinarian interested in canine reproduction can become a part-

ner in this semen banking project, after following a training on freezing, identification and storage of dog semen, either at the European Veterinary Society for Small Animal Reproduction (EVSSAR) congress or at the Faculty. By initiating this project and making it open for collaboration, it should achieve its primary goal, which is an increase in the number of pedigree dogs that will be successfully cryopreserved in Belgium and the Netherlands, resulting in an increased genetic diversity, if properly used. However, CanIFreeze is also a scientific project aiming to increase and improve the cryopreservation of dog semen. As previously described, there is a high variability in the resistance of sperm cells to withstand the freezing procedure (Rota et al., 2005; Schäfer-Somi et al., 2006; Farstad, 2009). Unsuitable semen leads to the elimination of a part of the canine gene pool that could be used in reproduction. Although an optimized standard protocol for the cryopreservation of dog semen would be ideal, this is not achievable due to variations in the cellular response to cryopreservation (Eilts, 2005). At present, Ghent University is using the 'Uppsala method' for freezing of dog semen. It consists of a two-step protocol with a Tris-citric acid-egg yolk-glucose-based extender. The first extender contains 3% of glycerol and is equilibrated with the semen until 4°C for 1-2 hours before the second extender, containing 7% of glycerol and Equex STM paste, is added. The semen is then packaged in straws of 0.5 ml and frozen with the automated programmable computerized freezer (IceCube) using the freezing curve described by Schafer-Somi in 2006 (Schäfer-Somi et al., 2006; Rijsselaere et al., 2011). With selected ejaculates of sufficient quality (at least 70 % progressive motility), this method is yielding about 50 % sperm survival and equal pregnancy rates. Therefore, in order to increase sperm survival and subsequent pregnancy rates, efforts will be made to develop new cryopreservation techniques and protocols to adapt the cryopreservation procedure on the individual. As such, during the period of this project, a part of the donated semen will be used for research.

## CONCLUSION

Semen donation can be an important tool to improve the poor genetic diversity currently observed in pedigree dogs. Cryopreservation of a fixed amount of semen doses from a large donor population increases the number of reproducers and helps to produce healthier generations of dogs. Furthermore, an open semen bank might increase the international gene flow. Involvement of many veterinary practices in the development of CanIFreeze is imperative in this respect. However, in order to successfully preserve the semen of as many dogs as possible, the cryopreservation procedure has to be optimized and individualized. Overall, the goal is to increase the genetic diversity in the Belgian (and other dog) population(s) worldwide.

## REFERENCES

- Abe Y., Lee D.-S., Sano H., Akiyama K., Yanagimoto-Ueta Y., Asano T., Suwa Y., Suzuki H. (2008). Artificial insemination with canine spermatozoa frozen in a skim milk/glucose-based extender. *Journal of Reproduction and Development* 54, 290-294.
- Alamo D., Batista M., Gonzalez F., Rodriguez N., Cruz G., Cabrera F., Gracia A. (2005). Cryopreservation of semen in the dog: use of ultra-freezers of -152 °C as a viable alternative to liquid nitrogen. *Theriogenology* 63, 72-82.
- Alcantar-Rodriguez A., Medrano A. (2017). The effect of cooling to different subzero temperatures on dog sperm cryosurvival. *Reproduction in Domestic Animals* 52, 422-428.
- Alhaider A.K., Watson P.F. (2008). Cryopreservation of dog semen effects of Equex STM paste on plasma membrane fluidity and the control of intracellular free calcium. *Animal Reproduction Sciences* 110, 147-161.
- Amidi F., Pazhohan A., Nashtaei M.S., Khodarahmian M., Nekoonam S. (2016). The role of antioxidants in sperm freezing: a review. *Cell and Tissue Banking* 17, 745-756.
- Axnér E., Lagerson E. (2016). Cryopreservation of dog semen in a tris extender with 1% or 2% soya bean lecithin as a replacement of egg yolk. *Reproduction in Domestic Animals* 51, 262-268.
- Barbas J.P., Mascarenhas R.D. (2009). Cryopreservation of domestic animal sperm cells. *Cell and Tissue Banking* 10, 49-62.
- Belala R., Brian-Amirat L., Vinciguerra L., Tainturier D., Kaidi R., Thorin C., Michaud S., Anton M., Bencharif D. (2016). Effect of equilibration time on the motility and functional integrity of canine spermatozoa frozen in three different extenders. *Research in Veterinary Science* 106, 66-73.
- Bencharif D., Amirat L., Anton M., Schmitt E., Desherces S., Delhomme G., Langlois M.-L., Barrière P., Larrat M., Tainturier D. (2008). The advantages of LDL (low density lipoproteins) in the cryopreservation of canine semen. *Theriogenology* 70, 1478-1488.
- Brito M.M., Lucio C.F., Angrimani D.S.R., Losano J.D.A., Dalmazzo A., Nichi M., Vannucchi C.I. (2017). Comparison of cryopreservation protocols (single and two-steps) and thawing (fast and slow) for canine semen. *Animal Biotechnology* 28(1), 67-73.
- Eilts B.E. (2005). Theoretical aspects of canine semen cryopreservation. *Theriogenology* 64, 692-697.
- England G.C.W., Millar K.M. (2008). The ethics and role of AI with fresh and frozen semen in dogs. *Reproduction in Domestic Animals* 43(2), 165-171.
- European Pet Food Industry Federation (FEDIAF) (2017). <http://www.fediaf.org/>. Consulted the 20/01/2019
- Farrell L.L., Schoenebeck J.J., Wiener P., Clements D.N., Summers K.M. (2015). The challenges of pedigree dog health: approaches to combating inherited disease. *Canine Genetics and Epidemiology* 2, 1-14
- Farstad W. (2000). Current state in biotechnologies in canine and feline reproduction. *Animal Reproduction Science* 60-61, 375-387.
- Farstad W. (2009). Cryopreservation of canine semen - new challenges. *Reproduction in Domestic Animals* 44(2), 336-341.
- Futino D.O., Mendes M.C.B., Matos W.N.L., Mondadori R.G., Lucci C.M. (2010). Glycerol, methyl-formamide and dimethyl-formamide in canine semen cryopreservation. *Reproduction in Domestic Animals* 45, 214-220.
- Hollinshead F.K., Hanlon D.W. (2017). Factors affecting the reproductive performance of bitches: A prospective cohort study involving 1203 inseminations with fresh and frozen semen. *Theriogenology* 101, 62-72.
- Khan J., Tahir M.Z., Khalid A., Sattar A., Ahmad N. (2017). Effect of cholesterol- loaded cyclodextrins on cryosurvival of dog spermatozoa. *Reproduction in Domestic Animals* 52(2), 265-268.
- Kim H.J., Oh H.J., Jang G., Kim M.K. (2007). Birth of puppies after intrauterine and intratubal insemination with frozen-thawed canine semen. *Journal of Veterinary Sciences* 8(1), 75-80.
- Kim S.H., Yu D.H., Kim Y.J. (2010). Effects of cryopreservation on phosphatidylserine translocation, intracellular hydrogen peroxide, and DNA integrity in canine sperm. *Theriogenology* 73, 72-82.
- Korochkina E., Johannisson A., Goodla L., Morell J.M., Axner E. (2014). Effect of prostatic fluid on the quality of fresh and frozen-thawed canine epididymal spermatozoa. *Theriogenology* 82, 1206-1211.
- Kutzler M.A. (2005). Semen collection in the dog. *Theriogenology* 64, 747-754.
- Leroy G., Verrier E., Wisner-Bourgeois C., Rognon X. (2007). Breeding goals and breeding practices of French dog breeders: results from a large survey. *Revue de Médecine Vétérinaire* 158, 496-503.
- Leroy G., Baumung R. (2011). Mating practices and the dissemination of genetic disorders in domestic animals, based on the example of dog breeding. *Animal Genetics* 42(1), 66-74.
- Leroy G., Rognon X. (2012). Assessing the impact of breeding strategies on inherited disorders and genetic diversity in dogs. *The Veterinary Journal* 194(3), 343-348.
- Mason S.J. (2017). A retrospective clinical study of endoscopic- assisted transcervical insemination in the bitch with frozen-thawed dog semen. *Reproduction in Domestic Animals* 52 (2), 275-280.
- Mason S.J. (2018). Current review of artificial insemination in dogs. *Veterinary Clinics of North America: Small Animal Practice* 48, 567-580.
- Mellersh C. (2008). Give a dog a genome. *The Veterinary Journal* 178(1), 46-52.
- Nöthling J.A., Shuttleworth R. (2005). The effect of straw size, freezing rate and thawing rate upon post-thaw quality of dog semen. *Theriogenology* 63, 1469-1480.
- Nugraha Setyawan E.M., Kim M.J., Oh H.J., Kim G.A., Jo Y.K., Lee S.H., Choi Y.B., Lee B.C. (2015). Maintaining canine sperm function and osmolyte content with multistep freezing protocol and different cryoprotective agents. *Cryobiology* 71, 344-349.
- Online Mendelian Inheritance in Animal (OMIA) (2019). <https://omia.org/home/>. Consulted the 20/01/2019
- Patterson D.F. (2000). Companion animal medicine in the age of medical genetics. *Journal of Veterinary Internal Medicine* 14(1), 1-9.
- Peña A., Linde-Forsberg C. (2000). Effects of Equex, one- or two-step dilution, and two freezing and thawing rates on post-thaw survival of dog spermatozoa. *Theriogenology* 54, 859-875.
- Rota A., Rota A., Martini M., Milani C., Romagnoli S. (2005). Evaluation of dog semen quality after slow (biological freezer) or rapid (nitrogen vapours) freezing. *Reproduction, Nutrition and Development* 45(1), 29-37.
- Rijsselaere T., Van Soom A., Maes D., de Kruif A. (2002).



- Effect of centrifugation on in vitro survival of fresh diluted canine spermatozoa. *Theriogenology* 57(6), 1669-1681.
- Rijsselaere T., Maes D., Van Den Berghe F., Van Soom A. (2011). Preservation and shipment of chilled and cryopreserved dog semen. *Vlaams Diergeneeskundig Tijdschrift* 80, 248-253.
- Schäfer-Somi S., Kluger S., Knapp E., Klein D., Aurich C. (2006). Effects of semen extender and semen processing on motility and viability of frozen-thawed dog spermatozoa. *Theriogenology* 66, 173-182.
- Sirivaidyapong S., Ursem P., Bevers M.M., Colenbrander B. (2001). Effect of prostatic fluid on motility, viability and acrosome integrity of chilled and frozen-thawed dog spermatozoa. *Journal of Reproduction and Fertility. Supplement* 57, 383-386.
- Thomassen R., Sanson G., Krogenaes A., Fougner J.A., Andersen Berg K., Farstad W. (2006). Artificial insemination with frozen semen in dogs a retrospective study of 10 years using a non-surgical approach. *Theriogenology* 66, 1645-1650.
- Wang S., Leroy G., Malm S., Lewis T., Strandberg E., Fikse W.F. (2017). Merging pedigree databases to describe and compare mating practices and gene flow between pedigree dogs in France, Sweden and the UK. *Journal of Animal Breeding and Genetics* 134(2), 152-161.
- Wijnrocx K., François L., Stinckens A., Janssens S., Buys N. (2016). Half of the 23 Belgian dog breeds has a compromised genetic diversity, as revealed by genealogical and molecular data analysis. *Journal of Animal Breeding and Genetics* 133(5), 375-383.

## Oproep



**CANIFREEZE**  
**SPERMABANK BIJ DE HOND**

Het aantal fokreuen moet toenemen om het aantal genetische ziekten bij honden te verminderen.

**CRITERIA:**

- Reu (niet gecastreerd)
- Rashond
- Minimum 15 kg
- Minimum 1 jaar oud

**VOORDELEN:**

- Gratis gezondheidscontrole
- Gratis sperma-onderzoek
- Eén gratis inseminatie binnen 5 jaar na collectie

**WIL JIJ ONS HELPEN OM DE GEZONDHEID VAN RASHONDEN TE VERBETEREN? JOUW HOND KAN HIERBIJ HELPEN**

De Universiteit van Gent zoekt intacte reuen voor

**SPERMADONATIE**

**VOOR INLICHTINGEN, CONTACTEER ONS OP 09/264.75.64**

Jij houdt van je hond maar je wilt er zelf niet mee fokken? Jij kan ons helpen om een spermabank op te starten voor toekomstige generaties.

GUILLAUME DOMAIN  
09/264.75.64  
VOORTPLANTING.GEZELSCHAPSDIEREN@UGENT.BE  
SALISBURYLAAN 233, 9000 MERELBEKE

UNIVERSITEIT GENT



## ORALE SEDATIE VOORAFGAAND AAN EUTHANASIE BIJ AGRESSIEVE HONDEN

## VRAAG

*Onlangs werd mij gevraagd een mannelijke Duitse herder (5 jaar, 35kg) te euthanaseren na plots overlijden van de eigenaar.*

*Sedert het overlijden van de eigenaar kon het dier enkel gevoed worden door zijn voeding met een lange stok onder zijn kennel te schuiven om bijtonden te voorkomen. Vandaar de vraag betreffende euthanasie van het dier. Overdracht naar een andere eigenaar was geen optie.*

*De hond zou dus eerst oraal gesedeerd moeten worden, omwille van zijn uiterst agressieve karakter tegenover andere mensen dan de eigenaar.*

*Ik had ergens gelezen dat de injecteerbare vorm van acepromazine een beter sedatief effect zou hebben (of sneller effect?) dan de tabletvorm die gebruikt wordt bij reisziekte. Eerst werd 12 ml van een injecteerbare acepromazine-oplossing 2% in ontdooid diepvriesvlees gemengd. Dit komt overeen met 6 tabletten van 20 mg. Het dier at dit op zonder problemen. Het dier was nuchter bij deze eerste toediening. Een uur later werden zes valiumtabletten van 10 mg in de voeding gemengd.*

*Nog eens een uur later werd geprobeerd 3 ml ketamine 100 mg/ml in de open dreigende muil van de hond te spuiten, wat maar gedeeltelijk lukte, en werd nog eens 12 ml acepromazine-oplossing 2% in de voeding gemengd. Ook dit werd zonder probleem opgegeten.*

*Alhoewel de hond zich 3 uur na de eerste toediening neerlegde en zich moeizaam en al waggelend voortbewoog, waren plotse bewegingen voldoende om een gevaarlijke uitval te doen. Uiteindelijk lukte het om door de tralies een lus over de kop te schuiven, de hond tegen de tralies aan te trekken en zoletil (tiletamine en zolazepam) intramusculair in te spuiten, waarna hij een anesthesiastadium bereikte.*

*Daarna volgde een intraveneuze injectie met euthasol vet (pentobarbital 400mg/ml).*

*Omwille van de moeilijke en traag inwerkende sedatie voorafgaand aan de eigenlijke euthanasie, mijn vraag: welk protocol (producten en doseringen) zou u voorstellen?*

## ANTWOORD

Intramusculaire (IM) of intraveneuze (IV) sedatie van angstige en/of agressieve dieren voorafgaand aan euthanasie blijkt soms erg moeilijk te verlopen, gezien deze dieren vaak moeilijk te benaderen zijn door de dierenarts en soms zelfs door de eigenaar. Men is daarom genoodzaakt om zijn toevlucht te zoeken tot een alternatieve sedatiemethode voorafgaand aan de eigenlijke euthanasie.

De toediening van orale formulaties (tabletten, gel) van tranquillizers of sedativa (acepromazine, dexmedetomidine) resulteert vaak in onbetrouwbare of lichte sedatie, in tegenstelling tot de IM- of IV-toediening van deze producten. Dit is te wijten aan een onvoldoende opname na orale toediening, resulterend in een lange inwerkingstijd en een onbetrouwbaar sedatief effect. Een betere sedatie is te verwachten na een geslaagde orale transmucosale toediening (OTM), i.e. opname via de slijmvliezen van de mond, maar dit is bij agressieve dieren technisch moeilijk uit te voeren (Cohen en Bennet, 2015).

Bovendien wordt vaak gezien dat dieren die gesedeerd lijken, toch snel kunnen reageren bij plotse bruuske manipulaties en/of geluiden, waardoor ze tijdelijk uit hun sedatie gehaald worden en een afweerreactie kunnen vertonen tegen eigenaar en/of dierenarts. Deze initiële orale (of OTM) sedaties dienen daarom vooral als hulpmiddel om een muilband te kunnen opzetten, waarbij men bij het uitvoeren van deze handeling uit veiligheidsoverwegingen achter het dier plaatsneemt. Na het plaatsen van de muilband kan een bijkomende injectie IM/IV gegeven worden voor bijkomende sedatie/anesthesie alvorens over te gaan tot euthanasie, i.e. multi-stappensedatie (Shaford, 2016).

Deze eerste sedatie dient dus louter om het dier benaderbaar te maken en leidt zelden tot een betrouwbare diepe sedatie. Volgende technieken/producten kunnen hiervoor gebruikt worden:

**Initiële sedatie (Papich, 2011):**

- Acepromazine: 0,05-0,1 mg/kg, injecteerbare vorm, oraal transmucosaal (OTM) in de mond sprayen of in mondhoek, 30 minuten wachttijd
- OF
- Dexmedetomidine: 10-25 µg/kg, injecteerbare vorm, OTM in de mond sprayen of in mondhoek, matige tot zware sedatie mogelijk
- OF
- Medetomidine: 20-50 µg/kg, injecteerbare vorm, OTM in de mond sprayen of in mondhoek, matige tot zware sedatie mogelijk

OF

- Fenobarbital: 6-30 mg/kg, PO, 1 uur wachttijd voorafgaand aan effect

Bijkomende toedieningen of een combinatie van de bovenstaande opties met fenobarbital zijn mogelijk in het geval er onvoldoende sedatie optreedt voor het voorzichtig plaatsen van een muilband. Na het aanbrengen van de muilband kan een IV-katheter geplaatst worden al dan niet voorafgegaan door bijkomende IM-sedatie, i.e. (dex)medetomidine of acepromazine, etc. al of niet in combinatie met ketamine (anesthesie).

Na het plaatsen van de IV-katheter kan de eigenlijke euthanasie plaatsvinden met een daarvoor geregistreerd middel.

## REFERENTIES

- Cohen A.E., Bennet S.L., (2015). Oral transmucosal administration of dexmedetomidine for sedation in 4 dogs. *Canadian Veterinary Journal* 56, 1144-1148.
- Papich M.G., (2011). *Saunders Handbook of Veterinary Drugs – Small and Large Animal*. Third edition, Elsevier Saunders, MI, USA.
- Shafford H.L., (2016). Serenity now: practical sedation options for cats & dogs. *Indiana Veterinary Medical Association, Summer Conference*.

Prof. dr. I. Polis  
Vakgroep Kleine Huisdieren,  
Faculteit Diergeneeskunde, UGent,  
Salisburylaan 133, B-9820 Merelbeke

## Uit het verleden

### ‘Snepper’ (geopend)


#### Museumcollectie Diergeneeskundig Verleden Merelbeke



Naast het zeer bekende en wijd verspreide vlijm om bloed te ‘laten’, gebruikten professionele chirurgijnen en veeartsen, die dat veelvuldig toepasten, ook een lancet (vlijm) met springveer. Gaf minder problemen bij onrustige of moeilijk bedwingbare dieren. Het deksel wordt op het instrumentje geschroefd en het veer opgespannen met behulp van een snaphaan, zoals bij een geweer. Hiermee kon men het vlijm uiterst snel en krachtig laten uitschieten om doorheen de huid het opgespannen bloedvat te openen.

Luc Devriese

### “Stories uit de stal”



Eind 2018 verscheen een zeer lezenswaardig geschenkboekje *Stories uit de stal* (Stichting Kunstboek, Oostkamp, 160 pagina's) met interviews afgenomen van een tiental oude dierenartsen uit de 'Grote Praktijk' en tot vlotte teksten bewerkt door Katrien Vervaele, die ook de foto's voor haar rekening nam. De teksten zijn stuk voor stuk niet enkel persoonlijke getuigenissen, samen vormen ook een uniek documentair geheel. Een beeld van een bijna verdwenen wereld. Hierbij gereproduceerd: de enige geïnterviewde die niet actief was in de gewone

praktijk, maar op de Buitenpraktijk van 't Schole'. Hij nam vooral de varkenspraktijk voor zijn rekening. Voor de jongskes die hem niet zouden kennen: prof. Marc Verdonck, gefotografeerd in de museumkelder van de faculteit.

Het boek is verkrijgbaar in de gewone boekhandel of via het internet op de site van de uitgeverij. Kost 19,95 euro, eventueel plus verzendkosten.

L. Devriese





# Wij hebben jou in 't oog. Jij ons?

[www.mediaservice.be](http://www.mediaservice.be)



© SHUTTERSTOCK 127745M100133

**Mediaservice**    
gericht adverteren