

## External abdominal pressure radiography versus survey radiography for the diagnosis of hiatal hernia in brachycephalic dogs

*Externe abdominale drukradiografie versus overzichtsradiografie voor de diagnose van hiatale hernia bij de brachycefale hond*

<sup>1</sup>G. Mercken, <sup>2</sup>B. Van Goethem, <sup>1</sup>J. Saunders, <sup>1</sup>E. Stock\*

<sup>1</sup>Department of Morphology, Imaging, Orthopedics, Rehabilitation and Nutrition, Faculty of Veterinary Medicine, Ghent University, Salisburylaan 133, B-9820 Merelbeke, Belgium

<sup>2</sup>Small Animal Department, Faculty of Veterinary Medicine, Ghent University, Salisburylaan 133, B-9820 Merelbeke, Belgium

emmelie.stock@ugent.be

### ABSTRACT

**Hiatal hernia (HH) is a common disorder in brachycephalic dogs with upper airway obstruction. The breathing effort results in an exaggerated transdiaphragmatic pressure gradient during inspiration that can displace the gastroesophageal junction causing gastroesophageal reflux. The diagnosis is challenging because the HH usually occurs intermittently and is often missed on survey radiography. In this retrospective study, the application of external abdominal pressure to mimic the transdiaphragmatic pressure gradient during radiographic screening for HH was evaluated in 146 dogs. Hiatal hernia was diagnosed with external abdominal pressure radiographs in 6.8% (10/146 dogs), whereas it was diagnosed via survey radiography in only 2% (3 dogs). In conclusion, the radiographic diagnosis of HH in brachycephalic dogs can be improved by performing external abdominal pressure radiographs.**

### SAMENVATTING

Hiatale hernia (HH) is een veel voorkomende aandoening bij brachycefale honden met obstructie van de bovenste luchtwegen. De ademhalingsinspanning resulteert in een overdreven transdiafragmatische drukgradiënt tijdens de inspiratie, waardoor de gastro-oesofageale overgang kan verplaatsen, wat gastro-oesofageale reflux veroorzaakt. De diagnose is een uitdaging omdat HH meestal intermitterend voorkomt en vaak over het hoofd wordt gezien tijdens overzichtsradiografie. In dit retrospectief onderzoek werd het uitvoeren van externe druk op het abdomen om de transdiafragmatische drukgradiënt na te bootsen tijdens radiografische screening voor HH geëvalueerd bij 146 honden. Op röntgenfoto's met externe abdominale druk werd HH gediagnosticeerd bij 6,8% (10/146 honden), terwijl slechts 2% gediagnosticeerd werd via overzichtsradiografie. De radiografische diagnose van HH bij brachycefale honden kan dus worden verbeterd door radiografie met externe buikdruk uit te voeren.

### INTRODUCTION

Hiatal hernia (HH) involves the cranial displacement of the abdominal esophagus, gastroesophageal junction, stomach and potentially other abdominal organs through the esophageal hiatus into the thoracic cavity (Pollard, 2012). Four types of hiatal hernia have been documented in dogs. Type I is the most common hiatal hernia and involves sliding cranial displacement

of the gastroesophageal junction through the esophageal hiatus into the thorax (Hall et al., 2020). Type II is a paraesophageal or rolling hernia in which the gastroesophageal junction remains in the abdomen, but part of the stomach herniates adjacent to it through the esophageal hiatus. Type III is a combination of sliding and rolling, and in type IV, other abdominal organs herniate through the hiatus (Reeve et al., 2017).

Brachycephalic dogs are well known to suffer from



**Figure 1.** Setup for the EAP radiography, with the dog in right lateral recumbency and a wooden spoon compressing the abdomen in a craniodorsal direction just behind the last rib.

brachycephalic obstructive airway syndrome (BOAS), but actually display mixed aerodigestive clinical signs (Freiche and German, 2021). This is caused by the common occurrence of sliding HH in brachycephalic dogs and the associated gastroesophageal reflux (GER) that is a major contributor to the clinical signs (Luciani et al., 2022). It causes regurgitation of food and water, discomfort and hypersalivation, reflux esophagitis, esophageal stricture formation, vomiting, coughing, and aspiration pneumonia (Mayhew et al. 2023; Freiche and German, 2021; Hall et al., 2020). Brachycephalic dogs with HH can also present without typical gastrointestinal clinical signs and solely display respiratory symptoms and aspiration pneumonia (Luciani et al., 2022). Correction of the upper airway obstruction together with the HH improves the clinical outcome (Mayhew et al., 2023). Correctly identifying this underlying digestive disorder is therefore warranted.

Hiatal hernia is thought to result from an increased transdiaphragmatic pressure gradient, i.e. the difference between intra-abdominal and intrathoracic pressures) occurring in BOAS dogs because of their increased inspiratory pressures (Broux et al., 2018). Survey (SRV) thoracic radiographs are amongst the modalities used to detect HH in dogs (Luciani et al. 2022; Reeve et al., 2017; Pollard, 2012). A lateral radiograph focussing on the diaphragm shows an abnormal soft tissue opacity at the level of the thoracic esophagus cranial to the diaphragm if an active herniation is present. Contrast radiography can help to identify the correct location of the esophagus in this soft tissue mass. Radiographic diagnosis is, however, frequently false negative because of the intermittent aspect of the esophageal displacement (Pollard, 2012). Inducing this transdiaphragmatic pressure gradient artificially during radiographic screening by applying external abdominal pressure (EAP) has been suggested to improve its diagnostic sensitivity (Broux et al., 2018; Pollard, 2012). Because radiography is

the most common imaging modality in general practice for the evaluation of a wide variety of respiratory clinical signs, increasing its diagnostic sensitivity for HH is clinically important. The authors hypothesized that EAP radiography could improve the diagnostic sensitivity for the radiographic detection of HH over SRV radiography.

## MATERIALS AND METHODS

A retrospective medical records review was conducted at the Department of Medical Imaging, Orthopedics and Hydrotherapy (Faculty of Veterinary Medicine, Ghent University) on dogs evaluated for the presence of a HH from January 1st, 2009 to December 31st, 2021. Dogs were included when at least two qualitative lateral thoracic radiographs, including 1 EAP radiograph and 1 SRV radiograph taken at the same date, were available. All the dogs were anesthetized and intubated for examination. In this study, there was no use of endotracheal tube occlusion (ETO) as described by Broux et al. (2018). Due to the retrospective study, there was no information available as to the anesthetic protocol.

Survey radiographs for HH screening were performed with the dog in right lateral recumbency and the radiograph collimated from the thoracic inlet (caudal aspect of the scapulae) up to the cranial aspect of the abdomen (level of the last rib). The radiograph was taken during inspiration. For the EAP radiograph, a wooden spoon was placed immediately caudal to the costal arch with pressure directed craniodorsal (Figure 1). Proper radioprotection measures were ensured during the procedure.

The diagnosis in the patient file was re-evaluated and scored as positive (presence of an abnormal soft tissue opacity cranial to the diaphragm fitting with HH), suspected (presence of an abnormal soft tissue opacity but unconvincing to be HH), and negative (no abnormal soft tissue opacity present). Dogs that could not be scored for HH on the radiographs due to confounding pathologies obscuring the area of interest were excluded.

Only dogs belonging to brachycephalic breeds were included (Freiche and German, 2021; Meola, 2013).

## RESULTS

During the study period, radiographic screening for HH was performed in 167 dogs. Twenty-two dogs were excluded from the study, including fourteen dogs that did not belong to a brachycephalic breed and seven dogs in which the presence of HH could not be scored due to confounding pathologies. A total of 146 dogs were included in the study. Breeds represented included French bulldog (n=84), English bulldog (n=26), pug (n=23), Bordeaux dog (n=5), cavalier King Charles spaniel (n=3), Chinese Shar Pei

**Table 1. The radiographic diagnosis of HH using external abdominal pressure radiography and survey radiography in 146 brachycephalic dogs suspected of hiatal hernia.**

SHH diagnosis	Positive	Suspected	Negative
Standard radiograph	3	2	5
External abdominal pressure radiograph	10	0	0

(n=2), and Chihuahua, Boston terrier and Old English bulldog (one each). The median age was 26 months (range 4 to 127 months). The sex distribution was 100 male dogs (76 male intact, 24 male castrated) and 46 female dogs (26 female intact, 20 female spayed).

Ten of the 146 dogs (6.8%) included in the study were diagnosed with HH based on either EAP radiography or SRV radiography. Nine dogs had a type-I sliding HH and one 2.5-year-old French bulldog was diagnosed with a type-II rolling HH. Male dogs were overrepresented with six male dogs (three male intact, three male castrated) versus four female dogs (one female intact, three female spayed). The median age was 34 months (range 8 to 127 months). Breeds included were the French bulldog (n=6), English bulldog (n=2), Chinese Shar Pei (n=1), and Pug (n=1). In these dogs, hiatal hernia was found in 100% (1/1 dogs) for the Chinese Shar Pei, 7.1% (6/84 dogs) for the French bulldog 7.7% (2/26 dogs) for the English bulldog, and 4.3% (1/23 dogs) for the pug in this study.

Survey radiographs resulted in a positive diagnosis of HH in 30% (3/10 dogs), a suspected diagnosis in 20% (2/10 dogs), and a negative diagnosis in 50% (5/10 dogs) of the dogs (Table 1). The two dogs with a suspected diagnosis of HH on SRV radiography had a positive diagnosis on EAP radiography. Five dogs with a negative diagnosis for HH on SRV radiography (Figure 2A) had a positive diagnosis on EAP radiography (Figure 2B).

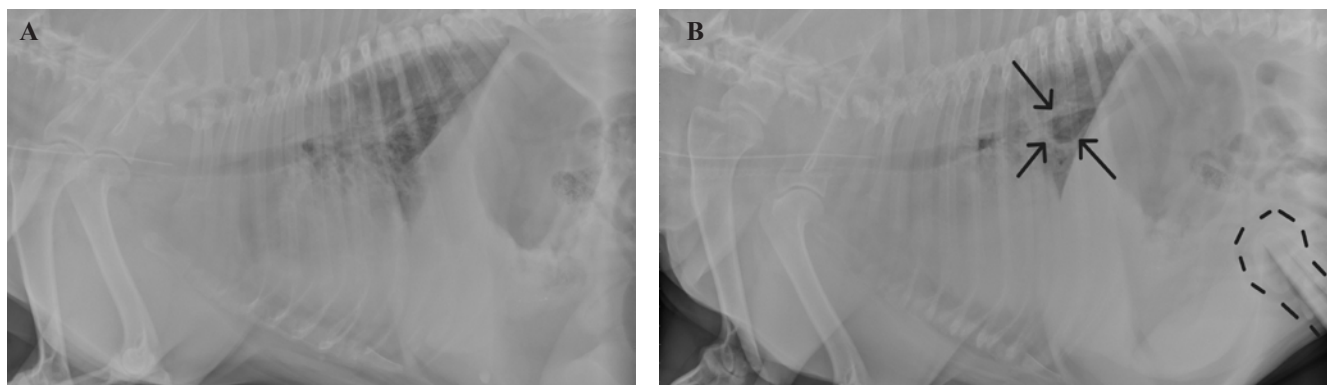
## DISCUSSION

In the current study, it was found that the application of external pressure on the abdomen during

radiographic HH screening in brachycephalic dogs increased the ability to diagnose HH over survey radiography (10/146 dogs positive on EAP radiography versus 3/146 dogs positive on SRV radiography). Dogs that were diagnosed as suspected or even negative on SRV radiography could unmistakably be diagnosed with HH on EAP radiography.

Survey radiographs have previously shown to be unreliable for the diagnosis of HH since they consistently underestimate the true prevalence and only detect between 20% (1/5 dogs) (Broux et al., 2018) and 55% (36/66 dogs) (Luciani et al., 2022) of the dogs ultimately diagnosed with HH via other imaging techniques. In the current study, only 30% (3/10 dogs) of the dogs with HH could be diagnosed on survey radiography. It has been suggested to increase the diagnostic yield of radiographic HH diagnosis by performing contrast radiography to help outline the gastroesophageal sphincter and make the identification of a displaced gastroesophageal junction easier (Reeve et al., 2017; Pollard, 2012). However, the diagnostic challenge is not the identification of the gastroesophageal junction but the fact that the most common type I or sliding HH is a transient disorder. During or preceding the radiographic study, dogs are preoxygenated and sometimes even sedated resulting in decreased respiratory effort and a decreased transdiaphragmatic pressure gradient (Vangrinsven et al., 2021). The presence of HH should therefore not be ruled out based on a negative survey radiography.

Manual pressure on the abdomen has been postulated for radiography (Broux et al., 2018; Pollard, 2012), but up till now, no studies have been performed on EAP radiography. The position of the dog during the imaging procedure also influences the transdia-



**Figure 2.** Example of a dog where A. no hiatal hernia was identified on survey radiography and B. a positive diagnosis was made on the external abdominal pressure radiography. Arrows point at the displaced gastroesophageal junction, dotted line outlines the wooden spoon applying external abdominal pressure.

phragmatic pressure gradient with lateral recumbency achieving a higher pressure versus sternal recumbency (Pratschke et al., 2001) and thirty-degrees Trendelenburg position (head down, tail up) achieving a higher pressure versus neutral table position (Broux et al., 2018). External abdominal pressure has been shown to achieve additional positive diagnoses during endoscopic screening for HH (Broux et al., 2018). The number of positive HH diagnoses increased from 2/5 to 5/5 dogs when EAP with the fist was performed during endoscopic HH screening. However, when EAP radiography was used during videofluoroscopic swallow studies for HH screening, this did not result in additional positive diagnoses (Eivers et al., 2019; Reeve et al., 2017). A possible explanation is the experienced difficulty to achieve an increased abdominal pressure in an awake animal in a standing position whilst respecting radioprotection measures close to the fluoroscopy beam. Another reason can be the high diagnostic yield of videofluoroscopic swallow studies, making it unlikely that dogs with HH are missed.

Broux et al. (2018) also described that the use of ETO increases the chance to diagnose gastroesophageal junction abnormalities. An interesting follow-up study would be to monitor the effect of applying both EAP and ETO at the same time, with the patient closely monitored to avoid unwanted side effects like hypoxia.

Dynamic medical imaging studies that allow imaging over several minutes, such as videofluoroscopic swallow studies or endoscopy, increase the likelihood of visualizing transient abnormalities (Pollard, 2012). Yet, the prevalence of HH based on endoscopy in brachycephalic dogs with aerodigestive disease varies between 0% and 4.1% (Broux et al., 2018, Poncet et al., 2006; Poncet et al., 2005). This underestimation is caused by the fact that the endotracheal tube and general anesthesia necessary during this imaging procedure ease the breathing effort and diminish the transdiaphragmatic pressure gradient necessary to induce the intermittent herniation (Vangrinsven et al., 2021). Inducing forced inspiration and restoring the increased transdiaphragmatic pressure gradient by briefly obstructing the endotracheal tube were successful in increasing the number of positive HH diagnoses from 0/5 to 4/5 dogs in the study by Broux et al. (2018).

Sensitivity and specificity rates of each imaging technique have not been described in the veterinary literature because there is often no gold standard diagnosis at surgery or autopsy to compare the findings of the imaging study with (Reeve et al., 2017). It also remains difficult to compare the different prevalences of HH amongst the different imaging techniques. Study populations differ and might contain only brachycephalic dogs with gastrointestinal clinical signs and thus achieving higher prevalences. In the current study, dogs with and without gastrointestinal signs were included. This might explain in part the lower

prevalence of 6.8% HH diagnoses in brachycephalic dogs. In other studies, a prevalence of 5% (1/20 dogs) via radiography (Broux et al., 2018), of 25% (5/20 dogs) via endoscopy (Broux et al., 2018), and of 44% (16/36 dogs) via videofluoroscopic swallow study (Reeve et al., 2017) were found.

The prevalence of HH has been reported to be higher in male dogs (Reeve et al., 2017; Poncet et al., 2005), which was also noted in the current study with a 2/1 male-to-female ratio. In the study by Reeve et al. (2017), the diagnosis of HH was made at the age of two years old. That is surprisingly young for a suspected acquired disease occurring due to inspiratory effort caused by BOAS. In the current study, a median age of 34 months was found.

Although the Chinese Shar Pei is considered a brachycephalic breed, the presence of HH has been attributed to a congenital disorder of the esophageal hiatus rather than an acquired disorder secondary to an increased transdiaphragmatic pressure gradient due to BOAS (Guiot et al., 2008). Congenital hernias occur due to a developmental abnormality of the esophageal hiatus or phrenicesophageal ligament (Reeve et al., 2017). The only Chinese Shar Pei dog in this study had a positive diagnosis on both SRV radiography and EAP radiography. Management of a congenital HH requires surgical reconstruction of the esophageal rim and hiatus (Callan et al., 1993).

For the management of HH secondary to BOAS, multilevel upper airway correction and supportive antacid medication have traditionally been advocated (Vangrinsven et al., 2021). On endoscopic follow-up monitoring, Poncet et al. (2006) found that 20% (10/51 dogs) showed improvement of their macroscopic GI lesions. This can be explained by the fact that multilevel surgery has the potential to decrease the transdiaphragmatic pressure difference at the esophageal hiatus and thus lower the frequency with which the gastroesophageal junction herniates. Two of the dogs in that study had sliding HH, but no further information was given on the evolution of the hernia (Poncet et al., 2006). In a recent study by Mayhew et al. (2023) in 13 dogs with sliding HH, the owners reported that the severity of the gastrointestinal signs was much lower after multilevel BOAS surgery. However, when evaluated by endoscopy and videofluoroscopic swallow study, the frequency of sliding HH and gastroesophageal reflux was unchanged (Mayhew et al., 2023). Since the laxity at the esophageal hiatus remains, herniation still happens and continues to cause problems for the dog although gastrointestinal clinical signs are not always evident. Surgical correction of sliding HH is therefore also indicated for the acquired form in brachycephalic dogs.

This study has several limitations. The first is the retrospective nature of the study and thereby the lack of standardization of the applied external abdominal pressure performed. However, even if the same person would perform all EAP radiographs, standardiza-

tion of the pressure among the different breeds would remain difficult. Secondly, the low number of dogs diagnosed with HH makes statistical analysis impossible. Last, it would have been interesting to compare the EAP radiographs with other imaging techniques, such as videofluoroscopic swallow study and endoscopy.

In the present study, it is demonstrated that the radiographic diagnosis of HH in brachycephalic dogs can be improved by performing external abdominal pressure radiographs together with survey radiography. Endoscopy and videofluoroscopic swallow study remain indicated for dogs that are suspected of HH but have a negative diagnosis on radiography.

## REFERENCES

- Broux, O., Clercx, C., Etienne, A.L., Busoni, V., Claeys, S., Hamaide, A., Billen, F., (2018). Effects of manipulations to detect sliding hiatal hernia in dogs with brachycephalic airway obstructive syndrome. *Veterinary Surgery* 47, 243-251.
- Callan, M.B., Washabau, R.J., Saunders, H.M., Kerr, L., Prymak, C., Holt, D., (1993). Congenital esophageal hiatal hernia in the Chinese Shar-Pei dog. *Journal of Veterinary Internal Medicine* 7, 210-215.
- Eivers, C., Rueda, R.C., Liuti, T., Schmitz, S.S., (2019). Retrospective analysis of esophageal imaging features in brachycephalic versus non-brachycephalic dogs based on videofluoroscopic swallowing studies. *Journal of Veterinary Internal Medicine* 33, 1740-1746.
- Freiche V., German A.J. (2021). Digestive diseases in brachycephalic dogs. *Veterinary Clinics of North America: Small Animal Practice* 51(1), 61-78. doi: 10.1016/j.cvsm.2020.09.006. PMID: 33187623.
- Guiot, L.P., Lansdowne, J.L., Rouppert, P., Stanley, B.J., (2008). Hiatal hernia in the dog: a clinical report of four Chinese Shar Peis. *Journal of the American Animal Hospital Association* 44, 335-341.
- Hall, E.J., Williams, D.A.O., Kathrani, A. (2020). *BSAVA Manual of Canine and Feline Gastroenterology*. Third edition, Quedgeley, Gloucester, British Small Animal Veterinary Association.
- Luciani, E., Reinerio, C., Grobman, M., (2022). Evaluation of aerodigestive disease and diagnosis of sliding hiatal hernia in brachycephalic and nonbrachycephalic dogs. *Journal of Veterinary Internal Medicine* 36, 1229-1236.
- Mayhew, P.D., Marks, S.L., Pollard, R., Balsa, I.M., Culp, W.T.N., Giuffrida, M.A., (2023). Effect of conventional multilevel brachycephalic obstructive airway syndrome surgery on clinical and videofluoroscopic evidence of hiatal herniation and gastroesophageal reflux in dogs. *Veterinary Surgery* 52, 238-248.
- Meola S.D. (2013). Brachycephalic airway syndrome. *Topics in Companion Animal Medicine* 28, 91-96.
- Pollard, R., (2012). Imaging evaluation of dogs and cats with dysphagia. *International Scholarly Research Notices* 238505, 15.
- Poncet, C.M., Dupre, G.P., Freiche, V.G., Bouvy, B.M., (2006). Long-term results of upper respiratory syndrome surgery and gastrointestinal tract medical treatment in 51 brachycephalic dogs. *Journal of Small Animal Practice* 47, 137-142.
- Poncet, C.M., Dupre, G.P., Freiche, V.G., Estrada, M.M., Poubanne, Y.A., Bouvy, B.M., (2005). Prevalence of gastrointestinal tract lesions in 73 brachycephalic dogs with upper respiratory syndrome. *Journal of Small Animal Practice* 46, 273-279.
- Pratschke, K.M., Bellenger, C.R., McAllister, H., Campion, D., (2001). Barrier pressure at the gastroesophageal junction in anesthetized dogs. *American Journal of Veterinary Research* 62, 1068-1072.
- Reeve, E.J., Sutton, D., Friend, E.J., Warren-Smith, C.M.R., (2017). Documenting the prevalence of hiatal hernia and oesophageal abnormalities in brachycephalic dogs using fluoroscopy. *Journal of Small Animal Practice* 58, 703-708.
- Vangrinsven, E., Broux O., Massart L., Claeys S., Clercx C., Billen F., (2021). Diagnosis and treatment of gastroesophageal junction abnormalities in dogs with brachycephalic syndrome. *Journal of Small Animal Practice* 62(3), 200-208.

