

ARTERIAL CATHETERIZATION AND VASCULAR ACCESS PORT IMPLANTATION FOR BLOOD SAMPLING AND CONTINUOUS BLOOD PRESSURE MEASUREMENT IN DOGS

Arteriële katheterisatie en "vascular access port" implantatie voor bloedstaalname en continue bloeddrukmeting bij de hond

I. Polis¹, Y. Moens², F. Gasthuys³, M. Tshamala¹, M. Risselada¹

¹Department of Small Animal Medicine and Clinical Biology,
Faculty of Veterinary Medicine, Ghent University, Salisburylaan 133, B-9820 Merelbeke, Belgium

²Department of Clinical Veterinary Sciences, Anesthesiology Unit,
Faculty of Veterinary Medicine, University of Berne, Länggasstrasse 124, CH-3012 Berne, Switzerland

³Department of Surgery and Anesthesia of Domestic Animals,
Faculty of Veterinary Medicine, Ghent University, Salisburylaan 133, B-9820 Merelbeke, Belgium

ABSTRACT

In the present study a modified method is described in which coated polyurethane catheters and a titanium vascular access port (VAP) with a silicone membrane were implanted into the femoral artery in forty dogs. This device enabled repeated arterial blood pressure measurement and blood sampling in conscious and anesthetized dogs for an average period of two weeks. The catheter was not removed by any of the dogs themselves, and few clinical problems were observed. An infection with *Pseudomonas aeruginosa* induced by a contaminated flush solution was diagnosed in four dogs. These dogs recovered rapidly after an appropriate antibiotic therapy.

The conclusion of the study is that this arterial catheterization technique with vascular access port in place over a two-week period is suitable and technically feasible for experimental protocols in dogs.

SAMENVATTING

In deze studie werd een gewijzigde chirurgische methode beschreven waarbij gecoate polyurethaan katheters en een "vascular access port" (VAP) met een silicone membraan geïmplanteerd werden in de femorale arterie bij 40 honden. Deze katheterisatietechniek gaf een arteriële toegangsweg gedurende een periode van 2 weken waardoor herhaalde arteriële bloeddrukmetingen en bloedafname makkelijk konden uitgevoerd worden bij geanestheerde en niet-gesedeerde honden. De katheters werden niet verwijderd door de honden zelf. Bovendien werden weinig andere klinische problemen opgemerkt. Een infectie met *Pseudomonas aeruginosa* tengevolge van een gecontamineerde spoelvoeistof trad op bij vier honden. Een snelle genezing werd bekomen met een aangepaste antibioticatherapie.

De beschreven arteriële katheterisatie met "vascular access port" is geschikt voor gebruik tijdens experimentele onderzoeksprotocollen bij de hond.

INTRODUCTION

Anaesthetic studies in experimental dogs often require repetitive blood sampling and blood pressure monitoring in unrestrained animals over a relatively long period of time. The repetitive puncturing of arteries and veins or multiple consecutive peripheral catheter placement is accompanied not only by techni-

cal problems and stress responses, but also by iatrogenically induced damage of the blood vessels, including thrombosis and sclerosis (Bagley and Flanders, 1990; Endres *et al.*, 1990; Grosse-Siestrup and Lajous-Petter, 1990; Mesfin *et al.*, 1988). Therefore, these methods are only suitable for a limited number of blood samples.

A potential option is the placement of a permanent intravenous or intra-arterial catheter combined with an implant, as mentioned in the literature (Abrams-Ogg *et al.*, 1992; Béliveau *et al.*, 1990; Evans *et al.*, 1994; Garner and Laks, 1985; Hai, 1982). However, the task of maintaining chronically indwelling catheters and avoiding destruction, dislodgment or infection of the catheters is often a challenge. Local infection, sepsis, migration, extravasation and early occlusion of the catheter are major complications of commonly used catheter implants (Evans *et al.*, 1994). Therefore, antibiotics are essential for preventing infection after implantation. Furthermore, as in humans, aseptic conditions during surgery and blood sampling are also of major importance (Burrows, 1982; Vazques and Jarrad, 1984). The catheter and vascular access port patency demands frequent flushing with heparinized saline.

Vascular access ports are not only helpful adjuncts for repetitive blood sampling and blood pressure monitoring, but they can also be used for infusions of antibiotics, fluids and blood products (Abrams-Ogg *et al.*, 1992; Garner and Laks, 1985). Moreover, cardiac output measurement and drug delivery directly into the intestinal tract are potential applications of vascular access ports in dogs (Lynch *et al.*, 1999; Meunier *et al.*, 1993). Only one study described the use of vascular access ports in cats for administering chemotherapy, though this technique is commonly used for vascular access in men with cancer (Henry *et al.*, 2002; Kuizon *et al.*, 2001). A major complication of this application is the risk of chemotherapy extravasation injuries leading to significant tissue damage and pain (Kassner, 2000).

The aim of the present study was to describe a modified surgical arterial catheterization technique in combination with the use of a vascular access port for repetitive blood sampling and blood pressure measurement during and after experimental anaesthetic protocols in dogs (Fig. 1).

MATERIALS AND METHODS

The study was approved by the Ethical Committee of the Faculty of Veterinary Medicine, Ghent University (file number 39/2000). Forty adult female Beagles of 11.97 ± 1.40 kg (mean \pm SD) from 1 to 2 years old were used in the study. The dogs were dewormed and vaccinated before the experiment. Clinical and blood examination one week before and the day of the experiment confirmed the good health status of the animals. Animals had free access to tap water and

commercial dog food (Advance™ Adult, Master Foods N.V., Belgium).

Anaesthetic protocol

The dogs were fasted 12 hours before surgical intervention. Acepromazine (0.05 mg/kg Placivet 2%, Codifar N.V., Wommelgem, Belgium) was administered intramuscularly as premedication. Anesthesia was induced 30 minutes later using propofol (4-6 mg/kg body weight Rapinovet, Mallinckrodt Veterinary, Aalst, Belgium) administered intravenously to effect. The dogs were intubated (endotracheal tube 6 mm ID, Rüschi, Germany) and connected to a commercial anaesthetic machine (Titus, Dräger, Lübeck, Germany) with a circle system delivering 1 L/min of oxygen. The dogs breathed spontaneously throughout the surgical procedure. An anaesthetic gas analyzer (Capnomac Ultima, Datex Engstrom Instrumentation Corp., Helsinki, Finland) and pulse oximeter (N-20PA Portable Pulse Oximeter, Nellcor Puritan Bennett Inc., Pleasanton, CA, USA) were used for non-invasive monitoring. No intravenous infusions were administered during anesthesia.

Anesthesia was maintained with propofol administered intravenously by an infusion pump (Ohmeda 9000 Syringe pump, Ohmeda, West Yorkshire, UK) at a dosage of 0.5 mg/kg/min. Analgesia and anesthesia of the hind quarters was assured with an epidural technique using a 50/50 (v/v) mixture of lidocaine 2% (Xyllocaine 2%, Astra Zeneca, Brussels, Belgium) and bupivacaine 0.5% (Marcaine 0.5%, Astra Zeneca, Brussels, Belgium) at a dosage of 1 ml/4 kg of body weight. Two dogs received half of the epidural dosage because the subarachnoid space was punctured. For additional postoperative analgesia, the dogs were treated with carprofen (4 mg/kg PO) for a period of 3 days, starting the day before surgery. The dog received a single injection of long-acting amoxicillin (15 mg/kg SC) (Duphamox LA, Fort Dodge, Brussels, Belgium) the day of catheter implantation.

Surgical procedure

After the dogs had been placed in left lateral recumbency, the right inguinal area, the medial side of the right knee and the backside of the dogs were surgically prepared. A 60 cm coated polyurethane catheter (Hydrocoat™ Catheter 3.5 Fr; Access™ Technologies, Skokie, USA) with a bead located 8 cm from the catheter tip and filled with heparinized saline (5 IU/ml of Heparine, Leo, Belgium) was used for arterial

catheterization. The catheter tip was transected obliquely and was grasped with a forceps (Semkin dressing forceps) for better handling. The catheter was occluded at the free end with a hemostatic clamp to prevent bleeding when inserting it into the femoral artery. A 4 cm incision was made through the skin and subcutis above the femoral groove. The femoral artery was exposed by separation of the sartorius and gracilis muscles starting in the femoral triangle. The artery was freed from the femoral nerve and vein by blunt dissection (Fig. 2). Hence, the femoral artery was elevated and occluded during the following surgical handling by gentle pulling on two sutures (Safil green 3/0, Braun, Melsungen, Germany) positioned under the artery (Fig. 3). Topical lidocain was administered to counteract the induced iatrogenic vasospasm of the femoral artery during handling. A small hole was made in the artery with a 19-gauge needle (19 G x 1"; 1.1 x 25 mm; Terumo Europe N.V., Leuven, Belgium) and the catheter tip was inserted about 8 cm into the artery in the direction of the aorta (Fig. 4). The proximal suture was used to fix the artery around the inserted catheter (Fig. 5). An additional suture was placed immediately behind the bead to assure an adequate ligation of the artery and the distal suture was used to ligate the femoral artery to the bead.

A second skin incision was made medial of the knee. The catheter was pulled subcutaneous from the femoral triangle to the knee with an atraumatic forceps (straight Rochester-Carmalt Haemostatic forceps). The catheter was secured using a single subcutaneous suture at the medial level of the knee. Finally, a paramedian incision was made proximal from the ilium on the back of the dog. A small amount of subcutaneous fat was removed allowing the formation of a suitable pocket for the titanium vascular access port (Access™ Technologies, Skokie, USA). The catheter was tunneled further subcutaneously from the knee to the backside of the dog with the same atraumatic forceps (Fig. 6). The vascular port was attached to the catheter allowing enough length for a so-called tension loop around the port (Fig. 7-8). Catheter patency was tested using heparinized saline and a Huber point needle (Posi-Grip Huber Point Needle 22 gauge x 0-3/4", Access™ Technologies, Skokie, USA) placed through the silicone membrane of the vascular access port. The vascular access port was sutured with 3 single sutures (Safil green 3/0, Braun, Melsungen, Germany) into the subcutaneous tissue.

After a final control of permeability, the catheter was filled with heparinized saline (200 IU/ml) and all skin incisions were closed with Safil (Fig. 9). The ca-

theters and implants were removed 17.9 ± 8.7 days after implantation (mean \pm SD) under a standardized isoflurane anesthesia.

Experimental design

A hemodynamic study was carried out in the period between the 2nd and the 6th day following catheter and vascular access port implantation. Measurements were performed for a period of 24 hours. The arterial catheter was flushed percutaneously through the silicone membrane of the vascular access port every two days before the experiment with 1 ml of heparinized saline (200 IU/ml). The vascular access port was used for arterial blood pressure measurement at several time points. This was done by perforating the membrane of the port through the skin with a Huber point needle. The needle was connected to an extension tube filled with heparinized saline and a pressure transducer (Vascumed N.V., Gent, Belgium) placed at the level of the heart. Mean, systolic and diastolic blood pressures were measured (Hellige Servomed SMV 104, Germany). Arterial blood for blood gas analysis was sampled using the same method.

Clinical observation and examination

A clinical examination, including recording of the rectal temperature, was carried out on a daily basis for each dog.

RESULTS

Anesthesia and surgery were uneventful. The surgical implantation time ranged from 35 to 75 minutes. All 40 dogs tolerated the sampling procedures (14 samples in 24 hours) well without external signs of discomfort. Blood sampling and blood pressure measurement were successful and easy to perform in all dogs.

Several complications were encountered. An inadvertent implantation of the catheter in the femoral vein was diagnosed in one dog. This dog had a swelling of the hind leg and venous blood (PaO₂: 33 mm Hg) could be sampled from the vascular access port. The catheter was removed and a period of one month was respected before a new catheter could be implanted in the femoral artery of the same side without problems. Another dog was lame in the surgically treated hind leg the day of the experiment, though without pain or swelling. Lameness disappeared spontaneously within 4 days without therapy. One dog removed the sutures of the inguinal wound without dama-

ging the arterial catheter. The wound was sutured again under local anesthesia with lidocain (Xylocaine 2%, Astra, Brussel, Belgium). Finally, a seroma occurred around the VAP in one of the dogs and was surgically treated by placing a Penrose drain (Penrose Tubing, Sherwood Medical, Tullamore, Ireland) after removal of the VAP.

The swelling caused no difficulties for blood sampling or blood pressure measurement.

The mean rectal temperature for all dogs was $39.3^{\circ}\text{C} \pm 0.48$ on the day of the experiment (2 to 6 days after catheter implantation). Four dogs had fever (more than 40.0°C) one to two days after catheter implantation. However, on clinical examination no

signs of lameness or inflammation at the catheter site were observed in these dogs. Samples for bacteriologic examination were taken from the heparinized flush solution used in these dogs. Contamination of the solution with *Pseudomonas aeruginosa* was found by a bacteriologic culture. An appropriate antimicrobial therapy guided by an antibiogram was done for 5 to 10 days with enrofloxacin SC (5 mg/kg/day) (Baytril 5%, Bayer, Leverkusen, Germany) and resulted in full clinical recovery. The arterial catheter and vascular access port of one of these dogs showed no bacteriological growth after surgical removal.

The catheters remained patent in all animals for at least 4.2 ± 2.2 days (mean \pm SD). After the experiment




Fig. 1. Vascular access port (Access™ Technologies, Skokie, USA).




Fig. 2. Surgical exposition of the femoral artery.
1. femoral vein and nerve
2. femoral artery.

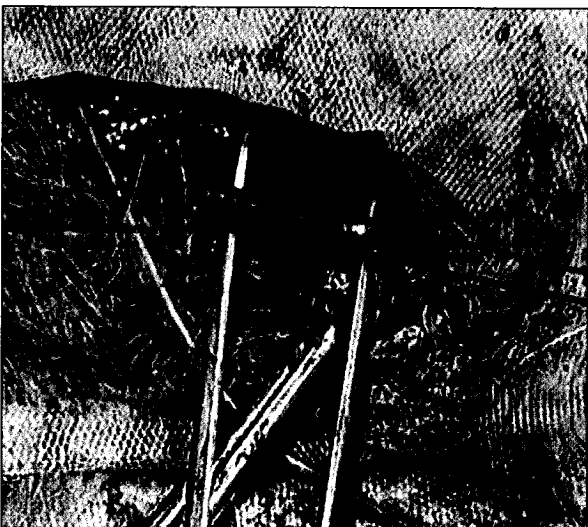


Fig. 3. Elevation of the femoral artery by two stay sutures.

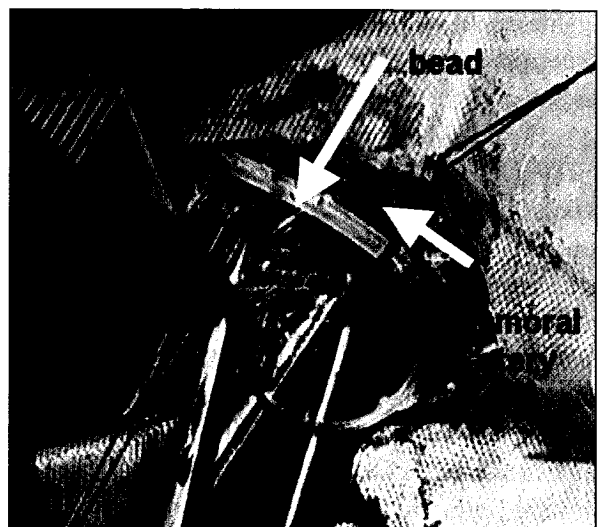


Fig. 4. Insertion of the catheter into the femoral artery.

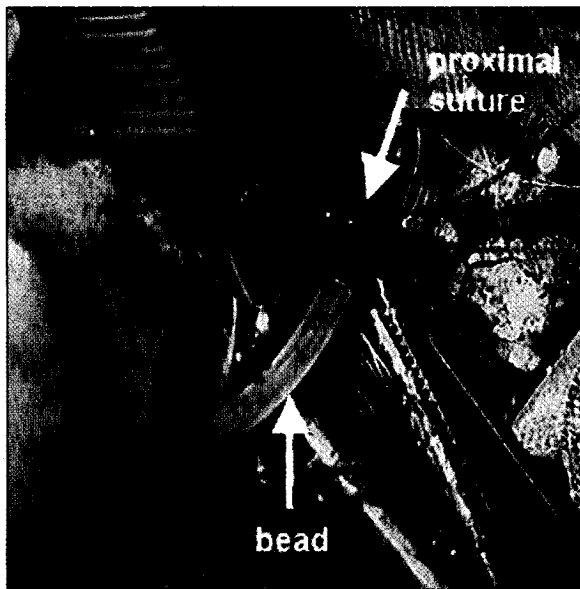


Fig. 5. Ligation of the femoral artery around the inserted catheter.

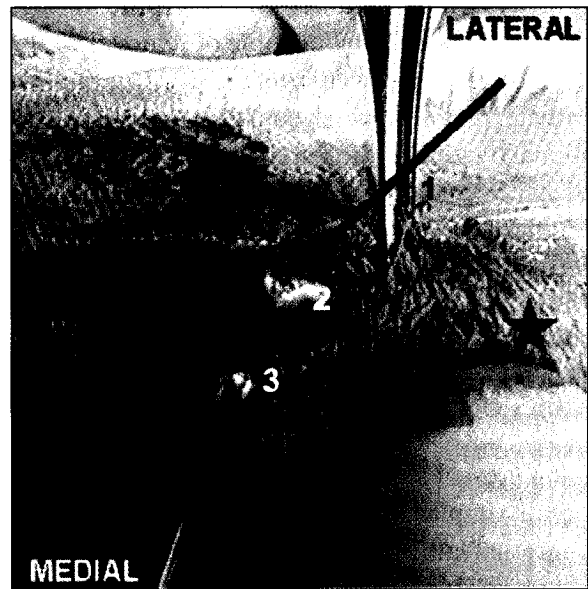


Fig. 6. Subcutaneous tunneling from the medial knee incision to the lumbar incision.

* Knee. 1. Subcutaneous tunneling. 2. Top of the atraumatic forceps covered by subcutaneous tissue. 3. Catheter.

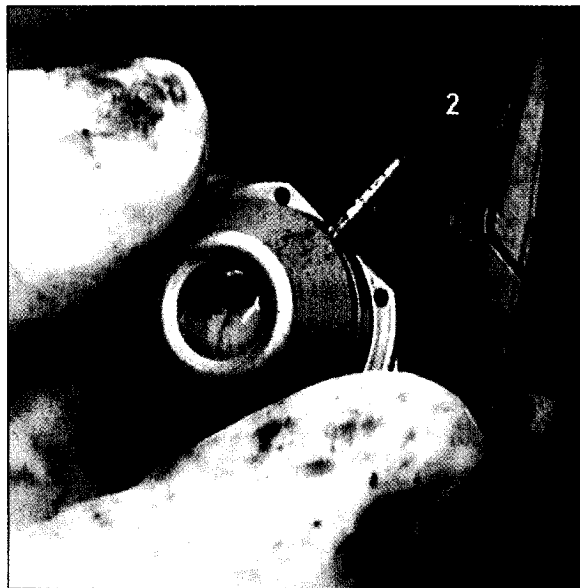

Fig. 7. Attaching the vascular access port to the catheter. 1. Vascular access port. 2. Coated polyurethane catheter.

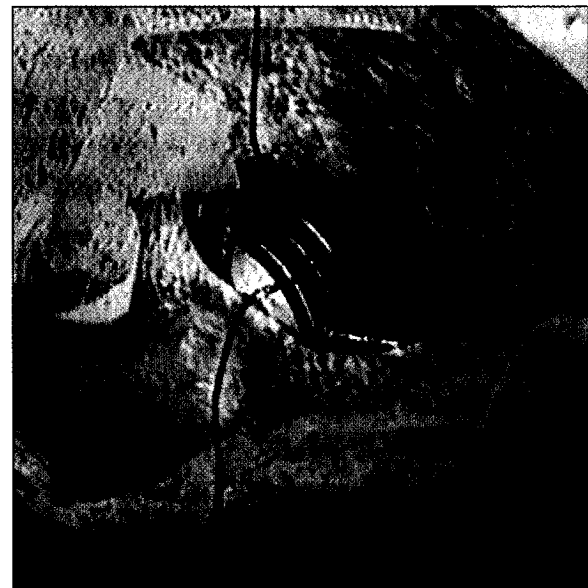

Fig. 8. Insertion of the vascular access port in a subcutaneous pocket.



Fig. 9. Testing of catheter patency.

the catheters were not further flushed in order to have an obstructed catheter by the time of removal 17.9 ± 8.7 days after implantation (mean \pm SD). This facilitated catheter removal, which could be done without an additional ligation of the femoral artery. After removal of catheters and vascular access ports, the skin incisions healed rapidly. No specific problems induced by the ligation of the femoral artery were encountered over time.

DISCUSSION

In the present study a permanent arterial catheter and totally implantable vascular access port system were inserted into the femoral artery of dogs for repetitive arterial blood sampling and invasive arterial blood pressure measurement at several time intervals during experimental procedures. The surgical technique was slightly modified from previously published studies (Evans *et al.*, 1994; Garner and Laks, 1985; Grosse-Siestrup and Lajous-Petter, 1990).

Coated polyurethane catheters in combination with titanium vascular access ports were used in the present study. Compared to polyvinyl chloride, silicone and Teflon catheters, heparinized polyurethane was proven to be the least thrombogenic of all materials (Solomon *et al.*, 1987). Moreover, silicone carries a greater risk for subcutaneous infection, as well as for inflammation and kinking (Sheretz *et al.*, 1995). In the present study, the catheter was inserted about 8 cm into the femoral artery. Immediately after surgical handling of the artery, a marked collapse of the vessel was observed, which made the insertion of the catheter difficult. Topical lidocain was administered to counteract the iatrogenically induced vasospasm (Kim *et al.*, 1996; Wadstrom and Gerdin, 1991). To facilitate catheter implantation, the catheter tip was cut off obliquely and an opening was made in the vessel wall. The efficiency of catheter placement improved with experience. No problems of hind limb vascularization were observed after occlusion of the distal part of the femoral artery; most likely a sufficient quantity of collateral vessels rapidly assured adequate circulation of the hind limb (Schaper and Ito, 1996). All catheters remained patent during the experiment. The incision wounds healed rapidly in the majority of the dogs, particularly the femoral wound. This was also reported in similar studies (e.g. Hai, 1982).

The vascular access port consisted of a titanium base with multiple holes for securing it to the surrounding tissue and a central silicone diaphragm for punc-

turing. Multiple membrane punctures are guaranteed without vascular access port leakage when using Huber point needles with off-center tips. The port was secured on the lumbar region in a separate pocket away from the femoral incision to minimize the potential for incisional swelling, pain or inflammation, which could interfere with multiple port function. The lumbar port position also facilitated blood sampling. In previous studies the vascular access port was implanted in the right hemi-cervical region of the dogs, thus facilitating access to the jugular vein (Evans *et al.*, 1994).

Blood sampling and blood pressure measurement were easy to carry out, requiring only minimal restraint. In most trained animals one person could do the blood sampling; the assistance of a second person was necessary only in nervous dogs. For blood pressure measurement, previous flushing with heparinized saline was advisable to get a sharp blood pressure waveform on the hemodynamic monitor.

The rectal temperature remained within acceptable ranges in most dogs. However, some dogs had a transient slightly increased temperature after catheter implantation. The impact of anesthesia and surgery and the implantation of a foreign body (catheter and VAP) certainly had an impact on body temperature. A slight transient increase in body temperature was also observed in similar studies after intravenous catheterization in pigs (Pijpers *et al.*, 1989; Van Leengoed *et al.*, 1987). Four dogs had an abnormal and persistent increase in body temperature ($> 40^{\circ}\text{C}$) without signs of lameness or local infection around the femoral artery or vascular access port. In human studies the most likely source of catheter infection was reported to be the normal bacterial skin flora, which can gain access during implantation of the catheter (Eykeyn, 1984). The etiology of the infection in the present study was a contamination of the heparinized saline solution with *Pseudomonas aeruginosa*, although the flush solution was prepared weekly and stored aseptically. After an appropriate antibiotic treatment with enrofloxacin, complete recovery was obtained. The anaesthetic experiment was postponed for several days, however, until the body temperature of the dogs returned to normal values. Heparin solution was renewed daily to prevent this phenomenon. Bacteremia were also occasionally observed (and successfully treated) in similar studies describing totally implantable catheter systems in dogs (Grosse-Siestrup and Lajous-Petter, 1990).

Other problems such as suture removal and seroma formation were of minor clinical importance, being easily treated using standard techniques (Garner and

Laks, 1985). Since the distal part of the femoral artery was occluded, the artery could probably not be reused for the same purpose later.

In conclusion, the above described modified arterial catheterization technique with vascular access port is suitable and technically feasible for experimental hemodynamic protocols in dogs. This catheter system can be applied to improve the well-being of experimental animals, to facilitate experimental work and to simplify serial blood sampling, though it requires proper handling and aseptic blood sampling procedures.

REFERENCES

- Abrams-Ogg A.C.G., Kruth S.A., Carter R.F., Valli V.E.O., Kamel-Reid S., Dubé I.D. (1992). The use of an implantable central venous (Hickman) catheter for long-term venous access in dogs undergoing bone marrow transplantation. *Canadian Journal of Veterinary Research* 56, 382-386.
- Bagley R.S., Flanders J.A. (1990). The use of totally implantable vascular access systems. *Compendium on Continuing Education for Practicing Veterinarians* 12, 22-27.
- Béliveau L., Fortier P., Péronnet F., Trudeau F., Nadeau R. (1990). A method for long-term catheterization of various capacitance vessels in dogs. *Laboratory Animal Science* 40, 97-100.
- Burrows C.F. (1982). Inadequate skin preparation as a cause of intravenous catheter-related infection in the dog. *Journal of the American Veterinary Medical Association* 180, 747-749.
- Endres D.R., Akimoto R., Lavelle-Jones M., Wahlstrom H.E. (1990). A simple method of maintaining chronic vascular access in the dog. *Journal of Investigational Surgery* 3, 267-278.
- Evans K.L., Smeak D.D., Couto C.G., Hammer A.S., Gaynor J.S. (1994). Comparison of two indwelling central venous access catheters in dogs undergoing fractionated radiotherapy. *Veterinary Surgery* 23, 135-142.
- Eykeyn S.J. (1984). Infection and intravenous catheters. *Journal of Antimicrobial Chemotherapy* 14, 203-208.
- Garner D., Laks M.M. (1985). New implanted chronic catheter device for determining blood pressure and cardiac output in conscious dogs. *American Journal of Physiology* 249, 681-684.
- Grosse-Siestrup C., Lajous-Petter A.M. (1990). Totally implantable catheter system in the dog. *Journal of Investigational Surgery* 3, 373-385.
- Hai N.P. (1982). Technical notes on long-term vascular access for more than 12 months in conscious dogs. *Journal of Pharmacological Methods* 7, 57-64.
- Henry C.J., Russell L.E., Tyler J.W., Buss M.S., Seguin B., Cambridge A.J., Moore M.E. (2002). Comparison of hematologic and biochemical values for blood samples obtained via jugular venipuncture and via vascular access ports in cats. *Journal of the American Veterinary Medical Association* 220, 482-485.
- Kassner E. (2000). Evaluation and treatment of chemotherapy extravasation injuries. *Journal of Pediatric Oncology Nursing* 17, 135-148.
- Kim D.C., Chen D., Perrotta V.J., Shuman C.A., Wendling W.W., Haraka C., Mitra A. (1996). Porcine gastropiploic artery as an in vitro experimental model to study vasodilators in microsurgery. *Annals of Plastic Surgery* 36, 502-507.
- Kuizon D., Gordon S.M., Dolmatch B.L. (2001). Single-lumen subcutaneous ports inserted by interventional radiologists in patients undergoing chemotherapy: incidence of infection and outcome of attempted catheter salvage. *Archives of Internal Medicine* 161, 406-410.
- Lynch T.M., Morris T.H., Dix J., Nelson P.R. (1999). Bacterial counts in canine duodenal fluid after exposure to saline, sodium bicarbonate and hypertonic dextrose solutions used to maintain patency of chronically implanted catheters. *Laboratory Animals* 33, 143-148.
- Mesfin G.M., Higgins M.J., Brown W.P., Rosnick D. (1988). Cardiovascular complications of chronic catheterization of the jugular vein in the dog. *Veterinary Pathology* 25, 492-502.
- Meunier L.D., Kissinger J.T., Marcello J., Nichols A.J., Smith P.L. (1993). A chronic access port model for direct delivery of drugs into the intestine of conscious dogs. *Laboratory Animal Science* 43, 466-470.
- Pijpers A., Noordhuizen-Stassen E.N., Goedegebuure S.A., van Dobbenburgh O.A., Roosendaal M., Cornelissen A.H.M., Verheijden J.H.M. (1989). Intravenous catheterisation of conventional pigs without application of antimicrobial agents. *Veterinary Quarterly* 11, 216-221.
- Schaper W., Ito W.D. (1996). Molecular mechanisms of coronary collateral vessel growth. *Circulation Research* 79, 911-919.
- Sheretz R.J., Carruth W.A., Morosk R.D., Espeland M.A., Johnston R.A., Solomon D.D. (1995). Contribution of vascular catheter material to the pathogenesis of infection: the enhanced risk of silicone in vivo. *Journal of Biomedical Material Research* 29, 635-645.
- Solomon D.D., Arnold W.L., Martin N.D., Lentz D.J. (1987). An in vivo model for the evaluation of catheter thrombogenicity. *Journal of Biomedical Material Research* 21, 43-57.
- Van Leengoed L.A.M.G., De Vrey P., Verheijden J.H.M. (1987). Intravenous catheterisation in pigs: an evaluation of two methods. *Journal of Veterinary Medicine* 34, 649-656.
- Vazques R.M., Jarrad M.M. (1984). Care of the central venous catheterisation site: the use of transparent polyurethane film. *Parenteral and Enteral Nutrition* 8, 181-186.
- Wadstrom J., Gerdin B. (1991). Modulatory effects of topically administered lidocaine and pentobarbital on traumatic vasospasm in the rabbit ear artery. *British Journal of Plastic Surgery* 44, 341-347.