

## A LOCAL EPIDEMIC OF EQUINE HERPESVIRUS 1-INDUCED NEUROLOGICAL DISORDERS IN BELGIUM

*Een lokale epidemie van equiene herpesvirus 1-geïnduceerde zenuwstoornissen in België*

K. van der Meulen, G. Vercauteren, H. Nauwynck, M. Pensaert

Department of Virology, Parasitology and Immunology  
Faculty of Veterinary Medicine, Ghent University,  
Salisburylaan 133, 9820 Merelbeke, Belgium  
Karen.vandermeulen@UGent.be

### SUMMARY

This case report describes a severe outbreak of equine herpesvirus 1 (EHV-1)-induced neurological disorders in horses on a riding school in Belgium. On at least 10 premises that had been in direct or indirect contact with the riding school during the onset of the outbreak, fever was reported. On 7 of these in-contact premises, horses also suffered from neurological disease. Of all the horses, 42 % showed fever and anorexy. Neurological disorders were observed in 15 % of all the horses. The disorders consisted mainly of ataxia and paralysis of hind limb and tail (76 % of the neurologically affected horses). Cerebral disorders such as blindness, torticollis and severe apathy were observed in 24 % of the neurologically affected horses. The mortality during the epidemic was 10 %. EHV-1 was isolated from blood mononuclear cells of two horses and identified using EHV-1-specific monoclonal antibodies.

### SAMENVATTING

In deze casuïstiek wordt een ernstige uitbraak beschreven van equiene herpesvirus 1 (EHV-1)-geïnduceerde zenuwstoornissen bij paarden op een manege in België. Op tenminste 10 bedrijven die tijdens het begin van de uitbraak direct of indirect contact hadden gehad met de manege, werd koorts gerapporteerd. Zeven van deze bedrijven werden eveneens getroffen door zenuwstoornissen. Tweeënveertig procent van alle paarden vertoonde koorts en anorexie. Neurologische stoornissen werden waargenomen bij 15 % van alle paarden. De neurologische stoornissen waren vooral ataxie en paralyse van de achterbenen en de staart (76 % van de neurologisch aangetaste paarden). Cerebrale stoornissen, zoals blindheid, torticollis en apathie, werden waargenomen bij 24 % van de neurologisch aangetaste paarden. De mortaliteit tijdens de uitbraak bedroeg 10 %. EHV-1 werd geïsoleerd uit de mononucleaire bloedleukocyten van twee paarden en geïdentificeerd met behulp van EHV-1-specifieke monoklonale antistoffen.

### INTRODUCTION

Equine herpesvirus 1 (EHV-1), a member of the subfamily *Alphaherpesvirinae* within the family *Herpesviridae*, is a major pathogen of horses. After infection, EHV-1 replicates in the upper respiratory tract and, subsequently, induces a cell-associated viremia. Carried by infected blood mononuclear cells, EHV-1 then spreads to internal organs such as the pregnant uterus or the nervous system, where it ultimately may induce abortion or neurological disorders (Allen and Bryans, 1986). EHV-1 infection is the most important

cause of infectious abortion worldwide, whereas neurological disorders occur more rarely. However, during the last decade, EHV-1-induced neurological disorders have been reported with increasing frequency (McCartan *et al.*, 1995; Friday *et al.*, 2000; van Maanen *et al.*, 2001; Stierstorfer *et al.*, 2002). In the first trimester of 2003, 6 outbreaks had already been reported in the UK (Church, 2003b) and one severe outbreak in Kentucky and Ohio (Church, 2003a). The incubation period of EHV-1-induced neurological disorders is 6 to 8 days (Jackson and Kendrick, 1971; Jackson *et al.*,

1977). Disorders may be preceded by fever, general malaise, respiratory disorders and/or abortion. Horses of all ages and breeds may be affected, although pregnancy or recent foaling appear to be predisposing (Greenwood and Simson, 1980; McCartan *et al.*, 1995; Goehring and Sloet van Oldruitenborgh-Oosterbaan, 2001). Neurological disorders may be seen in individual horses or in multiple horses during an outbreak. The onset of neurological disease is usually acute. Clinical signs vary in severity from mild hind limb incoordination to severe paralysis and quadriplegia. Additionally, distal limb oedema, head tilt, oedema of the testes, paralysis of the tail, penis prolaps and fecal and/or urinary incontinence may be observed. Horses that do not develop quadriplegia have good chances for recovery, although this may take several weeks. Horses that have been unable to stand for 24 hours have a poor prognosis (van Maanen *et al.*, 2001).

Until now, outbreaks of nervous system disorders in Belgium have occurred only sporadically and have mostly involved a limited number of horses on a single site (van der Meulen *et al.*, 2000). This paper describes a severe epidemic of EHV-1-induced neurological disorders in February 2003, which affected a Belgian riding school and at least 10 premises that had been in direct or indirect contact with the riding school.

## CASE HISTORY

### Primary outbreak on the riding school

The riding school herd consisted of 41 horses and ponies of both sexes and various ages and breeds. No pregnant mares were present. Twenty-eight horses and ponies were housed in adjacent individual box stalls (1-29), whereas an additional 13 ponies were housed in adjacent standing stalls (a-n). All stalls were located in a single barn (Figure 1). Even though some horses at the riding school had been irregularly vaccinated against EHV-1/EHV-4, there was no strict vaccination strategy for the purpose of minimizing the risk of EHV infections.

On February 6, a horse (A) grazing on a meadow of the riding school was pyrexemic and began coughing. Two days later, horse B showed anorexia (Figure 1). Horse B had been in direct contact with horse A in the barn. By February 9, both horses A and B were again clinically normal and horse B attended the jumping event that was held at the riding school that day.

On February 10, horse C became febrile and showed ataxia of the hind limbs and tail. Since at that point no one suspected an EHV-1 infection, the riding school remained open for horses from other premises. However, on February 13 horse B became ataxic and 8 other horses (D-K) showed anorexia and fever. The clinical condition of horse C rapidly deteriorated; it became recumbent on February 14 and was subsequently euthanized. At this time, the riding school instituted a quarantine. No horses were moved on or off the property and riding lessons were cancelled. All owners of non-resident ponies and horses that had attended the jumping event on February 8 and 9 were queried, but none of the animals appeared to have developed clinical signs of EHV-1 infection. Horse owners that had visited the school with their horses during riding lessons between February 10 and February 14 were advised to close their premises.

On February 15, horses E and G showed high fever ( $> 40^{\circ}\text{C}$ ) as well as paralysis, and both horses had to be euthanized within 12 hours. On February 16, horse F developed symptoms similar to those of horses E and G and had to be euthanized. Horse I developed severe cerebral disorders such as blindness, torticollis and apathy, but was not recumbent. Additionally, horse H became ataxic. Horse I was euthanized on February 17, due to its poor clinical condition.

Between February 18 and February 25, an additional horse (L) became febrile ( $38.5^{\circ}\text{C}$ ) but no neurological disorders were reported. On February 26, however, pony M, which had been housed at the riding school since February 10, suddenly showed severe ataxia and blindness and was euthanized. None of the ponies housed in the standing stalls developed clinical signs of an EHV-1 infection.

From February 26 onward, no more clinical cases occurred at the riding school. Horses B and H were still ataxic at that point, but in the course of the following three weeks their condition significantly improved. Quarantine was lifted on March 14.

Table 1 summarizes the number of horses showing clinical signs. Figure 2 summarizes the course of the disease at the riding school. Two distinct syndromes of neurological disease were observed. One syndrome was characterized by high fever ( $40\text{--}41^{\circ}\text{C}$ ) for two or three successive days and, afterwards, by ataxia of the hind quarters. The other syndrome was characterized by fever of  $40\text{--}41^{\circ}\text{C}$ , accompanied by paralysis or severe cerebral disorders. Infected horses that remained free of neurological disease developed only slight febrile responses of  $38.3\text{--}38.5^{\circ}\text{C}$ .

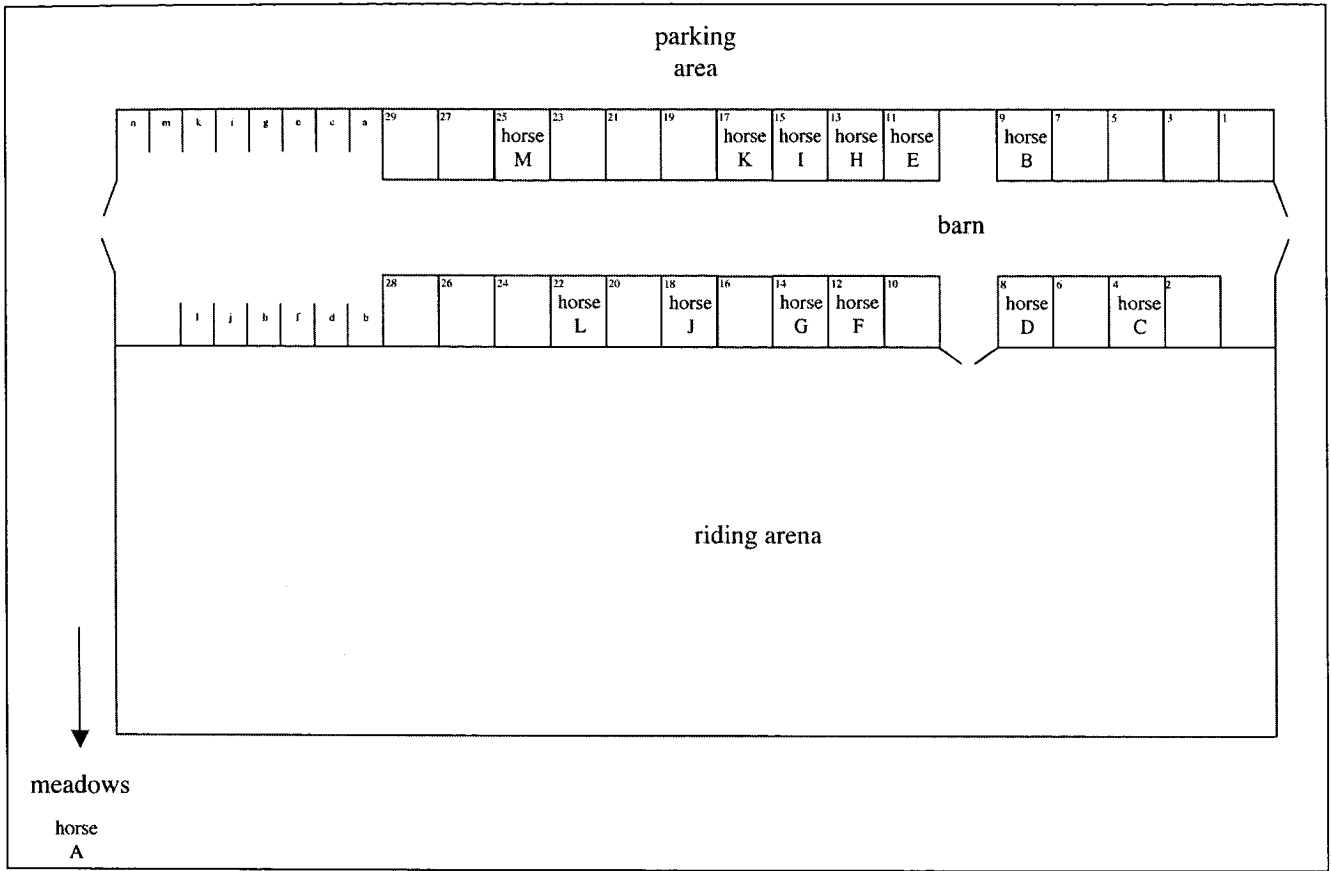


Figure 1. Schematic overview of the barn on the riding school.

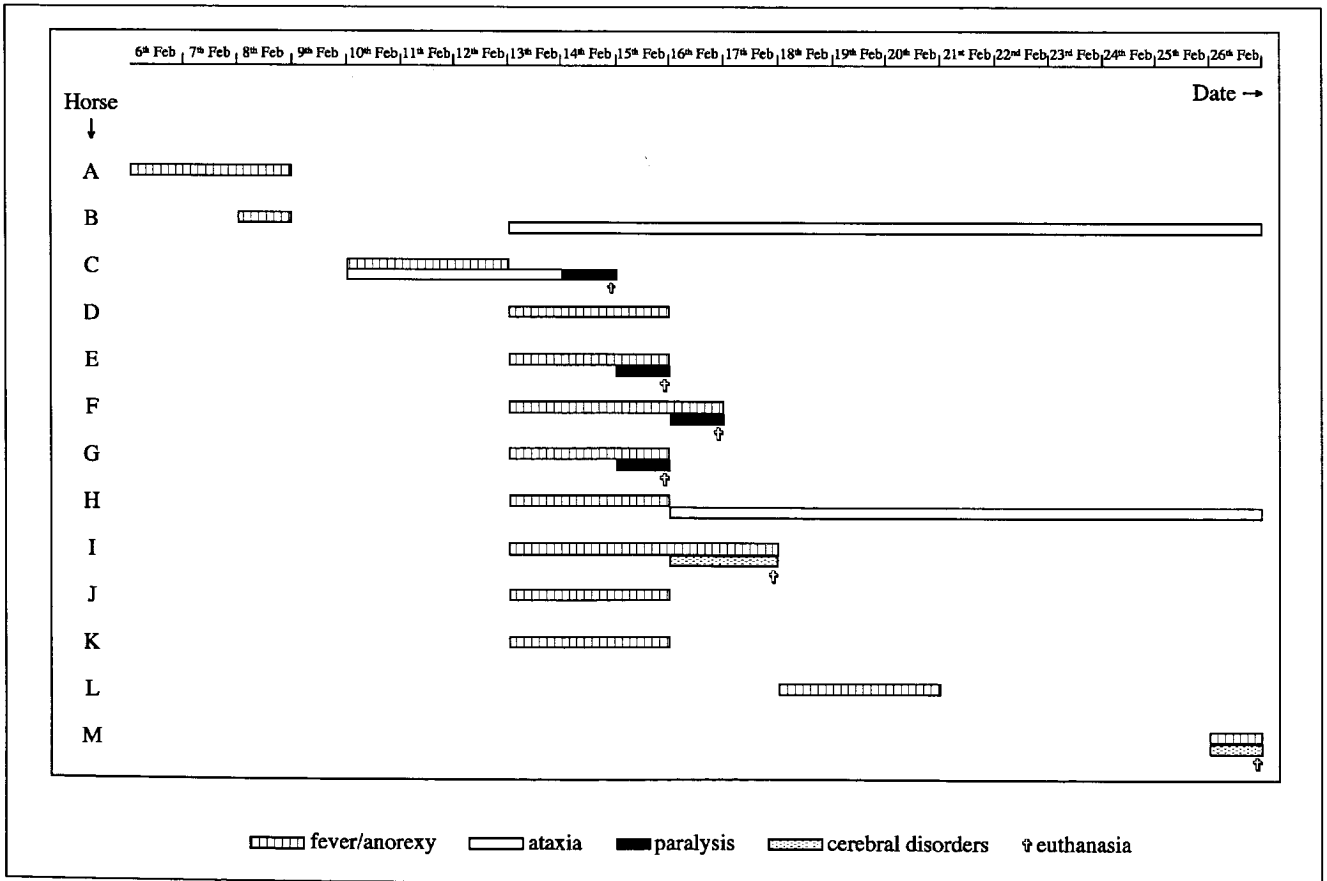


Figure 2. The course of EHV-1-induced disease on the riding school.

**Table 1. Number of horses affected by EHV-1 infection at the riding school and on the in-contact premises 1-10.**

Premises	Total no. of horses	No. of horses with					No. of euthanized horses
		Fever	Neurological disorders			Abortion / Neonatal death	
			Ataxia of hind quarters	Paralysis	Cerebral disorders		
Riding school	41	11	4	4	2	0	6
Premises 1	7	1	1	0	0	0	0
Premises 2	4	1	0	0	0	0	0
Premises 3	20	20	1	0	0	2	0
Premises 4	6	1	0	1	0	0	1
Premises 5	16	4	0	1	1	1	1
Premises 6	7	4	0	0	0	2	0
Premises 7	4	2	1	0	0	0	0
Premises 8	4	1	0	0	0	0	0
Premises 9	1	1	0	1	0	0	1
Premises 10	1	1	0	1	0	0	1
All (%)	111 (100%)	47 (42%)	5 (4.5%)	8 (7%)	4 (3.5%)	5 (4.5%)	10 (9%)

### Secondary outbreaks on other premises

Horses from other premises frequently visited the riding school during riding lessons or competitions and had direct contact with animals housed at the riding school while being saddled in the barn or being ridden in the riding arena. From February 15 onward, at least 9 of these premises (1-9) that had been in direct contact with the riding school between February 10 and February 14 reported fever in 35 out of a total of 69 horses. Additionally, a premise (10) that had been in contact with premise 3 also reported fever. An overview of the number of horses showing clinical signs indicative of EHV-1 infection on the in-contact premises is presented in Table 1. On a total of 7 of the in-contact premises, 8 horses developed nervous system disorders. On three in-contact premises (3, 5 and 6), a total of five abortions or neonatal foal deaths occurred within a time period of approximately one month after the febrile period. Whether these abortions or foal deaths were related to the EHV-1-induced

epidemic of neurological disorders remains undetermined, since no virological examination was performed.

### VIROLOGICAL EXAMINATION

Blood samples were collected from three horses housed on premises 1, 7 and 8, respectively. All three horses showed high fever ( $> 40^{\circ}\text{C}$ ) at the time of sampling. The two horses housed on premises 1 and 7 also showed ataxia.

Virus isolation was performed by cocultivation of blood mononuclear cells on rabbit kidney (RK13) cells. For this purpose, blood mononuclear cells were isolated from whole blood by means of density centrifugation on Ficoll Paque and, subsequently, inoculated on full-grown monolayers of RK13 cells. Monolayers were incubated at  $37^{\circ}\text{C}$  in an atmosphere containing 5%  $\text{CO}_2$  and examined daily for the presence of cytopathic effects. The formation of syncytia, which is highly indicative of an EHV-1 infection,

was observed after 3-5 days of incubation for both ataxic horses. Subsequently, the isolated virus was identified as EHV-1 by means of an indirect immunofluorescence staining using the EHV-1-specific mouse monoclonal antibody 13B2 directed against EHV-1 glycoprotein M.

No serological or pathological examination was performed.

## TREATMENT

On 5 of the premises, the horses were treated with the anti-herpesviral agent acyclovir (3x 800 mg/ day/ horse p.o. for a period of one week) either at the onset or during the occurrence of clinical signs. At least two premises also treated their horses with dexamethasone (2x 7.5 mg/day/horse IV for 2 days, followed by 1x 10 mg/day/horse IV for 5 days) to reduce inflammatory responses. All horses at the riding school were injected with Eqstim® Immunostimulant (ImmunoVet Inc., Florida, USA) (2x 2 ml/horse IV with a two-day interval), which has been reported to enhance the cell-mediated immunity.

## DISCUSSION

The present paper reports an outbreak of neurological disease at a Belgian riding school in February 2003. Additionally, fever indicative of EHV-1 infection was noted on 10 premises that had been in direct or indirect contact with the riding school during the onset of the outbreak. On 7 of these in-contact premises, horses also suffered from neurological disease. The lack of cases among the ponies in the standing stalls was likely due to lack of nose-to-nose contact between these animals and visiting horses in the barn, as well as to the fact that the standing stalls were located far away from the index cases.

One important feature of the present epidemic was the rapid occurrence of cerebral disorders such as blindness, torticollis and severe apathy in 4 out of 17 (24%) of the horses with neurological disorders. Severe cerebral disorders are an uncommon manifestation of EHV-1-induced neurological disease, having been reported only sporadically during field infections with EHV-1 (Carrol and Westbury, 1985; McCartan *et al.*, 1995; Friday *et al.*, 2000). Why the current outbreak in Belgium was accompanied by such a high number of horses showing cerebral disorders remains unclear. Earlier studies demonstrated that different strains of EHV-1 display different levels of virulence

in terms of their ability to induce nervous system disorders (Mumford *et al.*, 1994). This difference in virulence was associated with the degree of endotheliotropism of the respective EHV-1 strains (Smith *et al.*, 2000).

During the present epidemic, two syndromes of neurological disorders were observed. One syndrome took a progressive course and was characterized by fever of 40-41 °C for two or three successive days and, afterwards, by ataxia of the hind quarters. Affected horses did not become recumbent and they survived the infection. The other, more acute syndrome was characterized by fever of 40-41 °C and was accompanied by paralysis or severe cerebral disorders. The poor clinical condition of the affected horses necessitated euthanasia within 1 or 2 days.

How the present epidemic started is not known. It cannot be excluded that a horse at the riding school underwent reactivation of latent EHV-1 and, consequently, may have been a source of infectious virus for other horses (Edington *et al.*, 1985; van Maanen *et al.*, 2000). The reactivation of latent virus may be induced by stress situations such as transport (Burrows and Goodridge, 1984; van Maanen *et al.*, 2001) or by immunosuppression after treatment with corticosteroids (Edington *et al.*, 1985; Gibson *et al.*, 1992a; Slater *et al.*, 1994).

Since the outbreak was preceded by slight respiratory disorders in horse A on February 6, it may be hypothesized that this horse reactivated and initiated the outbreak. However, since many horses from other premises visited the riding school daily, it is also possible that a visiting horse introduced infectious virus to the riding school. Secondary spread of EHV-1 to other premises occurred as a consequence of direct contact between affected horses belonging to the riding school and visiting horses, except for the horse at location 10. This underlines the fact that EHV-1 infection spreads primarily by direct contact. Affected horses should, therefore, immediately be separated from other horses at the onset of clinical signs and the movement of horses on and off an affected premise should be restricted. It is advised to institute control measures as soon as a premise is clinically suspected of EHV-1 neurological disease, since a virological diagnosis is time consuming and difficult to obtain.

During the epidemic, horses on several premises were treated orally with acyclovir, an antiviral nucleoside analogue. *In vitro* studies demonstrated that nucleoside analogues are effective against EHV-1 in cell culture (Sakamoto, 1990; de la Fuente *et al.*, 1992; De Clercq *et al.*, 1996). Moreover, *in vivo* experiments

using the nucleoside analogue (S)-1-(3-Hydroxy-2-phosphonylmethoxypropyl)cytosine (HPMPC or Cidofovir) suggested that subcutaneous administration of the product may be active against EHV-1 in horses as well (Gibson *et al.*, 1992b). Indeed, a single subcutaneous administration of HPMPC of 20 mg/kg on the day of infection markedly reduced clinical signs and nasal excretion of virus following intranasal inoculation with EHV-1. When HPMPC was administered at a dose of 1 mg/kg on 0 and 3 days post inoculation, no effect was seen in terms of the clinical signs, but nasal excretion of the virus was reduced. Even though it appeared that no additional cases of neurological disease occurred on the premises after the onset of the oral acyclovir treatment during the present epidemic, it is difficult to evaluate the benefit of this treatment for neurological disorders, especially since there were no untreated control animals on the premises. Similarly, the role of Eqstim Immunostimulant, a biological response modifier containing inactivated *Propionibacterium acnes*, which has been described for the treatment of non-specific respiratory disease in horses (Evans *et al.*, 1988; Vial *et al.*, 1990), could not be determined.

Horses were also treated with dexamethasone, a long-acting corticosteroid, in order to reduce the inflammatory response in the nervous system. However, considerable care should be taken when treating horses with corticosteroids during an outbreak of EHV-1 disease. They induce immunosuppression and may reactivate EHV-1 in latently infected horses (Edington *et al.*, 1985; Slater *et al.*, 1994), and are therefore even contra-indicated.

Except for the horses on premises 3 and 8, most horses affected during the current epidemic were either infrequently vaccinated or not at all. However, it is important to note that vaccination implies no guarantee against the occurrence of neurological disease and, in particular, not against abortion. Indeed, EHV-1 neurological disease has been described in horses on well-vaccinated farms (Friday *et al.*, 2000; van der Meulen *et al.*, 2000). Up till now, the effect of vaccination for the prevention of EHV-1 neurological disease remains unclear. Further knowledge of the pathogenesis of and immunity to EHV-1 infection seems indispensable.

#### ACKNOWLEDGEMENTS

The authors wish to thank Ivo Vaes, the veterinary surgeon of the riding school, for providing the detailed

information on the outbreak and Dr. M. Yeargan of the Gluck Equine Research Center for supplying the monoclonal antibody 13B2 to identify the EHV-1 isolate.

#### LITERATURE

- Allen G.P., Bryans J.T. (1986). Molecular epizootiology, pathogenesis, and prophylaxis of equine herpesvirus-1 infections. *Progress in Veterinary Microbiology and Immunology* 2, 78-144.
- Burrows R., Goodridge D. (1984). Studies of persistent and latent equid herpesvirus-1 and herpesvirus-3 infections in the Pirbright pony herd. In: Wittmann, G., Gaskell, R. M., Rziha, H.-J. (eds.). *Latent herpesvirus infections in veterinary medicine*. Martinus Nijhoff, The Hague, pp. 307-319.
- Carroll C.L., Westbury H.A. (1985). Isolation of equine herpesvirus 1 from the brain of a horse affected with paresis. *Australian Veterinary Journal* 62, 345-346.
- Church S.L. (2003a). Ohio EHV-1 outbreak; Strain might be atypical. *Internet reference: www.thehorse.com/advancedsearch.asp?aid=81&nid=6&n=Equine+Herpesvirus+%28EHV%29&case=1*.
- Church S.L. (2003b). Details of the U.K. EHV-1 outbreak. *Internet reference: www.thehorse.com/advancedsearch.asp?aid=81&nid=6&n=Equine+Herpesvirus+%28EHV%29&case=1*.
- De Clercq E. (1996). Therapeutic potential of Cidofovir (HPMPC, Vistide) for the treatment of DNA virus (i.e. herpes-, papova-, pox- and adenovirus) infections. *Verhandelingen - Koninklijke Academie voor Geneeskunde van België* 58, 19-47.
- de la Fuente R., Awan A.R., Field H.J. (1992). The acyclic nucleoside analogue penciclovir is a potent inhibitor of equine herpesvirus type 1 (EHV-1) in tissue culture and in a murine model. *Antiviral Research* 18, 77-89.
- Edington N., Bridges C.G., Huckle A. (1985). Experimental reactivation of equid herpesvirus 1 (EHV 1) following the administration of corticosteroids. *Equine Veterinary Journal* 17, 369-372.
- Evans D.R., Hartgrove T.B., Rollins J.B. (1988). Inactivated *P. acnes* (ImmunoRegulin®) as adjunct to conventional therapy in the treatment of equine respiratory disease. *Equine Practice* 10, 17-21.
- Friday P.A., Scarratt W.K., Elvinger F., Timoney P.J., Bonda A. (2000). Ataxia and paresis with equine herpesvirus type 1 infection in a herd of riding school horses. *Journal of Veterinary Internal Medicine* 14, 197-201.
- Gibson J.S., Slater J.D., Awan A.R., Field H.J. (1992a). Pathogenesis of equine herpesvirus-1 in specific pathogen-free foals: primary and secondary infections and reactivation. *Archives of Virology* 123, 351-366.
- Gibson J.S., Slater J.D., Field H.J. (1992b). The activity of (S)-1-[(3-hydroxy-2-phosphonyl methoxy) propyl]cytosine (HPMPC) against equine herpesvirus-1 (EHV-1) in cell cultures, mice and horses. *Antiviral Research* 19, 219-232.

- Goehring L.S., Sloet van Oldruitenborgh-Oosterbaan M.M. (2001). The mystery of equine herpes myeloencephalopathy. *Equine Veterinary Education* 13, 36-42.
- Greenwood R.E., Simson A.R. (1980). Clinical report of a paralytic syndrome affecting stallions, mares and foals on a thoroughbred stud farm. *Equine Veterinary Journal* 12, 113-117.
- Jackson T., Kendrick J. W. (1971). Paralysis of horses associated with equine herpesvirus 1 infection. *Journal of the American Veterinary Medical Association* 158, 1351-1357.
- Jackson T.A., Osburn B.I., Cordy D.R., Kendrick J.W. (1977). Equine herpesvirus 1 infection of horses: studies on the experimentally induced neurologic disease. *American Journal of Veterinary Research* 38, 709-719.
- McCartan C.G., Russell M.M., Wood J.L.N., Mumford J.A. (1995). Clinical, serological and virological characteristics of an outbreak of paresis and neonatal foal disease due to equine herpesvirus-1 on a stud farm. *Veterinary Record* 136, 7-12.
- Mumford J.A., Hannant D., Jessett D.M., O'Neill T., Smith K.C., Ostlund E.N. (1994). Abortigenic and neurological disease caused by experimental infection with equid herpesvirus-1. *Proceedings of the 7<sup>th</sup> International Conference of Equine Infectious Diseases*, Tokyo, Japan, pp. 261-275.
- Sakamoto K. (1990). Antiviral activity of 9-(2-hydroxyethoxymethyl) guanine against equine herpesvirus type 1 HH-1 strain and pseudorabies virus YS-81 strain. *Nippon Juigaku Zasshi* 52, 1109-1111.
- Slater J.D., Borchers K., Thackray A.M., Field H.J. (1994). The trigeminal ganglion is a location for equine herpesvirus 1 latency and reactivation in the horse. *Journal of General Virology* 75, 2007-2016.
- Smith K. C., Whitwell K. E., Mumford J. A., Hannant D., Blunden A. S., Tearle J. P. (2000). Virulence of the V592 isolate of equid herpesvirus-1 in ponies. *Journal of Comparative Pathology* 122, 288-297.
- Stierstorfer B., Eichhorn W., Schmahl W., Brandmuller C., Kaaden O.R., Neubauer A. (2002). Equine herpesvirus type 1 (EHV-1) myeloencephalopathy: a case report. *Journal of Veterinary Medicine Series B* 49, 37-41.
- van der Meulen K.M., Nauwynck H.J., Pensaert M.B. (2000). Equine herpesvirus type 1 abortus, neonatale sterfte en zenuwstoornissen gediagnosticeerd in België in 1999. *Vlaams Diergeneeskundig Tijdschrift* 69, 38-41.
- van Maanen C., Willink D.L., Smeenk L.A., Brinkhof J., Terpstra C. (2000). An equine herpesvirus 1 (EHV1) abortion storm at a riding school. *Veterinary Quarterly* 22, 83-87.
- van Maanen C., Sloet van Oldruitenborgh-Oosterbaan M.M., Damen E.A., Derksen A.G. (2001). Neurological disease associated with EHV-1-infection in a riding school: clinical and virological characteristics. *Equine Veterinary Journal* 33, 191-196.
- Vial C.D., Netsved A.J., Rollins J.B. (1990). Adjunct treatment of equine respiratory disease complex (ERDC) with *P. acnes*, immunostimulant Eqstim<sup>®</sup>. *Equine Veterinary Science* 10, 399-403.