

## EPENDYMOMA IN A SHEEP

### *Ependymoma bij een schaap*

H. De Bosschere, S. Roels, E. Vanopdenbosch

Veterinary and Agrochemical Research Centre (VAR)  
National Reference Laboratory for Veterinary TSE (Belgium & Luxembourg)  
Department of Biocontrol  
Groeselenberg 99, B-1180 Brussels, Belgium

### SUMMARY

**This paper is the first description of an ependymoma in a sheep, diagnosed by chance from a fallen stock sheep included in the TSE epidemiosurveillance. Macroscopically only a very small grayish fluffy mass was present in the third ventricle of the mid-brain. Microscopically, the fluffy mass was diagnosed as an ependymoma.**

### SAMENVATTING

Dit is de eerste beschrijving van een ependymoma bij een schaap, per toeval vastgesteld bij een gestorven schaap opgenomen in de TSE epidemiologische bewaking. Macroscopisch was er slechts een kleine, grijze, vlok-kige massa te zien in het derde ventrikel. Microscopisch werd de vlokkige massa gediagnosticeerd als een ependymoma.

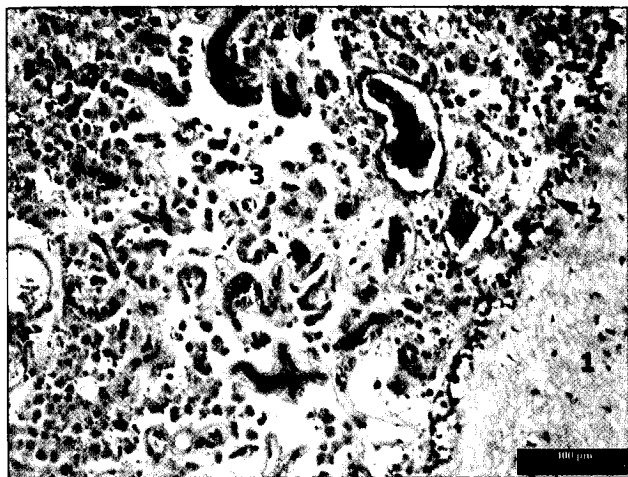
### INTRODUCTION

Active TSE epidemiosurveillance in sheep was introduced in April 2002 via a rapid screening test of a certain number of fallen stock (depending on the total sheep population per member state) and clinically suspected sheep older than 18 months (EC regulation 999/2001). By definition, "fallen stock" are also considered suspect and are therefore examined for TSE. Within this surveillance, a rare interesting case is occasionally diagnosed, as has already occurred in the past (Roels *et al.*, 2000; Roels and Vanopdenbosch, 2001; Roels *et al.*, 2002; Roels *et al.*, 2003). Ependymoma has already been described in cattle, horses, dogs, cats, rats (Hayes *et al.*, 1975; Palmer, 1961; Palmer *et al.*, 1974), hamsters (Corallini *et al.*, 1987) and mice (Lo *et al.*, 1974), but to our knowledge this is the first description of ependymoma in a sheep.

### CASE REPORT

A Suffolk sheep aged less than one year was found dead on presentation at the slaughterhouse. Accord-

ding to the TSE epidemiosurveillance protocol, this sheep was considered suspect and was therefore tested at our research facility. All the tests performed (Elisa [De Becker *et al.*, 2000], scrapie associated fibrils [SAF], histology [haematoxylin eosin (HE)] and immunohistology [Vanopdenbosch *et al.*, 1998]) were negative for TSE. Macroscopically, however, a small, fluffy grey mass was observed in the third ventricle. Histologically a tumorous mass was observed in the third ventricle. It was an intraventricular, densely cellular, well demarcated, expansively growing, unencapsulated neoplasm of 5 mm in diameter. The cells formed closely packed tubules, rosettes and cords with a very scanty but well-vascularized stroma. The cells were round to cuboidal, with indistinct cell borders and cilia at the apex of the cells. They had abundant eosinophilic granular cytoplasm and a round centrally located hyperchromatic nucleus (Fig. 1). Mitotic activity was sparse. No characteristics of malignancy were observed. This description corresponds well with the description given by Cordy (1990), Jubb and Huxtable (1993) and Summers *et al.* (1995). Differentiation should be made with choroid



**Figure 1. Microphotograph of endependymoma characterized by a densely cellular appearance of closely-packed tubules and cords, with a very scanty but well-vascularized stroma: 1: white matter; 2: outlining of ventricle by ependymic cells; 3: endependymoma. HE staining.**

plexus tumors and neuroblastomas, both of which lack true rosettes with cells containing cilia. An endependymoma also lacks the presence of a collagenous stroma, which is present in choroid plexus tumors (Summers *et al.* 1995).

In conclusion, the precise cause of death of this sheep could not be determined due to lack of case information and the impossibility of performing a thorough autopsy on the animal due to the TSE epidemiological surveillance protocol (Vanopdenbosch *et al.*, 1998). An endependymoma should be added to the list of interesting cases detected within this TSE surveillance protocol and sheep should be added to the list of animals in which this neoplasm has been reported.

#### ACKNOWLEDGMENTS

The authors wish to thank Rita Geeroms, Patrick Van Muylem, Stephanie Durand and Amina Chama for their technical assistance.

#### REFERENCES

- Corallini A., Altavilla G., Cecchetti M. G., Fabris G., Grossi M. P., Balboni P. G., Lanza G., Barbanti-Brodano G. (1987). Ependymomas, malignant tumors of pancreatic islets, and osteosarcomas induced in hamsters by BK virus, a human papovavirus. *Journal of the National Cancer Institute* 61, 875 - 883.
- Cordy D. R. (1990). Tumors of the nervous system and eye. In: Moulton J. E. (editor). *Tumors in Domestic Animals*, 3<sup>rd</sup> ed., University of California Press, Los Angeles, p. 640 - 665.
- De Becker D., Roels S., Vanopdenbosch E. (2000). BSE onderzoek: opsporen van PrPres door middel van de BIO-RAD Platelia BSE-kit. *Vlaams Diergeneeskundig Tijdschrift* 69, 382 - 384.
- Hayes H. M. Jr., Priester W. A., Pendergrass T. W. (1975). Occurrence of nervous-tissue tumors in cattle, horses, cats and dogs. *International Journal of Cancer* 15, 39 - 47.
- Jubb K. V. F., Huxtable C. R. (1993). The nervous system. In: Jubb K. V. F., Kennedy P. C. Palmer N. (editors). *Pathology of Domestic Animals* (vol. 1) 4<sup>th</sup> ed. Academic Press, London, p. 267 - 437.
- Lo J. S., Mirakian A., Kellen J. A. (1974). Suppression of mouse endependymoma growth after immunization with tumor ribosomal complexes. *Oncology* 30, 467 - 474.
- Palmer A. C. (1961). Clinical signs associated with intracranial tumors in dogs. *Research in Veterinary Science* 2, 326 - 329.
- Palmer A. C., Malinowski W., Barnett K. C. (1974). Clinical signs including papilloedema associated with brain tumors in twenty-one dogs. *Journal of Small Animal Practice* 15, 359 - 386.
- Roels S., Charlier G., Letellier C., De Meyer G., Schynts F., Kerkhofs P., Thiry E., Vanopdenbosch E. (2000). A natural case of bovine herpesvirus 1 meningo-encephalitis in an adult cow. *The Veterinary Record* 146, 586 - 588.
- Roels S., Vanopdenbosch E. (2001). B cell lymphoma in the brain of a sheep. *The Veterinary Record* 149, 392 - 394.
- Roels S., De Meyer G., Vanopdenbosch E. (2002). Choroid plexus hyperplasia in an adult cow with clinical suspicion of bovine spongiform encephalopathy (BSE). *Vlaams Diergeneeskundig Tijdschrift* 71, 359 - 361.
- Roels S., Walravens K., Saegerman C., Thelissen M., Vanopdenbosch E., Godfroid J. (2003). *Mycobacterium bovis* meningitis in cattle with clinical suspicion of bovine spongiform encephalopathy. *The Veterinary Record* 152, 807-808.
- Summers B. A., Cummings J. F., de Lahunta A. (1995). Tumors of the central nervous system. In: Summers B. A., Cummings J. F. and de Lahunta A. (editors). *Veterinary Neuropathology*. Mosby, Missouri, p. 351 - 401.
- Vanopdenbosch E., Dechamps P., Dufey J., Roels S., Mullier P., Hallet C., Brochier B., Costy F., Pastoret P. P. (1998). Le premier cas d'encephalopathie spongiforme bovine diagnostique en Belgique. *Annales de Médecine Vétérinaire* 142, 111 - 118.