

COMPUTED TOMOGRAPHY (CT) IN SMALL ANIMALS

PART 1. TECHNICAL ASPECTS

Computer tomografie (CT) bij kleine huisdieren

Deel 1. Technische aspecten

I. Gielen, A. Van Caelenberg, H. van Bree

Department of Medical Imaging
Faculty of Veterinary Medicine, Ghent University
Salisburylaan 133, B-9820 Merelbeke
Ingrid.Gielen@rug.ac.be

ABSTRACT

Computed tomography (CT) is a cross-sectional imaging technique using x-rays and computers that is becoming increasingly available to veterinarians. During CT scanning, an x-ray tube rotates 360° around the patient. Multiple radiographic projections of a particular slice of tissue are made, and information from all projections is combined to create a single tomographic (slice) image. CT images provide accurate anatomic evaluation of tissue planes and regions that often cannot be visualized with conventional radiography. Whereas conventional radiographs have five radiographic opacities (metal, bone, soft tissues, fat, and air), CT systems can record thousands of separate opacities, ranging from air to high-density metal. Many imaging artifacts can occur in the process of generating CT images. A good understanding of these artifacts is necessary to enable an accurate interpretation of the CT images. After the scan examination, images in other planes can be produced using computerized reformatting, which is of help in evaluating the extent of a lesion. To increase the amount of soft tissue information, negative (air) and positive contrast agents (radio-paque iodine) can be used. Positive contrast techniques are of greatest importance for demonstrating brain tumors. Biopsies can also be obtained under CT guidance, a procedure that can be accurately performed.

SAMENVATTING

Computer tomografie (CT) is een techniek die meer en meer toegankelijk wordt voor dierenartsen en waarbij gebruik gemaakt wordt van röntgenstralen en computers om een beeld te genereren. Tijdens de beeldacquisitie draait een röntgenbuis 360° rond de patiënt waarbij meerdere radiografische projecties van een doorsnede worden gemaakt. De informatie van al deze projecties wordt vervolgens verwerkt tot één enkel tomografisch beeld. Omdat superpositie van structuren vermeden wordt, laat CT-exploratie van gebieden toe die met klassiek röntgenonderzoek niet onderzocht kunnen worden. In tegenstelling tot radiografie, waarbij gebruik gemaakt wordt van slechts vijf grijswaarden (metaal, bot, weke delen, vet en lucht), laat CT toe om duizenden grijswaarden te genereren, wat aanzienlijk meer informatie over de weke delen oplevert. Tijdens het genereren van de CT-beelden kunnen heel wat artefacten optreden waarvan men een goede notie moet hebben om zich bij de beeldinterpretatie niet te vergissen. Een groot voordeel van CT is dat er, na het eigenlijke onderzoek, via de computer reconstructies in andere vlakken kunnen gemaakt worden. Dit is nuttig om uitbreiding van letsels accuraat in te schatten bij eventuele therapie. Contrastonderzoek geeft bijkomende informatie over de weke delen pathologie en is voornamelijk bij onderzoek van hersenaandoeningen belangrijk. Ook biopsie name onder CT-geleide is mogelijk.

INTRODUCTION

Computed tomography (CT) is a cross-sectional imaging technique using x-rays and computers (Huygens and Baert, 1983; Hathcock and Stickle, 1993).

With the discovery of X-rays in 1895, a new era in the practice of medical visualization of the inside of the body without painful and often life threatening surgery had begun. The discovery was almost immediately recognized and accepted for its potential as a new me-

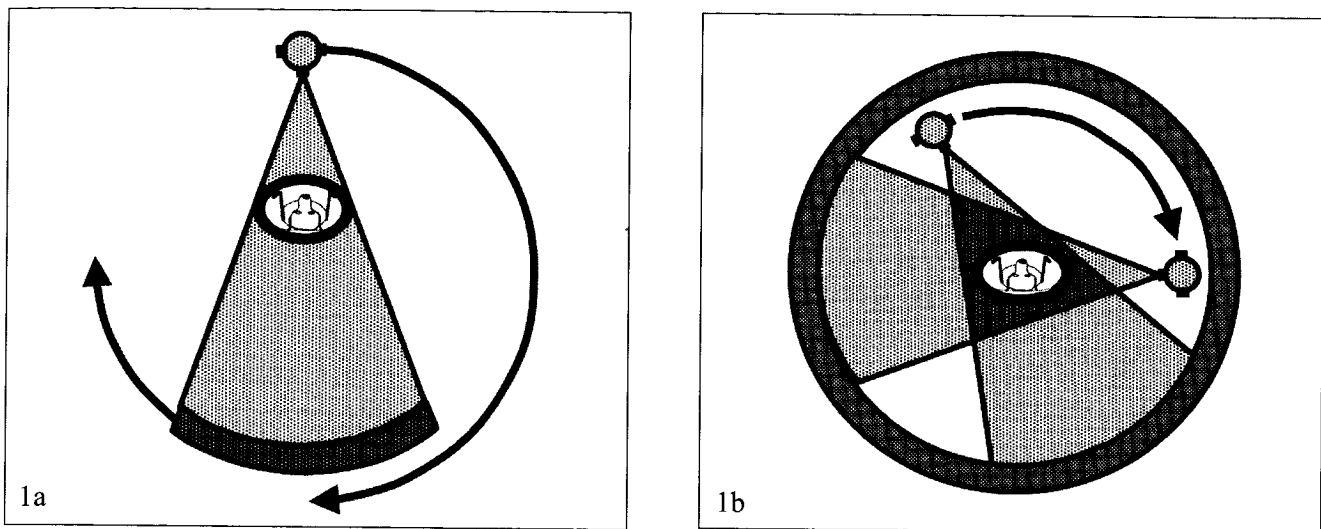


Fig. 1. Rotation scanner of the third generation (a) with movable detectors and of the fourth generation (b) with stationary detectors.

dical diagnostic technique. The technique has been characterized by many evolutionary improvements during the intervening 85 years. In the early 1970s a new implementation of X-ray imaging had a revolutionary impact on the practice of medicine. In 1971 an X-ray scanner was developed which produced cross-sectional images of the brain by employing several different scientific concepts, some known for over 50 years (Robb, 1982). The tomographic nature of CT images provides accurate anatomic evaluation of tissue planes and regions which are often impossible to visualize with conventional radiography. The most valuable property of this new technique was its higher contrast resolution. The ability to image in cross-section makes it possible to build up a three-dimensional picture which is invaluable for understanding normal anatomy and for planning surgical or radiotherapy treatment. The greatly increased tissue resolution allows differentiation between fluid and solid tissues and assessment of the internal structure of soft tissues (Dennis, 1995).

HISTORY

Already in 1963, Cormak was able to determine the absorption coefficient of x-rays through a flat object and to measure the variations in intensity of the x-ray beam in different planes. In 1967, Hounsfield had the idea that it must be possible to measure the intensity of the x-ray beam as it is sent through the body. He understood that a computer was needed to make the calculations. In 1972, Hounsfield introduced the EMI Mark I brain scanner for computerized axial transverse scanning of the head. Initially, the procedure was

known as CAT scanning (Computerized Axial Tomography or Computer-Aided Tomography), but the preferred term now is CT or Computed Tomography. This original scanner was capable of producing a pair of cross-sectional images following a four to five minute scan time (Wortman, 1986).

The first-generation scanners used a single, thin x-ray beam and one single detector. Hooked together, they moved in straight and parallel lines across the patient, radiation and recordings being made at the same time. At the end of the linear motion, the tube and the detector were rotated 1° and the linear motion was repeated again, in all, 180 times. A scan lasted 5 to 6 minutes per slice to acquire the data (Hathcock and Stickle, 1993; Wegener *et al.*, 1993).

A wide, fan-shaped x-ray beam and multiple detectors were used in the second-generation unit, allowing a larger rotation between linear motions. Scan times were reduced to less than 1 minute (Wegener *et al.*, 1993).

Third and fourth-generation units employ a rotating x-ray tube and movable or stationary detectors (Figure 1). Scan time with these units is only a few seconds.

The fifth-generation scanners were developed primarily for high-speed scanning. With the use of spiral CT, the scan time of data acquisition has been dramatically reduced, resulting in a much quicker overall examination, which is especially important in the investigation of small animals in reducing the number of motion artifacts. Thinner slices and faster imaging times are now possible, resulting in increased image resolution (Dennis, 1996; Seeram, 2001a). The newest development in CT-scanners is the multislice CT

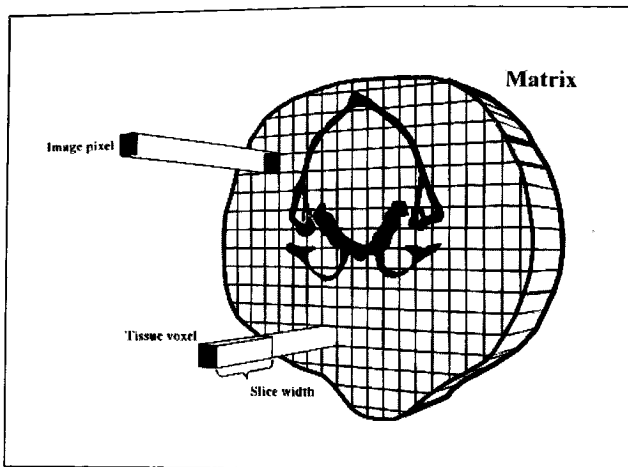


Fig. 2. Composition of the CT image: the smallest square unit of a CT image is the pixel. Each pixel is a two-dimensional representation of a three-dimensional block of tissue (voxel) from the body slice.

or the multirow detector CT scanners: these scanners produce multiple (2, 4 and 16) spiral acquisition slices simultaneously and gather a high data set of the scanned volume. This information can be processed in order to provide images of slices in all planes and directions. The newest multislice CT-scanners permit submillimeter collimation slice-width and can provide isotropic data set which allow not only an optimal plane resolution but also an identical spatial resolution of multiplanar reformatting (MPR) in all directions (Seeram, 2001e).

GENERAL PRINCIPLES OF COMPUTED TOMOGRAPHY

The CT image

In classic sequential CT, multiple radiographic projections of a particular slice of tissue are made, and information from all projections is combined to create a single tomographic (slice) image. A complete CT scan consists of a number of slices or images, usually contiguous, through the area of interest. The CT image is composed of a matrix of small tiny squares, called pixels. Each pixel is a two-dimensional representation of a three-dimensional block of tissue, the voxel. The third dimension of this block of tissue is the thickness of the slice of the tissue (Figure 2). The matrix may vary from 256x256 to 1024 x 1024 pixels. The more pixels in a matrix, the less the transition between the different pixels is visible and the better the resolution (Huygens and Baert, 1983; Feeney *et al.*, 2001).

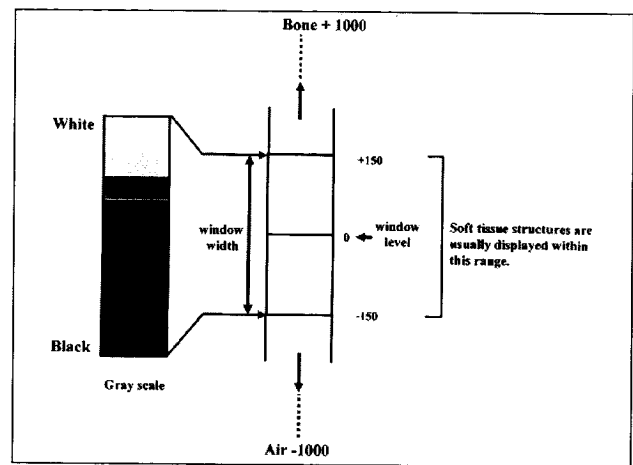


Fig. 3. For the final CT image, the CT numbers of the Hounsfield scale are converted to a grey scale. In the Hounsfield scale, +1000 is assigned to cortical bone, -1000 to air and 0 to water. The central grey color (window level (WL)) and the range above and below the window (window width (WW)) can be chosen.

The colors that are used are black, white and shades of grey. Whereas conventional radiographs have five radiographic opacities (metal, bone, soft tissues, fat, and air), CT systems can record thousands of separate opacities, ranging from air to high-density metal. Depending on the different properties of the structures through which the x-ray beam is absorbed or scattered (=attenuation), the grey scale is represented. Each tissue has its characteristic attenuation coefficient (Hathcock and Stickle, 1993).

The CT process

In CT images, the scale of the grey in the pixels represents the linear attenuation coefficient of the tissues in that voxel. The process of computed tomography determines linear attenuation coefficient to make a all the components of the CT equipment are used: the gantry and the patient table, the computer, the image display and console, and the film and camera for the data storage. The gantry contains the x-ray tube, x-ray collimators and x-ray detector. A CT scanner's gantry can, within limits, be tilted to angle the scan plane. In the spine, for example, the scan plane will be parallel to the intervertebral space. For brain examinations, the scan plane will be perpendicular to the hard palate. In CT, the choice of peak kilovoltage potential (kVp) is usually limited and a high kVp technique is always used. The kVp should be increased for very thick and dense body parts to ensure adequate penetration and for very dense objects to minimize beam hardening. Because of the limitations of thermal tube capacities with a given focal spot size, the choice of milliampe-

res seconds (mAs) also depends on the selected kVp. High mAs will increase image detail because it reduces image noise. When thin slices are made, an increase in mAs can compensate for otherwise very obvious image noise associated with thinner slice collimation (Seeram, 2001b).

Scan time is the time necessary for the x-ray tube to rotate around the patient while making the exposure. A longer scan time may result in improved image detail but may cause motion artifacts (including respiratory motion) and will cause x-ray tube heating (Stickle and Hathcock, 1993). We usually use a 3-second scan time. Effects of breathing motion are not a significant problem when scanning joints. Obviously, patient motion should be minimized by using general anesthesia. Because CT scanners use ionizing radiation, the anesthetist cannot be present when the scanner is in use. Therefore, monitoring of the patient should be done with monitors that are audible or have displays that can be seen from a distance (Robertson, 1999).

The patient lies horizontally on a movable table, so that images are transverse to the long axis of the body. At first a scout view of the object is obtained by moving the patient through the gantry as x-rays are being emitted while the tube and detectors remain stationary. A scout view is similar to a plain radiograph and is in fact a digital radiograph. The scout view is used to verify patient positioning and to assist the operator in planning the number and location of slices that will be obtained (Wortman, 1986).

During CT scanning, the x-ray tube emits the x-ray beam and rotates 360° around the patient. The collimator, located between the tube and the patient, determines the thickness of the slice (1-10 mm). The thinner the slice the better the study, but an increased number of slices requires more scan time. The more limited the area of interest, such as in joints, the thinner the slices can be (1-2 mm). Thick slices may result in small lesions remaining undetected because the attenuation information within each tomographic slice is averaged. Slices of 10 mm are used when scanning the entire canine thorax or abdomen. In brain CT, 5 mm thick slices are normally used. If it is essential to image every part of the object, continuous slices are required. This leads to an increased overall scanning time and tube load. Therefore thicker slices are often chosen instead. On the other hand, there are many body parts and conditions where continuous scanning is not essential. In these circumstances, scanning with a thin slice width and a few mm slice interval is often a better alternative (Stickle and Hathcock, 1993).

Depending on the kind of tissue and the thickness of the slices, the x-ray beam is absorbed or scattered. The x-ray photons emerging from the patient are absorbed by the x-ray detectors, converted to an electrical signal, amplified and converted into a number. This number is relative to the intensity of the beam as it emerges from the patient, and is equivalent to the attenuation. This number is transmitted to the computer. The x-ray tube circles around the patient and data are collected from all angles. In this way, different numbers are obtained and a complicated mathematical method is used to determine a specific number, the CT number, for each pixel (Hathcock and Stickle, 1993).

The range of these numbers assigned to the various tissues is from +1000 to -1000 (Hounsfield scale), where +1000 is assigned to cortical bone, -1000 to air and 0 to water. Thus the more radio-opaque the tissue, the more attenuation occurs within that voxel, the higher the CT number and the whiter that area of the image. Because the human eye can only differentiate 20 to 30 levels of grey, 32 to 64 grey levels are normally used. Groups of CT numbers are awarded to a particular scale of grey. The operator controls the tissue contrast. One can also choose the central grey color (window level (WL)) and the range above and below the window (window width (WW)). When the computer receives a CT number above or below the window edge, a white or black density is outlined (Figure 3). A narrow WW maximizes tissue contrast between tissues with a small difference in attenuation coefficient (soft tissue window). A wide WW is selected to view bony structures so that the bones stand out from the soft tissues (bone window) (Dennis, 1996; Hathcock and Stickle, 1993; Lee *et al.*, 1999).

Artifacts

Using CT, imaging artifacts may occur. A CT artifact is defined as any discrepancy between the reconstructed CT numbers in the image and the true attenuation coefficient of the object (Hsieh, 1995). This definition implies that anything that causes an incorrect measurement of transmission readings by the detectors will result in an image artifact (Shogo *et al.*, 1995; Seeram, 2001c). Artifacts can be very confusing and degrade image quality and affect the perceptibility of detail. A good understanding of this phenomenon is required to enable accurate interpretation (Seeram, 2001c).

The most common artifact seen on CT images is streaking. This artifact can have a number of causes,

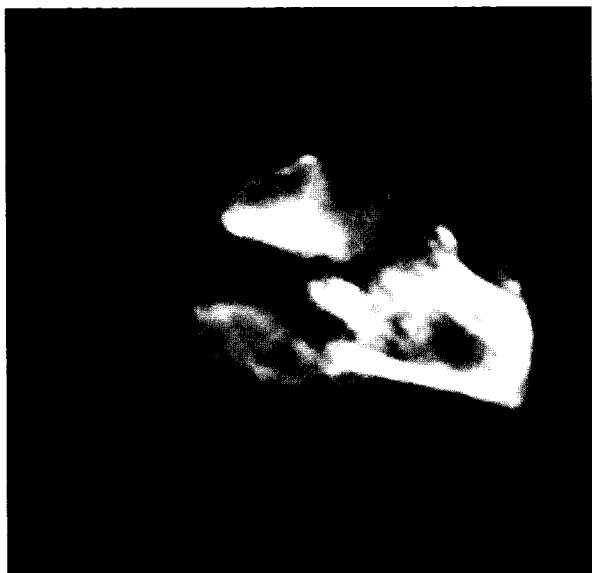

Fig. 4. Motion artifact on a CT image through a pathologic elbow joint: blurring of the image due to patient movements.

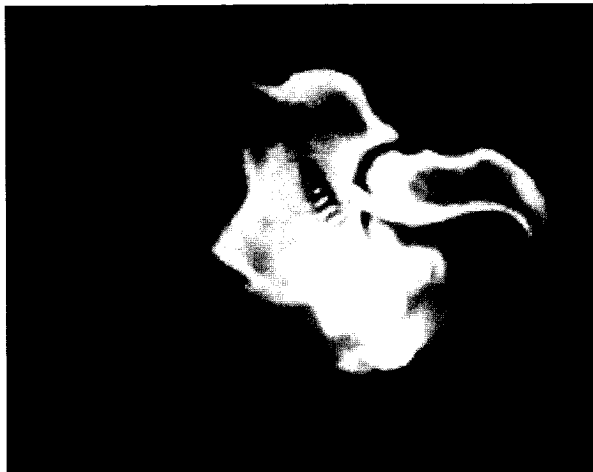

Fig. 5. Metal artifact due to a screw in the humeral condyle, causing streaking in the image.

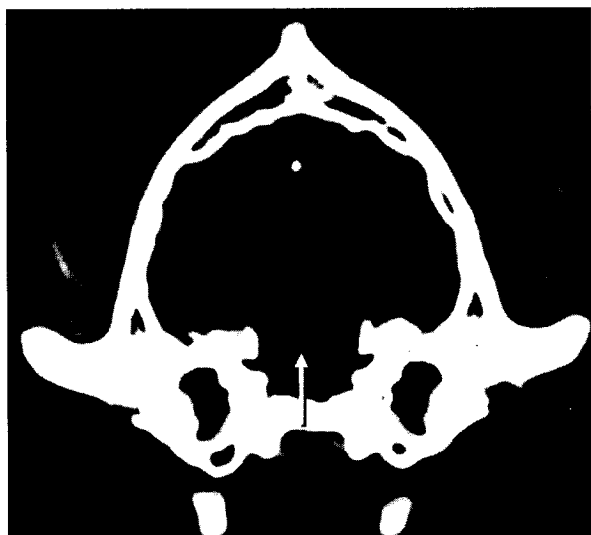

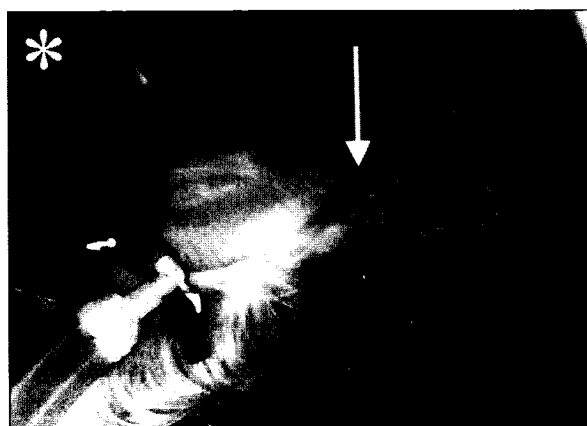
Fig. 6. Between the petrous temporal bones, the area of the ventral cerebellum and brainstem appears blacker (arrow) than the rest of the brain because the beam was selectively hardened as it passed through the petrous part of the temporal bone. This artifact is referred to as beam hardening.

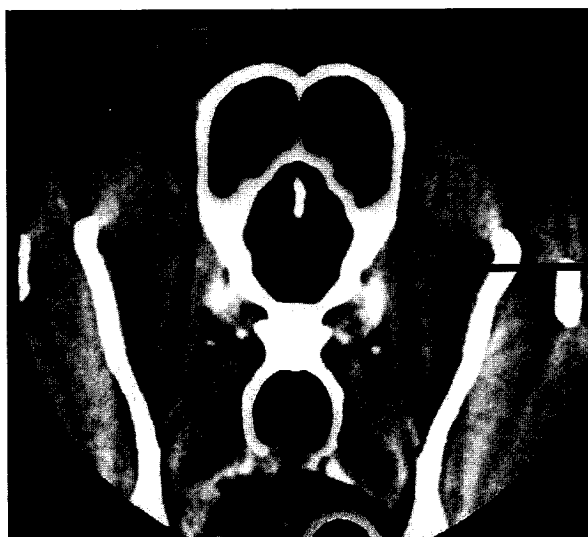

Fig. 7. Aliasing artifacts are streaks from the edges of high density structures. They may sometimes mask detail and result in misinterpretation of the image.



Fig. 8. Positioning of a dog in lateral recumbency to scan the elbow joints (arrow) without superimposition of the head (asterisk) and neck. Interference from body parts outside the scanning field, which may cause streak artifacts, is avoided through the use of this positioning.



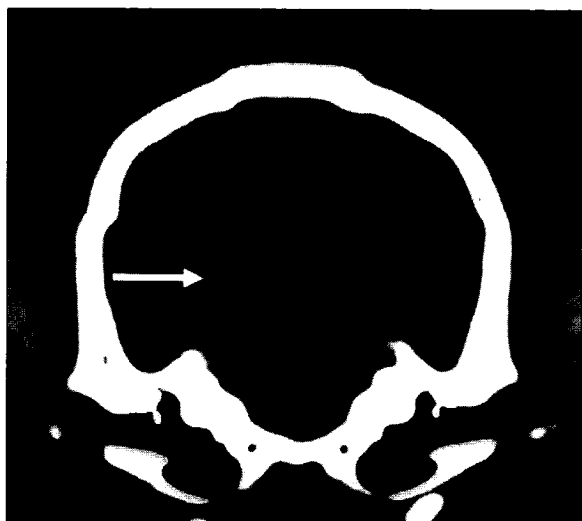


Fig. 9. Image through the brain with ring artifact (arrow), due to a failing detector.

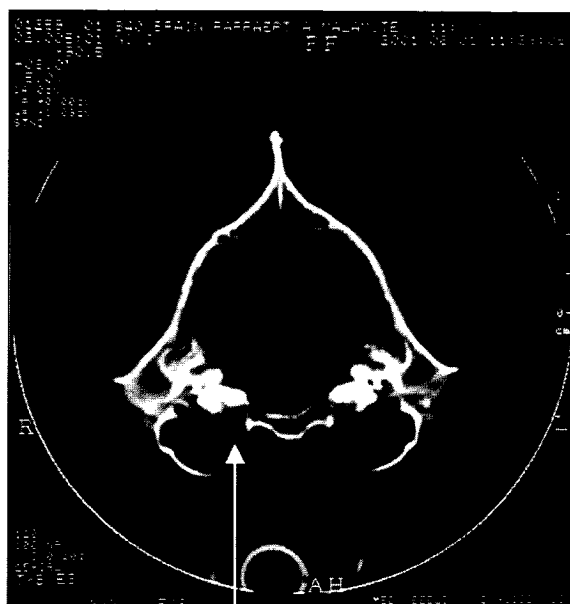

Fig. 10. The partial volume effect results from the inclusion of two different tissue densities within the thickness of the slice. On this transverse slice through the head, the partial volume effect is visible at the edge of the tympanic bullae, including both air and bone tissue (arrow).

including patient motion, presence of a high-density object (usually metal) in the scanning field, the effect of 'beam hardening', 'aliasing', 'edge gradient effect' and the presence of objects out of the scan field of view (Hathcock and Stickle, 1993).

In an individual slice, the assumption is that no movement occurred during the scan. In imaging small animals, patient movement is the most common cause and can create streaking and blurring of the image (Figure 4) (Feeney *et al.*, 1991a). The computer averages the density of the pixels and is affected by misinformation caused by the motion. The severity of streak artifacts depends not only on the amount of motion but also, to some extent, on the density of the part in motion. (Hathcock and Stickle, 1993).

Radiation streaks due to exceptionally high attenuation arising from metal implants, gun pellets and plastic tubes can extend across the entire image (Figure 5).

'Beam hardening artifacts' are the result of differences in the energy of the x-ray beam that fool the mathematical algorithm. Whenever the x-ray beam travels through substantial volumes of dense bone or metal, lower energy x-rays are absorbed by the dense material. The mean energy of the resulting x-ray beam becomes increased and the tissues on the far side of the dense object appear to be more radiolucent than they actually are. This is due to the over-penetration of the distal tissues by the higher energy x-ray beam.

This phenomenon results in dark streaks in areas near high-density/low-density interfaces. This artifact is best seen in the transverse image of the brain between the petrous temporal bones (Figure 6). In the canine skull, which is thicker than the human skull, beam hardening means that lesions in the pituitary and caudal fossa of the skull may be overlooked (Dennis, 1996; Feeney *et al.*, 1991a; Lee *et al.*, 1999; Seeram, 2001c).

'Aliasing artifacts' are streaks emanating from the edges of high-density structures, which result from inadequate sampling of the x-ray projection data. These streaks are sometimes in a moiré pattern and may mask detail within the image (Figure 7) (Hathcock and Stickle, 1993; Lee *et al.*, 1999).

The edge gradient effect consists of the creation of lucent edges or borders near very radiopaque objects such as the edges of the skull or the edges of the pelvis. These could be overestimated and misinterpreted as air instead of merely as artifacts of the image processing procedure (Feeney *et al.*, 1991a; Lee *et al.*, 1999).

Objects outside the scanning field of view also cause streak artifacts. These interfere with the reference detectors or alter the x-ray beam (Hathcock and Stickle, 1993). Therefore, it is necessary to try to move any body parts which are not to be imaged out of the scan plane. It is, for example, possible to scan the ca-

nine elbow joints without superimposition of the head and neck, which significantly improves the image quality (Figure 8) (De Rycke *et al.*, 2002).

Ring artifacts are typical for third generation CT scanners. They occur when a channel of the detector provides input/output properties which are different from those of other channels. These artifacts are ring-shaped obstructive shadows centered on the field of the view center (Figure 9) (Shogo *et al.*, 1995; Lee *et al.*, 1999).

Finally, an artifact may be caused by the partial volume effect, which results from the inclusion of two different tissue densities within the thickness of the slice (Feeney *et al.*, 1991a). These different densities are displayed as an average within the voxel. The CT numbers are not accurate, and at certain tissue interfaces the margins or borders are indistinct or fuzzy. These artifacts can lead to a false impression of bony proliferation or periosteal reactions (Figure 10). Selecting a reduced slice thickness minimizes this effect and makes it easier to show an exact value (Dennis, 1996; Shogo *et al.*, 1995).

Image reconstruction

Modern CT scanners allow a choice of reconstruction algorithms to provide the optimal image, depending on the area or tissue of greatest interest (bone, soft tissue, detail, etc.). From raw scan data, it is possible to use one algorithm for the primary reconstruction and another for the secondary reconstruction. The algorithms used for reconstruction techniques are based on calibration phantoms built for humans. Therefore the optimal reconstruction for small animals can often only be established on a trial-and-error basis. For example, very small patients often result in very noisy pictures. They require different reconstruction algorithms to reduce noise.

The portion of the patient that is seen on the display monitor (display field-of-view (DFOV)) can be much smaller than the scan field-of-view (SFOV). This allows small structures to be reconstructed with relatively large size, though with excellent detail and without degrading image quality. If one selects a DFOV which is too small or improperly centered for the area of interest, it is not necessary to do a new CT examination. If the raw data have been saved, a secondary reconstruction can be done to alter the DFOV (Stickle and Hathcock, 1993; Seeram, 2001d).

After the scan examination, images in other planes can be produced using computer reformatting. Using data from the transverse slices, images are reproduced

in other planes (Figure 11). It is easier to appreciate the extent of a lesion when it can be studied in multiple planes (Figure 12) (Dennis, 1996; Jeffery *et al.*, 1992).

Three-dimensional (3D) reconstruction is useful in selected cases for obtaining a panoramic view of a lesion and its extent of involvement, particularly in regard to bone lesions. By instructing the computer to eliminate soft-tissue CT numbers, a 3D surface image can be produced and rotated. 3D reconstructions for bone are clearer and more useful than for soft tissue (Figure 13) (Stickle and Hathcock, 1993; Seeram, 2001e).

Some scanners also give the choice of different degrees of edge enhancement, which increases sharpness (Figure 14).

Image interpretation

A working knowledge of normal anatomy is essential, certainly when dealing with cross-sectional images. Interpretation is simplified in some areas of the body because of bilateral symmetry. Straight positioning produces symmetric anatomy on transverse images, making interpretation much easier (Stickle and Hathcock, 1993). The identification of structures on one transverse image can usually be accomplished simply by examining multiple adjacent transverse images. The scanned structure can be followed as it appears and disappears in relation to recognizable surrounding organs. With its image based on the differential absorption of the X-ray beam by different tissues, CT provides ten times greater soft tissue resolution than conventional x-rays. Lesions are detected by virtue of the displacement or deformity of normal landmarks (mass effect) or by changes in tissue density due to pathological processes such as edema, hemorrhage, necrosis, calcification and osteolysis. External landmarks and depth measurements are used to localize lesions for the purpose of biopsy, surgery or radiotherapy. Appropriate window levels and window widths are crucial for the proper interpretation of CT images (Dennis, 1996). The window level and width must be appropriate for the tissue type and area of interest; otherwise the image will be either too light or too dark, and it will cause loss of information and misdiagnosis. Image manipulation can be done after the exposure as the image is on the display screen (Figure 15). Prior to making a printed copy of the CT scan, the correct density and contrast must be selected (Feeney *et al.*, 1991a). Regions of interest (ROI) can be selected and various data computed and displayed regarding them, including size and CT number average and range. Comparison of CT numbers between diffe-

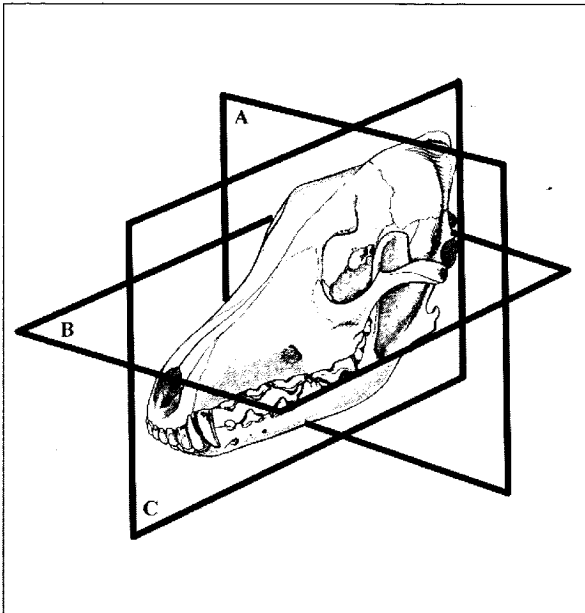


Fig. 11. After the scan examination, images can be reconstructed in different planes.
A: transverse plane, **B:** dorsal plane, **C:** sagittal plane.

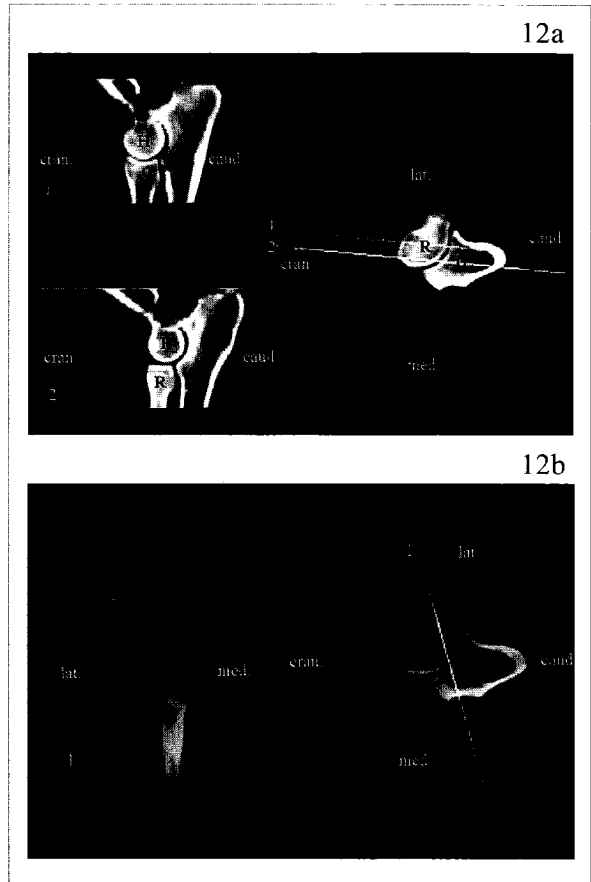


Fig. 12. Using data from the transverse slices of an elbow joint, reconstructed images can be reproduced in sagittal (a) and dorsal (b) planes.



Fig. 13. 3-D reconstructed image of hip joints in a young dog.

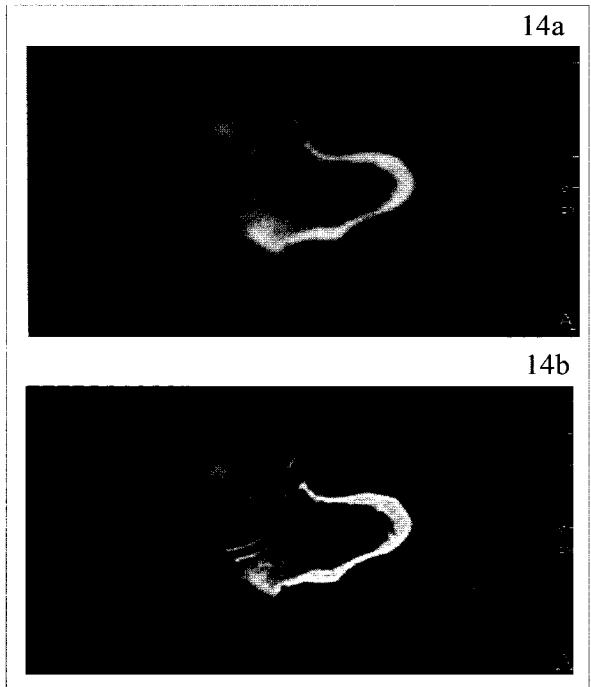


Fig. 14. After the CT image is displayed on the screen, the sharpness of the image can be increased. **a.** Survey transverse image at the level of radius and ulna. **b.** Same image after edge enhancement.

15a

15b

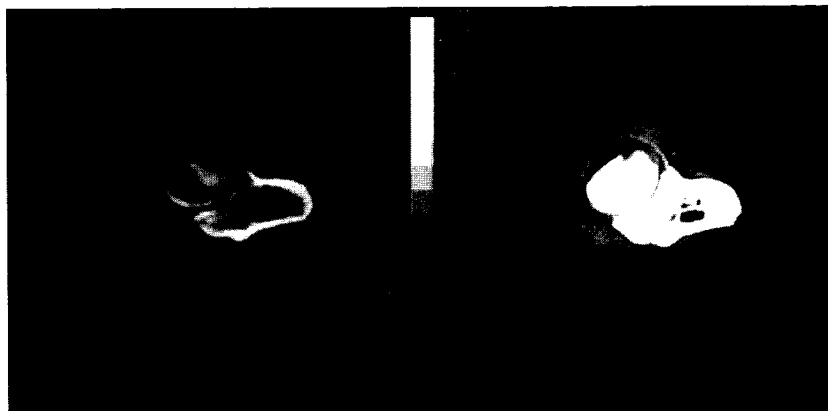

Fig. 15. After the scan examination, the window level and window width can be manipulated. Using a bone window (a), the subchondral details in radius and ulna are nicely visible. On a soft tissue (b) window, the details of muscles, tendons and vessels are more clearly visible.

16a

16b

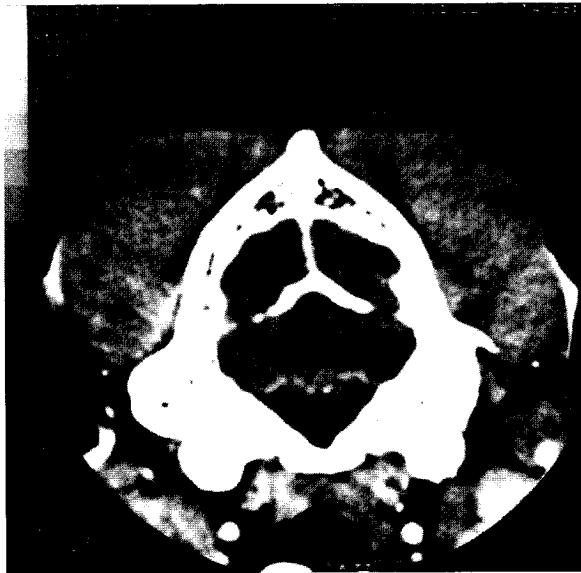
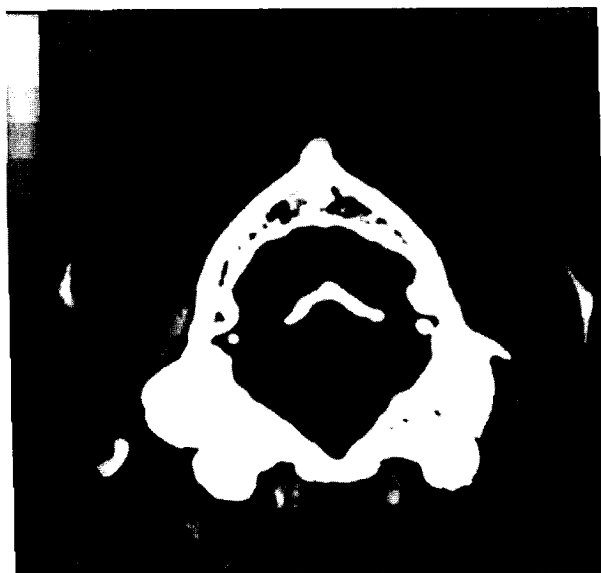
Fig. 16. Plain CT image (a) and corresponding image after the administration of IV contrast medium (b). The vascular structures become visible (black arrow heads) and the overall density of the brain parenchyma increases.

rent areas on an image is sometimes useful, particularly in regard to relative differences in density (Stickle and Hathcock, 1993).

Contrast studies

To increase the amount of soft tissue information, negative (air) and positive contrast agents such as radiopaque iodine can be used. CT myelography, gastro-intestinal and urogenital studies can be performed. Intravenous contrast is used to differentiate between normal and abnormal tissue (Seeram, 2001f). Positive contrast techniques are the most important tools in veterinary medicine for demonstrating brain tumors. Normally, water soluble iodinated contrast media do not cross the intact blood-brain barrier, though where this barrier has been damaged by a lesion, the contrast medium will enter and increase the radio-opacity of

that area. Normal brain enhances only 2-4 HU after the administration of intravenous contrast medium injection (Figure 16), but the opacity of a lesion will increase by 20-40 HU. Intravenously injected contrast media will produce contrast enhancement outside the brain. This enhancement simply reflects vascularity, but this phenomenon can be useful for delineating areas of necrosis (Dennis, 1996). The use of non-ionic contrast agents is advantageous because of their lower incidence of adverse reactions but they are more expensive than the ionic forms. The ionic, high osmolality contrast agents are good for providing positive contrast enhancement of fluid filled regions; they are less expensive and, in general, adverse reactions are a minimal problem in veterinary medicine (Holland, 1993).

Contrast agents can be injected either as a bolus or as an infusion. Improved visualization of a solid lesion in

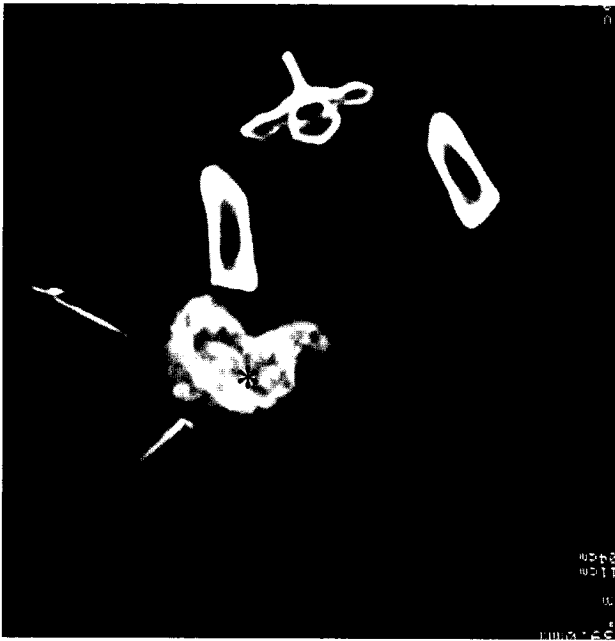

Fig. 17. Transverse image of the pelvis of a dog with a calcified mass (black asterisk) ventral to the ilium. Two metallic biopsy needles are in place to perform CT guided biopsy. Note the precise location of the needle tip. The histological diagnosis was chondrosarcoma.

liver, spleen, or pancreas is most likely achieved by scanning during bolus effect, that is, within the first 2 minutes after injection of a contrast material bolus or during a contrast material infusion (Burgener and Hamlin, 1981).

Best opacification of the ureters was obtained with 400 and 800 mgI/kg injected as a bolus, with a constant peak at 3 minutes and durable opacification for 1 hour (Barthes, 1998).

Ct guided biopsies

It is possible to obtain biopsies under CT guidance, a procedure which can be accurately performed when additional information is needed for diagnosis, staging or therapy planning. This approach can be of value for investigating mass lesions resulting from neoplasia or infections. Besides their use in the brain, CT

guided biopsies appear to be particularly useful for lesions involving the retrobulbar space, the nasal and paranasal cavities, the vertebrae and ribs, the pelvis, and the lung and mediastinum in dog and cat. Although stereotactic devices and guidance devices improve the accuracy, free-hand techniques are commonly used. CT guided percutaneous biopsy can be performed using a fine aspiration needle, a tru-cut needle to obtain tissue core samples, or a bone biopsy needle. Precise needle tip localization is an essential skill when performing CT guided needle biopsies (Figure 17) (Tidwell and Johnson, 1994a). The retrobulbar region is directly accessible to biopsy due to the incomplete bony orbit of the dog. Care must be taken not to damage the optic nerve (Penninck *et al.*, 2001). A percutaneous CT-guided needle biopsy of deep lesions such as a vertebral body or intervertebral disc can be determined in a safe and accurate way (Moore *et al.*, 2000; Risselada *et al.*, 2001).

CT guided aspiration in the thoracic cavity of lymph nodes or pulmonary masses results in a cytological diagnosis. The administration of intravenous injection of contrast medium delineates vessels immediately adjacent to a mass. During the puncture procedure, vessels can be avoided and the safety of CT guided biopsies in the thorax can be improved (Tidwell and Johnson, 1994b).

Stereotactic devices are normally used for obtaining brain biopsies. They are rather expensive and complicated, as they have to be adaptable to the different possible skull sizes in dogs. These biopsies are extremely useful in treatment planning, as most of the time the CT findings do not absolutely correlate with histological findings (LeCouteur, 1999; Moissonnier *et al.*, 2002).

REFERENCES

A complete list of references can be obtained from Ingrid Gielen.