

PHOTODYNAMIC THERAPY OF FELINE SUPERFICIAL SQUAMOUS CELL CARCINOMA OF THE NASAL PLANUM

De fotodynamische behandeling van een oppervlakkig plaveiselcelcarcinoom van de neusspiegel bij een kat

E. Vinck¹, H. Vinck², B. Cagnie¹, D. Cambier¹

¹ Department of Rehabilitation Sciences and Physiotherapy, Faculty of Medicine and Health Sciences, Ghent University, University Hospital, De Pintelaan 185 (6K3), 9000 Gent, Belgium

² Dendermondesteenweg 624, 9070 Destelbergen, Belgium
elke.vinck@UGent.be

ABSTRACT

The objective of this case report was to demonstrate the feasibility of photodynamic therapy for the treatment of feline superficial squamous cell carcinoma and to illustrate its approachability in veterinarian practice.

Photodynamic therapy using topical 5-aminolaevulinic acid was applied on a superficial squamous cell carcinoma at the nasal planum of a cat. After applying of the cream, the irradiation was performed with a red Light Emitting Diode contrivance with a wavelength of 660 nm.

The following day, the tumour area was erythematous and oedematous. On the second day after the treatment a scab was formed. The response rate was encouraging as visual observation of the tumour area revealed a removal of the malignant cells. The recovery of the normal epithelialised skin structure was observed two months after the treatment. A follow-up period up to two years revealed no recurrence.

These promising results demonstrate that photodynamic therapy should be considered as treatment modality for early stage superficial squamous cell carcinoma.

SAMENVATTING

Aan de hand van deze casus tracht men de bruikbaarheid van fotodynamische behandeling voor een oppervlakkig plaveiselcelcarcinoom bij een kat te illustreren en deze toegankelijk te maken voor de toepassing in de diergeneeskundige praktijk.

Een plaveiselcelcarcinoom ter hoogte van de overgang van de neusspiegel en de neusrug bij een kat werd fotodynamisch behandeld door middel van 5-aminolevulinezuurzalf in combinatie met bestraling door middel van een toestel met rode licht emitterende dioden, met een golflengte van 660 nm.

Daags na de fotodynamische behandeling vertoonde de behandelde zone erytheem en oedeem, de tweede dag na de bestraling werd korstvorming vastgesteld. De uiteindelijke reactie van het weefsel op de behandeling was gunstig; tijdens visuele observaties twee maanden na de behandeling werden geen maligne cellen meer vastgesteld en vond men normaal huidepitheel op de locatie van de laesie.

Er werd in de loop van de twee jaar durende follow-up periode geen recidief vastgesteld.

Deze veelbelovende resultaten laten toe te concluderen dat fotodynamische behandeling bij oppervlakkige plaveiselcelcarcinomen overwogen dient te worden.

INTRODUCTION

In clinical practice, feline squamous cell carcinoma (SCC) of the skin is traditionally treated by surgery, cryosurgery, intralesional chemotherapy and/or radiotherapy (Lana *et al.*, 1997; Moore and

Ogilvie, 2001). Though the success ratios of these treatments are relatively high, they do involve a number of disadvantages. These forms of therapy are costly and potentially harmful. They can leave a scar

and hypo- or hyperpigmentation, and may have other side effects such as pain, severe inflammation and irritation (De Rosa and Bentley, 2000; Moore and Ogilvie, 2001).

The search for a more acceptable treatment that is capable of killing cancerous cells in a more selective way has led to the development of photodynamic therapy (PDT). PDT is a treatment modality based on the interaction between a photosensitizer (precursor), light and oxygen, which causes photochemically induced selective cell death (De Rosa and Bentley, 2000; Guillen *et al.*, 2000; Maier *et al.*, 2001; Morton *et al.*, 2002). The selective toxicity of PDT is based on the preferential uptake or retention of the photosensitive agent at higher concentrations in tumor tissue than in the surrounding normal tissue. Application of the photosensitizer is followed by exposure to light of a wavelength corresponding to one of the absorption maxima of the photosensitizer. Light absorption transforms the sensitizing agent from its ground state into an excited triplet state molecule. The excited triplet can undergo two types of reaction. It can transfer its energy to oxygen directly to form reactive singlet oxygen. Alternatively, it can transfer its energy to intermediate molecules, which then react with oxygen to produce free radicals. As a result of the activation of reactive singlet oxygen or free radical production, subsequent tissue damage is generated. Without exposure of the photosensitizer to light of the appropriate wavelength, the photosensitizer is not activated and so there is no effect on the tumor tissue (Cairnduff *et al.*, 1994; Lucroy *et al.*, 2000; Lucroy *et al.*, 2002; Morton *et al.*, 2002; Peng *et al.*, 1997; Stell *et al.*, 2001). This case report, which is aimed at familiarizing practitioners with the use of PDT and providing the necessary information for eventual clinical application, deals with recent clinical progress in topical PDT of skin cancer using 5-aminolaevulinic acid (5-ALA) and Light Emitting Diodes (LEDs).

MATERIALS AND METHODS

A neutered male cat (domestic longhair, 18 months, 4 kg, FeLV negative and FIV negative) with cytologically confirmed superficial SCC of the nasal planum and the transition to the bridge of the nose, and tumor grade T1 (Figure 1) (Owen, 1980; Hahn and Richardson, 1995; Moore and Ogilvie, 2001) was selected for photodynamic treatment with 5-ALA and LED. Macroscopically, a grade T1 tumor (Owen, 1980; Hahn and Richardson, 1995; Moore and Ogil-

vie, 2001) is characterized by a crusting lesion with erythemic tissue beneath the crust. According to the TNM classification system, a T1 tumor is superficial and non-invasive (Owen, 1980; Hahn and Richardson, 1995; Moore and Ogilvie, 2001). Figure 2 pictures the corresponding cytological appearance. The diameter of the lesion (Figure 1) was approximately 1.2 cm. Clinical and routine blood examinations confirmed the good general health of the cat and no palpable regional lymph node enlargements were detected. Sensitization with 5-ALA cream was preceded by cleaning of the SCC with sterile polyvidon-iodine 10% solution (iso-BETADINE; Asta Medica) and removal of the crust. Two millimeters of Porphin 5-ALA cream 20% (Aladerm; Crawford Pharmaceuticals) was applied topically to the lesion and to a 2 mm margin of apparently normal skin tissue. Application occurred by means of a cotton swab. The cream was applied over a period of five hours. Every 30 minutes the presence of the cream was examined and, if necessary, more cream was applied. The cat was anesthetized throughout the entire procedure to avoid attempts to remove the cream by licking or rubbing and to avoid discomfort. Sedation was done with Medetomidine HCl 1 mg/ml (Domitor, Pfizer Animal Health) at 0.05 mg/kg intramuscular and anesthesia with Ketamine HCl 100 mg/ml (Anesketin, Eurovet) at 2.5 mg/kg intramuscular. Propofol 10 mg/ml (Rapinovet, Schering-Plough), which served as maintenance anesthesia, was administered intravenously as needed throughout the procedure. An insulant was used to prevent hypothermia during anesthesia. After removal of the photosensitizing agent, irradiation was accomplished using a red Light Emitting Diode contrivance (BIO-DIO preprototype; MDB-Laser Belgium) with a wavelength of 660 nm. LED irradiation at continuous mode was administered for a period of 20 minutes at a power output of 80 mW, resulting in a radiant exposure of 38 J/cm². During irradiation, the distance from light source to treatment area was 0.6 cm and aluminized tape was used to protect the eyes of the cat from irradiation (Figure 3). Immediately before irradiation, the tumor area was exposed to the ultraviolet light of a Wood lamp, verifying the presence of the typical red fluorescent spectrum of protoporphyrin IX (PPIX).

RESULTS

Besides normal distress after anesthesia, no adverse effects were monitored during a hospitalization

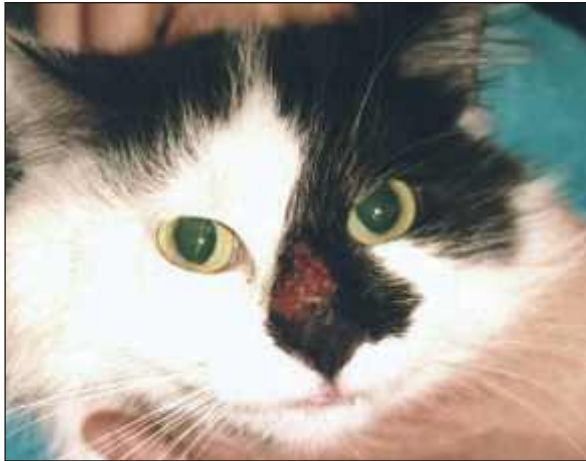

Figure 1. The tumour area after cleaning and removing the crust, immediately before photodynamical therapy with 5-aminolaevulinic acid and red Light Emitting Diodes.

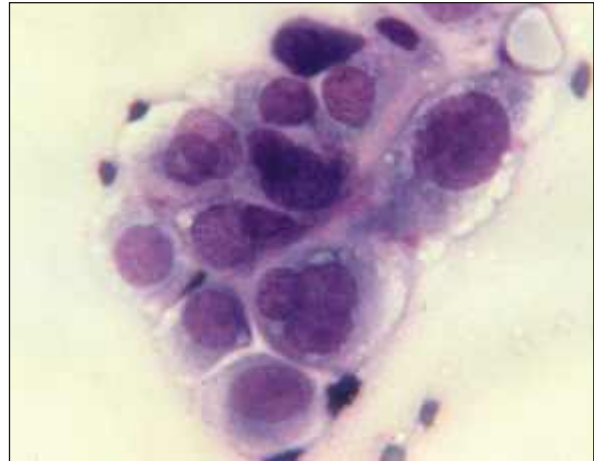

Figure 2. Cytological appearance of a tumour grade T1 (Owen, 1980; Hahn and Richardson, 1995; Moore and Ogilvie, 2001).

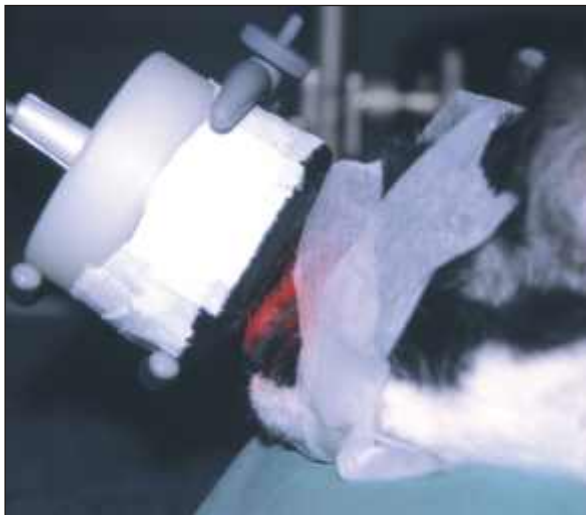


Figure 3. Irradiation of the SCC using a red Light Emitting Diode contrivance (BIO-DIO preprototype; MDB-Laser Belgium) with a wavelength of 660 nm. The eyes of the cat were protected from irradiation with aluminised tape.



Figure 4. Response at the time of the first visual observation, one month after the photodynamical therapy with 5-aminolaevulinic acid and red Light Emitting Diodes. The tumour is cleared from the nasal planum, the crusting lesion has disappeared and normal epithelia is emerging.

of 48 hours following the treatment. Consequently, no local anesthesia was administered, though as a precautionary measure an Elizabethan collar was applied for 24 hours to prevent licking, rubbing and scratching.

The day following irradiation, the tumor area became erythematous and somewhat edematous. The cat did not attempt to lick or scratch the treated area. Two days after the treatment, a scab developed. Response to the therapy was assessed by visual observation of the tumor area at 1 month (Figure 4), 2 months, 6 months and 2 years post-treatment. The second observation, at two months post-treatment,

revealed a complete response, which is defined as the disappearance of the malignant cells (based on macroscopic observations) and the complete disappearance of the crusting lesion, which relates to the recovery of normal re-epithelialized skin structure. No recurrence was noted up to two years post-treatment.

DISCUSSION

In the perspective of this case, PDT using topical 5-ALA and LED can be considered as safe and effective in treating early stage SCC of the skin. The initial response rate was encouraging, as normal tissue was

spared and healing occurred very fast. There also was an excellent cosmetic result, thanks to the small amount of crust formation. In accordance with some studies (Reeds *et al.*, 2004) and in contradiction to others (Peaston *et al.*, 1993; Frimberger *et al.*, 1998; Stell *et al.*, 2001; Touma *et al.*, 2004), this study did not reveal adverse effects such as local discomfort, lack of appetite or vomiting. Thanks to the topical use of the cream, systemic effects and generalized photosensitization leading to cutaneous sensitivity, which has been noted in cases of intravenously administered photosensitizing agent (Hahn *et al.*, 1998), was absent and the cat could be exposed to sunlight within 24 hours after the treatment (Savary *et al.*, 1998; Maier *et al.*, 2001).

Apart from the convincing outcome, several points should be noted. First of all it should be noted that during the follow up period the cat was exposed to nearly no direct sunlight as the owners live in an apartment. As sun avoidance and protection from sunlight are important precautionary measures to prevent recurrence of superficial squamous cell carcinomas, one essential risk factor for possible recurrence was eliminated (Anonymous, 2003; Alam and Ratner, 2001; Moore and Ogilvie, 2001). Secondly, the lesion was rather superficial (T₁) (Owen, 1980; Hahn and Richardson, 1995; Moore and Ogilvie, 2001) and, as Peaston *et al.* (Peaston *et al.*, 1993) state, treatment is more effective in tumors at stage T₂ and earlier. A third and final remark relates to the fact that only one case, and hence one type of lesion, was considered at one specific location. Consequently, the extrapolation of the results to various types of tumors, tumors located elsewhere than the nasal planum, and tumors with deeper dermal involvement (stages T₂-T₄) (Owen, 1980; Hahn and Richardson, 1995; Moore and Ogilvie, 2001) is only permitted after the treatment of a large number of various different tumors at different stages and at various different locations in the body.

The above mentioned points, which provide ample material for future investigations, do not lower the considerable value of this study, which has proved that PDT can lead to beneficial results in the treatment of superficial SCC of the nasal planum in cats.

Since this innovative procedure is a valuable alternative to conventional treatment (Reeds *et al.*, 2004), it is necessary to inform practitioners about it and to familiarize them with the use of PDT. By drawing up an elaborate description of the materials and methods, the investigators have endeavored to make the proce-

dure accessible for daily veterinarian practice, or at least to encourage veterinarians to refer patients to colleagues where PDT is available.

ACKNOWLEDGEMENTS

The authors are greatly indebted to Ms. T. Van den Berghe for her assistance both during treatment and during the follow up phase while the cat was still in the hospital. Thanks also to Prof. Dr. J. Declercq for supplying the necessary cytological photograph of a squamous cell carcinoma.

REFERENCES

- Alam, M., & Ratner, D. (2001). Cutaneous squamous-cell carcinoma. *The New England Journal of Medicine* 344 (13), 975-983.
- Anonymous (2003). Squamous cell carcinoma. *Current Problems in Dermatology-US* 3, 91-133.
- Cairnduff, F. Stringer, M., Hudson, E., Ash, D. & Brown S. (1994). Superficial photodynamic therapy with topical 5-aminolaevulinic acid for superficial primary and secondary skin cancer. *British Journal of Cancer* 69, 605-608.
- De Rosa, F.S & Bentley, V.L.B. (2000). Photodynamic Therapy of skin cancers: sensitizers, clinical studies and future directives. *Pharmaceutical Research* 17 (12), 1447-1455.
- Frimberger, A., Moore, A., Cincotta L., Cotter, S., & Foley J. (1998). Photodynamic therapy of naturally occurring tumors in animals using a novel benzophenothiazine photosensitizer. *Clinical Cancer Research* 4, 2207-2218.
- Guillen, C., Sanmartin, O., Escudero, A., Botella-Estrada, R., Sevilla, A. & Castejon, P. (2000). Photodynamic therapy for *in situ* squamous cell carcinoma on chronic radiation dermatitis after photosensitization with 5-aminolaevulinic acid. *Journal of the European Academy of Dermatology and Venereology* 14, 298-300.
- Hahn, K., Panjehpour, M., & Legendre A. (1998). Photodynamic therapy response in cats with cutaneous squamous cell carcinoma as a function of fluence. *Veterinary Dermatology* 9, 3-7.
- Hahn, K. & Richardson, R. (1995). The basics of cancer chemotherapy. Clinical Staging: Staging Classifications. In: Hahn, K. & Richardson, R. (eds.). *Cancer Chemotherapy. A Veterinary Handbook*. Williams & Wilkins, USA, pp. 25-42.
- Lana, E., Ogilvie, G., Withrow, S., Straw, R., & Rogers, K. (1997). Feline cutaneous squamous cell carcinoma of the nasal planum and the pinnae: 62 pinnae. *Journal of the American Animal Hospital Association* 33, 329-332.
- Lucroy, M. (2002). Photodynamic therapy for companion animals with cancer. *The Veterinary Clinics. Small Animal Practice* 32, 693-702.

- Lucroy, M., Edwards, B., & Madewell, B. (2000). Veterinary photodynamic therapy. *Journal of the American Veterinary Medical Association* 216, 1745-1751.
- Maier, A., Tomaselli, F., Matzi V. Rehak, P., Pinter, H. & Smolle-Jüttner, F. (2001). Photosensitization with hematoporphyrin derivative compared to 5-aminolaevulinic acid for photodynamic therapy of esophageal carcinoma. *Annals of Thoracic Surgery* 72, 1136-1140.
- Morton, C., Brown, S., Collins, S., Ibbotson, S., Jenkinson, H., Kurwa, H., Langmack, K., McKenna, K., Moseley, H., Pearse, A.D., Stringer, M., Taylor, D.K., Wong, G. & Rhodes, L.E. (2002). Guidelines for topical photodynamic therapy: report of a workshop of the British Photodermatology group. *British Journal of Dermatology* 146, 552-567.
- Moore, A. & Ogilvie, G. (2001). Management of specific diseases. Skin tumors: Squamous cell carcinoma. In: Ogilvie, G. & Moore, A. (eds.). *Feline Oncology. A comprehensive guide to compassionate care*. Veterinary Learning Systems, USA, pp.412-418 .
- Owen, L. (1980). TNM Classification of Tumors in Domestic Animals. *Geneva, World Health Organisation*, pp. 46-47.
- Peaston, A., Leach, M. & Higgins R. (1993). Photodynamic therapy for nasal and aural squamous cell carcinoma in cats. *Journal of the American Veterinary Medical Association* 202(8), 1261-1265.
- Peng, Q., Warloe, T., Berg, K., Moan, J., Kongshaug, M., Giercksky, K-E. & Nesland, J. (1997). *Cancer* 79(12), 2282-2308.
- Reeds, K., Ridgway, T., Higbee, R. & Lucroy, M. (2004). *Veterinary and Comparative Oncology* 2(3), 157-163.
- Savary, J.-F., Grosjean, P., Monnier, P., Fontollet, C., Wagnieres, G., Braichotte, D. & van den Bergh, H. (1998). Photodynamic therapy of early squamous cell carcinomas of the oesophagus: A review of 31 cases. *Endoscopy* 30, 258-265
- Stell A., Dobson, J., & Langmack, K. (2001). Photodynamic therapy of feline superficial squamous cell carcinoma using topical 5-aminolaevulinic acid. *Journal of Small Animal Practice* 42, 164-169.
- Touma, D., Yaar, M., Whitehead, S., Konnikov, N. & Gilchrist, B. (2004). A trial of short incubation, broad-area photodynamic therapy for facial actinic keratoses and diffuse photodamage. *Archives of Dermatology* 140, 33-40.