

SURVEY OF ORAL DISEASES IN CATS IN FLANDERS

Survey van mondaandoeningen bij katten in Vlaanderen

L. Verhaert¹, C. Van Wetter²

¹Department of Small Animal Medicine and Clinical Biology, Faculty of Veterinary Medicine, Ghent University, Salisburylaan 133, B 9820 Merelbeke, Belgium

BVBA Trivet, Kapelstraat 52, B 2540 Hove, Belgium

² Ter Rivierenlaan 101, 2100 Deurne, Belgium

leenvdent@pi.be

ABSTRACT

A survey of oral disease was conducted in a population of 753 client-owned cats examined by eleven Flemish veterinarians. Only 87 of these cats were presented for orodental disease. The possible effects of age, gender, diet, breed and lifestyle on the prevalence rates of oral diseases were studied. The results showed that most of the cats in this study were suffering from periodontal disease (gingivitis, periodontitis), and that periodontitis was more common in the older cats. Although this was a young population (mean age 4.5 years), and radiographic examination was not routinely done, one out of four cats in the population was found to suffer from odontoclastic resorptive lesions. Other diseases that were recorded included congenital/hereditary disease, trauma, oral proliferations and stomatitis. The results of this survey demonstrate that oral disease is very common in client-owned cats, and therefore deserves more attention in general veterinary practice.

SAMENVATTING

Een onderzoek naar de aanwezigheid van mondziekten bij 753 katten aangeboden voor algemeen onderzoek bij elf Vlaamse dierenartsen, wordt gepresenteerd. Slechts 87 van deze katten werden aangeboden voor een mondaandoening. Het mogelijk effect van leeftijd, geslacht, voeding, ras en levensstijl op het voorkomen van de verschillende mondaandoeningen werd onderzocht. Uit de resultaten bleek dat de meeste katten uit het onderzoek leden aan parodontale aandoeningen (gingivitis, parodontitis), en dat parodontitis meer voorkwam bij oudere katten dan bij jongere. Hoewel het hier een jonge populatie betrof (gemiddelde leeftijd 4,5 jaar), en er niet routinematig gebruik werd gemaakt van radiografisch onderzoek, had één kat op vier last van resorptieve letsels (FORL). Andere ziekten die werden genoteerd, zijn congenitale/erfelijke aandoeningen, trauma, proliferaties en stomatitis. De resultaten van dit onderzoek tonen aan dat mondziekten zeer vaak voorkomen bij de kat en dat de mond daarom veel meer aandacht zou moeten krijgen in de dagelijkse dierenartsenpraktijk.

INTRODUCTION

Oral disease in cats is very common, with periodontal disease being the most common of all oral diseases. It has been claimed that 85% of dogs and cats over the age of 5 years have periodontal disease, but actual data in support of this claim is lacking. All over the world studies have been done assessing different oral diseases in cats, most of these focusing on odontoclastic resorptive lesions (FORL). Depending on the population (feral versus domestic cats,

random population versus dental patients) and the examination methods (clinical examination versus radiographic examination), the reported prevalence rates of these lesions range from 2% to 75% (Reiter and Mendoza, 2002). Very little data is available on the effect of diet and lifestyle on the different oral diseases encountered in cats. There are reports that resorptive lesions are less common in wild roaming cats, but the lifestyle of client-owned cats and the possible effects of this lifestyle on the incidence of

resorptive lesions has only been assessed in two recent studies (Lund *et al.*, 1998; Scarlett *et al.*, 1999).

This survey had three aims: to establish the prevalence patterns of oral disease in the Flemish cat population, to see whether the prevalence patterns would be comparable to studies that had been done elsewhere in the world, and to see whether there would be any effect of gender, diet, breed or lifestyle on the prevalence rates of the different diseases.

MATERIALS AND METHODS

In 1995-1996 the Dentistry Working Group of the Flanders Section of the Small Animal Veterinary Association of Belgium conducted a survey of oral and dental problems of client-owned cats in the Flanders region of Belgium. The study was used as a way to habituate the members of the newly founded Dentistry Working Group to routinely using a dental examination as part of the routine examination of dogs and cats. Eleven investigators provided data for the survey.

The investigation included obtaining a history and visual examination of conscious cats and tactile examination of unconscious cats using periodontal probes and dental explorers when appropriate. Only one investigator used radiography on a regular basis (in patients that were presented for oral problems) to obtain additional information. The following oral problems were recorded: developmental/hereditary disease (malocclusion, supernumerary teeth, hypodontia), periodontal disease (plaque, calculus, gingivitis, periodontitis), stomatitis, resorptive lesions, oral proliferations, oral trauma (tooth fracture), and missing teeth. Teeth were considered congenitally missing in cats of less than one year of age; they were considered to be missing for other reasons (FORL, periodontal disease, extraction) in cats over the age of 1 year.

Definitions of gingivitis, periodontitis, stomatitis and resorptive lesions as used in this study are explained in Figs. 1 to 4 and in Verhaert (2002).

The history included age, gender, breed, feeding regimen and life style.

Sixteen breeds were represented in the study, with only two of them being relatively large (Domestic Shorthair and Longhair, and Persian and Exotic Shorthair). Certain breeds were put together in groups because of similar head shape, origin and/or inbreeding (Table 1). The 'European Shorthair' group included the British Shorthair, the European Shorthair and

the Chartreux. The 'Oriental Shorthair' group consisted of the Siamese and the Oriental Shorthair. Other breeds included the Abyssinian, the Birman, the Burmese, the Maine Coon, the Russian Blue, the Scottish Fold and the Somali.

The owners were asked if the cat was allowed to roam outside or not, and whether the cat was a hunter. A 'Hunter' was defined as a cat that comes in with prey at least twice a week and actually eats at least part of it.

All the results were entered into a computer for analysis by age group, gender, breed, feeding regimen, life style and reason for admission. Calculations were performed using Microsoft Excel.

RESULTS

A total of 753 cats between the ages of 3 months and 19 years (mean 4.5 years) were examined, 392 while anesthetized, the remaining 361 while conscious. The population was mixed, with only 87 cats being presented for oral/dental diagnosis and/or treatment. The distribution of different breeds in the study is represented in Table 1.

The overall results are given in Table 2.

The most commonly encountered disease was periodontal disease, i.e. gingivitis and periodontitis (73.2% and 18.5%, respectively). The second most common disease was odontoclastic resorptive lesions (25%). Missing teeth were present in 208 cats (27.6%), which is a consequence either of periodontal disease, or of resorptive lesions or of dental treatment (extraction).

The tooth congenitally missing most often was the upper second premolar. Supernumerary teeth were most commonly upper second premolar. In two cases a supernumerary lower fourth premolar was seen.

Age-linked differences

Age was recorded for 712 cats. The results were compared for age groups of: < 1 year (170 cats), 1 < 4 years (233 cats), 4 < 8 years (138 cats), 8 < 11 years (83 cats), 11 years and older (88 cats), as shown in Figure 5.

The subtotals for the age groups revealed that already in the age group below 1 year one out of two cats had established gingivitis. From 4 years of age, more than 90% had visible plaque, and around 90% had gingivitis and calculus. Periodontitis (21.7% at 4 < 8 years, 39.8% at 8 < 11 years and 44.3% from 11 years) will be underestimated because half of the cats were not anesthetized, making reliable detection of periodontal pockets and bone loss difficult if not

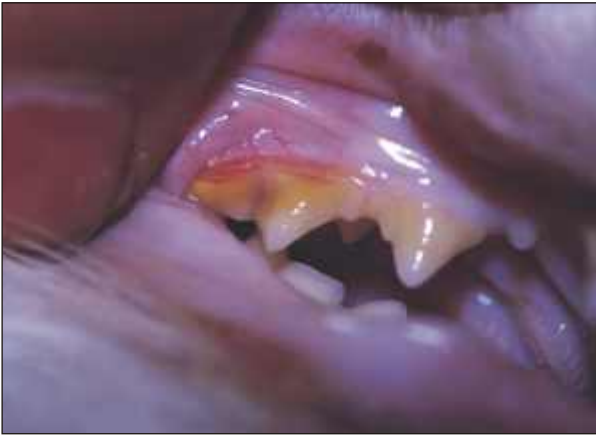

Fig. 1. Gingivitis. The gingiva is red, swollen and bleeds on probing with a periodontal probe. The picture shows gingivitis uncomplicated by periodontitis, i.e. there is no loss of attachment.

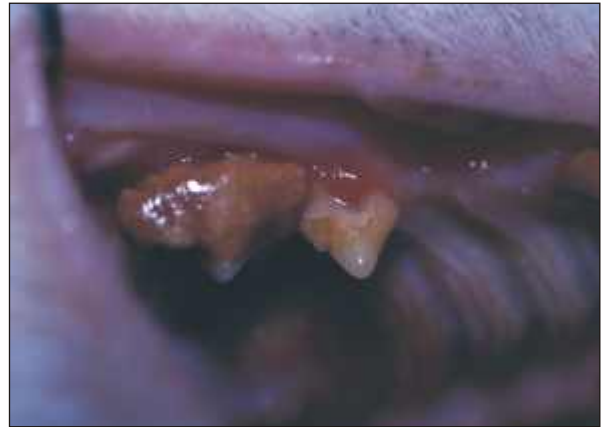

Fig. 2. Periodontitis. Inflammation of the periodontium, with loss of attachment. The picture shows severe periodontitis with gingival recession and furcation involvement of upper third premolar.

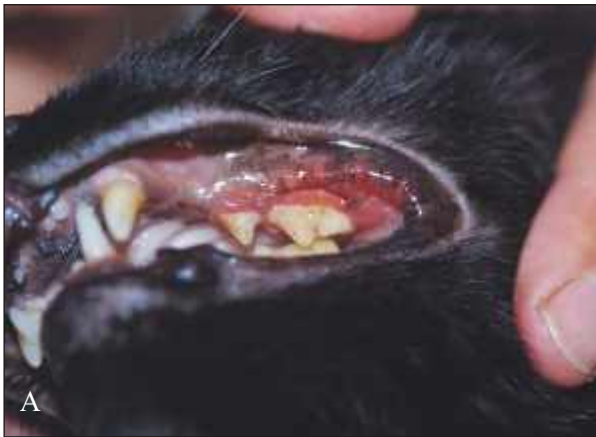

Fig. 3. Stomatitis. Inflammation of the oral mucosa beyond the mucogingival junction.
Fig. 3.a: buccostomatitis.

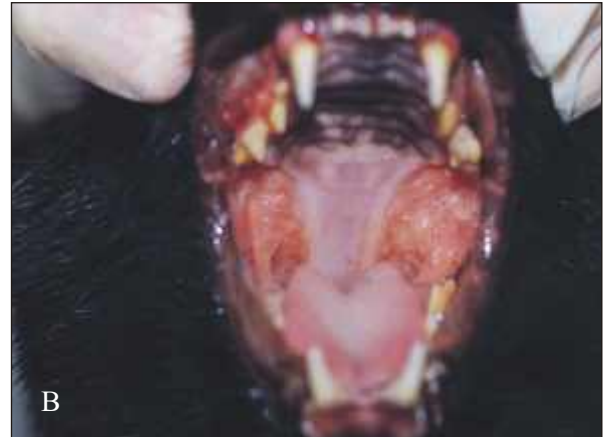

Fig. 3.b: faucitis.

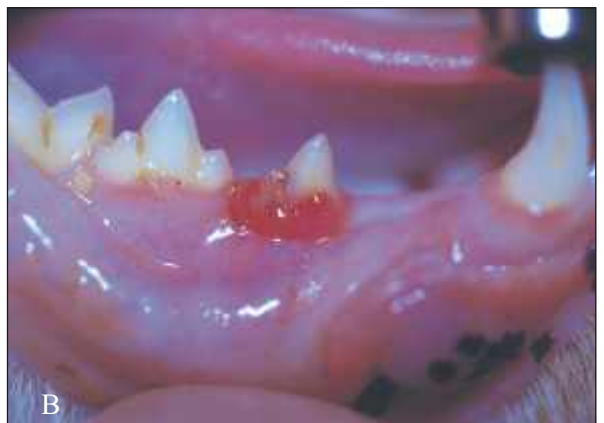
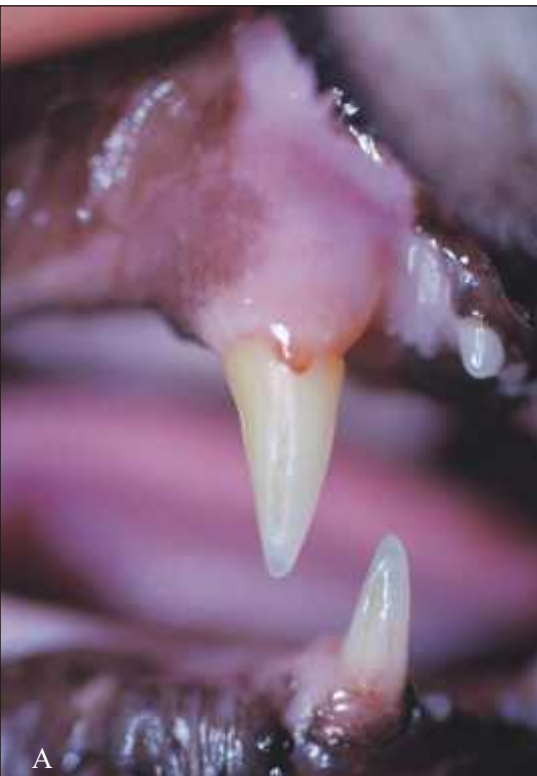
Fig. 4. Feline odontoclastic resorptive lesions. Clinically, defects in the tooth substance can be seen and/or probed with a sharp explorer if they occur at or just below the gingival margin. Usually, the gingiva will granulate into the defect thus covering it up.
Fig. 4.a: FORL at upper and lower canine.
Fig. 4.b: FORL at lower third premolar.

Table 1. Distribution of different feline breeds in the study according to skull anatomy and breed history (cross-breeding).

Breed	Group	Head type	Breed history	No. of cats
Domestic Shorthair (DSH); Domestic Longhair (DLH)	DSH/DLH	Mesocephalic	Non-pedigree cat, 'street cat'	617
Persian	Persian and Exotic Shorthair	Round, massive, broad head; brachycephalic	Old breed; used in many breeding programs to ameliorate eye/coat color	62
Exotic Shorthair	Persian and Exotic Shorthair	Round, massive, broad head; brachycephalic	Originates from crossing Persian cats with American shorthair cats; only allowable outcross breed today is the Persian	3
British Shorthair	European Shorthair	Round, broad and massive head; mesocephalic with tendency to brachycephalism	Originates from 'the most beautiful street cats', later on crossed with Chartreux and Persian	5
European Shorthair	European Shorthair	Fairly broad head with rounded contours; mesocephalic	Continental European equivalent to the British Shorthair; previously grouped (and crossed) with British Shorthair	2
Chartreux	European Shorthair	Round, broad head; mesocephalic	Old breed; crossbreeding with Persian (in the 1920s) and British Blue (in the 1960s-1970s); previously grouped with British Shorthair	7
Siamese	Oriental Shorthair	Long, triangular head; dolichocephalic	Very old breed; according to some a variant (colorpoint) of Oriental Shorthair	16
Oriental Shorthair	Oriental Shorthair	Long, triangular head; dolichocephalic	Differs from the Siamese only in coat and eye color	2

Other breeds (numbers in brackets): Abyssinian (2), Birman (3), Burmese (2), Maine Coon (1), Russian Blue (2), Scottish Fold (2), Somali (3)

Table 2. Number of cats affected with oral disease in the Flemish survey.

Clinical finding	No. of cats affected	% of total population
Plaque	659	87.5
Gingivitis	551	73.2
Calculus	506	67.2
Missing teeth	208	27.6
Resorptive lesion	189	25.0
Advanced periodontitis	139	18.5
Stomatitis	90	12.0
Tooth fracture	81	10.8
Malocclusion	37	4.9
Oral proliferation	10	1.3
Supernumerary tooth	9	1.2

impossible. The incidence reported here is the one for advanced periodontitis, i.e. those cases where extraction is the treatment of choice unless adequate home-care can be guaranteed. Resorptive lesions appeared already in the youngest age group, affecting 33.3% of cats in the group aged 4 < 8 years, 55.4% in the group aged 8 < 11 years old and 54.5% from 11 years onwards.

Sex-linked differences

Sex was recorded for 737 cats, including 167 male cats, 224 male castrates, 145 females and 201 female castrates, as shown in Figure 6.

Intact animals had less problems overall, mainly due to the lower mean age of the intact animals as compared to the castrated ones. The mean ages of the different groups were as follows: males 2.2 years, females 2.9 years, male castrates 6.1 years and female castrates 7.0 years.

Stomatitis was significantly more common in castrated males than in all the other groups (20.5% in castrated males, as compared to 6.6%, 6.5% and 11% in males, females and female castrates, respectively).

Breed-linked differences

Sixteen breeds were represented in this study (Table 1 and Figure 7). Only two groups were large enough to draw any conclusions: Domestic cats

(shorthair and longhair) (DSH/DLH) and Persian plus Exotic Shorthair cats. No marked differences could be seen between these two groups, except for the expected higher incidence of malocclusion in Persian and Exotic Shorthair cats. Persian cats did tend to have more severe periodontal disease at a younger age than domestic cats. The overall incidence of resorptive lesions was the same for DSH/DLH and Persian.

European Shorthair cats showed a relatively high incidence of malocclusion. Oriental and European Shorthair cats showed a higher incidence of stomatitis, which was often the reason for presenting them. Whether this might be significant is a question that requires further examination in a larger group of purebred cats. Both resorptive lesions and periodontitis were more often seen in the Oriental shorthair, but the mean age of these cats was higher than that of the other groups, so this is not likely to be significant.

Influence of Feeding Regimen

The feeding regimen was recorded for 614 cats. The distribution was as follows: 73 dry food, 99 canned food, 432 mixed (dry and canned). Ten cats received no commercial food (most of them meat and/or fish only). The mean age of cats eating soft

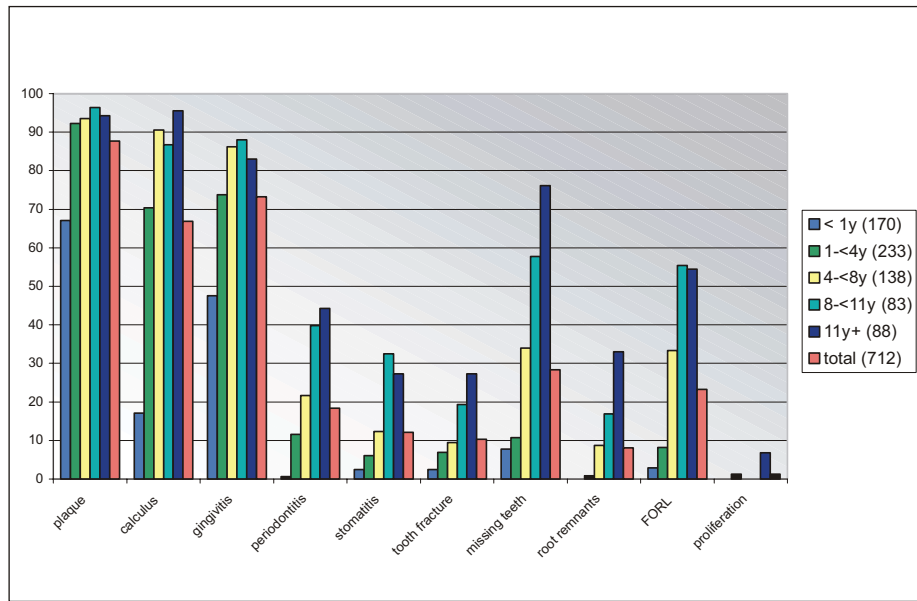


Fig. 5. Age-linked differences. Age was recorded for 712 cats. The Y-axis represents percentages per group. Numbers per group are between brackets in the legend.

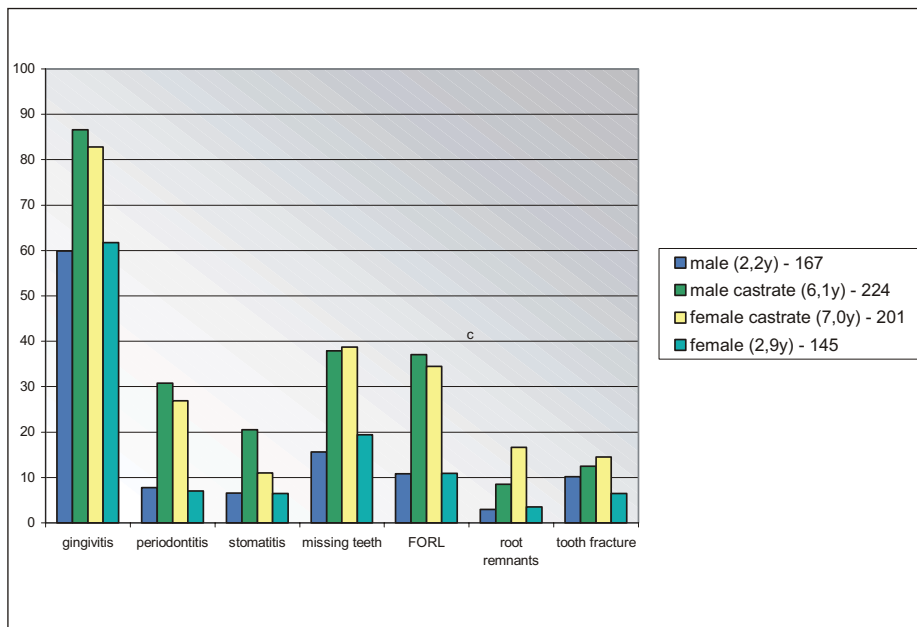


Fig. 6. Sex-linked differences. Sex was recorded for 737 cats. The Y-axis represents percentages per group. Numbers per group and mean age per group are indicated in the legend.

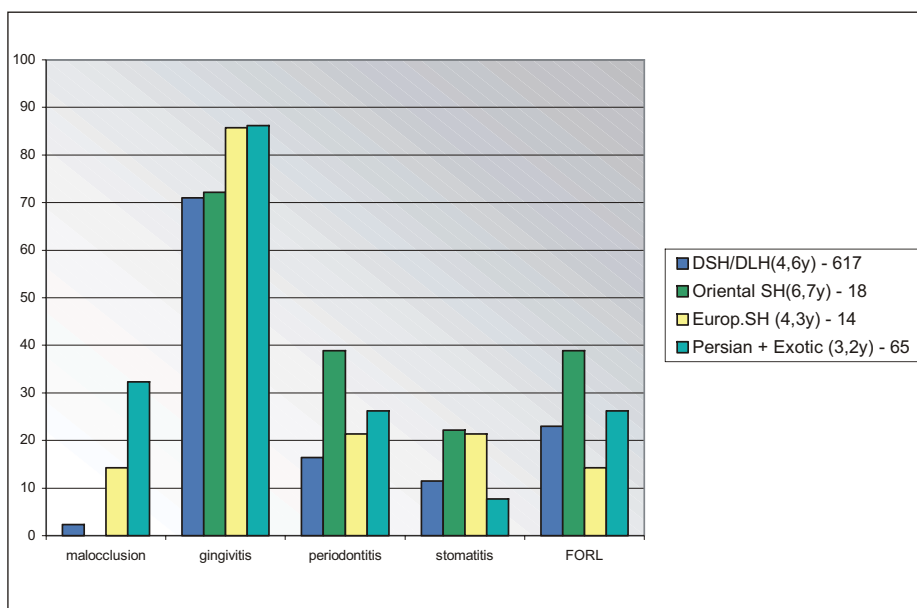


Fig. 7. Breed-linked differences. Sixteen breeds were represented. Only the larger groups are included in this graph. The Oriental Shorthair group includes 16 Siamese cats and 2 Oriental Shorthair cats. The European Shorthair group includes 5 British Shorthair, 2 European Shorthair and 7 Chartreux cats. The Y-axis represents percentage per group. Total numbers per group and mean age per group are indicated in the legend.

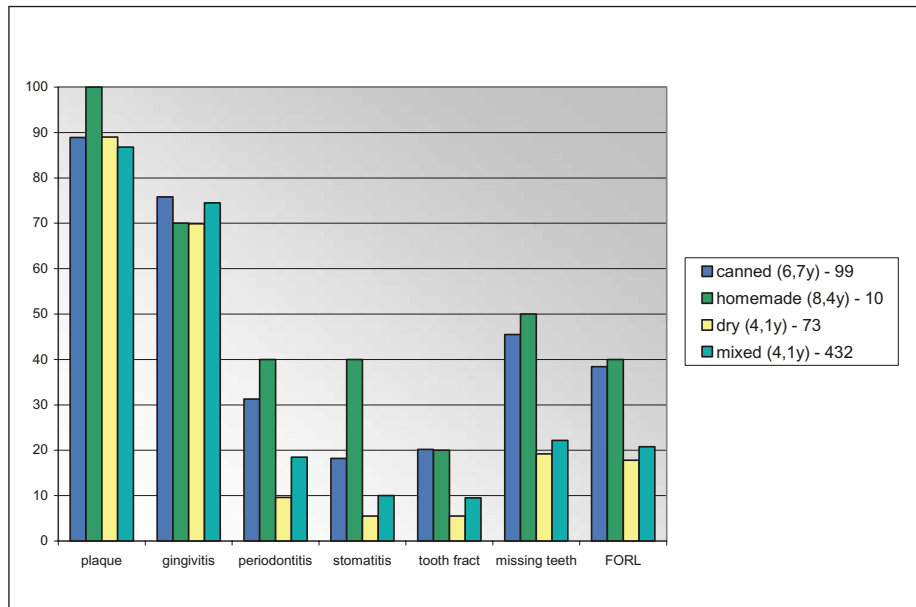


Fig. 8. Influence of feeding regimen. Feeding regimen was recorded for 614 cats. The Y-axis represents percentage per group. Numbers per group and mean age per group are indicated in the legend.

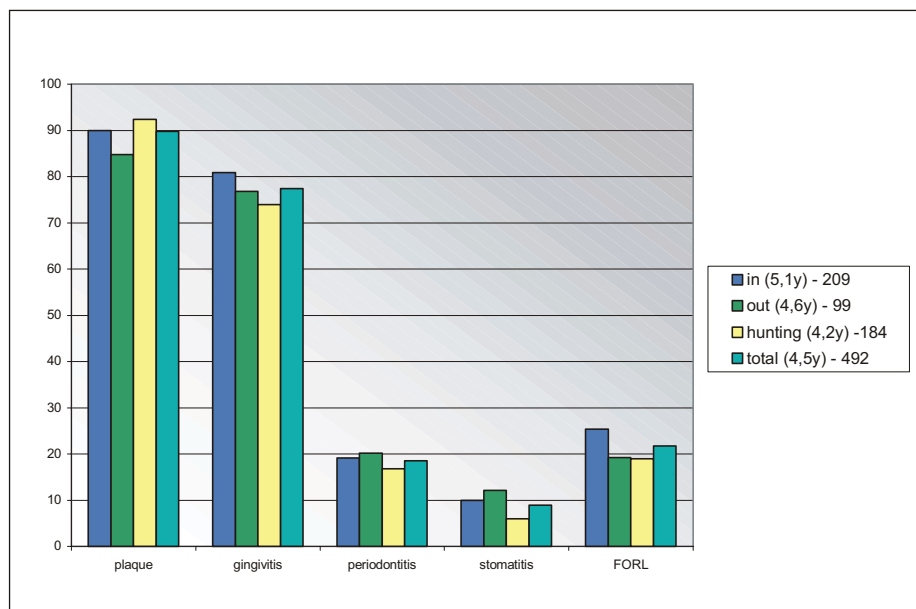


Fig. 9. Influence of lifestyle. Lifestyle was recorded for 492 cats. The Y-axis represents percentage per group. Numbers per group and mean age per group are indicated in the legend.

food only was higher than that of cats eating either dry food only or a combination of the two.

No marked differences for plaque and gingivitis could be seen, but cats fed only canned food or no commercial food had markedly more periodontal disease than cats receiving dry food or a combination of all the different foods (Figure 8). Cats eating only soft foods were more than twice as often affected by resorptive lesions. Cats eating only soft food also had more dental fractures and more missing teeth than cats eating dry food or a combination of dry and soft food.

Influence of Life Style

Lifestyle was recorded for 492 cats.

No marked differences could be seen between groups, so no conclusions could be drawn other than

that hunting behavior in these pet cats was not protective for any stage of periodontal disease or for the development of resorptive lesions (Figure 9). None of the cats examined was relying on natural food only.

DISCUSSION

The population that was examined was a mixed population, with only 87 cats presented for oral disease. The population was young, with a mean age of 4.5 years. Almost half of the cats were not anesthetized, and radiographs were only used by one investigator in cases presented for oral diseases other than malocclusion. This implies that the incidence of periodontal disease and FORL found in this survey will surely be underestimated. It has been shown that

more resorptive lesions will be found, both on the crown and the root, when radiographs are taken (Gengler *et al.*, 1995; Verstraete *et al.*, 1998). It has also been demonstrated that the full extent of periodontal disease is only seen when clinical examination is combined with radiological examination (Verstraete *et al.*, 1998).

Congenital and developmental problems were not seen frequently. The most common disorder was malocclusion, with a very high incidence in Persian and Exotic Shorthair Cats (one out of three). Persian and Exotic Shorthair cats are brachycephalic breeds, hence the high incidence of malocclusion. Brachycephalic cats have a shorter than normal upper jaw, while the lower jaw may have a normal length, leading to jaw discrepancy and malocclusion. The group of European Shorthair cats also showed a higher incidence than the general population. This is not a surprising finding, since Persian cats have been used in the breeding programs to ameliorate coat and eye color in the European and British Shorthair breeds.

The teeth most commonly reported as congenitally missing in cats are the maxillary second premolar and the first molar (Verstraete *et al.*, 1996a; Verstraete and Terpak, 1997). In our study, the tooth most often missing in cats below the age of one year was the maxillary second premolar. As in previous studies (Verstraete *et al.*, 1996a; Verstraete and Terpak, 1997), the location of the supernumerary teeth was most often in the region of the maxillary second premolar.

Plaque and gingivitis were seen in the majority of cats (87.5% and 73.2%, respectively). Very few people brush their cat's teeth, so this was to be expected. The study was conducted before the release of adjunctive aids such as 'dental diets' and 'dental treats', so most cats were not receiving any preventative measures to keep their teeth clean. The incidence of gingivitis in our survey is higher than that reported in a Swiss study of 200 cats that received clinical oral examination (Schlup, 1982). This study reports a 57% incidence of periodontal disease, i.e. gingivitis and/or periodontitis. About 18% of the cats in Schlup's study (1982) had moderate to severe periodontal disease, which is similar to our findings.

Odontoclastic resorptive lesions (FORL) were seen in 25% of the cats. This is very comparable to other studies of mixed populations of cats in which radiography was not routinely used (Schlup, 1982; Harvey, 1992). A recent study of a healthy population in the United Kingdom of a comparable age group shows an

incidence of 29% (Ingham *et al.*, 2001). In this study, however, all cats had full mouth radiographs, making detection of resorptive lesions more reliable, and none of the cats were regarded as having 'oral disease'. A study of a group of randomly chosen Swedish cats showed an incidence of 32% (Pettersson and Mannerfelt, 2003). In this study, diagnosis included radiographic examination.

When only cats presented for dental problems are examined, the prevalence rates are much higher. The incidence rates reported from all over the world vary between 48% and 71.7% (Van Wessum *et al.*, 1992; Crossley DA, 1991; Clarke, 1997; Gioso *et al.*, 1999; Lukman *et al.*, 1996; Harvey *et al.*, 2004; Lommer and Verstraete, 2000; Lommer and Verstraete, 2001; Scarlett, 1998), depending on the mean age of the group and whether radiography was routinely used or not.

Stomatitis was frequently seen, partly because of the mixed nature of the population: one-third of the cats presented for oral disease were presented for chronic stomatitis. Any inflammation exceeding gingivitis or periodontitis was considered to be stomatitis, a classification which therefore included buccostomatitis and faucitis, conditions that were not necessarily both present in the same cat, and which could be acute or chronic.

The prevalence of periodontitis, FORL and stomatitis increased with age, as reported in most other studies. Gengler *et al.* (1995) reports an incidence of more than 50% periodontitis over the age of 5 years in 81 randomly selected cats. These cats were both clinically and radiographically examined. From 7 years of age, 40% of these cats had advanced periodontitis, which is similar to the results found in our study. Only one report (Lommer and Verstraete, 2001) found no difference in the prevalence of periodontitis between young cats and the general population examined, but this study consisted of radiographic examination of a population of dental patients and therefore the reported prevalence may not reflect the true prevalence in a general cat population. FORL were seen in the youngest age group, (below one year), increasing to 55.4% above the age of 8 years.

No marked differences in periodontal status could be seen between the male and female cats in our study. Some studies mention a higher incidence of FORL in males than in female cats (Schlup, 1982; Van Wessum *et al.*, 1992). Lund *et al.* (1998) found a higher incidence in female cats than in males. Gender was not

found to have any effect on FORL either in our population or in several other reports (Coles, 1990; Lukman *et al.*, 1996; Clarke, 1997; Scarlett *et al.*, 1998). One interesting finding was that male castrates were affected with stomatitis twice as often as female castrates. This fact, which has not been reported previously, requires further investigation of a larger group of cats diagnosed with chronic stomatitis.

Of all the breeds represented in this survey, only a few were in groups large enough to draw any conclusions: the Domestic Shorthair and Longhair, the Persian and Exotic Shorthair, and the combined groups of European Shorthair (combining British Shorthair, European Shorthair and Chartreux) and Oriental shorthair (combining Oriental Shorthair and Siamese). Persian and Exotic Shorthair cats had more periodontitis at a younger age than any other group of breeds. The incidence of FORL was comparable for DSH/DLH and Persian/Exotic Shorthair cats. The Oriental Shorthair cats showed a higher incidence of resorptive lesions, though mean age of this group was higher (mean 6.7 years) than the overall population (4.5 years), so at least part of the difference is caused by age. The European shorthair cats showed a much lower incidence of resorptive lesions, with a mean age comparable to the overall population. The purebred cats, and especially the Siamese, are sometimes mentioned as being more frequently affected by FORL than are domestic cats (Van Wessum *et al.*, 1992; Schlup, 1982; Clarke, 1997). Van Wessum *et al.* (1992) found that the Persian cats were less often affected, but that they were affected at a younger age.

Cats eating soft food had more periodontitis than cats eating dry food or a combination of soft and dry food, though they did not show a higher incidence of plaque and gingivitis. The effect of 'dental diets' and 'dental chews' was not evaluated, since these adjunctive aids were not yet available for cats at the time. Cats in the soft food group were older than cats eating dry food or a mix of dry and soft food, so they would be expected to have more problems. Furthermore, cats with advanced periodontal disease are likely to experience some degree of pain, making them less likely to eat dry food. Only the presence of plaque and/or gingivitis were assessed in our study, and not the degree of the conditions. Plaque was not disclosed, so only significant amounts were regarded as 'plaque present'.

Cats eating soft food had more FORL than cats eating dry food or a mixed diet, but they were older and therefore expected to have more problems. No significant difference was seen between cats eating a

mixed diet and cats eating dry food only. Schlup (1982) found a higher incidence of resorptive lesions in cats receiving a high amount of raw liver, and no effect of other feeding regimens. Pettersson and Mannerfelt (2003) found more lesions in cats eating dry and soft food than in cats eating dry food only. Lund *et al.* (1998) could not find a difference related to type of food or amount of feeding times, but they did find more resorptive lesions in cats fed a diet low in magnesium. Recently, chronic excess dietary intake of vitamin D has been suggested as an important etiologic factor in the development of FORL (Reiter, 2003).

Forty percent of the cats receiving soft food only were diagnosed as having stomatitis. Pain while eating is the most common reason for presenting animals affected by stomatitis, and most of the time the affected individuals are reluctant to eat dry food.

Different lifestyles (living inside, allowed to go outside, hunting or not) do not seem to affect periodontal status. No differences could be seen between the different groups. This corresponds well to other studies, in which it has been shown that a 'natural lifestyle' (feral cat, housecat roaming outside and hunting) does not protect against periodontal disease (Schlup, 1982; Verstraete *et al.*, 1996b; Clarke D, 1997a). Lifestyle in our study does not affect the incidence of FORL, but of course none of the cats were relying on prey only. Other studies have shown marked differences between pet cats and wild roaming cats when it comes to FORL (Levin *et al.*, 1996; Verstraete *et al.*, 1996b). The latter were relying on prey all the time, and age was impossible to evaluate. Forty-five feral cats examined in Australia showed an incidence of 9%, but the age of this group of cats was less than two years (Clarke, 1997b). It was therefore concluded by the author that natural diet does not protect against FORL. Lund *et al.* (1998) did not see any correlation between lifestyle (indoor/outdoor) and resorptive lesions in a group of 145 cats, but cats drinking city water versus cats drinking well water were more likely to have lesions. Scarlett *et al.* (1999) conclude in a study of 59 cats that cats spending more time outdoors or living in a rural residence, or both, may have reduced risk, perhaps because of access to supplementation of their diet with natural prey. The results in our study do not support this.

CONCLUSION

Oral disease is very common in cats, and it should get a lot more attention in veterinary practice. In this young population, one out of four cats had resorptive lesions, and one out of five had advanced periodontal disease. Since periodontal disease is a preventable disease, more attention in veterinary medicine should be given to this aspect of every cat's health. Because of the high incidence of advanced periodontitis and FORL, the dental diagnosis and treatment of cats should include not only scaling and polishing but also routine radiographic examination and possibly extractions.

ACKNOWLEDGEMENTS

The data reported here was collected from the private practices of the authors and the following veterinarians: Stefaan Derdeyn, Marc Dieltiens, Veerle Durnez, Justine Meulemans, Sophie Odent, Marleen Rober, Jeanine Sauviller, Sara Van Cauwelaert and Johan Van Ommen. Special thanks to all of them!

REFERENCES

- Clarke D., (1997a). Dental conditions in feral Australian cats. *Proceedings of the 5th World Veterinary Dental Congress*.
- Clarke D. (1997b). Feline dental resorptive lesions in domestic and feral cats and the possible link with diet. *Proceedings of the 5th World Veterinary Dental Congress*.
- Coles S. (1990). The prevalence of buccal cervical root resorptions in Australian cats. *Journal of Veterinary Dentistry* 7, 14-16.
- Crossley DA, (1991). Survey of Feline Dental Problems encountered in a small animal practice in NW England. *British Veterinary Dental Association Journal* 2, 3-6.
- Gengler W, Dubielzig R, Ramer J, (1995). Physical examination and radiographic analysis to detect dental and mandibular bone resorption in cats: a study of 81 cases from necropsy. *Journal of Veterinary Dentistry* 12, 97-100.
- Gioso MA., Correa HL., Venturini MAFA., Mello MGP., Coelho ALM., Lacerda MS. (1999). Prevalence of Feline Odontoclastic Resorptive Lesions in three different cities in Brazil. *Proceedings of the 6th World Veterinary Dental Congress*.
- Harvey CE, (1992). Epidemiology of periodontal conditions in cats. *Proceedings of the 1st European Congress of Veterinary Dentistry*.
- Harvey CE., Orsini P., McLahan C, Schuster C. (2004). Mapping of the radiographic central point of Feline Dental Resorptive Lesions. *Journal of Veterinary Dentistry* 21, 15-21.
- Ingham KE., Gorrel C., Blackburn J., Farnsworth W. (2001). Prevalence of odontoclastic resorptive lesions in a population of clinically healthy cats. *Journal of Small Animal Practice* 42, 439-443.
- Levin J., Emily P., Frost P. (1996). The prevalence of odontoclastic resorptive lesions in feral, domestic and exotic felids. *Proceedings of the 8th Annual Meeting of the British Veterinary Dental Association*.
- Lommer MJ., Verstraete FJM. (2000). Prevalence of odontoclastic resorption lesions and periapical radiographic lucencies in cats: 265 cases (1995-1998). *Journal of the American Veterinary Medical Association* 217, 1866-1869.
- Lommer MJ., Verstraete FJM. (2001). Radiographic patterns of periodontitis in cats: 147 cases (1998-1999). *Journal of the American Veterinary Medical Association* 218, 230-234.
- Lukman K., Pavlica Z., Juntas P. (1996). Prevalence patterns and histological survey of Feline Dental Resorptive Lesions. *Proceedings of the 8th Annual Meeting of the British Veterinary Dental Association*.
- Lund EM., Bohacek LK., Dahlke JL. (1998). Prevalence and risk factors for odontoclastic resorptive lesions in cats. *Journal of the American Veterinary Medical Association* 212, 392-395.
- Pettersson A., Mannerfelt T. (2003). Prevalence of Dental Resorptive Lesions in Swedish Cats. *Journal of Veterinary Dentistry* 20, 140-142.
- Reiter AM., Mendoza KA. (2002). Feline odontoclastic resorptive lesions: an unsolved enigma in veterinary dentistry. *The Veterinary Clinics of North America, Small animal practice* 32, 791-837.
- Reiter AM. evaluation of serum concentrations of calcitropic hormones in cats with feline odontoclastic resorptive lesions. *Proceedings of the 17th Annual Veterinary Dental Forum*.
- Scarlett JM., Saidla J., Hess J. (1999). Risk factors for odontoclastic resorptive lesions in cats. *Journal of the American Animal Hospital Association* 35, 188-192.
- Schlup D. (1982). Epidemiologische und morphologische Untersuchungen am Katzengebiss I. Mitteilung: Epidemiologische Untersuchungen. *Kleintierpraxis* 27, 87-94.
- Van Wessum R., Harvey CE., Hennes P. (1992). Feline dental resorptive lesions: prevalence patterns. *The Veterinary Clinics of North America Small Animal Practice* 22, 1405-1416.
- Verhaert L. (2002). Gebits- en mondproblemen bij de kat - diagnose, behandeling en preventie. *Vlaams Diergeneeskundig Tijdschrift* 71, 100-108.
- Verstraete FJM., van Aarde RJ., Nieuwoudt BA., Mauer E., Kass PH. (1996a). The dental pathology of feral cats on Marion Island, part I: congenital, developmental and traumatic abnormalities. *Journal of Comparative Pathology* 115, 265-282.
- Verstraete FJM., van Aarde RJ., Nieuwoudt BA., Mauer E., Kass PH. (1996b). The dental pathology of feral cats on Marion Island, part II: Periodontitis, external odontoclastic resorption lesions and mandibular thickening. *Journal of Comparative Pathology* 115, 283-297.
- Verstraete FJM., Terpak CH. (1997). Anatomical variations in the dentition of the domestic cat. *Journal of Veterinary Dentistry* 14, 137-140.
- Verstraete FJM., Kass PH., Terpak CH. (1998). Diagnostic value of full-mouth radiography in cats. *American Journal of Veterinary Research* 59, 692-695.