

## LEAD INTOXICATION BY INGESTION OF LEAD SHOT IN RACING PIGEONS (*Columba livia*)

*Een geval van loodintoxicatie bij sportduiven*

P. Tavernier<sup>1</sup>, S. Roels<sup>2</sup>, K. Baert<sup>3</sup>, K. Hermans<sup>1</sup>, F. Pasmans<sup>1</sup>, K. Chiers<sup>1</sup>

<sup>1</sup>Department of Bacteriology, Pathology and Poultry Diseases,  
Faculty of Veterinary Medicine, Ghent University,  
Salisburylaan 133, B-9830 Merelbeke, Belgium

<sup>2</sup>Pathology Unit, Department of Biocontrol, Veterinary and Agrochemical Research Centre (CODA/CERVA),  
Groeselenberg 99, B-1080 Brussel

<sup>3</sup>Ministry of the Flemish Community, Institute for Forestry and Game Management (IBW),  
9500 Geraardsbergen  
paul.tavernier@UGent.be

### ABSTRACT

Acute lead poisoning caused by ingestion of lead shot was diagnosed in two young racing pigeons that had been feeding on a meadow where lead shot was available. One bird showing a blood level of 7000 µg/l lead died despite calcium disodium EDTA treatment, while the other was saved.

### SAMENVATTING

Acute loodvergiftiging door opname van loodhagel werd vastgesteld bij twee jonge duiven die foerageerden op een weide waar frequent geschoten werd. Eén duif die een bloedconcentratie van 7000 µg/ml lood vertoonde, stierf ondanks calciumdinatrium EDTA-behandeling. Het andere dier kon gered worden.

### INTRODUCTION

Lead intoxication in birds by ingestion of lead shot has been recognised in many countries since Bellrose (1959) first described the long-term devastating effects on wild waterfowl populations. Secondary intoxication occurs in raptors preying on waterfowl (Müller *et al.*, 2001). A wide variety of other bird species have been found susceptible to lead intoxication by mistaking lead shot for grit or food particles (Scheuhammer and Norris, 1995).

Only few descriptions of clinical cases of lead intoxication in pigeons are available. We comment a case of lead intoxication by ingestion of lead shot in a loft of racing pigeons. Similar casualties in domestic birds might reflect a more widespread intoxication problem in wildliving birds in Belgium.

### CASE DESCRIPTION

Two pigeons of about 8 months old were presented in August 2004 with complaints of a distended crop and regurgitation of liquids. They belonged to a loft of 20 young pigeons, which during their daily flights alighted and fed on a nearby meadow where frequent shooting activity was noticed during and beyond the hunting season. The owner reported having seen similar cases in former years.

On clinical examination the two pigeons were thin and anaemic and displayed an unusual behaviour characterised by lethargy and a backwards stretching of the neck. Simultaneous lateral to and fro rolling movements of the distended crop could be seen under the skin. Deep palpation of the crops induced regurgitation of foul smelling liquid crop contents. In one pigeon ptosis was obvious. The urate fraction of the excreta was watery in one pigeon and a soft consistency of the faeces was noticed in both.

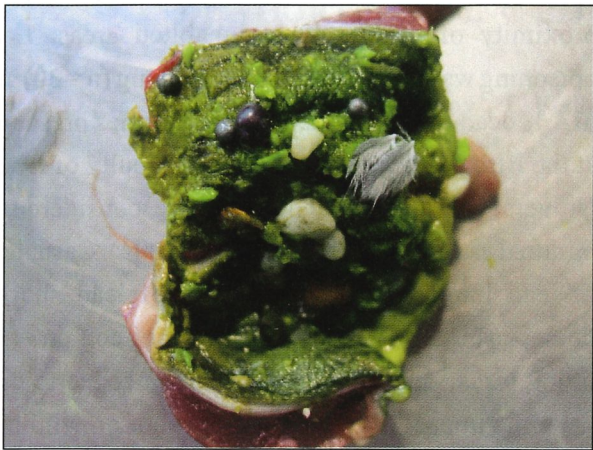


Fig. 1. Crop contents with leadshot exposed.

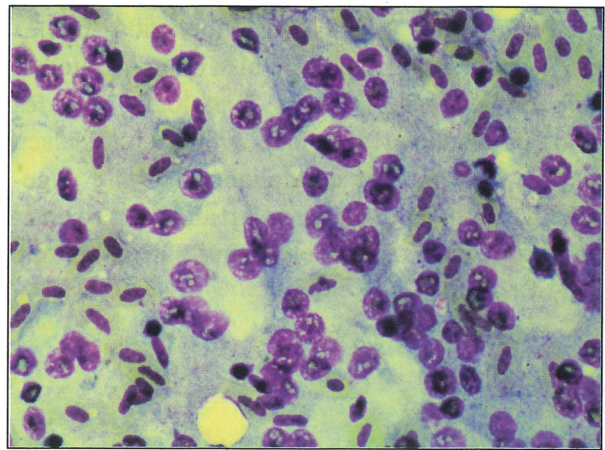


Fig. 2. Intranuclear inclusion bodies in the kidney.

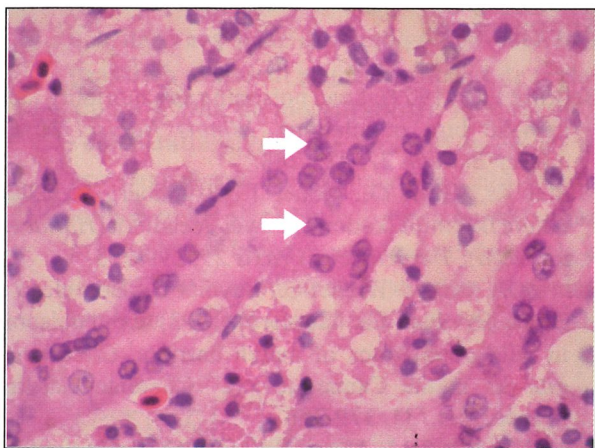


Fig. 3. Renal tubular nephropathy. Lead inclusion bodies in the nuclei of the tubular epithelial cells (arrows). Haematoxylin-eosin stain.

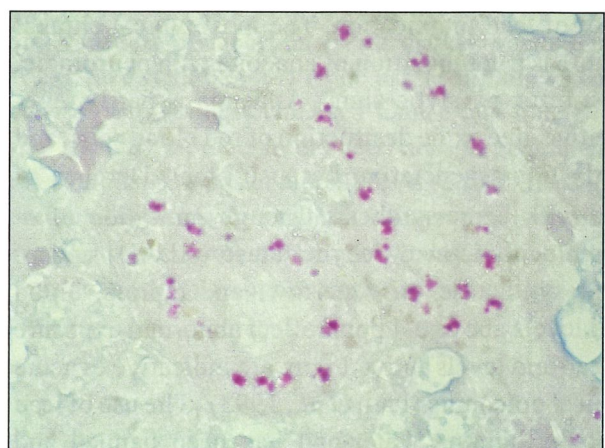


Fig. 4. Renal tubular nephropathy. Red staining acid-fast intranuclear inclusion bodies. Ziehl Neelsen stain.

In the differential diagnosis we retained crop infection by trichomoniasis or candidiasis, adenovirus infection, salmonellosis and heavy metal intoxications including lead and zinc. Newcastle disease (paramyxovirus 1) was not considered because all the pigeons on the loft had been vaccinated secundum artem.

Microscopical examination of a wet crop swab (magnification x100) was negative for *Trichomonas gallinae*. A second crop swab was rolled on a glass slide, stained with Hemacolor® (Merck, Darmstadt, D.) and examined under immersion microscopy (x1000). No trichomonads nor *Candida albicans* could be detected but numerous lactobacilli were present on the smear. A whole body radiograph of one pigeon confirmed the wide distention of the crop, which contained grit and food particles. In the gizzard one round radiopaque pellet, probably lead shot, could be easily distinguished from the grit particles. A heparinised blood sample was taken in the same

pigeon. Haematological examination of a blood smear stained with Hemacolor (Merck, Darmstadt, Germany) showed numerous erythroblasts, polychromatic erythrocytes and reticulocytes, indicating a severe regenerative anaemia. Atomic absorption spectrophotometry performed in a commercial laboratory showed a blood lead concentration exceeding 7 ppm (7000 µg/l).

The two pigeons were treated by I.M. injection of 40 mg/kg calcium disodium EDTA twice daily in intermittent 5 day courses. No grit was offered because the grinding action of grit favours the fragmentation and ionisation of lead in the gizzard. Mineral oil was administered orally instead of attempting surgery to eliminate the lead shot.

The pigeon in which the high blood lead concentration was found, died after five days of treatment. A post-mortem radiograph and a necropsy revealed 11 lead pellets in the gizzard (fig. 1) and in the intestine, whereas only the biggest one had been seen on the



first radiograph. An impression smear of the kidney showed numerous intranuclear inclusion bodies (Fig. 2). These inclusions were also demonstrated in Haematoxylin-Eosin stained histological slides (Fig. 3) and stained acid-fast with Ziehl-Neelsen (Fig. 4). Many tubular epithelial cells were degenerated. The other bird became alert and showed good appetite, but was still anaemic and slim after one month of treatment.

## DISCUSSION

The cytotoxic nature of lead and its capacity of inhibiting important enzymatic processes are responsible for the wide variety of symptoms observed in cases of lead intoxication. The most typical clinical picture is a combination of anaemia with neurologic, most often paralytic signs. Anaemia is partly regenerative, due to the destruction of red blood cells, and partly non-regenerative because of interference of lead with heme-synthesis through inhibition of  $\delta$ -aminolevulinic-acid-dehydratase (ALAD) and of heme-synthetase. In waterfowl and raptors, blood lead levels above 0.4 ppm reflect abnormal exposure to lead and levels above 1 ppm are indicative of acute clinical poisoning (Pain *et al.*, 1993). The use of lead shot for hunting waterfowl has been banned and replaced by the use of steel shot in a number of countries. In the Netherlands and in Denmark the use for any kind of hunting, as well as the possession of lead shot, is forbidden. In Belgium, though lead shot is still used for hunting, no information is available on the impact of lead intoxication on wild or domestic birds. Due to the high density of building in this

country, hunting is often taking place in the close proximity of backyards in inhabited areas. Lead poisoning was diagnosed in 16.6 % living ( $n=30$ ) and in 4 % dead ( $n=99$ ) domestic anseriformes presented at the Bird Clinic of the Veterinary Faculty of Ghent University. These percentages were considered as minimal estimates (Tavernier *et al.*, 2004). Casualties of lead intoxication by ingestion of lead shot in domestic birds might indicate similar effects on wild-living birds. A systemic approach is needed to evaluate the impact of the use of lead shot on wild bird populations in Belgium.

## REFERENCES

- Bellrose F.C. (1959). Lead poisoning as a mortality factor in wild bird populations. *Illinois Natural History Survey Bulletin* 27, 235-288.
- Müller K., Krone O., Göbel T., Brunnberg L. (2001). Akute Bleiintoxikation bei zwei Seeadlern (*Haliaeetus albicilla*). *Tierärztliche Praxis* 29, 299-213.
- Pain D.J., Amiard-Triquet C., Bavoux C., Burneleau G., Eon L., Nicolau-Guillaumet P. (1993). Lead poisoning in wild populations of march harriers, *Circus aeruginosus* in the Camargue and Charente-Maritime, France. *Ibis* 135, 379-386.
- Scheuhammer A.M., Norris S.L. (1995). Toxicity of lead shot and sinkers (Ch.3). In: Review of the environmental impacts of lead shotshell ammunition and lead fishing weights in Canada. Canadian Wildlife Service, *Occasional Paper n°88*, Ottawa.
- Tavernier P., Cauwerts K., Van Caelenbergh A., Pasmans F., Martel A., Hermans K. (2004). Twee gevallen van loodintoxicatie bij anseriformes. *Vlaams Diergeneeskundig Tijdschrift* 73, 303-306.