

ANAESTHESIA OF A HORSE WITH ATRIAL FIBRILLATION

Anesthesie van een paard met atriumfibrillatie

S. Schauvliege¹, G. van Loon², V. Martin-Bouyer¹, F. Gasthuys¹

¹Department of Surgery and Anesthesiology of Domestic Animals,

²Department of Internal Medicine of Large Domestic Animals,

Faculty of Veterinary Medicine, Ghent University, Salisburylaan 133, B-9820 Merelbeke

stijn.schauvliege@UGent.be

ABSTRACT

A 25-year-old Belgian Warmblood mare with pre-existing atrial fibrillation was presented for surgical treatment of sinusitis. Echocardiography evidenced signs of compromised cardiovascular function, including a decreased contractility of the left ventricle and mitral valve insufficiency. The horse was treated with 2.2 µg/kg digoxin IV, followed by 11 µg/kg orally twice a day for one week before surgery. Premedication consisted of 0.02 mg/kg acepromazine IM and 80 µg/kg romifidine IV. Anesthesia was induced with 0.06 mg/kg midazolam and 2.2 mg/kg ketamine IV and maintained with isoflurane in oxygen. During the anesthesia, a continuous rate infusion with lidocaine (bolus 1.5 mg/kg, then 1.7 mg/kg/h) was administered and a temporary ventricular pacing unit, placed preoperatively, was available to treat possible bradycardia. Dobutamine was used to increase blood pressure but was accompanied by an obvious increase in heart rate. No major problems were encountered during the course of the anesthesia and recovery.

SAMENVATTING

Een 25 jaar oude Belgische warmbloedmerrie met atriumfibrillatie werd aangeboden voor chirurgische correctie van een sinusitis van de maxillaire linkersinus. Tekenen van verminderde contractiliteit van het linkerventrikel en mitralisinsufficiëntie werden vastgesteld met echocardiografie. Het paard werd gedurende één week vóór de operatie behandeld met digoxine (2,2 µg/kg IV, gevolgd door 11 µg/kg per oraal b.i.d.). De premedicatie bestond uit 0,02 mg/kg acepromazine IM en 80 µg/kg romifidine IV. De anesthesie werd geïnduceerd met 0,06 mg/kg midazolam en 2,2 mg/kg ketamine IV en onderhouden met isofluraan en zuurstof. Tijdens de anesthesie werd een continu infuus met lidocaïne (bolus 1,5 mg/kg, daarna 1,7 mg/kg/h) toegediend. Een tijdelijke, preoperatief geplaatste, ventriculaire pacemaker was beschikbaar om eventuele bradycardie te behandelen. Om de bloeddruk op peil te houden werd dobutamine toegediend met een duidelijke stijging van de hartfrequentie tot gevolg. Zowel tijdens de anesthesie als tijdens de recovery traden geen bijzondere problemen op.

INTRODUCTION

Atrial fibrillation (AF) is the most frequently diagnosed clinically important arrhythmia in horses (Deem and Fregin, 1982). Reported prevalences range from 0.23% to 2.40% (Holmes *et al.*, 1969; Deem and Fregin, 1982) and the most common complaint in these horses is reduced performance (Deem and Fregin, 1982). If no underlying cardiac disease is present, no symptoms are observed at rest. During exercise, however, the atrial contribution to ventricular filling becomes important,

as the time for ventricular filling is reduced by the increasing heart rate, resulting in decreased cardiac output (Blissitt, 1999).

In horses with AF, auscultation reveals an "irregularly irregular" rhythm with a variable intensity of the heart sounds and without an audible atrial heart sound (S4). The heart rate is normal when there is no underlying cardiac disease (Fregin, 1971; Bertone and Wingfield, 1987; Blissitt, 1999) and a pulse deficit can be present (Else and Holmes, 1971; Fregin, 1971; Deem and Fregin, 1982). Typical findings on the electrocardio-

gram (ECG) include an irregular R-R interval, a lack of P waves and the occurrence of f waves, while the configuration of the QRS-T complexes is normal (Fregin, 1971; Bertone and Wingfield, 1987; Manohar and Smetzer, 1992; Blissitt, 1999).

Although the incidence of AF is quite high, only a few case reports have been published about anesthesia of horses with pre-existing AF (Muir and McGuirk, 1984; Marr *et al.*, 1994) or about AF occurring during or after anesthesia (Muir and McGuirk, 1984; Hubbell *et al.*, 1986; Gasthuys *et al.*, 1988). This case report describes the peri-operative management of a horse with pre-existing AF.

CASE DETAILS

History

A 25-year-old Belgian Warmblood mare with a body weight of 474 kg was presented to the clinic with problems of nasal discharge that had been occurring the past 8 weeks. The horse had been treated with antibiotics (trimethoprim + sulfadiazine sodium, Emdotrim 60% mix®, Ecuphar, Oostkamp, Belgium) for 1 month, without obvious clinical improvement. Endoscopic and radiographic examination revealed a sinusitis of the left maxillary sinus. A surgical intervention was planned.

Pre-anesthetic examination

The horse had clinical signs of Cushing's disease such as reduction of muscle mass, altered fat deposition, pendulous abdomen, curly hair coat, hirsutism and hyperhidrosis (Fey *et al.*, 1998; Sgorbini *et al.*, 2004). Temperature and respiratory rate were normal. The respiration was costo-abdominal and auscultation of the lungs revealed no abnormalities.

Auscultation of the heart revealed an "irregularly irregular" rhythm with a frequency of 52 beats per minute (BPM). A left-sided holosystolic murmur (degree 2/6) was present. Electrocardiography showed

clear signs of AF: irregular R-R intervals with normal QRS morphology, presence of f waves and absence of P waves (Fig. 1).

Cardiac ultrasound (VingMed CFM 800 SV®, GE Medical Systems, Diegem, Belgium) revealed a decreased contractility of the left ventricle on the M-Mode (fractional shortening 25%). The A-peak of the mitral valve was not visible in M-mode. The Color Flow Doppler showed a moderate mitral regurgitation.

On the basis of these findings, the horse was regarded as an ASA (American Society of Anesthetists) class III patient, which indicates that the patient has moderate systemic disease with functional limitations.

Pre-operative management

In order to improve left ventricular inotropy, the horse was treated with a loading dose of 2.2 µg/kg digoxin IV (Lanoxin®, GlaxoSmithKline, Genval, Belgium), followed by 11 µg/kg orally twice a day for 1 week prior to anesthesia. The day before the operation, neomycin and penicillin (Neopen®, Intervet Belgium, Mechelen, Belgium), flunixin meglumine (Emdofluxin®, Ecuphar, Zuienkerke, Belgium) and tetanus antiserum (Anti-tetanusserum®, Intervet Belgium, Mechelen, Belgium) were administered. The treatment with antibiotics and NSAID's was repeated on the day of surgery.

On the morning of the operation, 0.02 mg/kg acepromazine (Placivet®, Codifar, Wommelgem, Belgium) was administered intramuscularly. Thirty minutes later, the skin of the left jugular vein was surgically prepared and, after local anesthesia (1 cc lidocaine 2% (Xylocaine 2%®, AstraZeneca, Zoetermeer, the Netherlands)), an 8.5 F introducer sheath (Intro-flex®, Baxter, Germany) was placed in the lower third of the vein. A bipolar temporary pacing catheter (Bipolar Intracardiac Electrode®, USCI Bard, USA) was inserted via the jugular vein and advanced into the right atrium. Catheter positioning was guided by cardiac ultrasound and by monitoring both the surface ECG and the electrogram from the pacing catheter. The intra-atrial electrogram was recorded and showed that

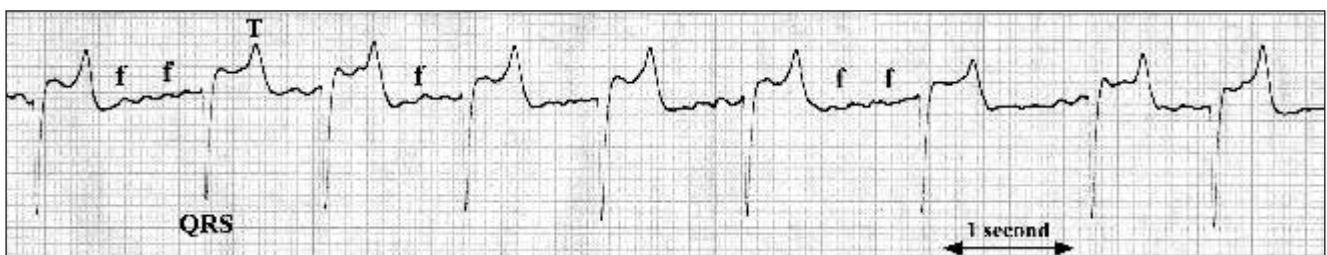


Figure 1. Base-apex ECG indicating atrial fibrillation because of the presence of f waves (f), the absence of P waves, normal QRS-T complexes and irregular R-R intervals.

the AF cycle length was 133 ms, which corresponds to an AF rate of 450/min. Subsequently, the catheter tip was advanced into the caudal region of the right ventricular apex so that consistent capture was achieved with an output of 3.5 Volt and 0.5 ms. The external pacing unit (Thera D ®, Medtronic and Programmer 9790, Medtronic, Minneapolis, USA) was disconnected but the pacing catheter was kept in place. The pacing unit was standby throughout the entire anesthetic procedure. Right ventricular pacing, at a rate of 40 BPM and with an output of 7.5 Volt and 0.5 ms, was only to be initiated if bradycardia (< 40 BPM) occurred during anesthesia.

The horse was sedated with 80 µg/kg romifidine IV (Sedivet ®, Boehringer Ingelheim, Brussels, Belgium). Anesthesia was induced with 2.2 mg/kg ketamine IV (Anesketin ®, Eurovet, Heusden-Zolder, Belgium) and 0.06 mg/kg midazolam IV (Dormicum ®, Roche, Brussels, Belgium). An orotracheal tube (Soft rubber tracheal tube, Willy Rüsck AG, Kernen, Germany) of 28 mm diameter was placed blindly.

Perioperative management

General anesthesia was maintained with isoflurane (Isoflo ®, Abbott Laboratories Ltd., Queenborough, Kent, United Kingdom) in oxygen, using a large animal anesthetic unit (Matrix medical inc., Orchard Park, New York, USA + Sulla 909V ®, Dräger, Lübeck, Germany) with an out-of-circuit vaporizer (Drägerwerk AG, Lübeck, Germany) and a large animal respirator (Smith respirator LA 2100 ®, model 2002, Veterinary Technics/BDO-Medipass, Hoogezand, the Netherlands). The oxygen flow was started at 6 L/min and decreased to 4 L/min after 10 minutes. Lactated Ringer's solution (Haemofiltration Formula E2, Clear-Flex ®, Bieffe Medital, Grosotto, Italy) was infused during the anesthesia, which lasted 120 minutes. Surgery included a sinusotomy (creating a sinus flap) to remove the infected tissue and rinse the sinus.

Monitoring of the patient included multi-gas analysis, pulse oxymetry (Capnomac Ultima ®, Datex, Helsinki, Finland), electrocardiography and direct blood pressure measurement from the facial artery (Servomed ®, Hellige, Freiburg, Germany), using a 21G butterfly catheter (Surflo ® Winged infusion set, Terumo Europe, Leuven, Belgium). Arterial blood samples were taken every 30 minutes for analysis of PaO₂, PaCO₂ (Fig. 2), saturation, pH, base excess, tCO₂ and bicarbonate (ABL5 ®, Radiometer, Copenhagen, Denmark).

An initial bolus of 1.5 mg/kg lidocaine was administered to the horse over a period of 10 minutes. Subsequently, a continuous rate infusion (CRI) of lidocaine was started at a rate of 1.7 mg/kg/h. Thirty minutes post induction, the rate was decreased to 1.3 mg/kg/h, followed by a further decrease to 0.8 mg/kg/h at 60 minutes post induction. The CRI of lidocaine was terminated 40 minutes before the end of surgery (Fig. 2).

Initially, the horse was allowed to breathe spontaneously. Fifteen minutes post induction, respiration was assisted because of the low PaO₂ (80 mm Hg). The tidal volume was set at 5 L, and the maximal inspiratory pressure at 20 cm H₂O. Thirty minutes post induction, the PaO₂ was 138 mm Hg. Fifty minutes post induction, respiration was both assisted and controlled, with the minimal respiratory frequency set at 8 times per minute, because of the rather high PaCO₂ (66 mm Hg). By ninety minutes post induction, the PaCO₂ had decreased to 56 mm Hg (Fig. 2).

Ten minutes post induction, the mean arterial pressure (MAP) was 108 mm Hg. It gradually decreased to 65 mm Hg at 55 minutes post induction, at which time dobutamine (Dobutamine Mayne ®, Mayne Pharma, Brussels, Belgium) was administered as a CRI at a rate of 0.35 µg/kg/min. The blood pressure increased to 76 mm Hg 15 minutes later and the rate of the CRI of dobutamine was decreased to 0.25 µg/kg/min. Another 15 minutes later (85 minutes post induction), the rate was further decreased to 0.20 µg/kg/min. This rate was maintained until the end of the surgery. MAP remained between 75 and 80 mm Hg (Fig. 2).

The heart rate remained between 50 and 60 BPM during the first hour. After one hour, it decreased to 40 BPM. Ten minutes later, the heart rate had increased

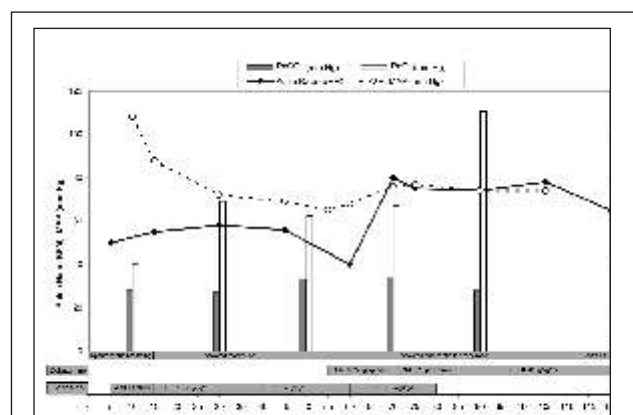


Figure 2. Values for heart rate (beats per minute, BPM), mean arterial pressure (MAP) (mm Hg), arterial carbon dioxide (PaCO₂) (mm Hg) and arterial oxygen (PaO₂) (mm Hg) during anesthesia. The grey bars on the X-axis indicate the time when drugs were administered (CRI = continuous rate infusion) and when respiration was changed.

to 80 BPM and remained between 70 and 80 BPM until the end of anesthesia (Fig. 2).

After 70 minutes of anesthesia, physiological saline (NaCl 0.9%, Vascumed, Ghent, Belgium) was given as infusion fluid because the base excess exceeded 5 mmol/L.

By the time the operation was nearly finished, the horse was spontaneously breathing 10 times per minute, so the horse was only assisted in respiration instead of being assisted and controlled. At the end of anesthesia, the horse received 0.17 mg/kg xylazine IV (Xyl-M®, V.D.M., Arendonk, Belgium).

Recovery

The recovery was uneventful. The orotracheal tube was removed after ten minutes. Five minutes later, the horse got into sternal recumbency and fifteen minutes later, with the assistance of head and tail ropes, the horse was standing.

DISCUSSION

To the authors' knowledge, there are only a few reports about the anesthesia of horses with AF. Hubbell *et al.* (1986) reported that cardiac output and arterial blood pressure in a Standardbred horse with AF (with no other signs of cardiac disease) under general anesthesia were not markedly different from those seen in healthy horses. Marr *et al.* (1994) stated that a horse with AF, but no other cardiac disease, can usually maintain efficient circulation during anesthesia. Although human subjects with AF show an increased risk of stroke due to the development of atrial thromboemboli, this has not been reported in horses and there is no clear evidence of atrial thrombi at post mortem in horses with AF (Blissitt, 1999). On the other hand, the horse's ability to tolerate AF depends on good ventricular function and cardiovascular reflexes, both of which are usually depressed in an anesthetized horse (Marr *et al.*, 1994). Muir and McGuirk (1984) found a decrease in arterial blood pressure in 5 of 7 horses in which AF developed during anesthesia.

In a normal horse, the atria are responsible for approximately 15% of ventricular filling (Marr *et al.*, 1994). During AF, however, there is no concerted contraction of the atria (Bertone and Wingfield, 1987). As a result, filling of the ventricles occurs passively and is attributable only to the flow and pressure gradient transmitted from the venous and pulmonary capillary beds to the right and left ventricles (Muir and McGuirk, 1984). Therefore, ventricular filling becomes more dependent on the duration of diastole, and

the heart rate at which ventricular filling becomes critical will be lower (Miller and Holmes, 1984). At rest, the ventricular rate in horses with AF is protected by a high vagal tone, which causes a decreased conduction through the atrioventricular node and more concealed conduction (Bertone and Wingfield, 1987). Passive filling of the ventricle during the long diastole is sufficient to maintain a normal cardiac output (Muir and McGuirk, 1984). If there is ventricular disease or the animal is exercised, vagal tone decreases and the ventricular rate increases above normal values because of the higher number of impulses conducted through the atrioventricular node (Manohar and Smetzer, 1992). Once the heart rate exceeds 70 to 80 BPM, there is a rapid decrease in left ventricular ejection time and stroke volume (Miller and Holmes, 1984).

For these reasons, rate-control is important in patients with AF. Digitalis glycosides (promote decremental and concealed conduction), propranolol (a beta-blocker) or verapamil (a calcium channel blocker which slows electrical conduction in the heart) are used to control the ventricular rate in dogs with atrial fibrillation (Manohar and Smetzer, 1992). However, left ventricular end diastolic pressure (LVEDP) is related to the time for left ventricular filling as represented by pulse interval (PI), but the relationship tends to be non-linear: LVEDP increases less for larger values of PI. This confirms that most ventricular filling occurs in the early diastolic period. Consequently, there is a limit to the advantage of increasing the diastolic interval (Miller and Holmes, 1983). Our aim was to keep the heart rate above 40 BPM during anesthesia.

Because in patients with congestive heart failure, sympathetic tone is increased, the ventricular rate is much more rapid in the presence of AF (Manohar and Smetzer, 1992). If the ventricular rate of horses with AF exceeds 60-70 BPM, myocardial disease and dysfunction should be suspected (Bertone and Wingfield, 1987; Marr *et al.*, 1994). In the present case, the heart rate was 52 BPM. Nevertheless, the echocardiography of this horse revealed a compromised cardiovascular function, including a decreased left ventricular fractional shortening and moderate holosystolic regurgitation through the mitral valve. These findings are in agreement with the results of Marr *et al.* (1995), where the majority of horses with AF had evidence of left ventricular dysfunction and reduced fractional shortening. Furthermore, Reef *et al.* (1988) reported that mitral insufficiency was the most commonly detected valvular abnormality in horses with AF. In the absence of AF, moderate mitral regurgitation *per se*

would rather result in a normal to high left ventricular fractional shortening due to a decreased afterload.

The ideal solution in the present case would have been a conversion to normal sinus rhythm prior to anesthesia. However, the owner declined an oral quinidine sulphate treatment because of the associated risks (diarrhea, dyspnea, anorexia, weakness, colic, tachycardia, hypotension, fatal arrhythmias, ataxia, laminitis, urticaria, convulsions, ...) (Morris and Fregin, 1982; Bertone and Wingfield, 1987; Blissitt, 1999). In order to improve left ventricular contractility, digoxin was administered for one week just prior to surgery. The positive inotropic effects plus the negative chronotropic actions of digoxin increase cardiac output in AF horses, due to an increased end-diastolic volume at lower ventricular rates (Bertone and Wingfield, 1987). An initial intravenous bolus of digoxin followed by an oral treatment every 12 hours is generally recommended in horses (Sweeney *et al.*, 1993). In order to obtain an effective plasma level of digoxin, this treatment was continued for 1 week before surgery. A maximum contractile response can be expected with plasma digoxin concentrations of 2 ng/ml (Button *et al.*, 1980).

As digitalis glycosides decrease atrioventricular conduction during AF (Bertone and Wingfield, 1987; Keen, 1990), it was hypothesized that the combination of digoxin and sedation might result in bradycardia. Therefore, a temporary pacing catheter was placed in the right ventricle as a precaution to allow ventricular pacing if bradycardia should occur during anesthesia. This technique has been described elsewhere (van Loon *et al.*, 2001; van Loon *et al.*, 2002) and has been applied successfully for the treatment of peri-anesthetic bradycardia in a horse (van Loon *et al.*, 2005). One hour post-induction, the heart rate decreased to 40 BPM. However, pacing was not started since the continuous rate infusion of dobutamine resulted in a significant increase in heart rate to 80 BPM.

The use of sympathomimetics (dobutamine and dopamine) in horses with AF is controversial. On one hand, these drugs help to maintain an adequate blood pressure due to their positive inotropic effects. On the other hand, they could precipitate either rapid supraventricular tachycardia or ventricular arrhythmias in horses (Marr *et al.*, 1994). According to Staudacher (1989), sympathomimetics increase the risk of arrhythmias under the influence of digitalis glycosides. However, Taylor and Clarke (1999) stated that in horses with AF, dobutamine has been used to increase blood pressure and is the agent of choice if increasing fluid infusion does not resolve hypotension. In the

present case, MAP could be maintained above 70 mm Hg using the CRI of dobutamine. However, a major increase in heart rate was observed, which can usually only be observed using higher doses of dobutamine in normal horses ($>2.5\mu\text{g}/\text{kg}/\text{min}$) (Gasthuys *et al.*, 1991). Dobutamine increases atrioventricular nodal conduction (Bianchi *et al.*, 1975; Tisdale *et al.*, 1995; Nishikawa *et al.*, 1996), which can result in a marked increase in ventricular rate in the event of atrial fibrillation, even at low doses of dobutamine. Higher doses might even result in inadequate ventricular filling due to excessively high heart rates.

AF increases atrial pressure (Marr *et al.*, 1994). The mitral insufficiency observed in this horse further increased left atrial pressure and subsequently this could have been accompanied by pulmonary hypertension and pulmonary edema. Clinically, no overt signs of compromised respiratory function were observed.

As premedication, acepromazine and romifidine were used. Acepromazine has anti-arrhythmic properties and is assumed to reduce the amount of circulating catecholamines by calming the patient prior to sedation and induction (Marr *et al.*, 1994). This can be important in the event of AF: dogs with AF have an increased sympathetic tone, leading to a relative coronary vasoconstriction (an increase in coronary oxygen extraction despite an increase in coronary blood flow). Alpha-adrenoceptor blockade abolishes this coronary "vasoconstrictive" effect of AF (Wichmann *et al.*, 1983). As such, acepromazine could be beneficial in the event of AF, not only because it decreases circulating catecholamines, but also because it blocks alpha-receptors. However, high doses are not recommended since an intense alpha-adrenoceptor blockade could lead to hypotension (Marr *et al.*, 1994). In the present case, a low dose of acepromazine was combined with romifidine. In horses at risk of developing AF, sedation with an alpha-2 agonist should be avoided (Hubbell *et al.*, 1986), mainly because alpha-2 agonists increase vagal tone, which could contribute to the initiation of AF (Marr *et al.*, 1994).

Anesthesia was induced with midazolam and ketamine, and maintained with isoflurane in oxygen. One advantage of ketamine is that it supports cardiovascular function (Marr *et al.*, 1994). The advantage of using isoflurane over halothane is its lack of arrhythmogenesis, its ability to rapidly change anesthetic planes and its better cardiac output during controlled ventilation (Marr *et al.*, 1994). In horses at risk of developing AF, isoflurane is preferred over halothane since isoflurane, but not halothane, has been reported to have antifi-

brillatory effects in atrial tissue in dogs at 1.0 MAC (Freeman *et al.*, 1990).

Carbon dioxide has to be maintained within the normal ranges (35-45 mm Hg) in cardiac patients because hypercapnia has been shown to predispose to arrhythmias (Gaynor *et al.*, 1993). On the other hand, positive pressure ventilation can result in hypotension because of the negative effects on venous return. This effect could be even more pronounced in the event of AF, where atrial contractions are absent (Marr *et al.*, 1994). In the present horse, the blood pressure decreased, but could be restored using a low dose of dobutamine.

Lidocaine is the most effective antiarrhythmic used for the treatment of ventricular arrhythmias (Marr *et al.*, 1994). In addition, a CRI of lidocaine reduces the minimum alveolar concentration of volatile anesthetics (Doherty and Frazier, 1998; Valverde *et al.*, 2004), so that the cardiovascular depressant effects of volatile anesthetics are reduced.

In conclusion, the present report describes the pre- and peri-anesthetic management of a horse with AF. This patient was treated with digoxin because of pre-existing low fractional shortening. A temporary ventricular pacing unit was available, although bradycardia could be treated with standard drugs. High doses of dobutamine, however, should be avoided since they increase the heart rate above 70-80 BPM, which results in inadequate ventricular filling and thus reduced cardiac output.

REFERENCES

- Bertone J.J., Wingfield W.E. (1987). Atrial fibrillation in horses. *Compendium on Continuing Education for the Practicing Veterinarian* 9, 763-771.
- Bianchi C., Diaz R., Gonzales C., Beregovich J. (1975). Effects of dobutamine on atrioventricular conduction. *American Heart Journal* 90, 474-478.
- Blissitt K.J. (1999). Diagnosis and treatment of atrial fibrillation. *Equine Veterinary Education* 11, 11-19.
- Button C., Gross D.R., Johnston J.T., Yakatan G.J. (1980). Digoxin pharmacokinetics, bioavailability, efficacy and dosage regimens in the horse. *American Journal of Veterinary Research* 41, 1388-1395.
- Deem D.A., Fregin G.F. (1982). Atrial fibrillation in horses: a review of 106 clinical cases, with consideration of prevalence, clinical signs and prognosis. *Journal of the American Veterinary Medical Association* 180, 261-265.
- Doherty T.J., Frazier D.L. (1998). Effect of intravenous lidocaine on halothane minimum alveolar concentration in ponies. *Equine Veterinary Journal* 30, 300-303.
- Else R.W., Holmes J.R. (1971). Pathological changes in atrial fibrillation in the horse. *Equine Veterinary Journal* 3, 56-64.
- Fey K., Jonigkeit E., Moritz A. (1998). Equine Cushing syndrome (ECS). Case report, review of its diagnosis and therapy and substantial differences from Cushing syndrome in dogs. *Tierärztliche Praxis Ausgabe G, Grosstiere/Nutztiere* 26, 41-47.
- Freeman L.C., Ack J.A., Fligner M.A., Muir W.W. III (1990). Atrial fibrillation in halothane- and ioflurane-anesthetized dogs. *American Journal of Veterinary Research* 51, 174-177.
- Fregin G.F. (1971). Atrial fibrillation in the horse. *Proceedings of the 16th Annual Convention of the American Association of Equine Practitioners*, p. 383-388.
- Gasthuys F., De Moor A., Parmentier D. (1991). Influence of dopamine and dobutamine on the cardiovascular depression during a standard halothane anaesthesia in dorsally recumbent, ventilated ponies. *Zentralblatt für Veterinärmedizin Reihe A*, 38, 494-500.
- Gasthuys F., De Moor A., Picavet M.-T., Muylle E., Steenhaut M. (1988). Atrial fibrillation during eye enucleation in a horse. *Vlaams Diergeneeskundig Tijdschrift* 57, 207-212.
- Gaynor J.S., Bednarski R.M., Muir W.W. (1993). Effect of hypercapnia on the arrhythmogenic dose of epinephrine in horses anaesthetised with guaifenesin, thiamylal sodium and halothane. *American Journal of Veterinary Research* 54, 315-321.
- Holmes J.R., Darke P.G.G., Else R.W. (1969). Atrial fibrillation in the horse. *Equine Veterinary Journal* 1, 211-222.
- Hubbell J.A.E., Muir W.W., Bednarski R.M. (1986). Atrial fibrillation associated with anesthesia in a Standardbred gelding. *Veterinary Surgery* 15, 450-452.
- Keen P. (1990). The use of drugs in the treatment of cardiac disease in the horse. *Equine Veterinary Education* 2, 81-82.
- Manohar M., Smetzer D.L. (1992). Atrial fibrillation, key facts. *Compendium on Continuing Education for the Practicing Veterinarian* 14, 1327-1333.
- Marr C.M., Reef V.B., Reimer J.M., Sweeney R.W., Reid S.W.J. (1995). An echocardiographic study of atrial fibrillation in horses: before and after conversion to sinus rhythm. *Journal of Veterinary Internal Medicine* 9, 336-340.
- Marr C.M.; Robertson S.A., Caron J.P., Brown C.M., Johnston G.M., Johnson C.B., Taylor P.M., Schumacher J. (1994). Expert Opinion Case Series: is it appropriate to perform an ovariectomy for treatment of granulosa cell tumour in an aged Thoroughbred mare with atrial fibrillation? *Equine Veterinary Education* 6, 293-300.
- Miller P.J., Holmes J.R. (1983). Effect of cardiac arrhythmia on left ventricular and aortic blood pressure parameters in the horse. *Research in Veterinary Science* 35, 190-199.
- Miller P.J., Holmes J.R. (1984). Relationships of left side systolic time intervals to beat-by-beat heart rate and blood pressure variables in some cardiac arrhythmias of the horse. *Research in Veterinary Science* 37, 18-25.
- Morris D.D., Fregin G.F. (1982). Atrial fibrillation in horses: factors associated with response to quinidine sulphate in 77 clinical cases. *The Cornell Veterinarian* 72, 339-349.
- Muir W.W., McGuirk S.M. (1984). Hemodynamics before and after conversion of atrial fibrillation to normal si-

- nus rhythm in horses. *Journal of the American Veterinary Medical Association* 184, 965-970.
- Nishikawa K., Yabe M., Mori T., Terai T., Yukioka H., Fujio-moro M. (1996). The effects of dobutamine and phenylephrine on atrioventricular conduction during combined use of halothane and thoracic epidural lidocaine. *Anesthesia and Analgesia* 82, 551-557.
- Reef V.B., Levitan C.W., Spencer P.A. (1988). Factors affecting prognosis and conversion in equine atrial fibrillation. *Journal of Veterinary Internal Medicine* 2, 1-6.
- Sgorbini M., Panzani D., Maccheroni M., Corazza M. (2004). Equine Cushing-like Syndrome: diagnosis and therapy in two cases. *Veterinary Research Communications* 28, 377-380.
- Staudacher V.G. (1989). Individuelle Glykosidtherapie mittels Serumkonzentrationbestimmung bei der Herzinsuffizienz des Pferdes. *Berliner und Münchener Tierärztliche Wochenschrift* 102, 1-3.
- Sweeney RW, Reef VB, Reimer JM. (1993). Pharmacokinetics of digoxin administered to horses with congestive heart failure. *American Journal of Veterinary Research* 54, 1108-1111.
- Taylor P.M., Clarke K.W. (1999). Anaesthetic problems. In: Taylor P.M. and Clarke K.W. (editors). *Handbook of Equine Anaesthesia*, W.B. Saunders Company, Philadelphia, London, p. 105.
- Tisdale J.E., Patel R., Webb C.R., Borzak S., Zarowitz B.J. (1995). Electrophysiologic and proarrhythmic effects of intravenous inotropic agents. *Progress in cardiovascular diseases* 38, 167-180.
- Valverde A., Doherty T.J., Hernandez J., Davies W. (2004). Effect of lidocaine on the minimum alveolar concentration of isoflurane in dogs. *Veterinary Anaesthesia and Analgesia* 31, 264-271.
- van Loon G., Duytschaever M., Tavernier R., Fonteyne W., Jordaens L., Deprez P. (2002). An equine model of chronic atrial fibrillation: methodology. *The Veterinary Journal* 164, 142-150.
- van Loon G., Laevens H., Deprez P. (2001). Temporary transvenous atrial pacing in horses: threshold determination. *Equine Veterinary Journal* 33, 290-295.
- van Loon G., De Clercq D., Tavernier R., Amory H., Deprez P. (2005). Transient complete atrioventricular block following transvenous electrical cardioversion of atrial fibrillation in a horse. *The Veterinary Journal* 170, 124-127.
- Wichmann J., Ertl G., Höhne W., Schweisfurth H., Wernze H., Kochsiek K. (1983). Alpha-receptor restriction of coronary blood flow during atrial fibrillation. *American Journal of Cardiology* 52, 887-892.

Uit het verleden

Hommage aan Marten Toonder 1912 – 2005

Geestelijke vader van Tom Poes, Heer Bommel en zegswijzen, zoals *kommer en kwel, als je begrijpt wat ik bedoel, geld speelt geen rol* en nog zoveel meer.

DE DUIF

Een duif ontkomen aan des valken grof geweld,
De wiek besmeurd, het oog gekweld,
Stort op mijn bottines neder.
Haar bloed bevlekt het leder
Maar mijn hart blijft teder
Als ik haar zachtkens, doch met zwier
Terzijde schuif om voort te schrijden.

Mijn hart bloedt voor 't aanvallig dier,
Maar op querelleren ben ik niet gesteld
En vlegelend nadert de valkenier.
Ik wil een indecent dispuut vermijden.

Ach, hoe haat ik plat geweld!

Uit: Toonder's "*De verzamelde poëmen van Querulijn Xaverius Markies de Canteclaer van Barneveldt*", Amsterdam, De Bezige Bij, 1997, p. 35.

