

REPAIR OF A LOWER EYELID COLOBOMA-DERMOID WITH A MODIFIED SLIDING SKIN GRAFT TECHNIQUE IN A DOG

Herstel van een colobomadermoid van het onderste ooglid met behulp van een aangepaste glijdende huidflap

S. Bossuyt

People's Dispensary for Sick Animals Petaid Hospital Aston,
49 Grosvenor Road, Aston, Birmingham B6 7LY, United Kingdom
StevBossuyt@aol.com

ABSTRACT

A 5-month-old entire female Staffordshire Bull Terrier was presented with an unusual lower eyelid-defect of the right eye. There was an abnormal thickening and inversion of the lateral aspect of the right lower eyelid. The affected area incorporated the conjunctiva and was covered with abnormally long hairs. The lateral half of the right lower eyelid margin was absent. There was an associated conjunctivitis and keratitis in the right eye. A diagnosis of a coloboma in association with a dermoid of the lower eyelid was made. The defect was repaired with the use of a modified sliding skin graft with an excellent result.

SAMENVATTING

Een vrouwelijke Staffordshire Bull Terrier van vijf maanden werd aangeboden met een ongewoon defect van het onderste rechterooglid. Het lateraal aspect vertoonde een abnormale verdikking en inversie. De conjunctiva maakte deel uit van het defect en vertoonde abnormaal lange ooglidharen. De laterale rand van het onderste rechterooglid kon niet geïdentificeerd worden. Er waren tevens een conjunctivitis en keratitis van het rechteroog aanwezig. De diagnose van een coloboma in associatie met een dermoid van het onderste ooglid werd gesteld. Het defect werd hersteld met behulp van een aangepaste glijdende huidflap met een uitstekend resultaat.

INTRODUCTION

An eyelid coloboma is a congenital defect of the lid. This defect can be partial or full thickness. Eyelid colobomata are uncommon in the dog. In this case the coloboma was associated with a dermoid. A dermoid or choristoma is a congenital focal or circumscribed overgrowth of microscopically normal tissue in an abnormal location. Reviewing the literature similar cases have been encountered in the Staffordshire Bull Terrier, the Pyrenean Mountain dog, the Golden retriever, the St. Bernard and the German Shepherd dog (Peiffer, 1989; Bedford 1999; Barnett *et al.* 2002, Peterson-Jones 2002). This report describes the successful management of a lower eyelid colobomadermoid in a Staffordshire Bull Terrier by means of a modified sliding skin graft.

CASE HISTORY

Clinical presentation

A five-month-old entire female Staffordshire Bull Terrier was presented at the Veterinary Centre with an abnormality of the lateral aspect of both lower eyelids. The abnormalities had been present since birth (Figure 1).

Clinical Examination and diagnosis

No obvious abnormalities, other than the ocular problems, were detected on general physical examination. Examination in normal illumination without magnification revealed blepharospasm and generalised conjunctival hyperaemia in both eyes. In the right eye there was an abnormal thickening and inrolling of the lateral half of the lower eyelid which was covered

with abnormally long hairs. The lower eyelid margin was absent from halfway the eyelid to the lateral canthus. Another area of thickened skin with more prominent hairs was visible on the medial aspect of the right lower eyelid about 1 cm below the eyelid margin (Figure 2). The left lower eyelid (lateral aspect) was slightly inrolling and there was a focal area of thickened skin with more prominent hairs about 2 mm below the eyelid margin (Figure 3).

Menace responses and palpebral reflexes were normal in both eyes. Shirmer-tear tests were performed. Tear-production was above 15 mm in both eyes after 1 minute. There was no obvious change in the position of the eyelids after application of topical anaesthesia (proxymethacaine) to both eyes. Examination in a darkened room with focal illumination and slit-lamp biomicroscopy was subsequently performed. Pupillary light reflexes were normal in both eyes. There was generalised hyperaemia of both conjunctivae. Keratitis presenting as superficial neovascularisation and some corneal oedema was present peri-limbal around a 6 to 8 o'clock area in the right eye. The palpebral conjunctiva of the affected lateral aspect of the right lower eyelid consisted of dermoid tissue including hairs. In the left eye a much lesser degree of keratitis was present around 5 to 6 o'clock peri-limbal. Persistent pupillary membranes were detected in both eyes. These fine remnants were present circumferentially spread over the iris-colarette area. In the left eye some of the persistent pupillary membranes were attached to the posterior cornea resulting in a corneal opacity located paracentrally in a 8 to 10 o'clock area (Figure 3). Completing a full ophthalmological examination no further abnormalities were detected.

A diagnosis was made of a lower eyelid coloboma associated with a dermoid of the lateral aspect of the right lower eyelid with secondary conjunctivitis and keratitis. A mild lateral lower eyelid entropion was also present in the left eye. Both lower eyelids also presented with a localised thickening of the eyelid below the eyelid margin. The clinical features of these lesions resembled these of a dermoid.

TREATMENT AND SURGERY

The animal was admitted for surgery. The dog was premedicated with acepromazine (ACP injection 2 mg/ml, Novartis Animal Health Ltd., 0.03mg/kg BW s.c.) and carprofen (Rimadyl, Pfizer, 4mg/kg BW s.c.). Induction of general anaesthesia was obtained with thiopentone (Thiopentone sodium, Merial, 10

mg/kg BW i.v.). After intubation general anaesthesia was maintained using halothane (Halothane, Merial) carried in an oxygen/nitrous oxide (1/3 oxygen and 2/3 nitrous oxide) mixture delivered at a flow rate of 150 ml/kg/min and administered via a parallel Lack circuit.

A modified sliding skin graft procedure was performed to correct the lateral aspect of the right lower eyelid. Firstly, the abnormal tissue was removed. A triangular shape, incorporating the lesion (which consisted of eyelid skin and abnormal palpebral conjunctiva) was excised with the use of a No.10 Bard-Parker scalpel blade assisted with tenotomy scissors. Thereafter a 6 to 7 cm long curvilinear incision was made starting from the lateral canthus curving in a dorso-lateral direction. A triangle of skin of similar shape was then excised on the dorsal side based laterally on the incision (Figure 4B). The subcutaneous layers of the lateral canthal region in the areas ventral and lateral to the incisions were loosened with tenotomy scissors to enable the skin graft to slide in position. The excised triangular areas were closed by sliding the skin medially. Hereby a new lateral part of the lower eyelid was created (Figure 4B, 4C). In the areas lateral to the lateral canthus the subcutaneous layers and the skin were sutured with 4/0 simple interrupted polyglactin 910 sutures. Thereafter, conjunctival mucosa from adjacent palpebral conjunctiva was loosened with tenotomy scissors to line the posterior aspect of the new eyelid. This conjunctiva was sutured to the posterior side of the new eyelid using 8/0 simple interrupted polyglactin 910 sutures. The sutures did not pass entirely through the conjunctival mucosa, to avoid interference with the corneal surface. The most medial side of the skin graft was sutured to the normal medial part of the right lower eyelid with 6/0 simple interrupted polyglactin 910 sutures. Thereafter, a 3 mm wide strip of skin including the hair follicles was removed from the newly formed lateral eyelid margin to form a hair-free lateral eyelid margin (Figure 4D and 5). This area was left to heal per secundam. To correct the left lower eyelid entropion a Hotz-Celsus procedure (modified for the lateral part of the lower eyelid) was performed using 6/0 simple interrupted polyglactin 910 sutures. The two remaining areas resembling a dermoid were clinically not significant. Surgery would have been purely cosmetic and cosmetic surgery without clinical need is currently not offered at the Hospital.

Post-operatively carprofen (Rimadyl, Pfizer, 2mg/kg BW p.o. twice daily) and amoxicillin (Duphamox



Figure 1. A five-month-old Staffordshire Bull Terrier with abnormal lower eyelids.

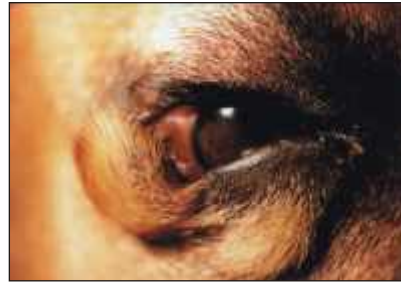

Figure 2. Close-up of the right eye: Combined coloboma-dermoid of the lateral aspect of the lower eyelid and another dermoid medially.

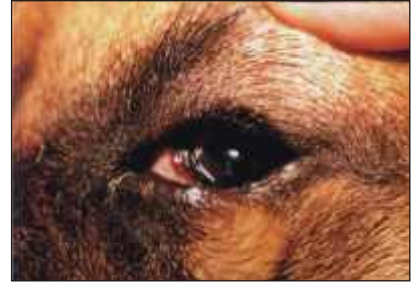

Figure 3. Close-up of the left eye: lower eyelid entropion, dermoid and paracentral corneal opacity (attachment of persistent pupillary membranes to the posterior aspect of the cornea).

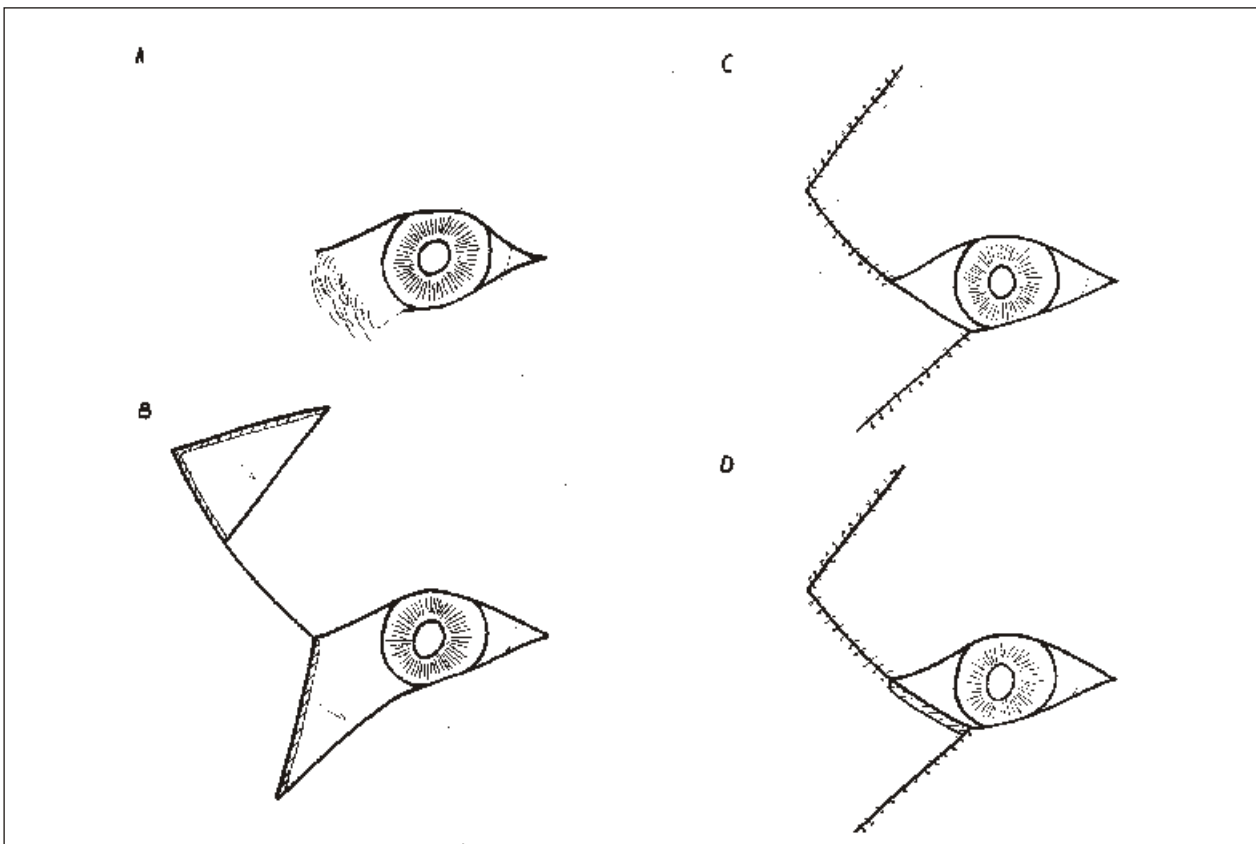


Figure 4. Illustration of a modified sliding skin graft technique for the repair of the lower eyelid defect after resection of the combined coloboma-dermoid.

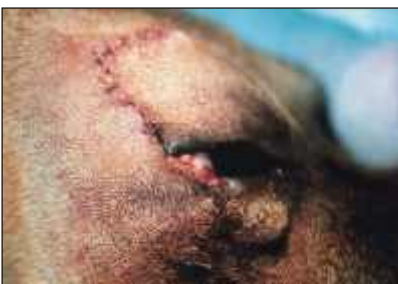

Figure 5. Right lower eyelid immediately after surgery.

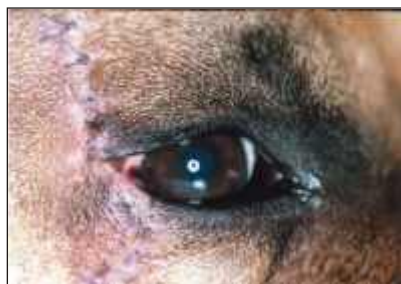

Figure 6. Right lower eyelid 10 days after surgery.

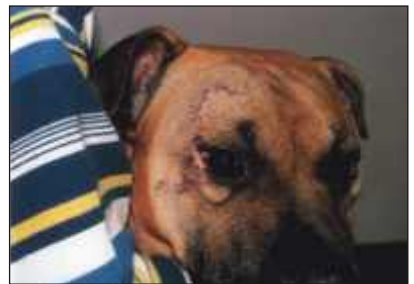

Figure 7. Both eyelids 10 days after surgery.

200 mg, Fort Dodge, 15mg/kg BW p.o. twice daily) were given for one week.

Chloramphenicol eye drops (Chloramphenicol, Cusi (UK) Ltd., 1 drop 8 times daily) were given for ten days.

FOLLOW-UP

The animal was reviewed after 3 days. Conformation of both the right and left lower eyelid was satisfactory. A degree of conjunctival hyperaemia was still present in the right eye. Superficial neovascularisation of the right cornea had regressed. Ten days after surgery a nicely outlined and smooth new eyelid margin was present (Figure 6 and 7). Conjunctival hyperaemia was minimal in the right eye and absent in the left eye. The left eyelid had a normal position. No further medication was given. The polyglactin sutures were left to resorb. However, protruding suture-material was trimmed as possible. One month later both eyes were fine. With the only exception of lack of pigmentation of the right lateral lower eyelid no abnormalities were detected. More than a year later no further problems have been reported.

DISCUSSION

A coloboma of the eyelid is a congenital defect of the eyelid. In the dog it is usually the lower eyelid towards the lateral canthus, which is affected. Eyelid coloboma's are uncommon in the dog. They can be unilateral or bilateral and be partial or full thickness. In the cat they are more common, tend to be bilateral and involve mainly the lateral part of the upper eyelids (Bedford, 1999; Slatter, 2001; Barnett, 2002). In this case the coloboma was associated with a dermoid. A dermoid or choristoma is a congenital focal or circumscribed overgrowth of microscopically normal tissue in an abnormal place caused by displacement of embryonic tissue. Eyelid dermoids contain all the elements of normal skin and the hair they bear is characteristically long (Bedford, 1999; Slatter, 2001; Barnett 2002; Peterson-Jones 2002).

The presence of an eyelid coloboma and/or dermoid should alert the practitioner other congenital ocular abnormalities could be present (Bedford 1999). In this case dermoids were present in other places on both lower eyelids. Also persistent pupillary membranes were present in both eyes leading to a posterior corneal opacity in the left eye.

In cases in which an eyelid coloboma is associated with a dermoid the lesion is usually more extensive. Corneal and conjunctival irritation, lacrimation, secondary keratitis and impaired blink mechanism is seen. Therefore, these lesions need surgical correction. Several techniques have been described in the literature how to deal with such eyelid defects (Gelatt *et al.* 1969; Carter 1973; Gwin 1980; Munger *et al.* 1981; Pavletic *et al.* 1982; Esson 2001; Wolfer 2002; Lewin 2003).

Smaller lesions of less than one third of the eyelid can be corrected by a simple wedge resection (Featherstone, 2003). Larger lesions need more extensive surgery.

Which technique to use for larger lesions is open to discussion. The goal of the surgery is fourfold, removal of the lesion in its totality, restoring or creating a functional eyelid, cosmesis and absence of pain and irritation (Gwin 1980). Restoration or creation of a functional eyelid is especially important for the upper eyelid, which is the more mobile.

The cross lid flap or Mustardé technique is a superior technique for the repair of large upper eyelid defects (Munger *et al.* 1981; Esson 2001). A normal smooth eyelid margin is created in this way. The only real disadvantage of this technique is the need for more than one general anaesthetic. With other techniques such as H-blepharoplasty, Z-blepharoplasty, sliding skin grafts and split eyelid flaps there is the possibility of creating trichiasis, especially for the upper eyelid. Also the eyelid can lack strength and contracture or scarring can develop with these techniques (Gelatt *et al.* 1969; Carter 1973; Gwin 1980; Lewin 2003). Careful harvesting of conjunctival lining and preventing excessive tension on the conjunctiva as well as on the skin can prevent the latter (Bedford 1999). The advantage with these techniques rests with a single general anaesthetic.

For the lower eyelid a superior technique is the mucocutaneous subdermal plexus flap from the lip (Pavletic, 1982). With this technique a hairless smooth eyelid margin is created. The technique is more complicated and in some cases a cosmetic revision procedure is required. H-blepharoplasty, Z-blepharoplasty, sliding skin grafts and split eyelid flaps can also be used for the lower eyelid with the same possible complications as above (Gelatt *et al.* 1969; Carter 1973; Gwin 1980; Lewin 2003). However, for the lower eyelid, being the less mobile, the problems of creating trichiasis and secondary keratitis are less common.

In this case a sliding skin graft technique as described was used with a modification, the removal of a small strip of skin at the eyelid margin, which was left to heal per secundam. This aspect of the technique was partially employed by Stades for the treatment of upper eyelid entropion and trichiasis in the English Cocker Spaniel (Stades, 1991; Stades, 1993; Wolfer, 2002). Using this modification trichiasis was prevented and a smooth eyelid margin was created. Only one general anaesthetic was required and there was a good surgical outcome. No contracture was evident. The Staffordshire Bull Terrier as a breed has a rather taut skin. This technique could be less advantageous in breeds with more supple eyelids such as for instance the Yorkshire Terrier.

Concluding, a modified sliding skin graft technique for the repair of a large lateral lower eyelid defect after resection of a coloboma-dermoid is described with a good surgical outcome. Advantages of this technique are use of a single general anaesthetic, the technical ease of the procedure and its applicability in general practice.

REFERENCES

- Barnett, K.C., Sansom, J., Heinrich, C. (2002). Upper and lower eyelids, congenital anomalies. In: Barnett K.C., Sansom J. and Heinrich C. (editors). *Canine Ophthalmology*, London, W.B. Saunders, 49-50.
- Bedford, P.G.C. (1999). Diseases and surgery of the canine eyelid. In: Gelatt K.N. (editor). *Veterinary Ophthalmology*, 3rd edition, Philadelphia, Lippencott Williams & Wilkins, 535-568.
- Carter, J.D. (1973). Surgery of congenital eyelid defects. *Veterinary Clinics of North America* 3(3), 423-432.
- Esson, D. (2001). A modification of the Mustardé technique for the surgical repair of a large feline eyelid coloboma. *Veterinary Ophthalmology* 4, 159-160.
- Featherstone, H. (2003). Self assessment, dermoid. *UK Vet* 8(7), 85-87.
- Gelatt, K.N., Blogg, J.R. (1969). Blepharoplastic procedures in small animals. *Journal of The American Animal Hospital association* 5, 67-78.
- Gwin, R.M. (1980). Selected blepharoplastic procedures of the canine eyelid. *Compendium on Continuing Education for the Practicing Veterinarian* 11, 267-272.
- Lewin, G. (2003). Eyelid reconstruction in seven dogs using a split eyelid flap. *Journal of small Animal Practice* 44, 346-531.
- Munger, R.J., Gourley, I.M. (1981). Cross lid flap for repair of large upper eyelid defects. *Journal of The American Veterinary Medical Association* 178(1), 45-48.
- Pavletic, M.M., Nafe, L.A., Confer, A.W. (1982). Mucocutaneous subdermal plexus flap from the lip for lower eyelid restoration in the dog. *Journal of The American Veterinary Medical Association* 180, 921-926.
- Peterson-Jones, S. (2002). Congenital conditions of the eyelids in dogs. In: Petersen-Jones S and Crispin S. (editors). *BSAVA Manual of Small Animal Ophthalmology*, 2nd edition, Gloucester, BSAVA, 80-82.
- Slatter, D. (2001). Eyelids, congenital abnormalities. In: Slatter D. (editor). *Fundamentals of Veterinary Ophthalmology*, 3rd edition, Philadelphia, W.B. Saunders Company, 152-153.
- Slatter, D. (2001). Congenital abnormalities, dermoid. In: Slatter D. (editor). *Fundamentals of Veterinary Ophthalmology*, 3rd edition, Philadelphia, W.B. Saunders Company, 208.
- Stades, F.C., Van de Sandt, R.R., Boeve M.H. (1993). Clinical aspects and surgical procedures in trichiasis. *Tijdschrift voor Diergeneeskunde* 118, 38S-39S.
- Stades, F.C. (1991). Hereditary eye disease, diagnosis, therapy and prevention. *Tijdschrift voor Diergeneeskunde* 116, 889-897.
- Wolfer, J.C. (2002). Correction of eyelid coloboma in four cats using subdermal collagen and a modified Stades technique. *Veterinary Ophthalmology* 5, 269-272.