

EMPHYSEMATOUS CYSTITIS WITHOUT GLUCOSURIA IN A CALF

Emfysemateuze blaasontsteking zonder glucosurie bij een kalf

O. Ozmen, M. Haligur

Department of Pathology, Faculty of Veterinary Medicine, University of Akdeniz, 15100, Burdur, Turkey

oozmen@akdeniz.edu.tr

ABSTRACT

A two-month-old male non-diabetic Holstein Friesian calf with numerous decubital ulcers due to arthrogryposis and a history of inability to stand since birth was diagnosed with emphysematous cystitis. The diagnosis was based on the necropsy and the histopathological findings. No glucosuria was detected and *Escherichia coli* was isolated from the urine and blood. The contamination of the skin ulcers with *E. coli* and septicemia was probably the main underlying mechanism involved in the pathogenesis. The urinary bladder mucosa was affected with blebs of emphysema and petechiae. Histopathologically, hemorrhage, emphysema and a few neutrophil leukocyte infiltrations were observed in the mucosa of the urinary bladder. Although emphysematous cystitis is commonly associated with glucosuria, especially in dogs, this report indicates that it can equally occur as a complication of septicemia in calves.

SAMENVATTING

Bij een mannelijk, niet-diabetisch Holstein Friesian kalf dat ten gevolge van arthrogryposis niet kon opstaan na de geboorte en daardoor talrijke decubitusletsels kreeg, werd op de leeftijd van twee maanden emfysemateuze cystitis gediagnosticeerd. De diagnose werd op basis van de resultaten van de autopsie en de verdere histopathologische bevindingen gesteld. Er werd geen glucosurie vastgesteld maar *Escherichia coli* werd uit de urine en het bloed geïsoleerd. De vervuiling van de zweren met *E. coli* en de daaruitvolgende septikemie waren vermoedelijk betrokken bij de pathogenese. Op de mucosa van de urineblaas werden emfysemateuze blazen en petechieën aangetroffen. Histopathologisch werden bloedingen, emfyseem en plaatselijke leukocyteninfiltraties in de mucosa van de urineblaas opgemerkt. Hoewel emfysemateuze cystitis gewoonlijk met glucosurie gepaard gaat (voornamelijk bij de hond), werd in deze casuïstiek aangetoond dat de ontsteking ook kan optreden als een complicatie van septikemie bij kalveren.

INTRODUCTION

Emphysematous cystitis is a condition that is caused by infection with gas-producing bacteria, which leads to gas-filled vesicles in the wall of the bladder. This happens most frequently in the presence of glucosuria, especially in patients with diabetes mellitus (Jones *et al.*, 1997; Tan, 2000; Hazirolu and Milli, 2001). Emphysematous cystitis occurs rarely in dogs and cats, in which minute spaces in the inflamed and thickened wall of the bladder can be seen (Root and Scott, 1971; Sherding and Chew, 1979; Wuggening *et al.*, 1992; Davies and Williams, 1993; Jones *et al.*, 1997; Cohn *et al.*, 2001). The incidence of emphysematous cystitis in cattle is even lower. There is only one report of emphysematous cystitis in a calf, which was associated with glucose treatment (King, 1995).

In this report we describe a case of emphysematous cystitis, not associated with glucosuria, in a calf.

MATERIALS AND METHODS

A two-month-old male Holstein Friesian calf which had not been able to stand after being born was brought to the Veterinary Medical Teaching Hospital. Arthrogryposis was observed in both hind legs, together with incoordination in the front legs of the calf. Because of the congenital leg abnormality, the calf was lying down continuously. Due to the calf's inability to stand, several decubital ulcers had developed, especially on the legs and the sternum. The ulcers were bleeding when the calf attempted to stand up. Alopecia was seen on the hind legs. Other clinical findings included cachexia and anemia. Because of the poor prog-

nosis, the calf was admitted to the Department of Pathology and put down.

During the necropsy, tissue samples were taken from all organs. The samples were fixed in 10% buffered formalin and processed routinely for light microscopy. Five-micron-thick sections were taken from paraffin embedded tissues and stained with Hematoxylin-Eosin (HE) and with the modified Brown and Brenn method for the assessment of bacteria (Luna, 1968). A urine sample was taken from the urinary bladder under aseptic conditions for laboratory examination. Samples also were taken for microbiological isolation.

RESULTS

At necropsy, fibrinopurulent pleuritis and pericarditis were seen associated with perforated ulcers on the sternum. Pneumonia was seen in the ventral parts of the lungs, associated with pleuritis and bacterial contamination of the thorax due to perforated decubital ulcers. In addition to these findings, adhesions were observed between lungs and sternum. Osteomyelitis was observed in some sternal bones and severe purulent myositis was seen in muscles near the ulcers.

The urinary bladder was filled with urine and a little gas, and the mucosa of the bladder showed numerous white foci (Figure 1). After removal of the urine for analysis, the bladder was examined macroscopically. Diffusely distributed white areas were seen on the bladder mucosa. Emphysema and petechiae were visible at the mucosal surface. The wall of the bladder was thickened by emphysema and crepitation was found when the wall of the bladder was palpated.

Histopathologically severe fibrinopurulent pleuritis and pericarditis were also seen. Purulent pneumonia was observed in the lungs, especially near the pleura. Slight neutrophil leukocyte infiltrations were present in liver and kidneys. In addition to these findings, acute catarrhal enteritis was observed. There were no lesions observed in the pancreas consistent with diabetes mellitus.

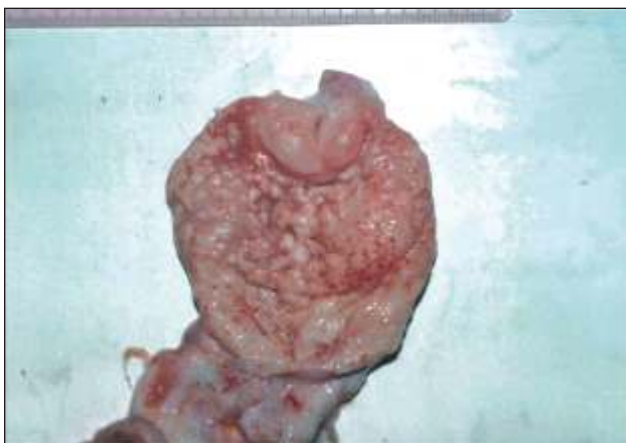

Figure 1. Gross appearance of the urinary bladder with emphysematous cystitis.

Histopathological examination of the urinary bladder mucosa revealed that there were many emphysematous spaces under the lamina epithelialis (Figure 2). Hyperemia, hemorrhage, and slight neutrophil leukocyte infiltrations were observed on the submucosa of the bladder. There was no inflammatory reaction on the tunica muscularis and serosa.

Laboratory examination of the urine revealed that it had a light yellow color, a specific gravity of 1.018, and a pH of 6.52. Glucosuria was not detected. Microhematuria was seen after centrifugation of the urine sample for 5 minutes at 2500 rpm. Microscopic examination of the urine showed the presence of numerous leukocytes and bacteria. Microbiological culture of urine resulted in the growth of *E. coli*. Hematologic tests revealed leukocytosis and microcytic microchromic anemia. *E. coli* was also isolated from the blood and septicemia was diagnosed.

DISCUSSION

Emphysematous cystitis is a rare form of infectious cystitis characterized by the presence of gas in the bladder wall. Emphysematous cystitis is nearly always associated with diabetes mellitus, because gas in the bladder wall is the result of fermentation of urinary glucose to carbon dioxide, typically by *E. coli* species. Occasionally, emphysematous cystitis is seen in cases of long-standing outlet obstruction, neurogenic bladder, or bladder diverticulum. Clinically, emphysematous cystitis results in dysuria, hematuria, and pneumaturia (Doige and Weisbrode, 1993; Jones *et al.*, 1997; Martiarena *et al.*, 1999; Tan, 2000; Haziroglu and Milli, 2001). At cystoscopy, the bladder mucosa is red and edematous, containing multiple gas-filled blebs that rupture easily (Root and Scott, 1971; Sherding and Chew, 1979; Wuggening *et al.*, 1992; Cohn *et al.*, 2001). In humans, the symptoms vary widely, ranging from no symptoms or mild symptoms of typical cystitis to severe abdominal pain and sepsis. A history of pneumaturia is rare, but should raise suspicion of emphysematous cystitis as part of the differential diagnosis (Benson *et*

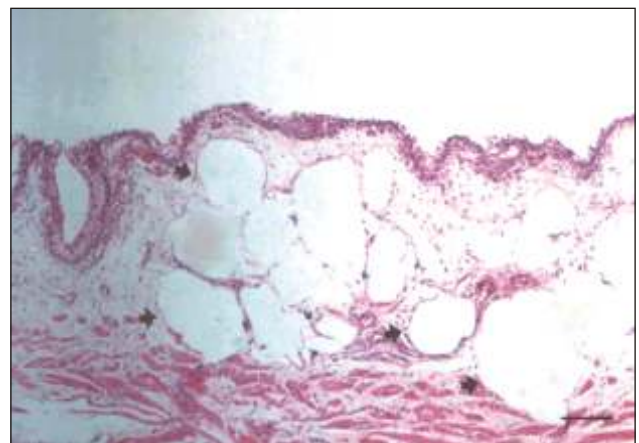


Figure 2. Microscopical appearance of the emphysema in the bladder wall (arrows), HE Bar, 50 μ .

al., 1986; Quint *et al.*, 1992; Katz *et al.*, 1993). Although microhematuria was observed in this case, no urinary bladder abnormality and dysuria or pneumaturia were diagnosed. There were no other agents isolated from the urine that can cause emphysema.

Emphysematous cystitis is most commonly seen in association with urinary tract infections in diabetic patients. This disease develops as the result of infection of the urinary bladder with gas-producing bacteria. Most cases, including this one, result from *E. coli* (Davies and Williams, 1993; Jones *et al.*, 1997; Martiarena *et al.*, 1999; Cohn *et al.*, 2001; Hazirolu and Milli, 2001). In humans, as well, most cases are caused by gram-negative organisms like *E. coli* (Hill, 1989). In the present study, a primary urinary tract infection was not diagnosed. Septicemia was probably the main underlying mechanism involved in the pathogenesis.

Glucosuria is the most common cause of emphysematous cystitis, a condition which is usually seen in dogs, cats and humans (Root and Scott, 1971; Doige and Weisbrode, 1993; Jones *et al.*, 1997; Martiarena *et al.*, 1999; Hazirolu and Milli, 2001). Although emphysematous cystitis typically develops as a result of infection with glucose-fermenting bacteria in humans and in other animals with diabetes mellitus, it can develop in nondiabetic animals as well (Sherding and Chew, 1979; Wuggening *et al.*, 1992; Davies and Williams, 1993; Doige and Weisbrode, 1993; Jones *et al.*, 1997; Tan, 2000; Hazirolu and Milli, 2001). King (1995) reported a case of urinary bladder emphysema in a calf after 50% glucose treatment. In our report, glucosuria was not observed and no glucose treatment was used. In septic cases without signs of emphysematous cystitis, this condition should be taken into consideration.

The characteristic feature in the pathology is the presence of large empty spaces, or "gas pockets", confined to the area of inflammation. Initially, these spaces are gas-filled tears that compress surrounding tissues (Hill, 1989). The mechanism of gas formation is believed to involve the fermentation of glucose or albumin to carbon dioxide by gas-producing organisms in the bladder (Rocca and McClure, 1985; Quint *et al.*, 1992). Aerobic fermentation of glucose by bacteria produces the gas, although yeast and anaerobic bacteria are also implicated (Katz *et al.*, 1993). Very similar findings were observed in this case.

Arthrogryposis implies persistent congenital flexure or contraction of joints. It is commonly seen in calves. It can cause decubital ulcers and make it difficult or even impossible for the calf to stand (Doige and Weisbrode, 1993; Jones *et al.*, 1997). Septicemia due to contamination of decubital ulcers with *E. coli* was the cause of the emphysematous cystitis in the present report.

Accordingly, this report describes a case of emphysematous cystitis without glucosuria in a 2-month-old male arthrogryptic Holstein calf related to bacterial contami-

nation of decubital ulcers and *E. coli* septicemia. Although emphysematous cystitis is commonly associated with glucosuria, this report indicates that it can occur as a complication of septicemia in calves. Sometimes, emphysematous cystitis can also be seen as a complication of septicemia in canine and human medicine.

REFERENCES

- Benson M., LiPuma J., Resnick M. (1986). The role of imaging studies in urinary tract infection. *Urologic Clinics of North America* 13, 605-625.
- Cohn L.A., Cook C. R., Priddy N., Johannes C. (2001). What is your diagnosis? Emphysematous cystitis pneumaturia and lumbar spondylitis. *Journal of American Veterinary Medical Association* 218 (5), 703-704.
- Davies N.L., Williams J. H. (1993). Emphysematous cystitis in a non-diabetic cat. *Journal of the South African Veterinary Association* 64, 162-164.
- Doige C. E., Weisbrode, S. E. (1995). Disease of Bone and Joints. In: Carlton W. W., McGavin M. D. (Editors). *Thomson's Special Pathology*, Mosby Publishing, Missouri, pp. 452.
- Hazirolu R., Milli U. H., (2001). Urinary System. In: *Veterinary Pathology*, Medipres, Ankara, Turkey, pp. 208.
- Hill G.S., (1989). Renal infection. In: *Urology*. Churchill Livingstone, London, pp. 349-351.
- Jones T. C., Hunt R. D., King N. W. (1997). Urinary System. In: *Veterinary Pathology*. 6th ed. Williams & Wilkins, Philadelphia, USA, pp. 1145.
- Katz D.S., Aksoy E., Cunha B.A. (1993). *Clostridium perfringens* emphysematous cystitis. *Urology* 41, 458-460.
- King J. M. (1995). Frostbite and urinary bladder emphysema in a calf. *Veterinary Medicine* 90, 1132.
- Luna L.G. (1968). *Manual of Histologic Staining methods of the Armed Forces Institute of Pathology*, 3rd ed. McGraw-Hill Book Company, New York, pp.222.
- Martiarena B., Maucebin E., Mas J., Navarro D., Zanzottera E., (1999). Emphysematous cystitis (due to *Clostridium perfringens* and *Escherichia coli*) and pneumaturia (in a dog): notes from a case study and literature review. *Selecciones Veterinarias* 7, 453-456.
- Quint H., Drach G, Rappaport W., Hoffman C.L. (1992). Emphysematous cystitis: A review of the Spectrum of Disease. *Journal of Urology* 147, 134-137.
- Rocca J.M., McClure J. (1985). Cystitis emphysematosa. *British Journal of Urology* 57, 585-586.
- Root C.R., Scott R.C. (1971). Emphysematous cystitis and other radiographic manifestations of diabetes mellitus in dogs and cats. *Journal of the American Veterinary Medical Association* 158, 721-728.
- Sherding R.G., Chew, D. J. (1979). Nondiabetic emphysematous cystitis in two dogs. *Journal of the American Veterinary Medical Association* 174, 1105-1109.
- Tan J. S. (2000). Infectious complications in patients with diabetes mellitus. *International Diabetes Monitoring* 12, 1-7.
- Wuggenig Von K., Koppel E. (1992). Cystitis emphysematosa bei einer Cockerspaniel-Hündin. *Wiener Tierärztliche Monatsschrift* 79, 38-40.