

EQUINE COITAL EXANTHEMA IN A MARE IN BELGIUM

Equien coïtaal exantheema bij een merrie in België

K. van der Meulen¹, A. Caij², K. Smets³, H. Nauwynck¹

¹Laboratory of Virology, Faculty of Veterinary Medicine, Ghent University,
Salisburylaan 133, B-9820 Merelbeke, Belgium

²Veterinary and Agrochemical Research Centre, Groeselenberg 99, 1180 Brussels, Belgium

³Alpharma Animal Health, Regulatory Affairs, Uitbreidingstraat 86, 2600 Antwerp, Belgium

karen.vandermeulen@Ugent.be

ABSTRACT

This case report describes a clinical case of equine coital exanthema in a mare in Belgium. Several days following coitus, the mare showed typical lesions of coital exanthema consisting of papules, pustules and ulcers on the vaginal and vestibular region. The lesions healed within three weeks. The infection had no effect on fertility and gestation. The mare carried to term and delivered a healthy foal. Equine herpesvirus 3 was isolated from the lesions by means of virus isolation on an equine cell culture and subsequently identified by means of a PCR.

SAMENVATTING

In deze casuïstiek wordt een klinisch geval van equien coïtaal exantheema beschreven bij een merrie in België. Enkele dagen na de dekking vertoonde de merrie typische letsels van coïtaal exantheema, zoals papels, puisten en ulcera op de vaginale en vestibulaire mucosa. Drie weken na hun ontstaan waren de letsels genezen. De infectie had geen invloed op de vruchtbaarheid en de dracht. De merrie bracht à terme een gezond veulen ter wereld. Equien herpesvirus 3 werd geïsoleerd uit de letsels aan de hand van een virusisotatie op primaire paardencellen. De identificatie van het virus werd uitgevoerd met behulp van een PCR.

INTRODUCTION

Equine coital exanthema (ECE) is caused by equine herpesvirus (EHV)-3, a member of the family *Herpesviridae*, subfamily *Alphaherpesvirinae* (O'Callaghan *et al.*, 1984; Hartley *et al.*, 1999). EHV-3 has a worldwide distribution. Since the late 1960s, infection has been demonstrated in the United States (Bryans and Allen, 1973; Crandell and Davis, 1985), Canada (Girard *et al.*, 1968), Denmark (Bitsch, 1972), Norway (Krogstad and Onstad, 1971), England (Gibbs *et al.*, 1970), Australia (Pascoe *et al.*, 1969; Feilen *et al.*, 1979), India (Uppal *et al.*, 1989) and, very recently, in Japan (Seki *et al.*, 2004). The seroprevalence increases with age, with a maximum value of about 50% in horses of 8 years and more (Bagust *et al.*, 1972). This clearly indicates that the major mode of transmission of EHV-3 is venereal.

EHV-3 mainly affects vaginal and vestibular mucosa, modified skin of the penis and prepuce, and the skin of the perineal region. Occasionally, the skin of the lips and mucosa of the upper respiratory tract are affected (Wilks

and Studdert, 1976; Crandell and Davis, 1985). The restriction of EHV-3 to mucosal surfaces of the reproductive tract has been related to the temperature sensitivity of the virus (Jacob, 1986; Bouchev *et al.*, 1987; Jacob and Steiner, 1988). Clinical signs of ECE are mild. Lesions initially appear as small, raised and reddened papules that rapidly progress to pustular lesions and, by day 6, to ulcers. A general reddening of the vaginal mucosa may occur. Systemic signs are rare, except when ECE is complicated by a secondary bacterial infection. ECE has no effect on fertility or on pregnancy (Pascoe, 1981). Lesions are usually healed after 14 days, leaving de-pigmented, white spots.

Up till now, no serological evidence or outbreaks of ECE have been reported in Belgium.

CASE HISTORY

A 21 year-old pony mare from France was brought to a small breeding facility in Belgium, where she was housed with two 3 year-old pony mares and a 20 year-old

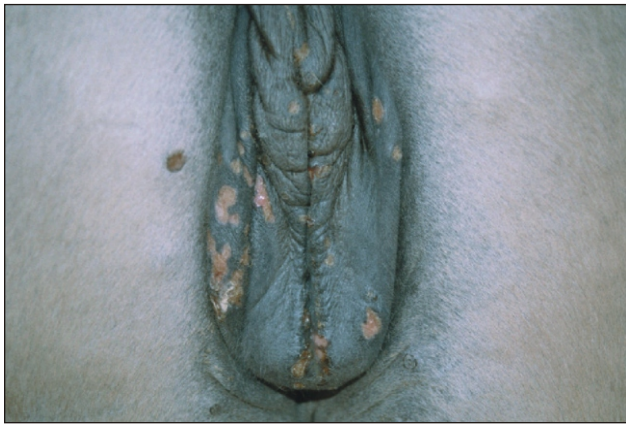

Figure 1. Clinical lesions on the perineum and the vulva of a mare, suspected of an EHV-3 infection.

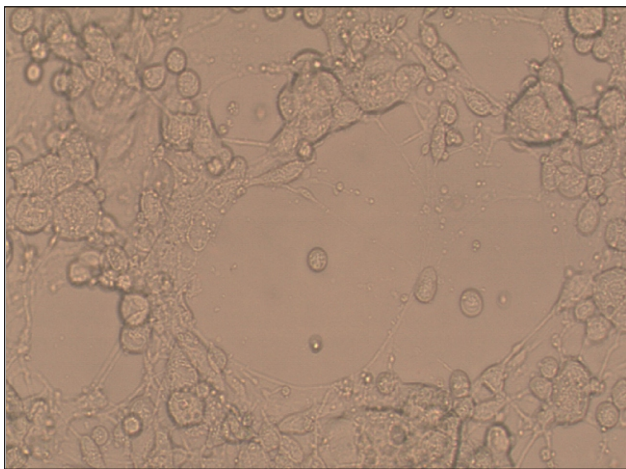
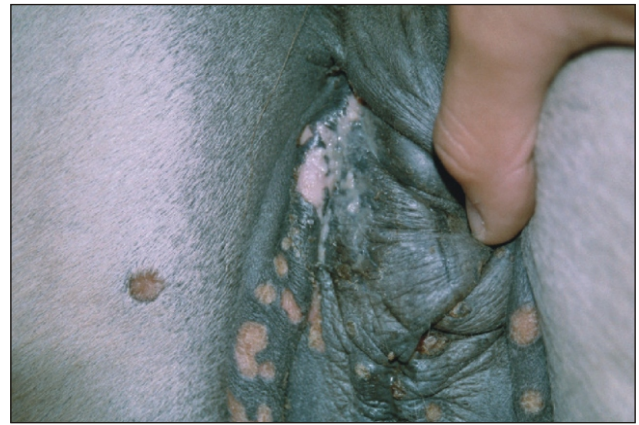


Figure 2. Cytopathic effect at three days post inoculation of equine embryonic kidney cells with sample supernatant of a mare suspected of an EHV-3 infection.

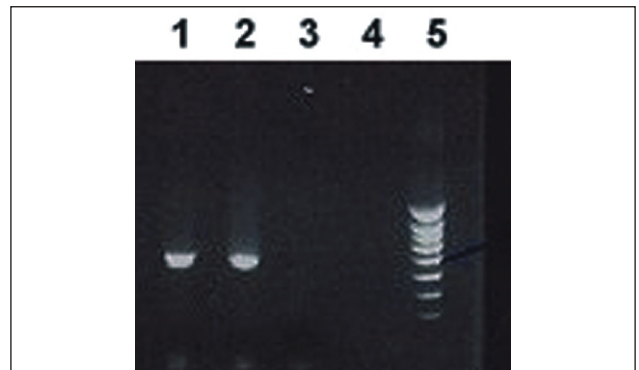


Figure 3. Polymerase chain reaction for the detection of the glycoprotein G of EHV-3 in a strain isolated from the affected mare and in the known EHV-3 strain 334/74 (Lane 1: positive control supernatant containing EHV-3 strain 334/74; lane 2: sample supernatant; lane 3: negative control supernatant of non-inoculated EEK cells; lane 4: H₂O; lane 5: molecular weight standard).

pony stallion. Four days after the mares were covered, the mare from France developed lesions, indicative of an EHV-3 infection. They consisted of papules and pustules on the vaginal and vestibular mucosa as well as on the perineal skin. Lesions soon evolved to a severe, purulent vulvovaginitis. Some of the typical lesions are illustrated in Figure 1. The 3 year-old mares and the stallion developed no clinical signs.

The vagina of the affected mare was flushed twice daily with isobetadine 10%. After three days, the lesions dried out and, within three weeks, evolved to de-pigmented spots. Four weeks after breeding, pregnancy was confirmed and the mare returned to France. She carried to term and delivered a healthy foal. The two 3-year-old mares also gave birth to healthy foals.

LABORATORY EXAMINATIONS

Sampling

Samples were collected by roughly rubbing the lesions with a dry cotton swab. The lesions were not disinfected

before sampling in order to avoid destroying the virus. After sampling, the swab was brought into physiological salt solution and transported to the Laboratory of Virology at 4°C, where the samples were vortexed and subsequently centrifuged to pellet debris. The supernatant fluid was kept at -70 °C until use.

Virus isolation

Primary equine embryonic kidney (EEK) cells and continuous cell lines of equine embryonic lung (EEL) cells and equine dermis (ED) cells were cultured in 24-well plates (Nunc). For primary cells, the culture medium consisted of Hank's Minimal Essential Medium (MEM) supplemented with 100 U/ml penicillin, 0.1 mg/ml streptomycin, 0.1 mg/ml kanamycin, 0.3 mg/ml glutamine, 4.45 mM NaHCO₃, 2.5 mg/ml lactalbumin hydrolysate, 0.1 mg/ml gentamycin, 5 g/ml fungizone and 10% fetal calf serum. For the continuous cell lines, MEM supplemented with 100 U/ml penicillin, 0.1 mg/ml streptomycin, 0.1 mg/ml kanamycin, 0.3 mg/ml glutamine and 5% fetal calf serum was used. When the cells had

grown to confluency, the medium was removed. Then the cells were inoculated with 200 μ l of the sample supernatant and subsequently incubated at 37°C and 5% CO₂ for 1 h. The supernatant was then removed, and the cells were washed twice with medium and cultured with fresh medium at 37°C and 5% CO₂.

Cytopathic effect was observed in EEK cells at three days post inoculation. The cytopathic changes were characterized by rounding of the cells and formation of syncytia (Figure 2). No cytopathic effect was observed in EEL or ED cells.

Polymerase chain reaction

A polymerase chain reaction (PCR) was used for the identification of EHV-3. Viral nucleic acid was extracted from 200 μ l of the sample supernatant as well as from control culture supernatant of primary equine fetal kidney (EFK) cells inoculated with the previously identified EHV-3 strain 334/74 (Gleeson *et al.*, 1976). For extraction, a QIAamp DNA mini kit (Qiagen) was used according to the manufacturer's instruction.

The primers used for the PCR were those described by Dynon *et al.* (2001). These primers are capable of amplifying the partial length glycoprotein G of EHV-3. PCR was performed in a 50 μ l reaction volume using 1X PCR buffer, 1.5 mM MgCl₂, 1 μ M of each primer, 0.2 mM dNTP, 1 U Taq DNA polymerase and 5 μ l of sample. The PCR was carried out for 40 cycles at 95 °C for 30 sec, at 60 °C for 30 sec and at 72 °C for 45 sec. PCR products were separated on an agarose gel and stained with ethidium bromide.

The PCR products obtained from sample and control supernatant were identical and had the expected 520 base pairs in size (Figure 3). On the basis of this result, the isolate of the mare was identified as EHV-3 (isolate 04P57).

DISCUSSION

How the disease was initiated in the mare remains unclear. Even though not formerly demonstrated, it is generally accepted that EHV-3 can induce a latent infection, with spontaneous reactivation in association with various stresses (Studdert, 1996). Therefore, it is possible that a reactivation of latent virus occurred in the mare in association with stress induced by her transport from France to Belgium or by the covering. It is also possible that the stallion was latently infected and had reactivated, with subsequent infection of the mares during coitus. That only the 21 year-old mare developed clinical signs may have been related to her poor general condition (Studdert, 1996). However, since no serological examination was performed of the mares or the stallion, the definite course of the infection cannot be untangled.

As described for previous cases of ECE in other countries (Studdert, 1996), this case in Belgium also occurred as a relatively mild disease with complete healing of lesions within one month. Due to its mild character, the disease has not attracted great demand for control. In the event of an outbreak, the affected horses should not be used for breeding activities until the lesions are completely healed. Local treatment of lesions with mild disinfectant solutions can promote their rapid and uncomplicated healing and may, therefore, be helpful for shortening the required period of suspended mating. For this purpose, topical treatment with antiviral compounds could also be useful. Cullinane and coworkers (1994) were already using a 5% human topical cream formulation of acyclovir in stallions and mares with ECE. However, since no untreated control animals were included in their study, the benefit of the antiviral therapy was difficult to assess. Vaccines against ECE are not available.

REFERENCES

- Bagust T.J., Pascoe R.R., Harden T.J. (1972). Studies on equine herpesviruses 3. The incidence in Queensland of three different equine herpesvirus infections. *Australian Veterinary Journal* 48, 47-53.
- Bitsch V. (1972). Cases of equine coital exanthema in Denmark. *Acta Veterinaria Scandinavica* 13, 281-283.
- Bouchev D., Evermann J., Jacob R. J. (1987). Molecular pathogenesis of equine coital exanthema (ECE): temperature sensitivity (TS) and restriction endonuclease (RE) fragment profiles of several field isolates. *Archives of Virology* 92, 293-299.
- Bryans J.T., Allen G.P. (1973). In vitro and in vivo studies of equine coital exanthema. In: Bryans J.T., Gerber H. (eds.). *Equine infectious diseases III*. S Karger, New York, pp 322-336.
- Crandell R.A., Davis E.R. (1985). Isolation of equine coital exanthema virus (equine herpesvirus 3) from the nostril of a foal. *Journal of the American Veterinary Medical Association* 187, 503-504.
- Cullinane A., McGing B., Naughton C. (1994). The use of acyclovir in the treatment of coital exanthema and ocular disease caused by equine herpesvirus 3. In: Plowright W., Nakajima H. (eds.). *Equine infectious diseases VII*. R&W Publications, Newmarket, p 55.
- Dynon K., Varrasso A., Ficorilli N., Holloway S., Reubel G, Li F., Hartley C., Studdert M., Drummer H. (2001). Identification of equine herpesvirus 3 (equine coital exanthema virus), equine gammaherpesviruses 2 and 5, equine adenoviruses 1 and 2, equine arteritis virus and equine rhinitis A virus by polymerase chain reaction. *Australian Veterinary Journal* 79, 695-702.
- Feilen C.P., Walker S.T., Studdert M.J. (1979). Equine herpesvirus type 3 (equine coital exanthema) in New South Wales. *Australian Veterinary Journal* 55, 443- 444.
- Gibbs E.P., Roberts M.C., Morris J.M. (1972). Equine coital exanthema in the United Kingdom. *Equine Veterinary Journal* 4, 74-80.
- Girard A., Greig A.S., Mitchell D. (1968). A virus associated with vulvitis and balanitis in the horse- preliminary report. *Canadian Journal of Comparative Medicine* 32, 603-604.

- Gleeson L.J., Sullivan N.D., Studdert M.J. (1976). Equine herpesviruses: type 3 as an abortigenic agent. *Australian Veterinary Journal* 52, 349-354.
- Hartley C.A., Drummer H.E., Studdert M.J. (1999). The nucleotide sequence of the glycoprotein G homologue of equine herpesvirus 3 (EHV3) indicates EHV3 is a distinct equid alphaherpesvirus. *Archives of Virology* 144, 2023-2033.
- Jacob R.J. (1986). Molecular pathogenesis of equine coital exanthema: temperature-sensitive function(s) in cells infected with equine herpesviruses. *Veterinary Microbiology* 11, 221-237.
- Jacob R.J., Steiner M.R. (1988). Molecular pathogenesis of equine coital exanthema: identification and expression of infected cell polypeptides at the restricted temperature during equine herpesvirus 3 infection. *Veterinary Microbiology* 18, 363-371.
- Krogstad J., Onstad O. (1971). Equine coital exanthema. Isolation of a virus and transmission experiments. *Acta Veterinaria Scandinavica* 12, 1-14.
- O'Callaghan D.J., Sullivan D.C., Bauman R.P., Caughman G.B., Flowers C.C., Robertson A.T., Staczek J. (1984). Genomes of the equine herpesviruses: molecular structure, regions of homology and DNA sequences associated with transformation. In: F. Rapp (ed.). *Herpesvirus*. Alan R Liss, New York, pp 507- 525.
- Pascoe R.R., Spradbrow P.B., Bagust T.J. (1969). An equine genital infection resembling coital exanthema associated with a virus. *Australian Veterinary Journal* 45, 166-170.
- Pascoe R.R. (1981). The effect of equine coital exanthema on the fertility of mares covered by stallions exhibiting the clinical disease. *Australian Veterinary Journal* 57, 111-114.
- Seki Y., Seimiya Y.M., Yaegashi G., Kumagai S., Sentsui H., Nishimori T., Ishihara R. (2004). Occurrence of equine coital exanthema in pastured draft horses and isolation of equine herpesvirus 3 from progenital lesions. *Journal of Veterinary Medical Science* 66, 1503-1508.
- Studdert M.J. (1996). Equine coital exanthema (Equine herpesvirus 3). In: M.J. Studdert (ed.). *Virus infections of equines*. Elsevier, Amsterdam, pp 39- 46.
- Uppal P.K., Yadav M.P., Singh B.K., Prasad S. (1989). Equine coital exanthema (EHV-3 virus) infection in India. *Zentralblatt für Veterinärmedizin* 36, 786-788.
- Wilks C.R., Studdert M.J. (1976). Equine herpesviruses. 6. Sequential infection of horses with types 2, 3 and 1. *Australian Veterinary Journal* 52, 199-203.

Uit het verleden

PAARDENMEESTER EN HUMANE DOKTER: ELK ZIJN HONING

De oude geneesheren werden ook wel eens piskijkers genoemd en mochten ze het horen, ze zouden er trots op zijn. Via het onderzoek (vooral van de geur en het kleur) van de urine van hun beklagenswaardige patiënten wisten zij immers tot allerhande diagnoses te komen. Op oude schilderijen en prenten werden doctors in de medicijnen steevast voorgesteld met een pisfles tegen het licht houdend en aandachtig bestuderend. Maar hoe zou dat gezeten hebben bij hun tijdgenoten, de ongediplomeerde en Latijn onkundige paardenmeesters?

Een tipje van de sluier werd opgelicht in *Den Lust-Hof van het Cureren der Peirden, beschreven door Mr. Jacobus de Smet, Peirde-Meester in Borgerhout, buyten de Stadt Antwerpen* (eerste druk, Antwerpen 1686). Daarin vinden we het volgende kenmerk van de goede vakman: *een goet Peirde-meester moet altydts riecken aen den strondt, ende een Doctoer der menschen die magh wel snuffelen aen de pisse, soo dat ieder een syn honingh daer uyt haele*. Want wie dat niet doet is geen *goet Meester*. Door dat onderzoek moet men tot een oordeel komen van hoe het *van binnen gestelt* is. En de medicatie moet op dit oordeel gebaseerd zijn, zo voegde Jacobus de Smet er nog ten overvloede aan toe.

Overigens was meester de Smet goed op de hoogte van de paardenanatomie en hij had een rudimentair begrip van fysiologie. Zo wou hij in zijn boek *mede bewys doen van den ommeloop des Bloedts*. Hij stond mede aan het begin van een diergeneeskunde gesteund op anatomische kennis en schreef dit expliciet: *My dunkt dat het wel noodigh waer al eer iemandt hem begint te bemoeyen met het meesteren ofte Cureren van eenige Peirden, dat sy al voren goede kennis hadden van alle Lidt-maeten (onderdelen) van deselve, om dat sy daer uyt souden considereren uyt wat oorspronck dat de quael gesproten is om hem voorts daer naer te reguleren met de Medecynen*.

De citaten zijn afkomstig uit de vierde, van *vele fauten* gezuiverde en vermeerderde druk te Antwerpen, zonder jaartal.

Luc Devriese