

## Unusual presentation of an avulsion of the long digital extensor tendon in a dog: radiographic, computed tomographic, arthroscopic, surgical and histological findings

*Een ongewone vorm van avulsie van de pees van de m. extensor digitorum longus bij een hond: radiografische, computertomografische, artroscopische, chirurgische en histologische bevindingen*

<sup>1,2</sup>G. Verhoeven, <sup>1</sup>B. Van Ryssen, <sup>1</sup>I. Gielen, <sup>1</sup>M. Risselada, <sup>1</sup>H. van Bree

<sup>1</sup>Department of Medical Imaging of Domestic Animals, Faculty of Veterinary Medicine, Ghent University, Salisburylaan 133, B-9820 Merelbeke

<sup>2</sup>Algemene Dierenkliniek Randstad, Frans Beirenslaan 155, B-2150 Borsbeek

Geertverhoeven@hotmail.com

### ABSTRACT

**A long digital extensor tendon avulsion is reported in a 15-month-old intact male Great Dane with a right pelvic limb lameness of 2-week duration. The orthopedic, radiographic, computed tomographic, arthroscopic, surgical and histological findings are described. Surgical excision of the avulsed bone fragment and re-attachment of the tendon to the lateral joint capsule of the stifle joint was successful and the dog was free of lameness 6 and 12 months after therapy.**

### SAMENVATTING

Een avulsie van de pees van de extensor digitorum longus wordt beschreven bij een Deense Dog met reeds 2 weken claudicatie rechts achter. De orthopedische, radiografische, computer tomografische, artroscopische, chirurgische en histologische bevindingen worden beschreven. De chirurgische excisie van het geavulseerde botfragment en de hechting van de pees aan het lateraal gewrichtskapsel van het kniegewricht waren succesvol en de hond was vrij van manken 6 en 12 maanden na de ingreep.

### INTRODUCTION

Avulsion of the long digital extensor (LDE) tendon is a rare cause of hind limb lameness in dogs. The long digital extensor is a spindle shaped muscle that originates proximally by means of a tendon from the extensor fossa of the lateral femoral condyle and passes the joint to run through the extensor groove in the proximal tibia. It then lies on the craniolateral aspect of the tibia, between the cranial tibial muscle and the peroneus longus muscle. More distally, at the level of the metatarsal bones, it becomes a tendon that divides into four portions that pass along the dorsal aspect of the metatarsal and phalangeal bones of the second to the fifth digit to end on the distal phalanx of the supporting digits (Nickel *et al.*, 1983). Its action is extension of the digits and flexion of the tarsus but it does not take part in stabilizing the stifle joint (Smith, 1999).

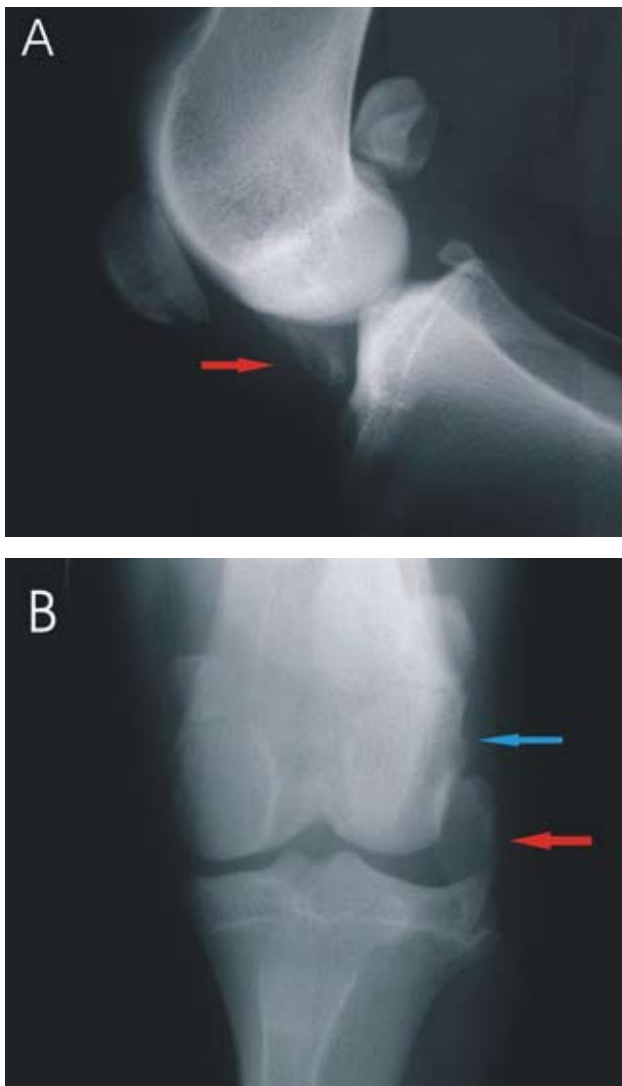
In this report, avulsion of the proximal attachment of the long digital extensor muscle possibly occurred

as an incidental finding at the age of 10 months and became clinical after a minor traumatic event at the age of 15 months.

### CASE DESCRIPTION

#### Workup

A fifteen-month-old male Great Dane, weighing 67.3 kg, was presented with a non-weight bearing lameness of the right hind limb after jumping out of a car 2 weeks earlier. Previous signs of lameness had never been observed but the owner had noticed a distinct firm swelling on the lateral aspect of the right stifle 5 months previously, which was still present at the time of presentation. No radiographs had been taken at that time. Palpation of the right hind limb revealed mild muscle atrophy compared to the left hind limb, and painless crepitation during passive flexion and extension of the right stifle joint. No joint instability was



**Figure 1.** Medio-lateral (A) and caudo-cranial (B) radiographic projections of the right stifle. A triangular-shaped radiopaque mineralized structure (red arrow) is present at the level of the cranial aspect of the condyles and the cranial tibial plateau. An oval-shaped radiopaque mineralized structure (red arrow) measuring 2x3cm is present lateral to the joint space. An irregular zone (blue arrow) is present on the lateral surface of the lateral femoral condyle.

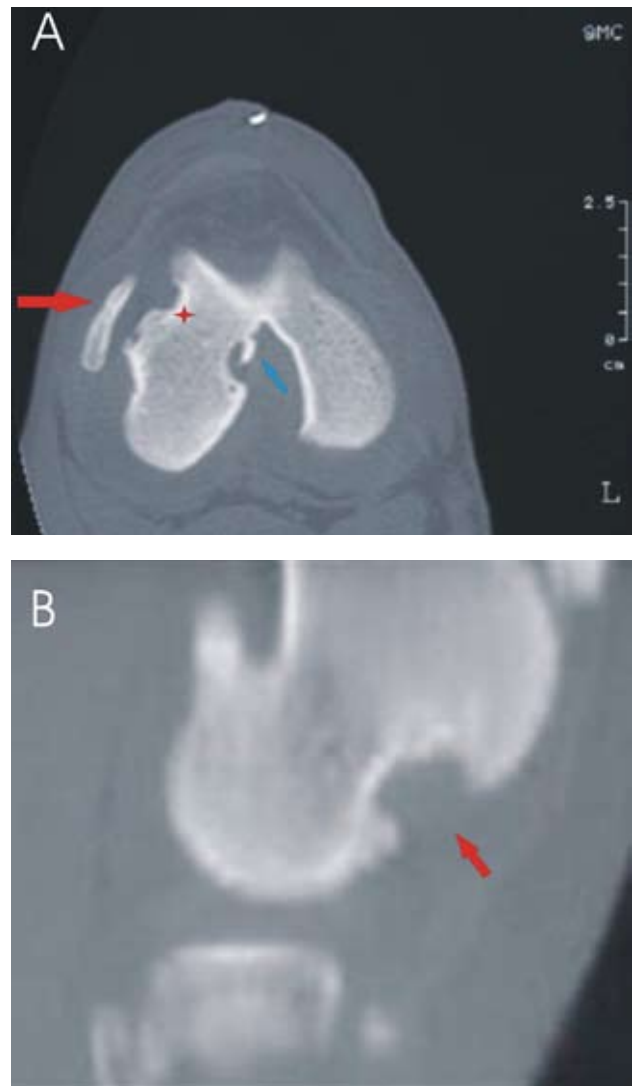
present. The popliteal lymph node was not enlarged. Other clinical abnormalities were not observed.

### Radiographic findings

Medio-lateral and caudo-cranial radiographs (Figures 1A and B) of the right stifle joint revealed a 2 x 3 cm mineralized oval-shaped fragment lateral to the joint space and an irregular bone surface at the level of the lateral femoral condyle. Some joint effusion was noticeable. No osteophytes were observed.

### CT findings

CT examination was performed with a third-generation conventional CT scanner (120 KV, 100 mA). The dog was positioned in ventral recumbency with both hind limbs extended into the tunnel. Contiguous 2-mm transversal CT slices were obtained parallel to

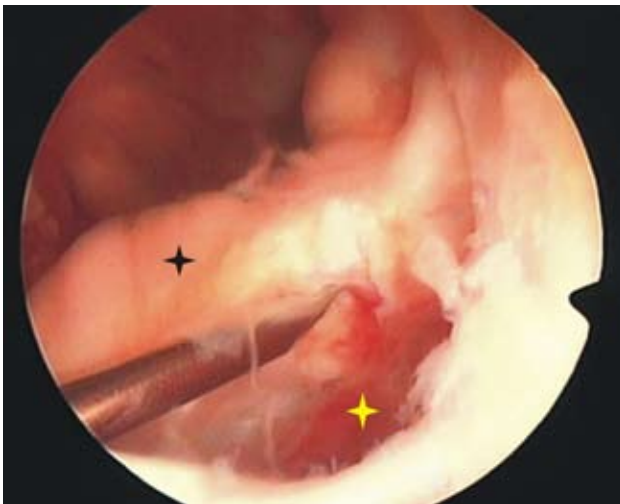

**Figure 2.** Transverse CT image (A) and sagittal reconstruction CT (B) of the right stifle. A mineralized fragment (red arrow in Figure 2 A) is present lateral to the lateral femoral condyle at the level of the attachment of the lateral digital extensor. An irregular defect (asterisk) is noted at the insertion site of the lateral digital extensor. An osteophyte (blue arrow) is present in the intercondylar notch of the femur at the medial surface of the lateral condyle. The bony fragment is larger than the defect in the femoral condyle. The red arrow in figure 2B represents the semicircular bony defect.

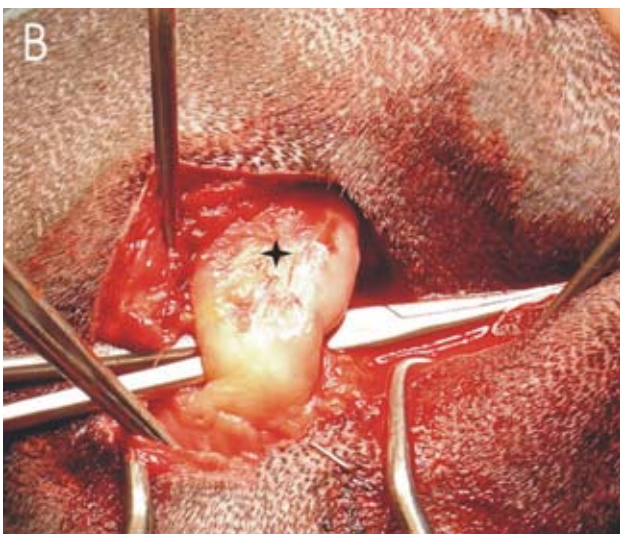
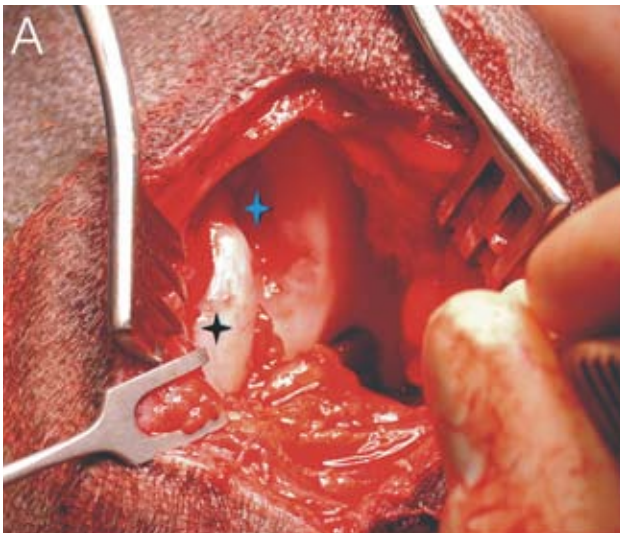
the joint space. An osseous fragment could be seen on a bone window (WW 3500 – WL 500), from the level of the distal part of the lateral femoral condyle extending to the proximal aspect of the tibial plateau (Figure 2A and B). An irregular subchondral defect in the lateral region of the lateral femoral condyle was apparent. A small osteophyte in the intercondylar notch region was evident.

### Arthroscopic findings

After aseptical preparation, the dog was positioned in dorsal recumbency with the affected limb extended caudally. Five millilitres of hemorrhagic synovial fluid was aspirated before distension of the stifle with irrigation fluid (lactated Ringer's solution). The synovial fluid was not further investigated. A thor-



**Figure 3.** Arthroscopic view of the lateral compartment of the right stifle joint. The needle is inserted between the bony defect (yellow asterisk) in the lateral femoral condyle and the partially attached fragment (black asterisk).



**Figure 4.** Intra-operative view of a lateral surgical approach to the right stifle. (A) A defect (blue asterisk) is present in the lateral femoral condyle with the partially overlying osteocartilagenous fragment (black asterisk). (B) A hemostat is inserted under the osteocartilagenous fragment (black asterisk).

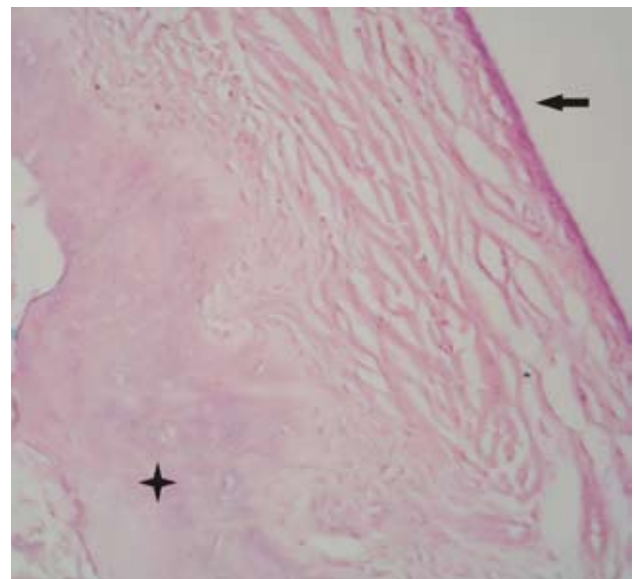
ough inspection of the entire joint was performed. A smooth fragment of cartilage with the long digital extensor still attached ventrally was visible (Figure 3). Some free movement of the fragment was present. An irregular zone on the lateral femoral condyle where the long digital extensor tendon normally originates was obvious. Mild synovial thickening and some reddish discoloration was noticeable.

### Surgical findings

Two weeks later, a craniolateral arthrotomy was performed and the joint was inspected (Piermattei and Johnson, 2004). Mild synovial thickening and redness were noticed and an ovoid mass of cartilage and bone to which the long digital extensor tendon was attached was found. Some fibrous tissue adhesions between the fragment and the lateral femoral condyle were apparent (Figures 4A and B). The avulsed piece was bluntly isolated and excised. The long digital extensor tendon was sutured to the lateral joint capsule using a modified Bunnell-Mayer tendon suture pattern in 2-0 polydioxanone (PDS, Ethicon). Closure of the joint and soft tissues was performed in routine fashion.

### Histological findings

The excised fragment was fixed in 10% phosphate-buffered formalin and embedded in paraffin, then sectioned at 5  $\mu$ m and stained with hematoxylin-eosin (HE) and Giemsa. Viable mineralized trabecular bone was present in the center of the fragment, surrounded by osteoblasts. The bony center was surrounded by a thin rim of cartilage. Peripherally, fibrous tissue was present (Figure 5). Bone formation was by endochondral ossification. The attached tendon did not show any signs of metaplasia. The synovial villi were irregular with neovascularization of the supporting layer. Neutrophils were found occasionally in the synovial membrane.



**Figure 5.** Section of the bony piece illustrating surrounding fibrous tissue (arrow) and the more centrally located osteocartilagenous fragment (asterisk).

## Follow-up

The dog was rested for 4 weeks and given 10 mg/kg tepoxalin (Zubrin, Schering-Plough) once daily for 2 weeks. On re-examination 6 weeks and 6 months postoperatively, a mild lameness was still present but no pain could be elicited on palpation despite a firm swelling on the lateral joint surface. The range of motion was similar for both stifles and no crepitation was present on palpation. Phone contact with the owner 1 year postoperatively revealed no lameness and excellent function of the dog.

## DISCUSSION

Pathology of the long digital extensor (LDE) muscle tendon is rare: avulsion of its proximal attachment (Pond, 1973; Lammerding *et al.*, 1976; Olmstead and Butler, 1976; Stickle and Birchard, 1981; Bardet and Piermattei, 1983; Fitch *et al.*, 1997) and dislocation from the tibial sulcus have been described (Bennett and Campbell, 1979; De Rooster *et al.*, 2004). In these previous reports, the long digital extensor avulsion occurs mainly in skeletally immature large breed dogs, less than 1 year old, except for a 14-month-old Great Dane that was presented for a tibial fracture with an incidental and subclinical long digital extensor avulsion (Stickle and Birchard, 1981). Concurrent skeletal abnormalities such as partial avulsion of the popliteus muscle tendon, patellar luxation (Bardet and Piermattei, 1983) and osteochondrosis dissecans of the lateral femoral condyle of the contralateral stifle (Fitch *et al.*, 1997) have been reported.

The etiology of long digital extensor avulsion is not clear, but the disease seems to occur after a traumatic episode, although major trauma is not present in most cases (Whittick, 1990). Clinical signs may vary from mild to severe hind limb lameness. Lameness quickly may subside to become mild and chronic with a firm swelling on the lateral part of the stifle joint. Pain and crepitation during passive flexion and extension may be obvious. More advanced imaging techniques such as computed tomography and magnetic resonance imaging (Fitch *et al.*, 1997) can provide additional spatial information because superposition of structures is avoided.

Surgery is the therapy of choice. Conservative treatment results in chronic irritation of the synovial membrane and joint cartilage by the large fragment, which results in degenerative joint disease. Surgical options depend on the size of the fragment (Anderson, 1994). Re-attachment of the bony fragment with its tendon to the original insertion using a bone screw or Kirschner wires can be achieved in cases with a fresh avulsion. This technique can only be performed within one week after the avulsion because after seven days, the fragment has already grown to a more round and smooth structure. Furthermore, the defect in the insertion site may decrease in an attempt to close as healing takes place. Trimming the fragment to its original size and re-attaching it is time consuming and not recommended. Excision of the fragment and suturing the tendon to the lateral joint capsule or

the lateral collateral ligament is a simple and effective method. Most cases regain full function within several weeks or months after surgery, independent of the technique used.

The dog described herein became acutely lame following a mild traumatic event while jumping out of a car. According to the owner, a distinct swelling on the lateral part of the stifle joint had been present for several months before this event although no trauma or lameness had been observed previously. This is an unusual finding in comparison to previous reports but similar to the case described by Stickle and Birchard (1981), who reported on a 14-month-old Great Dane whose owner had noticed a distinct swelling on the lateral part of the stifle following a sudden occurrence of lameness at 9 months of age. In that report, the dog was presented for a tibial fracture which was repaired, and functional recovery occurred without surgical intervention on the long digital extensor avulsion. Avulsion of the long digital extensor tendon can therefore be asymptomatic for an extended period of time, without causing degenerative joint disease.

It is unclear why the dog in this report did not show any lameness after the lateral swelling emerged at the age of 10 months. Partial long digital extensor avulsion without clinical signs, followed by complete avulsion, may have occurred after additional trauma. Another possible cause is a complete long digital extensor avulsion with a fragment that becomes more stable over time without causing gross inflammation, followed by fragment instability with acute synovial inflammation and hemarthrosis after additional trauma. Because minor osteoarthritic findings were found on radiography, arthroscopy, computed tomography and surgery, hemarthrosis due to osteoarthritis was considered unlikely. Bacterial arthritis due to hematogenous spread of bacteria after trauma is another possible cause of hemarthrosis. Although no further synovial fluid investigations were performed, bacterial arthritis was considered unlikely in this case because of the lack of fever, lymph node swelling and pain during palpation and the absence of gross neutrophilic synovial inflammation on histopathology.

Our case was slightly older (15 months) compared to most dogs described (5-8 months), possibly indicating that an initial avulsion took place at an earlier age. Because of these unusual clinical findings, we chose to obtain better diagnostic insight concerning the lesions and other intra-articular structures before performing further surgery.

The significance of the intercondylar osteophyte seen on the CT images is uncertain and may or may not be representative for osteoarthritis. In the presence of a chronically unstable intra-articular fragment, osteophytes on radiography, arthroscopy and CT would be expected. The presence of hemarthrosis, observed during arthroscopy, supports the suspicion of recent trauma, although the active endochondral ossification on histopathology and the fibrous attachment of the bone fragment during arthroscopy suggests a more chronic condition of the long digital extensor avulsion. These findings support the hypothesis of an old subclinical long digital extensor pathology followed by a more recent long digital extensor avulsion.

## CONCLUSION

Avulsion of the long digital extensor can occur without clinical signs, with lameness occurring only later after a further minor traumatic event. Computed tomographic imaging and stifle arthroscopy were used to provide a more thorough diagnostic insight into long digital extensor avulsion. Computed tomographic imaging was the only technique by means of which degenerative bone lesions were detected. The outcome after surgical excision of the fragment and re-attachment of the tendon to the joint capsule was excellent in this case.

## REFERENCES

- Anderson J. (1994). Conditions involving muscles arising or inserting around the stifle. In: Houlton JEF, Collinson RW (editors). *Manual of Small Animal Arthrology*. 1st ed. The British Small Animal Association, Gloucestershire, p 290.
- Bardet J.F., Piermattei D.L. (1983). Long digital extensor and popliteal tendon avulsion associated with lateral patellar luxation in a dog. *Journal of American Veterinary Medical Association* 183, 465-466.
- Bennett D., Campbell J.R. (1979). Unusual soft tissue orthopaedic problems in the dog. *Journal of Small Animal Practice* 20, 27.
- De Rooster H., Risselada M., van Bree H. (2004). Displacement of the proximal tendon of the long digital extensor muscle: a case report in a bilaterally affected working dog. *Veterinary and Comparative Orthopedics and Traumatology* 3, 1-3.
- Fitch R.B., Wilson E.R., Hathcock J.T., Montgomery R.D. (1997). Radiographic, computed tomographic and magnetic resonance imaging evaluation of a chronic long digital extensor tendon avulsion in a dog. *Veterinary Radiology and Ultrasound* 38, 177-181.
- Lammerding J.J., Noser G.A., Brinker B.O., Carrig C.B. (1976). Avulsion fracture of the origin of the extensor digitorum longus muscle in three dogs. *Journal of American Animal Hospital Association* 12, 764.
- Nickel R., Schummer A., Seiferle E (1983). The locomotor system of the domestic mammals. In: *The Anatomy of the Domestic Animals*. Vol.1. Ed. Verlag Paul Parey, Berlin-Hamburg, p 417-418.
- Olmstead M.L., Butler H.C. (1976). Surgical correction of avulsion of the long digital extensor in the dog. *Veterinary Medicine/Small Animal Clinics* 71, 608.
- Piermattei D.L., Johnson K.A. (2004). *An Atlas of Surgical Approaches to the Bones and Joints of the Dog and the Cat*. 4th ed. WB Saunders, Philadelphia, p 342-345.
- Pond M.J., (1973). Avulsion of the extensor digitorum longus muscle in the dog. A report of four cases. *Journal of Small Animal Practice* 14, 785.
- Smith B.J. (1999). Muscles of the pelvic limb. In: Smith BJ (editor). *Canine Anatomy* Lippincot Williams & Wilkins Philadelphia, p 524-542.
- Stickle R.L., Birchard S.J. (1981). Questions and answers. *Journal of American Veterinary Medical Association* 179, 715-716.
- Whittick W.G. (1990). Lea and Febiger (editors). *Canine Orthopedics*. 2nd ed. Philadelphia/London, p 778-779.