

Enterococcus cecorum osteomyelitis and arthritis in broiler chickens

Enterococcus cecorum osteomyelitis en arthritis bij vleeskuikens

¹P. De Herdt, ²P. Defoort, ³J. Van Steelant, ⁴H. Swam, ⁵L. Tanghe, ⁶S. Van Goethem,
³M. Vanrobaeys

¹ Intervet Belgium, Bedrijvenlaan 7, B-2800 Mechelen, Belgium

² Provet Veterinary Practice, Ieperse Heerweg 53, B-8820 Torhout, Belgium

³ Animal Health Care Flanders, Industrielaan 29, B-8820 Torhout, Belgium

⁴ Intervet International, W. de Körverstraat 35, NL 5831 AN Boxmeer, the Netherlands

⁵ Benevet Veterinary Practice, Vrijlatenstraat 21, B-8020 Ruddervoorde

⁶ Veterinary Practice, Uilenstraat 203, B-9100 Sint-Niklaas

ABSTRACT

Starting from December 2006, *Enterococcus cecorum* infections with a clinical course have increasingly been observed in Belgian broilers. The present paper describes the characteristics of the disease on the basis of observations in 10 different farms. The affected chicks always suffered from paresis and lameness. Onset of the signs was usually within the first 2 weeks of life, and it resulted in up to 7% increased mortality starting from day 21-32. The cocks were affected significantly more often than the hens. Lesions of osteomyelitis of the caudal thoracic vertebrae compressing the spinal cord and/or arthritis of the hock joints were consistently found. *E. cecorum* was always isolated from these lesions. The disease was recurrent in successive rounds in 9 out of the 10 farms. Antibiotic treatment was only successful when initiated preventively from the first week of life onwards. Other infections often associated with similar signs were not detected. It can be concluded that *E. cecorum* infections form an important emerging disease in broilers, leading to high mortality rates.

SAMENVATTING

Sinds december 2006 worden *Enterococcus cecorum* infecties met een klinisch verloop in toenemende mate waargenomen bij Belgische vleeskuikens. In dit artikel worden de kenmerken van de ziekte aan de hand van de observaties op 10 verschillende pluimveebedrijven besproken. Aangestaste kuikens vertoonden steeds tekenen van verlamming en manken. De symptomen begonnen meestal binnen de eerste twee levensweken en resulteerden in een verhoogde sterfte tot 7% vanaf dag 21-32. Hanen waren significant meer aangetast dan hennen. Steeds werden osteomyelitis van de caudale thoracale wervels met een compressie van het ruggenmerg en/of artritis van het hakgewricht aangetroffen. *E. cecorum* kon altijd uit deze letsels geïsoleerd worden. Op 9 van de 10 bedrijven traden de problemen in meerdere opeenvolgende ronden op. Een antibioticumbehandeling was slechts succesvol wanneer ze preventief werd toegepast vanaf de eerste levensweek. Andere infecties die vaak met gelijkaardige symptomen geassocieerd worden, werden niet aangetroffen. Er werd besloten dat *E. cecorum* infecties een belangrijke aandoening vormen die vaak optreedt en leidt tot hoge sterftepercentages.

INTRODUCTION

The Gram-positive bacterium *Enterococcus cecorum* (Devriese *et al.*, 1983) is a normal part of the gut flora in numerous animal species including chickens, ducks, pigeons, canaries, pigs, calves, horses, cats and dogs (Baele *et al.*, 2002; Devriese *et al.*, 1991, 1992a, 1992b, 1994). The agent is sporadically involved in peritonitis, septicemia and empyema in humans suffering from other underlying diseases or weakening factors such as alcohol abuse, liver cirrhosis, malnourishment and continuous ambulatory peritoneal dialysis. As far as we know, *E. cecorum* associated disease in humans has only been described four times (De Baere *et al.*, 2000; Greub *et al.*, 1997; Hsueh *et al.*, 2000; Woo *et al.*, 2004).

The clinical relevance of *E. cecorum* in animals seems until now to have been restricted to broiler chickens and broiler breeders. Indeed, *E. cecorum* could occasionally be held responsible for bone and joint lesions resulting in lameness and paralysis of broilers, as reported twice in 2002 (Devriese *et al.*, 2002; Wood *et al.*, 2002) and for similar problems in broiler breeders, as reported once in 2007 (Aziz and Barnes). To the best of our knowledge, no other reports on disease caused by *E. cecorum* in either humans or animals are available in the literature.

Starting from December 2006, outbreaks of paresis and lameness due to *E. cecorum* osteomyelitis and arthritis have increasingly been observed in Belgian broiler flocks. The same is true for broilers in neighbo-

ring countries (poultry practitioners, personal communications). Clinical problems caused by *E. cecorum* thus seem to be well-established in at least some Western European countries at present. This paper aims to give a review of *E. cecorum* associated disease outbreaks that occurred in 10 broiler farms between December 2006 and May 2008.

CASE HISTORY

From December 2006 to January 2008, 10 Belgian broiler farms experienced similar clinical complaints. The first signs usually presented at the age of 7 – 14 days with some chicks showing difficulties in walking. Within the following weeks, this problem developed in an increasing number of birds, though the percentage of affected chicks remained low for one to four weeks. However, starting between day 21 and day 32 of age, there was always a sudden increase in the number of affected chickens and the severity of the clinical problems. The latter consisted of paresis and lameness. Rather typical in this respect were birds sitting on their back parts with their legs directed forwards (Figure 1). Chicks suffering from these signs were often no longer able to move towards the feed and water supplies, because of which they rapidly dehydrated and died. The daily mortality associated with this phenomenon ranged from 0.11% to 0.58% of the flocks (Table 1), resulting in an overall increased mortality at the end of the growing period of 2% - 7%. A remarkable fact was that it was especially the cocks that showed clinical signs and died. Indeed, the cocks constituted 95% of all the birds that were randomly collected from groups of clinically affected chicks for autopsy purposes. Besides the reported signs of paresis and lameness, the general health of the flocks was excellent and the mean weights at slaughter were always high. In most flocks, however, the overall feed conversion calculated at the end of the round was rather poor; which was probably a consequence of the



Figure 1. Thirty-nine-day-old broiler chick sitting on its back parts with the legs directed forwards. This typical posture is due to compression of the spinal cord at the caudal thoracic vertebrae resulting from *E. cecorum* induced lesions of osteomyelitis.

strongly increased mortality rates during the growing period. Moreover, dehydrated birds were subject to slaughterhouse condemnation, thereby elevating the flock condemnation rates.

Seven out of the 10 flocks experiencing these types of problems were grown in farms that had multiple broiler houses. In none of these farms, however, did the signs occur in more than one house. On the other hand, a common feature in 9 out of the 10 flocks was reoccurrence of the clinical signs in multiple successive rounds of the same house, even for up to 1.5 years in one of them. In all farms, the pattern of recurrent disease at the flock level stopped after preventive treatments with amoxicillin and/or tylosin at regular intervals during the growing period of the chicks, starting from the first week of life.

In all flocks, 5 – 30 chicks showing paresis or lameness were euthanized and necropsied. A consistent finding in almost all the birds was the presence of a

Table 1. Characteristics of 10 flocks of broiler chicks suffering from clinical disease associated with *E. cecorum* infections.

Flock	Age at onset of signs and mortality*	Daily mortality from onset of signs to slaughter**	Rounds with similar clinical course
1	Day 32	0.22 %	9
2	Day 32	0.43 %	8
3	Day 29	0.58 %	3
4	Day 21	0.25 %	2
5	Day 29	0.24 %	3
6	Day 26	0.13 %	2
7	Day 26	0.26 %	1
8	Day 25	0.43 %	2
9	Day 22	0.11 %	2
10	Day 22	0.15 %	2

*Age at onset of signs and mortality = age when clinical signs of paralysis and lameness became overt at the flock level and mortality significantly increased. This was usually preceded at an earlier age by chicks showing difficulties in walking but without clearly increased flock mortality.

** Age of slaughter = day 41 (8 farms) or day 42 (2 farms)

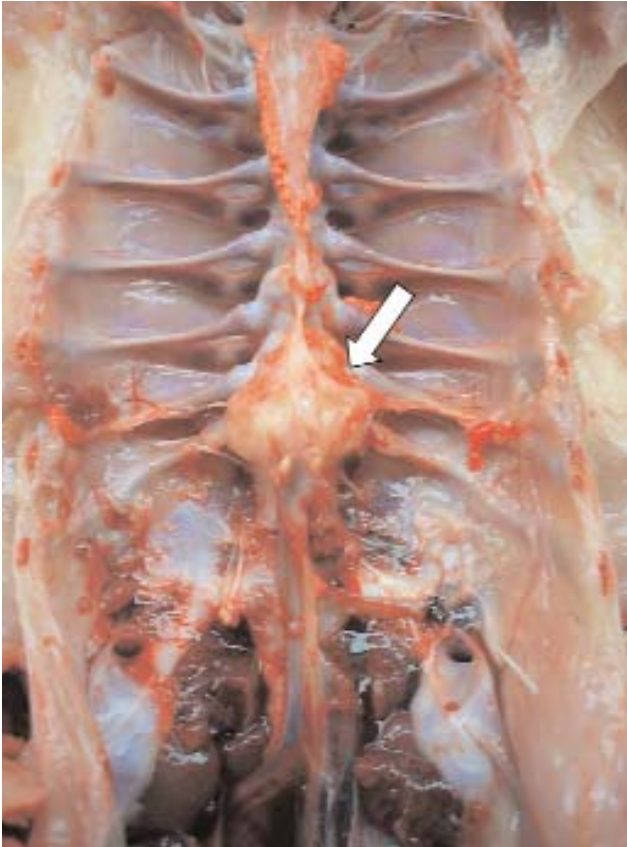


Figure 2. Osteomyelitis characterized by a firm bony swelling (arrow) at the caudal thoracic vertebrae in a broiler suffering from paresis. *E. cecorum* was isolated from this lesion.

firm swelling at the caudal part of the thoracic vertebrae, usually extending over two adjacent vertebrae between T5 and T7 (Figure 2). The lesion was macroscopically invisible unless the kidneys and lungs were removed. It could easily be palpated, however. Upon longitudinal section of the swelling, it could be observed that the spinal cord was often compressed at this site (Figure 3), thereby most probably causing the clinical signs. In some chicks, arthritis of the hock joints was also noted, usually with just a discrete swelling. Furthermore there was a remarkably high incidence of femoral head necrosis in all affected flocks. Besides the dehydration in a number of chicks, no other abnormalities were observed.

Standard diagnostic procedures in necropsied birds included cytological examination of multiple organs, most often trachea, lungs, heart, liver, kidneys, pancreas, gastrocnemius tendon, hock joint, and jejunum. For this purpose, impression smears were stained with the Hemacolor (Merck, Darmstadt, Germany) staining reagents and observed microscopically at a magnification of x1000. In the overall majority of chicks, inflammatory lesions were absent in most examined organs. In a few birds, however, an abundant infiltration of heterophilic granulocytes and coc-shaped bacteria was found in impression smears of the gastrocnemius tendon and the hock joints. In 2 chicks

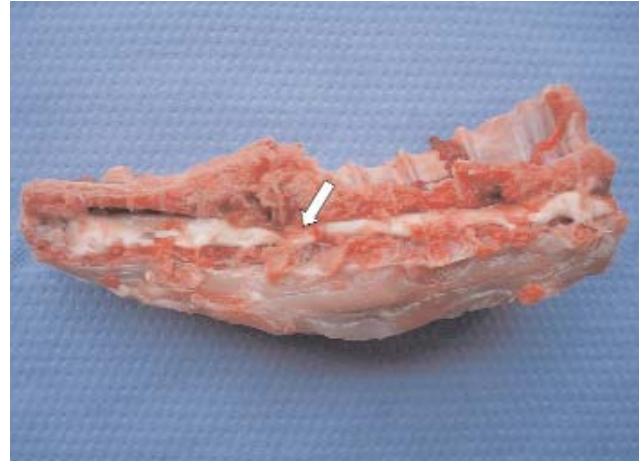


Figure 3. Longitudinal section of the vertebral column of a broiler suffering from paresis. A lesion of osteomyelitis at the caudal thoracic vertebrae is compressing the spinal cord (arrow), thus causing the clinical signs. *E. cecorum* was isolated from the lesion.

obtained from different farms, coc-shaped bacteria were also observed in the liver.

Vertebral lesions of three chicks were fixated in a 4% phosphate-buffered formalin solution, decalcified and processed for histological examination. Tissue sections were stained with hematoxylin and eosin. The lesions indicated a multifocal chronic purulent osteomyelitis, characterized by the formation of large cysts and resorption of trabecular bone. The cysts were centrally filled with heterophilic granulocytes, while at the periphery there was a marked proliferation of connective tissue and giant cells.

In all flocks, routine bacteriological examination was done of samples collected from the vertebral nodules of 4 – 8 affected chicks. Following inoculation of the samples onto Columbia blood agar (Oxoid, Basingstoke, UK) and incubation at 37 °C in a 5% CO₂-enriched atmosphere, in each bird pure and abundant cultures of *E. cecorum* were obtained. No other bacteria were detected. *E. cecorum* was furthermore isolated from hock joints in 3 out of the 10 farms, two of which were in pure cultures, and the other of which was together with *Staphylococcus spp.* *E. cecorum* was identified on the basis of its colony morphology, its capnophilic nature, its inability to grow on Slanetz and Bartley agar (Oxoid), and the unique reaction profiles in API 20 STREP (Biomérieux, La Balme-les-Grottes, France). For bacteria obtained from a single flock, their identity was confirmed on the basis of tDNA intergenic spacer PCR (Baele *et al.*, 2000).

Antibiogram testing of isolates from 7 farms on Columbia blood agar under 5% CO₂-enrichment using Neosensitab tablets (Rosco, Taastrup, Denmark) consistently revealed sensitivity to ampicillin/amoxicillin and macrolides. Acquired resistance to lincomycin, tetracyclines, oxacillin and aminoglycosides was observed in 2, 3, 3 and 6 of the 7 isolates, respectively.

PCR's for the detection of *Ornithobacterium rhinotracheale*, *Mycoplasma synoviae* and *Mycoplasma*

gallisepticum were performed (Labofarm, Loudéac, France) on samples taken from vertebral lesions in 10 individual birds. All the samples were consistently negative.

In 4 flocks, samples of vertebral lesions, gastrocnemius tendons, livers, pancreases and bursas were examined for the presence of reovirus, as described (De Herdt *et al.*, 2008; van Loon *et al.*, 2001). Briefly, supernatant obtained after centrifugation of homogenized tissue samples was inoculated onto freshly prepared primary chicken embryo liver cells. After 4 to 8 days of incubation, the monolayers were inspected for the presence of a cytopathic effect. In the event of negative results, up to 3 serial passages were made.

Reovirus was isolated in none of the flocks. The isolation procedure, however, revealed the presence of a Fowl Adenovirus serotype 5 (FAV5) isolate in the livers of one of the flocks.

DISCUSSION

The clinical significance of *E. cecorum* infections in broilers was first described in 2002 (Devriese *et al.*, 2002; Wood *et al.*, 2002). Until recently, *E. cecorum* infections with a clinical course were extremely rare. Indeed, the rather typical signs related to *E. cecorum* infections were only sporadically observed. This is also reflected in the lack of reports on the disease in the literature since the initial descriptions in 2002. However, starting from December 2006, *E. cecorum* associated signs have increasingly been observed in broilers in Belgium. The present study dealt with 10 confirmed cases, but the incidence in the field is much higher. Since the typical signs and lesions allow an easy diagnosis, poultry practitioners often do not seek further laboratory examinations. Increasing numbers of outbreaks have also been seen in neighboring countries (poultry practitioners, personal communications). This evidence thus seems to indicate that *E. cecorum* infections form an emerging disease in broilers, at least in Western Europe.

It is unclear why broilers are increasingly suffering from clinical disease caused by *E. cecorum*. A clonal origin of isolates with increased virulence could be possible. However, differences in antibiotic susceptibility between isolates do not support this view. Another explanation could be that broiler chicks are more frequently being exposed to factors predisposing to a clinical course of *E. cecorum* infections. Genetic selection, changing nutritional requirements of chicks, restrictions on the use of certain feed additives, increased prevalence of specific concurrent infections, and other factors could be considered. However, up to the present it has not been possible to identify any predisposing factors. In the present study, at least no indications were found for the consistent presence of concurrent infections. An adenovirus infection was demonstrated in one of the affected flocks, but its role in the pathogenesis of the *E. cecorum* infections is unclear. It is possible that the simultaneous passage of the two agents in the flock was based purely on coin-

idence. Adenoviruses may pass through broiler flocks without causing apparent clinical disease (McFerran, 2003).

The pathogenesis of *E. cecorum* infections is unknown. Field observations have substantiated that clinical problems caused by *E. cecorum* can be carried over from one round to another. This could indicate that a contaminated environment can act as the source of infection. The caudal thoracic vertebrae and the hock joints seem to be predilection places for multiplication of the bacteria, leading to clinical signs. The underlying mechanisms for this special affinity and the way the agents reach these parts of the body are unknown. The presence of coc-shaped bacteria observed in the liver of some affected chicks could indicate septicemia, but more evidence is needed to support this possibility. It was furthermore remarkable that almost all the affected birds were cocks. There thus seems to be an association between the sex of the birds and the occurrence of clinical signs. Again, the pathogenetic background is unknown but it seems possible that the vertebral column and the joints are more heavily weighed on in cocks because of their higher body weights, thereby eventually causing traumata and promoting the multiplication of *E. cecorum*. In conclusion, more research on the pathogenesis of *E. cecorum* infections in broilers is needed.

ACKNOWLEDGEMENTS

The authors wish to express their great appreciation to M. Baele from the Department of Pathology, Bacteriology and Poultry Diseases of Ghent University for performing a tDNA intergenic spacer PCR.

REFERENCES

- Aziz T, Barnes J. (2007). Is spondylitis an emerging disease in broiler breeders? *World Poultry* 23, 44-45.
- Baele M., Baele P., Vaneechoutte M., Storms V., Butaye P., Devriese L.A., Verschraegen G., Gillis M., Haesebrouck F. (2000). Application of tRNA intergenic spacer PCR for identification of *Enterococcus* species. *Journal of Clinical Microbiology* 38, 4201-4207.
- Baele M., Devriese L.A., Butaye P., Haesebrouck F. (2002). Composition of enterococcal and streptococcal flora from pigeon intestines. *Journal of Applied Microbiology* 92, 348-351.
- De Baere T., Claeys G., Verschraegen G., Devriese L.A., Baele M., Van Vlem B., Vanholder R., Dequidt C., Vaneechoutte M. (2000). Continuous peritoneal dialysis peritonitis due to *Enterococcus cecorum*. *Journal of Clinical Microbiology* 38, 3511-3512.
- De Herdt P., Paul G., Koopman R., Van De Zande S. (2008). Field experiences with ERS type reovirus infections in diseased broilers reared under Western European field circumstances. *Flemish Veterinary Journal* 78, 168-172.
- Devriese L.A., Dutta G.N., Farrow J.A.E., Van De Kerckhove A., Phillips B.A. (1983). *Streptococcus cecorum*, a new species isolated from chickens. *International Journal of Systematic Bacteriology* 73, 421-425.

- Devriese L.A., Hommez J., Wyffels R., Haesebrouck F. (1991). Composition of the enterococcal and streptococcal intestinal flora of poultry. *Journal of Applied Bacteriology* 71, 46-50.
- Devriese L.A., Cruz Colque J.I., De Herdt P., Haesebrouck F. (1992a). Identification and composition of the tonsillar and anal enterococcal and streptococcal flora of dogs and cats. *Journal of Applied Bacteriology* 73, 421-425.
- Devriese L.A., Laurier L., De Herdt P., Haesebrouck F. (1992b). Enterococcal and streptococcal species isolated from faeces of calves, young cattle and dairy cows. *Journal of Applied Bacteriology* 72, 29-31.
- Devriese L.A., Hommez J., Pot B., Haesebrouck F. (1994). Identification and composition of the streptococcal and enterococcal flora of tonsils, intestines and faeces of pigs. *Journal of Applied Bacteriology* 77, 31-36. 1994.
- Devriese L.A., Cauwerts K., Hermans K., Wood A.M. (2002). *Enterococcus cecorum* septicaemia as a cause of bone and joint lesions resulting in lameness in broiler chickens. *Flemish Veterinary Journal* 71, 219-221.
- Greub G., Devriese L.A., Pot B., Dominguez J., Bille J. (1997). *Enterococcus cecorum* septicaemia in a malnourished adult patient. *European Journal of Clinical Microbiology and Infectious Diseases* 16, 594-598.
- Hsueh P.R., Teng L.J., Chen Y.C., Yang P.C., Ho S.W., Luh K.T. (2000). Recurrent bacteremic peritonitis caused by *Enterococcus cecorum* in a patient with liver cirrhosis. *Journal of Clinical Microbiology* 38, 2450-2452.
- McFerran J.B. (2003). Adenovirus infections: introduction. In: Saif Y.M, Barnes H.J., Glisson J.R., Fadly A.M., McDougald L.R., Swayne D.E. (editors). *Diseases of Poultry*. 11th Ed., Iowa State Press, Ames, IA., p. 213-214.
- van Loon A.A., Koopman H.C., Kosman W., Mumczur J., Szeleszcuk O., Karpinska E., Kosowska G, Lütticken D. (2001). Isolation of a new serotype of avian reovirus associated with malabsorption syndrome in chickens. *Veterinary Quarterly* 23, 129-133.
- Woo P.C., Tam D.M., Lau S.K., Fung A.M., Yuen K.Y. (2004). *Enterococcus cecorum* empyema thoracis successfully treated with cefotaxime. *Journal of Clinical Microbiology* 42, 919-922.
- Wood A.M., MacKenzie G, McGillveray N.C., Brown L., Devriese L.A., Baele M. (2002). Isolation of *Enterococcus cecorum* from bone lesions in broiler chickens. *The Veterinary Record* 150, 27.



BREEDEX

De vakbeurs voor de professionele veehouderij

Brussels Expo - Paleis 12

Van woensdag 2 tot vrijdag 4 december 2009

Breedex, georganiseerd door Fedagrim, stelt de professionele veehouderij in de kijker en laat u toe gedurende 3 dagen efficiënt zaken te doen aan een minimale kost.

Mis deze gedroomde kans niet om de leveranciers van producten of diensten voor de professionele veehouderij te ontmoeten: veevoederproducenten en leveranciers van veevoederadditieven, farmabedrijven, adviesverlenende bedrijven in de veehouderij, slachthuizen en afnemers van vee, veetransportbedrijven, grondstoffenfabrikanten en opslagbedrijven, melkerijen, lastenboekbeheerders, ...

Contacteer ons voor meer informatie of om uw stand te reserveren op +32 (0)2 262 06 00 (tel) - +32 (0)2 262 04 02 (fax) - info@fedagrim.be



