

## Septic pericarditis in a complicated case of non-associated immune-mediated hemolytic anemia in a Jack Russel terrier

*Septische pericarditis in een complex geval van niet-geassocieerde immuungemedieerde hemolytische anemie bij een jack russell terriër*

C. De Voogt, G. Mampaey, G. Schils, P. Smets, L. Stammeleer

Small Animal Department, Faculty of Veterinary Medicine, Ghent University,  
Salisburylaan 133, B-9820 Merelbeke, Belgium

charlotte.devoogt@ugent.be

### ABSTRACT

A three-year-old, male, intact Jack Russel terrier was referred for severe regenerative anemia and was diagnosed with non-associated immune-mediated hemolytic anemia. Treatment was implemented according to the ACVIM guidelines (Swann et al., 2019). As no response was seen eleven days later despite two immunosuppressive drugs, intravenous immunoglobulins (IVIG, 1 g/kg) were administered. Three days later, septic shock and diffuse intravascular coagulation (DIC) developed. Echocardiography revealed pericardial effusion with cardiac tamponade and thrombus in the right atrium. Fluid analysis confirmed septic pericarditis. A pericardial drain was placed following immediate reoccurrence of the pericardial effusion. Despite a stable hematocrit for several days following IVIG administration, a decrease in hematocrit was subsequently noted and splenectomy was performed. In total, six blood transfusions were given. Two years after presentation and intensive follow-up, immunosuppressive therapy was tapered, and the dog had excellent quality of life.

### SAMENVATTING

Een drie jaar oude, mannelijke, intacte Jack Russell terriër werd doorverwezen voor erge regeneratieve anemie en werd gediagnosticeerd met niet-geassocieerde immuungemedieerde hemolytische anemie. Een behandeling werd opgestart volgens de ACVIM-richtlijnen (Swann et al., 2019). Aangezien er geen respons werd waargenomen na elf dagen ondanks twee immunosuppressiva, werden intraveneuze immunoglobulines (IVIG, 1 g/kg) toegediend. Drie dagen later ontstonden bij de hond septische shock en diffuse intravasculaire coagulatie (DIC). Tijdens het echocardiografisch onderzoek werden pericardiale effusie met harttamponade en thrombus in het rechteratrium aangetoond. Analyse van de effusie bevestigde septische pericarditis. Een pericardiale drain werd geplaatst wegens het onmiddellijk heroptreden van de pericardiale effusie. Ondanks een stabiele hematocriet gedurende verscheidene dagen na IVIG-toediening, daalde de hematocriet opnieuw en een splenectomie werd uitgevoerd. In totaal werden zes bloedtransfusies gegeven. Twee jaar na initiële presentatie en intensieve opvolging werd de immunosuppressieve therapie afgebouwd en had de hond een excellente levenskwaliteit.

### INTRODUCTION

Immune-mediated hemolytic anemia (IMHA) is a common disease in which autoantibodies target erythrocytes. Therapy consists of immunosuppressive drugs, thromboprophylaxis, blood transfusions

and supportive treatment (Swann et al., 2019). The mortality rate is the highest in the first weeks after diagnosis, ranging from 21% up to 83% (Kidd and Mackman, 2013). Most dogs are in a hypercoagulable state and are at high risk for thromboembolism, which is one of the most common causes of death in IMHA.

Thromboembolism has been detected in 28% of dogs with IMHA and in up to 80-100% on postmortem examination (Carr et al., 2002; Weinkle et al., 2005; Kidd and Mackman, 2013). Comorbidity caused by immunosuppressive therapy, which can differ greatly in severity ranging from mild side effects to severe opportunistic infections, is often noticed. Development of new infections is more common than (re)activation of latent, preexisting infections (Swann et al., 2019). In a study by High and Olivry (2020), the prevalence of bacterial infections was 17% in dogs treated with cyclosporine as an immunosuppressant. These dogs were treated with cyclosporine for immune-mediated polyarthritis, anal furunculosis, meningitis of unknown origin or to prevent renal transplantation rejection. Bacterial infections were most common in the gastro-intestinal tract, urinary tract and respiratory system (High and Olivry, 2020). Depending on the severity of the infection and on how well the IMHA is controlled, immunosuppressive therapy sometimes needs to be modified (Swann et al., 2019). In this case report, the successful management of a dog with refractory IMHA with an unusual opportunistic infection due to immunosuppressive therapy is described.

**CASE HISTORY**

A three-year-old, entire, male Jack Russell terrier was referred to the Small Animal Clinic of Ghent University for severe regenerative anemia. The dog was presented four days earlier at the referring veterinarian for acute lethargy, hyporexia, vomiting, icterus

and pigmenturia. Blood examination at the referring veterinarian revealed a regenerative anemia with a hematocrit of 31%, reticulocytosis of 421 K/ $\mu$ L and hyperbilirubinemia (0.46 mg/dL ref. <0.10 mg/dL). Urinalysis revealed moderate bilirubinuria. One day later, the dog became febrile and the hematocrit decreased to 21%. Blood typing was performed (dog erythrocyte antigen 1.1 positive) and the dog was stabilized with a whole blood transfusion. A Coombs test and rapid osmotic fragility test (ROFT) were positive. Clotting times were normal. Treatment with doxycycline (10 mg/kg SID PO; Ronaxan, Boehringer Ingelheim Animal Health, France) was started while waiting for the results of infectious disease screening because of a travel history to Spain. Thoracic radiographs and abdominal ultrasound did not show any significant abnormalities. Administration of prednisolone (2 mg/kg SID PO; Prednisolone kela, KELA Laboratoria nv, Belgium) was started for non-associated immune-mediated hemolytic anemia. On the fifth day, the hematocrit decreased to 12.5% and the dog was referred.

At presentation at the Small Animal Clinic of Ghent University, the dog was in anemic shock. Crossmatching was performed since the dog received a blood transfusion four days earlier, and a second blood transfusion with packed red blood cells (20 mL/kg over four hours) was started in accordance to these results. Macroscopic auto-agglutination was present. Blood smear revealed spherocytes, but the dog received a blood transfusion three days before. The evolution of the hematocrit from the time of diagnosis at the referring veterinarian until discharge from the University hospital is depicted in Figure 1.

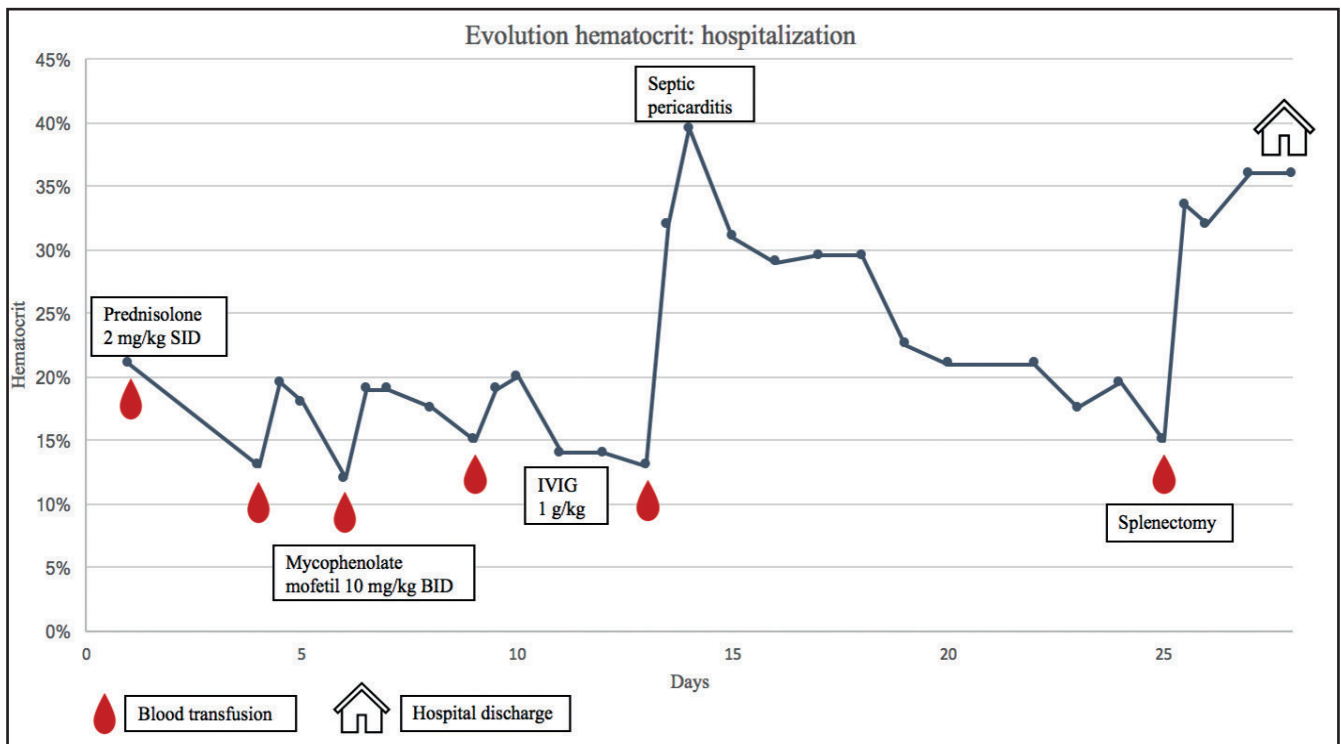


Figure 1. Evolution of the hematocrit from time of diagnosis until discharge. Blood transfusions are indicated with the blood drop symbol. Timepoints of major therapeutic changes are indicated on the timeline.

**Table 1. Infectious disease testing with type of test and results (Idexx).**

Infectious diseases		
Infection	Test	Result
<i>Leishmania</i>	Serology	<400 ref: <800
<i>Anaplasma phagocytophilum, Anaplasma platys</i>	Serology	Negative
<i>Ehrlichia canis, Ehrlichia ewingii</i>	Serology	Negative
<i>Ehrlichia canis</i>	PCR	Negative
<i>Borrelia burchdorferi</i>	Serology	Negative
<i>Dirofilaria immitis</i>	Antigen test	Negative
<i>Babesia spp.</i>	PCR	Negative
<i>Mycoplasma spp.</i>	PCR	Negative

## DIAGNOSIS

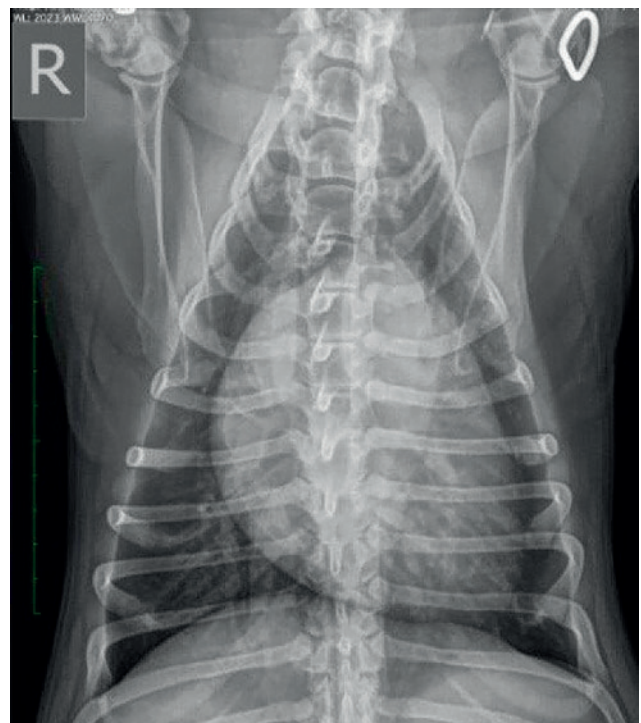
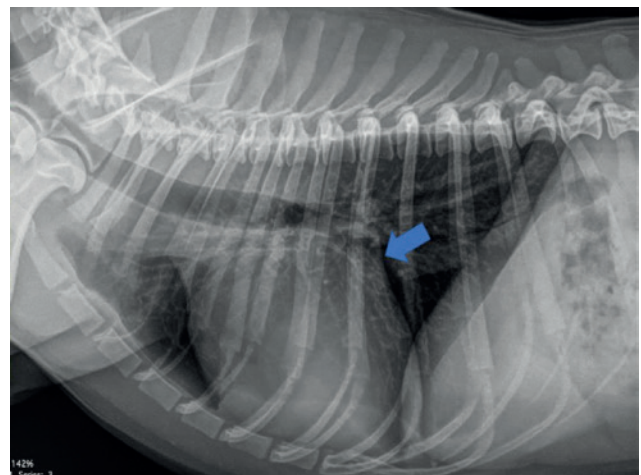
The dog was diagnosed with IMHA as more than one sign of hemolysis (icterus, hyperbilirubinemia, bilirubinuria and hemoglobinemia) and two signs of immune-mediated destruction (positive Coombs test and spherocytosis) were present (Garden et al., 2019). Screening for infectious diseases was negative (Table 1).

To completely exclude other underlying causes for IMHA, an abdominal ultrasound and additional thoracic radiographs were performed. Abdominal ultrasound revealed no abnormalities. Thoracic radiographs showed moderate cardiomegaly and bulging of the left atrium (Figure 2).

Subsequently, echocardiography was performed, which showed a mild volume overload of the left ventricle and borderline low systolic function. The mild echocardiographic abnormalities were supposed to be secondary to the anemia and systemic illness. As no underlying cause for IMHA was found, the dog was diagnosed with non-associated IMHA according to the ACVIM guidelines (Garden et al., 2019).

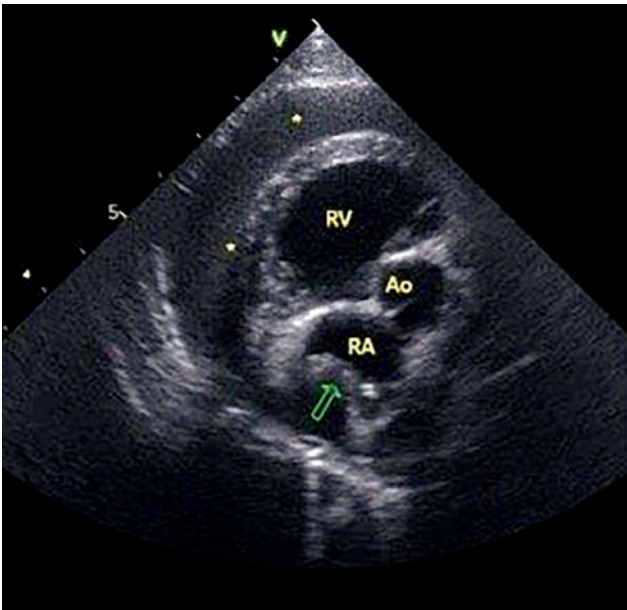
## TREATMENT AND COMPLICATIONS

The dog was hospitalized on the intensive care unit (ICU). Prednisolone (2 mg/kg SID PO) was continued. Thromboprophylaxis was provided with clopidogrel (3.75 mg/kg SID PO; Clopidogrel EG, Eurogenerics, Belgium) and dalteparin (250 IU/kg TID SC; Fragmin, Pfizer, Belgium). Intravenous fluid therapy with Ringers lactate at maintenance rate was given. Multiple blood transfusions were given due to recurrent decompensation (Figure 1). A second immunosuppressant, mycophenolate mofetil (10 mg/kg BID PO; Cellcept, Hoffmann-La Roche AG, United Kingdom), was started according to the ACVIM guidelines since no response to therapy was seen after six days of prednisolone, the need for multiple blood transfusions and because of a drop in hematocrit of more than five

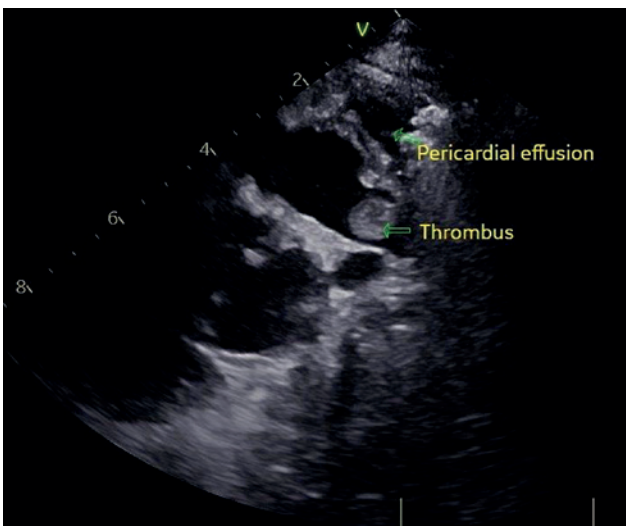


**Figure 2. Thoracic radiographs at admission showing moderate cardiomegaly and bulging of the left atrium (blue arrow).**





**Figure 3.** Echocardiography showing a moderate amount of pericardial effusion (asterisk) and tamponade (green arrow) of the right atrium (RA). RV (right ventricle), Ao (aorta).

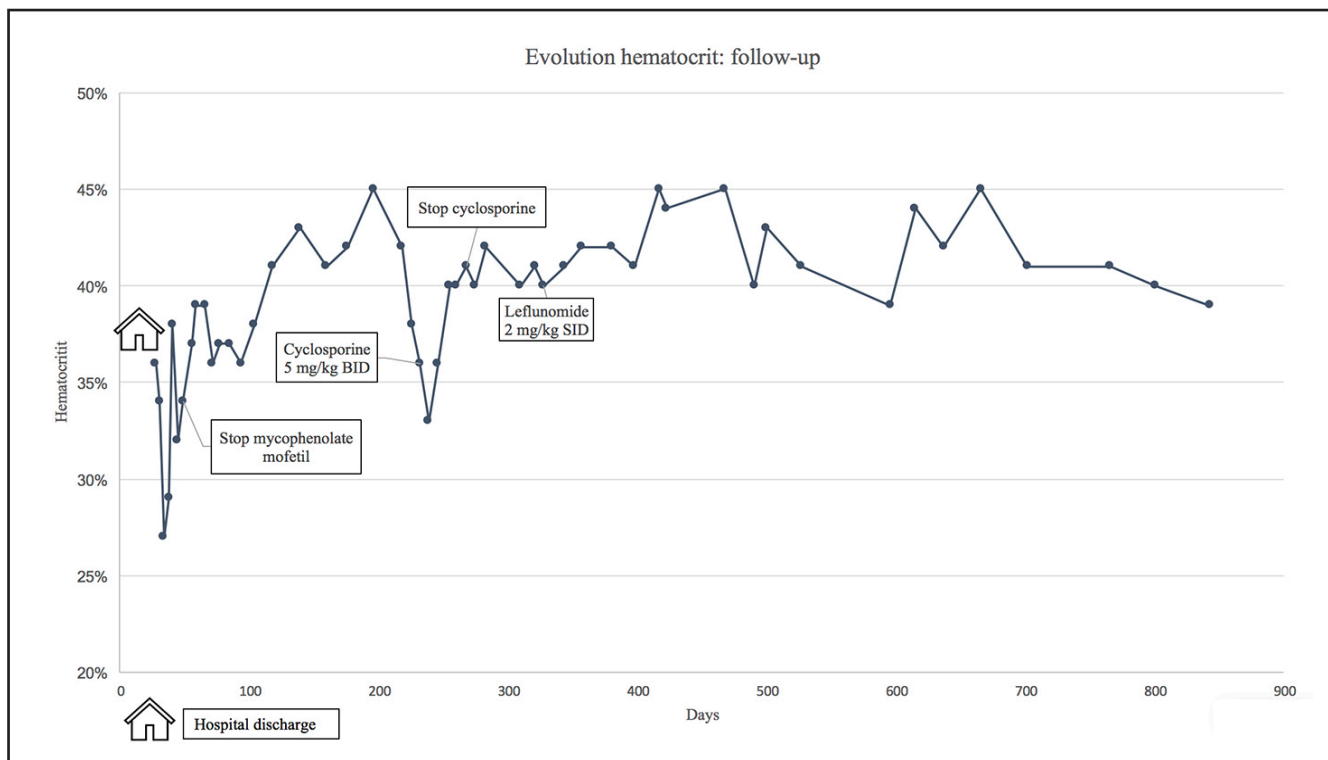


**Figure 4.** Echocardiography showing the thrombus in the right atrium.

percent in 24 hours (Swann et al., 2019). After eleven days of immunosuppressive therapy, human intravenous immunoglobulins (IVIg) (1 g/kg IV; Privigen, CSL Behring GmbH, Germany) were administered over four hours. Following the fifth blood transfusion, there was no clinical improvement despite an increase in hematocrit. The dog had signs of abdominal pain, large bowel diarrhea and showed regurgitation. Analgesia (methadone 0.2 mg/kg q4h IV; Insistor, Richter Pharma, Austria), prokinetics (metoclopramide CRI 2 mg/kg/day; Metomotyl, Le Vet, the Netherlands and erythromycin 1 µg/kg TID IV; Erythrocin, Amdipharm, Ireland) and an antiemetic (maropitant 1 mg/kg SID IV; Cerenia, Zoetis, Belgium) were added to

the treatment. Abdominal ultrasound showed an enlarged, heterogenous pancreas and a mild amount of anechoic abdominal effusion. DGGR lipase was within normal limits (54 U/L ref. <63 U/L). Pericardial effusion was seen while performing the ultrasound of the cranial abdomen. Subsequent echocardiography revealed pericardial effusion causing cardiac tamponade (Figure 3). Pericardiocentesis was performed and 195 mL of purulent pericardial effusion was drained. Cytology showed degenerative neutrophils and intracellular bacteria (gram-positive cocci), which confirmed a septic pericarditis. While waiting for culture and sensitivity results, a bactericidal antibiotic with activity against gram-positive bacteria was started (amoxicillin clavulanic acid 20 mg/kg TID IV; Augmentin, SmithKline Beecham, United Kingdom). The dog developed DIC. This was diagnosed based on mild thrombocytopenia and prolonged clotting times. A fresh frozen plasma transfusion (20 mL/kg over four hours) was started as supportive treatment for DIC. Subsequently, septic shock with hypoglycemia and systemic hypotension developed. A second antibiotic was added to the treatment (enrofloxacin 10 mg/kg SID IV; Floxadil, Animalcare Ltd, United Kingdom). A glucose 5% infusion at maintenance rate was started to resolve severe hypoglycemia. Pimobendan (0.15 mg/kg BID IV; Vetmedin, Boehringer Ingelheim, Germany) and a CRI of dobutamine up to 10 µg/kg/min (Dobutrex mylan, Cenexi, France) were started to improve systolic function and normalize systemic blood pressure.

The pericardial effusion reoccurred within the same day and a pericardial drain (BD Angiocath IV catheter for special placement 14-gauge 133 mm) was placed. An additional 110 mL of pericardial effusion was drained over the next twelve hours (1 mL/kg/h). The pericardium was flushed three times a day with diluted heparin solution. Sedation to restrain the dog and keep the pericardial drain in place, and analgesia were achieved with a CRI of fentanyl up to 7 µg/kg/h (Fentadon, Dechra, the Netherlands), a CRI of lidocaine up to 60 µg/kg/min (Xylocaine, Recipharm, France) and paracetamol (15 mg/kg BID IV; Paracetamol, Fresenius Kabi, Germany). Dosages of prednisolone and mycophenolate mofetil were halved for three days. A central venous line (jugular vein) and arterial catheter (dorsal pedal artery) were placed to prevent overinfusion and for monitoring of the venous and arterial blood pressure. The dog improved clinically. After 48 hours, the pericardial drain was removed as it was minimally productive (<0.5 mL/kg/h). Cytology showed degenerative neutrophils, but was free of bacteria. The culture of the pericardial effusion came back positive for a multiresistant *Staphylococcus pseudintermedius* (MRSP), which is a bacteria resistant to all commonly used veterinary antibiotics. However, since the dog responded clinically very well to amoxicillin clavulanic acid and enrofloxacin, antibiotic therapy was kept unchanged. Enrofloxacin was



**Figure 5. Evolution of the hematocrit from the time of discharge from the University Hospital until the time of writing. Timepoints of major therapeutic changes are indicated on the timeline.**

stopped after two weeks and amoxicillin clavulanic acid was given for a total of two months.

After resolution of the septic pericarditis and two weeks after IVIG administration, the hematocrit decreased again. A splenectomy was advised. Thromboprophylactic treatment was stopped two days preoperatively. Clotting times, platelet count and buccal mucosal bleeding time (BMBT) were normal before surgery. After a sixth blood transfusion, splenectomy was performed without complications.

Preanesthetic control echocardiography showed a thrombus in the right atrium (Figure 4). Thromboprophylaxis with dalteparin was changed to rivaroxaban (1 mg/kg SID PO; Xarelto, Bayer AG, Germany) post-surgery, and clopidogrel was restarted. The dog recovered well from surgery and was discharged three days postoperative with a stable hematocrit. After 24 days of hospitalization, the dog went home with the following therapy; prednisolone 2 mg/kg SID PO, mycophenolate mofetil 10 mg/kg BID PO, rivaroxaban 1 mg/kg SID PO, clopidogrel 3.75 mg/kg SID PO, amoxicillin clavulanic acid 20 mg/kg BID PO and paracetamol 10 mg/kg TID PO.

## FOLLOW-UP

Follow-up echocardiography showed complete resolution of the thrombus in the right atrium one week after discharge. Ten months after the septic pericarditis, no signs of constrictive pericarditis were seen on echocardiography.

The evolution of the hematocrit from the time of

discharge from the hospital until the time of writing is shown in Figure 5. Mycophenolate mofetil was tapered and stopped after several weeks. Due to two relapses of IMHA, immunosuppressive treatment was adapted. Cyclosporine (5 mg/kg BID PO; Cycloavance, Virbac, France) was added as second immunosuppressant after the first relapse and after the second relapse, it was replaced by leflunomide (2 mg/kg SID PO; Leflunomide Sandoz, Haupt Pharma Münster GmbH, Germany). Prednisolone was tapered gradually. The owner was reluctant to stop prednisolone completely, physiologic doses of prednisolone were continued (0.1 mg/kg EOD). Thromboprophylaxis was stopped when prednisolone was tapered to physiologic doses. Almost 2.5 years after presentation, leflunomide was tapered and will hopefully be discontinued in the future.

## DISCUSSION

In this case report, the successful management of a dog with refractory non-associated immune-mediated hemolytic anemia with severe complications is described.

Immunosuppressive treatment with glucocorticoids was started as first-line therapy for IMHA. In a high proportion of cases, this leads to disease control (Swann and Skelly, 2013; Goggs, 2020). Azathioprine, cyclosporine and mycophenolate mofetil are frequently used in IMHA as a second immunosuppressant, but no consensus exists on which of these

drugs leads to better disease control (Swann et al., 2019). The use of leflunomide has been described in refractory immune-mediated diseases, but is used infrequently and the efficacy is less well-known (Bianco and Hardy, 2009; Colopy et al. 2010; Sato et al., 2017). In the present case, leflunomide led to long-term control of IMHA without relapses. Although some dogs need lifelong therapy to prevent relapses (Swann et al., 2019), the goal of the present case was to attempt discontinuation of all immunosuppressive therapy if possible. In relapse cases, good quality of life on lower dosages of immunosuppressive medication can be expected.

The recommendations of the ACVIM consensus statement were followed and human intravenous immunoglobulins were administered as the dog was unresponsive to treatment with two immunosuppressive drugs (Grundy and Barton, 2001; Whelan et al., 2009; Swann and Skelly, 2016; Swann et al., 2019). IVIG blocks the fragment crystallizable (Fc) receptor on phagocytic cells, so that these cells cannot interact with the Fc region of the autoantibody coated erythrocytes. The onset of action is rapid and IVIG is probably most useful for short-term improvement in the acute hemolytic crisis (Scott-Moncrieff et al., 1997). In the study of Kellerman and Bruyette (1997), a very good response rate of 85% was seen in contrast to the study of Whelan et al. (2009) where there was no difference compared to only-prednisolone treatment. In the first study, IVIG was only administered to dogs with IMHA not responsive to prednisolone after seven days such as in the current case, while in the second study, IVIG was part of the initial treatment protocol. Probably, IVIG is only of benefit in certain IMHA cases. In the patient of the current case report, IVIG administration led to a prolongation of the blood transfusion interval. Due to the inconsistent proof of efficacy, possible hypersensitivity reactions, limited availability and costs, IVIG is currently reserved for refractory cases.

Splenectomy remains a salvage procedure for canine IMHA (Horgan et al., 2009), despite being a well-recognized treatment for IMHA in human medicine. Before performing splenectomy in an immunosuppressed patient, infectious disease testing should be negative. Clinical disease caused by vector-borne infections, such as *Mycoplasma haemocanis* or *Babesia gibsoni*, can be triggered by splenectomy (Kemming et al. 2004; Trotta et al. 2009; Swann et al., 2019). The ACVIM consensus statement recommends tapering or discontinuing immunosuppressive and antithrombotic drugs prior to surgery (Swann et al., 2019). In the present case, thromboprophylactic treatment was stopped two days before surgery. Thrombocytes, clotting times and BMBT were normal preoperatively. Therefore, the risk of bleeding was considered minimal. Blood products were available if necessary. The risk of infection due to surgery in this immunosuppressed patient was considered minimal as splenec-

tomy is a fast and non-contaminated procedure. At the moment of surgery, the patient was still receiving antibiotics for the septic pericarditis.

In a study by Horgan et al. (2009), ten dogs with IMHA that underwent splenectomy, had an increase in hematocrit three days post-surgery and needed less frequent blood transfusions post-surgery. In another study, four out of seven dogs with IMHA had a partial or complete response to treatment after splenectomy (Bestwick et al., 2022). These outcomes could have been influenced by response to the immunosuppressive therapy since most dogs in both studies were treated in the acute phase of IMHA. The dog in the present case had already been medically treated for 25 days, so the stable hematocrit after splenectomy was unlikely to be due to the medical treatment alone. Recently, it has been shown that splenectomy can also be beneficial in dogs with non-regenerative IMHA (Morishita et al., 2022).

Opportunistic infections can emerge during immunosuppressive therapy, especially if multiple drugs are used (Swann et al., 2009). The first clinical sign of septic pericarditis in this patient was acute abdominal pain. In human medicine, rarely, purulent pericarditis can unexpectedly present as an acute abdomen in children (Donnelly et al., 1999).

A few reports of septic pericarditis in dogs have been described. Most cases are caused by bite wounds, migrating foreign bodies, postoperative infections and systemic infections (Fuentes et al., 1991; Aronson and Gregory, 1995; Casamián-Sorrosal et al., 2008; Veloso et al., 2014; Sheehan et al., 2019; Brincin et al., 2022). Only two cases of septic pericarditis in immunosuppressed dogs have been described. In a study by Mohri et al. (2009), a dog with IMHA treated with multiple immunosuppressive drugs developed septic pericarditis with cardiac tamponade after 5.5 weeks. At that point, pericardiocentesis was performed, but the dog died of multi-organ failure the next day. In a study by Pascutti et al. (2022), a dog treated with immunosuppressive doses of prednisolone for inflammatory bowel disease and oclacitinib for atopy, was surgically treated for septic pericarditis. Independent of the underlying cause, almost all cases with a good outcome were treated surgically with pericardiectomy (Aronson and Gregory, 1995; Casamián-Sorrosal et al., 2008; Veloso et al., 2014; Sheehan et al., 2019; Pascutti et al., 2022). To the authors' knowledge, the dog in this case report is the first dog that has successfully been managed with medical treatment consisting of pericardiocentesis, antibiotics and placement of a pericardial drain. Pericardial catheter placement has been previously described as a safe procedure to avoid repeated pericardiocentesis (Cook et al., 2019; Cook et al., 2021).

Constrictive pericarditis is a possible complication of infectious pericarditis in veterinary and human medicine (Thomas et al., 1984; Farhat et al., 2003; Ariki and Bandou, 2009). Bacterial pericarditis pro-



gresses to constrictive pericarditis in 20% to 33% of human patients (Tseng et al., 2010; Latif et al., 2020), but early drainage of purulent pericardial effusion can possibly prevent its development (Latif et al. 2020). Follow-up echocardiography did not show signs of constrictive pericarditis in this dog.

As a conclusion, firstly, with this case report, the authors wanted to illustrate how refractory and complicated cases of non-associated IMHA can successfully be managed in an ICU setting. Secondly, the authors wanted to show that septic pericarditis can be a rare, but serious complication in immunosuppressed dogs. Finally, in this case report, non-surgical management of septic pericarditis is supported. Owner motivation made prolonged treatment of this patient possible. During the intensive phase in the treatment of this dog, quality of life and the possibility of a good long-term outcome remained a priority.

## REFERENCES

- Ariki H., Bandou K. (2009). Pyopericardium followed by acute progression of constrictive pericarditis. *The Japanese Journal of Thoracic Surgery* 62(2), 133-135.
- Aronson L.R., Gregory C.R. (1995). Infectious pericardial effusion in five dogs. *Veterinary Surgery* 24(5), 402-407.
- Bestwick J.P., Skelly B.J., Swann J.W., Glanemann B., Bexfield N., Gkoka Z., Warland J. (2022). Splenectomy in the management of primary immune-mediated hemolytic anemia and primary immune-mediated thrombocytopenia in dogs. *Journal of veterinary internal medicine* 36(4), 1267-1280.
- Bianco D., Hardy R.M. (2009). Treatment of Evans' syndrome with human intravenous immunoglobulin and leflunomide in a diabetic dog. *Journal of the American Animal Hospital Association* 45(3), 147-150.
- Brincin C., Ryan T., Harris K. (2022). Gastroesophageal intussusception secondary to induction of emesis with subsequent development of septic pericardial effusion after corrective surgery. *Journal of Small Animal Practice* 63(1), 72-77.
- Carr A.P., Panciera D.L., Kidd L. (2002). Prognostic factors for mortality and thromboembolism in canine immune-mediated hemolytic anemia: a retrospective study of 72 dogs. *Journal of Veterinary Internal Medicine* 16, 504-509.
- Casamián-Sorrosal D., Fournier D., Shippam J., Woodward B., Tennant K. (2008). Septic pericardial effusion associated with pulmonary and pericardial botryomycosis in a dog. *Journal of Small Animal Practice* 49(12), 655-659.
- Colopy S.A., Baker T.A., Muir P. (2010). Efficacy of leflunomide for treatment of immune-mediated polyarthritis in dogs: 14 cases (2006–2008). *Journal of the American Veterinary Medical Association* 236(3), 312-318.
- Cook S., Cortellini S., Humm K. (2019). Retrospective evaluation of pericardial catheter placement in the management of pericardial effusion in dogs (2007–2015): 18 cases. *Journal of Veterinary Emergency and Critical Care* 29(4), 413-417.
- Cook S., Cortellini S., Humm K. (2021). Prospective evaluation of pericardial catheter placement versus needle pericardiocentesis in the management of canine pericardial effusion. *Journal of Veterinary Emergency and Critical Care* 31(1), 11-17.
- Donnelly L.F., Kimball T.R., Barr L.L. (1999). Purulent pericarditis presenting as acute abdomen in children: abdominal imaging findings. *Clinical Radiology* 54(10), 691-693.
- Farhat F., Dubreuil O., Durand P.G., Jegaden O. (2003). Constrictive pericarditis following a pyopericardium due to *Staphylococcus aureus*. *Interactive Cardiovascular and Thoracic Surgery* 2(4), 626-628.
- Fuentes V.L., Long K.J., Darke P.G.G., Burnie A.G. (1991). Purulent pericarditis in a puppy. *Journal of Small Animal Practice* 32(11), 585-588.
- Garden O.A., Kidd L., Mexas A.M., Chang Y.M., Jeffery U., Blois S.L., Szladovits B. (2019). ACVIM consensus statement on the diagnosis of immune-mediated hemolytic anemia in dogs and cats. *Journal of Veterinary Internal Medicine* 33(2), 313-334.
- Goggs R. (2020). Therapeutic strategies for treatment of immune-mediated hemolytic anemia. *Veterinary Clinics: Small Animal Practice* 50(6), 1327-1349.
- Grundy S.A., Barton C. (2001). Influence of drug treatment on survival of dogs with immune-mediated hemolytic anemia: 88 cases (1989–1999). *Journal of the American Veterinary Medical Association* 218(4), 543-546.
- High E.J., Olivry T. (2020). The prevalence of bacterial infections during cyclosporine therapy in dogs: A critically appraised topic. *The Canadian Veterinary Journal* 61(12), 1283.
- Horgan J.E., Roberts B.K., Schermerhorn T. (2009). Splenectomy as an adjunctive treatment for dogs with immune-mediated hemolytic anemia: ten cases (2003–2006). *Journal of Veterinary Emergency and Critical Care* 19(3), 254-261.
- Kellerman D.L., Bruyette D.S. (1997). Intravenous human immunoglobulin for the treatment of immune-mediated hemolytic anemia in 13 dogs. *Journal of Veterinary Internal Medicine* 11(6), 327-332.
- Kemming G., Messick J.B., Mueller W., Enders G., Meisner F., Muenzing, S., Thein, E. (2004). Can we continue research in splenectomized dogs? *Mycoplasma haemocanis*: old problem–new insight. *European Surgical Research* 36(4), 198-205.
- Kidd L., Mackman N. (2013). Prothrombotic mechanisms and anticoagulant therapy in dogs with immune-mediated hemolytic anemia. *Journal of Veterinary Emergency and Critical Care* 23(1), 3-13.
- Latif A., Patel A.D., Mahfood Haddad T., Lokhande C., Del Core M., Esterbrooks, D. (2020). Massive purulent pericarditis presenting as cardiac tamponade. *Baylor University Medical Center Proceedings* 33(4), 662-663.
- Mohri T., Takashima K., Yamane T., Sato H., Yamane Y. (2009). Purulent pericarditis in a dog administered immune-suppressing drugs. *Journal of Veterinary Medical Science* 71(5), 669-672.
- Morishita K., Sugawara M., Yamazaki J., Kim S., Hosoya K., Sasaki N., Takiguchi M. (2022). Evaluation of the therapeutic efficacy of splenectomy in 20 dogs with non-regenerative immune-mediated anemia. In: *Proceedings of the ACVIM forum 2022*, June 23-25, Austin, Texas.
- Pascutti K.M., Dolan J.K., Porter L.T., Gilor S., Harris A.N. (2022). Case Report: Septic pericarditis with *Achromobacter xyloxidans* in an immunosuppressed dog. *Frontiers in Veterinary Science* 9, 1-6.
- Sato M., Veir J.K., Legare M., Lappin M.R. (2017). A retro-

- spective study on the safety and efficacy of leflunomide in dogs. *Journal of Veterinary Internal Medicine* 31(5), 1502-1507.
- Scott-Moncrieff J.C., Reagan W.J., Snyder P.W., Glickman L.T. (1997). Intravenous administration of human immune globulin in dogs with immune-mediated hemolytic anemia. *Journal of the American Veterinary Medical Association* 210(11), 1623-1627.
- Sheehan N.K., Kelliher H.B., Yarnall B., Graham M., Moore F. (2019). Septic pericarditis and pericardial abscess secondary to a migrating foreign body in a dog. *Journal of Veterinary Cardiology* 23, 122-128.
- Swann J.W., Skelly B.J. (2013). Systematic review of evidence relating to the treatment of immune-mediated hemolytic anemia in dogs. *Journal of Veterinary Internal Medicine* 27(1), 1-9.
- Swann J.W., Skelly B.J. (2016). Canine autoimmune hemolytic anemia: management challenges. *Veterinary Medicine: Research and Reports* 7, 101.
- Swann J.W., Garden O.A., Fellman C.L., Glanemann B., Goggs R., LeVine D.N., Whitley N.T. (2019). ACVIM consensus statement on the treatment of immune-mediated hemolytic anemia in dogs. *Journal of Veterinary Internal Medicine* 33(3), 1141-1172.
- Thomas W.P., Reed J.R., Bauer T.G., Breznock E.M. (1984). Constrictive pericardial disease in the dog. *Journal of the American Veterinary Medical Association* 184(5), 546-553.
- Trotta M., Carli E., Novari G., Furlanello T., Solano-Gallego L. (2009). Clinicopathological findings, molecular detection and characterization of *Babesia gibsoni* infection in a sick dog from Italy. *Veterinary Parasitology* 165(3-4), 318-322.
- Tseng J.R., Lee M.J., Lin J.L., Yen T.H. (2010). Definite and probable septic pericarditis in hemodialysis. *Renal Failure* 32(10), 1177-1182.
- Veloso G.F., Manteiga E.F., Trehy M., Freeman A., McConnell J.F., McEwan J.D. (2014). Septic pericarditis and myocardial abscess in an English Springer spaniel. *Journal of Veterinary Cardiology* 16(1), 39-44.
- Weinkle T.K., Center S.A., Randolph J.F., Warner K.L., Barr S.C., Erb H.N. (2005). Evaluation of prognostic factors, survival rates, and treatment protocols for immune-mediated hemolytic anemia in dogs: 151 cases (1993–2002). *Journal of the American Veterinary Medical Association* 226(11), 1869-1880.
- Whelan M.F., O'Toole T.E., Chan D.L., Rozanski E.A., DeLaforcade A.M., Crawford S.L., Cotter S.M. (2009). Use of human immunoglobulin in addition to glucocorticoids for the initial treatment of dogs with immune-mediated hemolytic anemia. *Journal of Veterinary Emergency and Critical Care* 19(2), 158-164.



© 2023 by the authors. Licensee Vlaams Diergeneeskundig Tijdschrift, Ghent University, Belgium. This article is an open access article distributed under the terms and conditions of

the Creative Commons Attribution (CC BY) license (<http://creativecommons.org/licenses/by/4.0/>).