

Immune-mediated hemolytic anemia (IMHA) in cats - part 2: case report

Immuungemedieerde hemolytische anemie bij katten - deel 2: een klinisch geval

¹G. Paes, ¹J. Veldeman, ¹D. Paepe, ²J. Saunders, ¹S. Daminet

¹Department of Small Animal Medicine and Clinical Biology

² Department of Veterinary Medical Imaging and Small Animal Orthopedics,
Faculty of Veterinary Medicine, Ghent University,
Salisburylaan 133, B-9820, Merelbeke, Belgium

geert.paes@ugent.com

ABSTRACT

A two-year-old male domestic shorthair cat was referred to the Department of Small Animal Medicine and Clinical Biology at the Ghent University, Faculty of Veterinary Medicine, Merelbeke, Belgium because of lethargy and anorexia. The cat had severe non-regenerative anemia and marked lymphocytosis. Primary non-regenerative immune-mediated hemolytic anemia was diagnosed on the basis of severe hemolytic anemia in combination with a positive osmotic fragility test, a positive Coombs test and the exclusion of underlying causes. A bone marrow core biopsy revealed erythroid maturation arrest with mild myelodysplasia. The cat responded quickly to treatment with a blood transfusion and immunosuppressive dosages of prednisolone. The prednisolone was tapered down and stopped after 5 months. Two years after the initial diagnosis, there were no signs of clinical relapse.

SAMENVATTING

Een twee jaar oude kater werd doorverwezen naar de vakgroep Geneeskunde en Klinische Biologie van de Kleine Huisdieren van de Faculteit Diergeneeskunde in Merelbeke, België omwille van lethargie en anorexia. De kat had een uitgesproken niet-regeneratieve anemie en lymfocytose. De diagnose van niet-regeneratieve primaire immuungemedieerde hemolytische anemie werd gesteld op basis van de aanwezigheid van hemolytische anemie in combinatie met een positieve osmotische fragiliteitstest, een positieve coombstest en de uitsluiting van onderliggende oorzaken. Het onderzoek van een beenmergbiopsie wees op een maturatiestop van de rode bloedcellen en op milde myelodysplasie. De kat reageerde zeer snel op de behandeling met een bloedtransfusie en prednisolone aan een immunosuppressieve dosis. De prednisolone werd afgebouwd en stopgezet na 5 maanden. Twee jaar na het stellen van de diagnose vertoonde de kat geen tekenen van klinisch recidief.

INTRODUCTION

Immune-mediated hemolytic anemia (IMHA) is rarely seen in cats, and in the majority of cases the disease occurs secondary to an underlying infectious, neoplastic or inflammatory condition (McCullough, 2003). The diagnosis of primary IMHA is made when immune-mediated red blood cell (RBC) destruction is present in the absence of an underlying cause (Kohn *et al.*, 2006).

In more than half (58%) of cats with IMHA, non-regenerative anemia is seen, which can be a consequence of the acute onset of the disease, because 3 to 5 days are required to develop a substantial reticulocyte response (Kohn *et al.*, 2006; Weis, 2008). When signs of regeneration are still absent 5 days after the onset of the anemia, bone marrow should be examined to determine whether the animal has erythroid maturation arrest, which would suggest the immune-mediated destruction of erythroid precursors or erythroid hyper-

plasia. A higher mortality rate is seen in cats with non-regenerative IMHA and bone marrow erythroid hyperplasia than in those with erythroid maturation arrest or with pure red cell aplasia (Weis, 2008).

This case report describes a young male cat with non-regenerative primary IMHA and bone marrow erythroid maturation arrest with mild myelodysplasia.

CASE REPORT

A two-year-old male, castrated domestic shorthair cat with a body weight of 3.8 kg was presented at the Department of Small Animal Internal Medicine of the Ghent University Faculty of Veterinary Medicine because of a 5-day history of lethargy and anorexia. One week before presentation, the cat had an episode of diarrhea which had resolved without treatment. Otherwise, the cat had no medical history. The cat was kept indoors, with limited outdoor access. It had regularly, though not recently, been vaccinated against feline

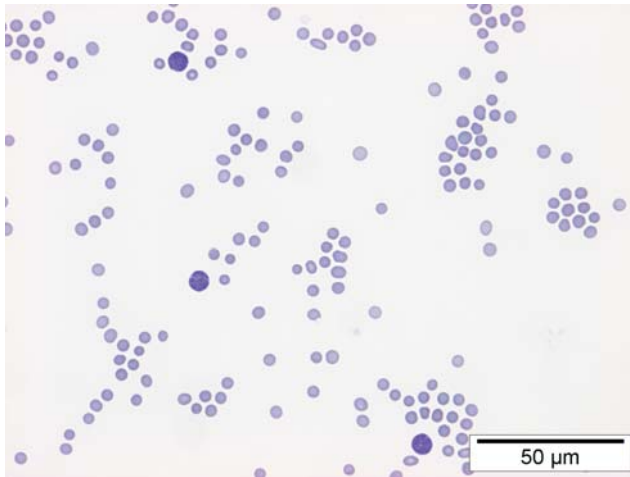


Figure 1. Blood smear with a low cellularity. Furthermore, mild erythrocyte anisocytosis and polychromasia and an increased number of lymphocytes can be seen (HE, 60x).




Figure 2. A positive osmotic fragility test with a red supernatant (due to hemolysis) in 0.62% NaCl and with a colorless supernatant in 0.9% NaCl.

calicivirus, feline panleukopenia virus and feline herpes virus type I and was being fed a commercial feline diet.

The referring veterinarian had performed a complete blood count one day earlier which showed severe, non-regenerative anemia, severe lymphocytosis and mild thrombocytopenia. The cat was referred to perform further tests.

On physical examination, the cat was lethargic, had severely pale mucous membranes, tachycardia (heart rate of 212 beats/min) with strong femoral pulse quality, and a rectal temperature of 37.7°C. Other findings were unremarkable. Pale mucous membranes can be a result of shock or anemia. Tachycardia can be a result of anemia, hypoxia, hypovolemia, hypotension, pain, fever or stress. In this cat the severe anemia, detected on CBC by the referring veterinarian, was assumed to be the cause of the pale mucous membranes and the tachycardia. A serum biochemistry profile and urine analysis were performed and the CBC was repeated to evaluate

Table 1. Results of complete blood count on the day of submission.

		Reference range
Hct (%)	7.1	24-45
MCV (fl)	39.8	37-55
MCH (pg)	14	12-18
MCHC (g/dL)	35.1	30-36
Leucocytes (/μL)	16710	5000-15000
Band neutrophils (/μL)	0	< 550
Segmented neutrophils (/μL)	3175	3600-10500
Lymphocytes (/μL)	11363	900-4200
Monocytes (/μL)	1838	<550
Basophils (/μL)	0	0-80
Eosinophils (/μL)	334	<800
Platelets (/μL)	111900	175000-500000
Reticulocytes (%)	0.004	<0.013

the packed cell volume (PCV) and to determine whether the anemia had become regenerative or not. The results of the CBC are presented in Table 1. On the serum biochemistry profile, the only abnormality was hyperbilirubinemia (total bilirubin 17.4 μmol/L {reference range < 6.8 μmol/L}). On urine analysis, bilirubinuria was present. A commercially available ELISA test (SNAP™ Combo Plus) was negative for FIV antibodies and FeLV antigen.

On a blood smear (Figure 1), a sufficient number of platelets (more than 10 platelets per oil immersion field (100x)) was present. The erythrocytes showed mild anisocytosis and mild polychromasia. Furthermore, a markedly increased number of reactive lymphocytes were seen.

The cat received oxygen and blood typing was performed. A total of 60 mL fresh whole blood (type A blood) was immediately transfused at a rate of 10 mL/kg/h. Furthermore, the cat was warmed with an infrared light.

Considering the severe anemia with marked hyperbilirubinemia and the absence of other abnormalities on blood and urine analysis, the cat was suspected of having hemolytic anemia. The important differentials for hemolysis in this cat were the immune-mediated destruction of RBCs (primary or secondary), hereditary erythrocyte membrane defects, infectious causes (*Mycoplasma M. hemofelis*, *Babesia felis*) and intoxication (lead, acetaminophen or methylene blue). Additional laboratory tests to detect the cause of hemolysis were carried out. The autoagglutination test, performed by mixing 5 drops of 0.9% NaCl with 1 drop of the patient's blood on a smear slide, was negative. The RBC osmotic fragility test was carried out by adding 5 drops of blood to each of two tubes containing 5 mL of a 0.62% and a 0.9% NaCl solution, respectively. After standing at room temperature for 5 minutes, the two tubes were centrifuged at 3500 rpm for 5 minutes. The osmotic fragility (OF) test was positive, because the supernatant of the 0.62% NaCl solution was red, in contrast to the colorless supernatant of the 0.9% NaCl solution (Figure 2). A Coombs test was performed by

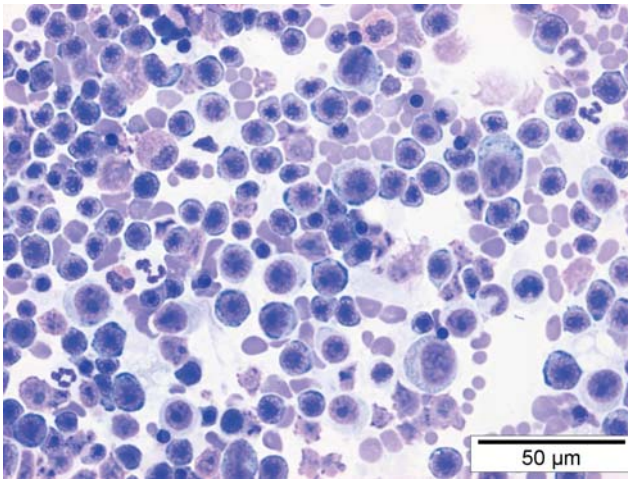


Figure 3. Cytology of a bone marrow aspirate showing erythroid series cells at all stages of maturation into the metarubricyte stage and a moderate amount of small mature lymphocytes (HE, 60x).

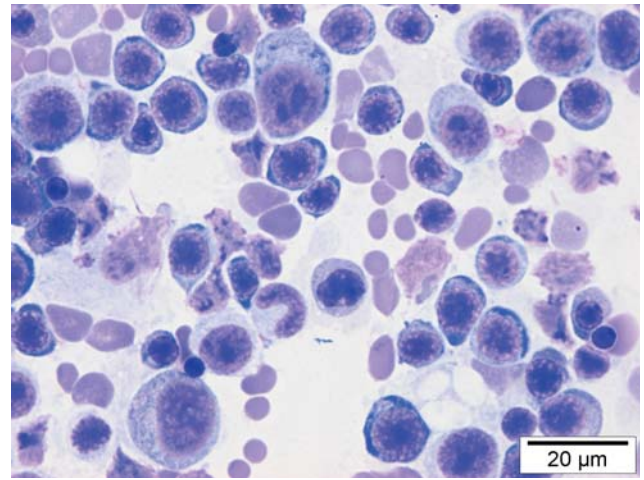


Figure 4. Cytology of a bone marrow aspirate showing predominantly erythroid series cells at different stages of maturation into the metarubricyte stage and few myeloid series cells at the early blast and promyelocyte stages (HE, 100x).

using two 96 well HTS microplates containing anti-feline globulin IgG and IgM in the gel matrix, one at 37° and one at 4 °C The coombs' test was positive at 37°C.

Immune-mediated hemolytic anemia (IMHA) was diagnosed on the basis of the combination of severe hemolytic anemia, the positive OF test and the positive Coombs test.

After the transfusion, the PCV increased to 12.5% and the clinical status of the cat improved, which made it possible to perform additional diagnostic tests to detect the possible underlying cause of the IMHA. Thoracic radiography and abdominal ultrasonography revealed no abnormalities. Because the anemia was non-regenerative and clinical symptoms had already been present for up to 5 days (erythrocyte regeneration is expected after 3 to 5 days), a bone marrow core biopsy was taken and cytology and histopathology were performed. The cat was anesthetized using methadone (0.1 mg/kg) as premedication and propofol (6 mg/kg) as induction and maintenance. The bone marrow was aspirated with an 18G needle (Spinocan®). Bone marrow cytology and histopathology revealed moderate hypercellularity and a moderate amount of small lymphocytes with normal morphologic features. Scattered megakaryocytes were found. Erythroid series cells were present at all stages of maturation into the metarubricyte stage, and myeloid series cells were observed mostly at the early blast and promyelocyte stages, suggesting a maturation arrest in both cell lines (Figures 3 and 4). Furthermore, a mild myelodysplasia was considered to be present, based upon the presence of megaloblasts. An aliquot of the bone marrow was used to perform PCR assays for FeLV, *Mycoplasma hemofelis*, *Candidatus mycoplasma hemominutum* and *Candidatus mycoplasma turicensis*. All PCR assays were performed in the 'Laboratoire d'analyses vétérinaires', Scanelis, France and were negative.

By exclusion of other causes, a primary non-regenerative IMHA was suspected in this cat and treatment with immunosuppressive dosages of corticosteroids

(prednisolone, 1 mg/kg twice daily) was started. Additional therapy included infusion of crystalloids (NaCl 0.9% solution, 50 mL/kg/24h) and prophylactic IV administration of a histamine blocker (ranitidine, 2 mg/kg twice daily). The PCV continued to improve and returned to reference ranges 13 days after the initial diagnosis. The PCV was checked two weeks thereafter and was still within reference ranges. At that time, the dosage of prednisolone was decreased to 0.75 mg/kg twice daily. Subsequently, a blood sample for hematology was taken monthly and the dosage of prednisolone was tapered down by 25% each month. The lymphocyte counts remained high and were still slightly above reference ranges (4500/µL {reference range 900 to 4200/µL}) when a last blood sample was taken, 5 months after the initial diagnosis. At that moment, the PCV was 42% and the cat was doing well clinically, while receiving prednisolone at 0.5 mg/kg once daily, every other day. Therapy with prednisolone was stopped. Two years after diagnosis, the cat was still clinically healthy.

DISCUSSION

In the reported case, the diagnosis of primary non-regenerative IMHA was based upon the evidence of hemolysis, the evidence of immune-mediated RBC destruction (positive Coombs' test and positive OF test), the exclusion of underlying causes and its good response to immunosuppressive corticosteroid treatment. Only when, despite extensive investigation, no underlying cause for the immune-mediated destruction of the RBC's can be identified, is a diagnosis of primary IMHA made. However, in patients with primary IMHA the possibility cannot be completely excluded that there might have been a trigger to the immune-mediated RBC destruction, as the trigger might have disappeared already.

The autoagglutination test was negative, suggesting that the IMHA in this case was probably caused by the

presence of warm-type IgG antibodies, which may dissolve after the addition of NaCl solution (Slappendel, 1986).

While in the majority of dogs IMHA is primary, this condition is only rarely seen in cats (McCullough, 2003). In contrast to IMHA dogs, which are most often presented with a regenerative anemia, the majority of cats have a non-regenerative anemia, which was also seen in this case (Reimer *et al.*, 1999; Kohn *et al.*, 2006). On bone marrow cytology and histopathology an erythroid maturation arrest and mild myelodysplasia were present. Furthermore, a moderate lymphocyte hyperplasia was seen, which has been reported to be present in the bone marrow of 86% of cats with IMHA (Weiss, 2008). Erythroid maturation arrest may result from immune-mediated destruction of erythroid precursor cells within the bone marrow (Weiss, 1986). Myelodysplasia has been associated with the production of defective RBCs that have a higher rate of apoptosis (Weiss and Aird, 2001). Therefore, the non-regenerative character of the anemia in this cat was likely a consequence both of the immune-mediated destruction of RBC precursors and ineffective erythropoiesis.

The clinical presentation of the cat in this report is in agreement with what has been reported in the literature (Kohn, 2006). The cat was presented with non-specific symptoms of anorexia and lethargy, and physical examination revealed abnormalities such as pale mucous membranes, tachycardia and strong femoral pulses, all of which are consequences of severe anemia.

The laboratory abnormalities (severe anemia, mild thrombocytopenia, marked lymphocytosis, hyperbilirubinemia) seen in this cat have all been reported in cats with IMHA. The mild thrombocytopenia in this cat was due to a 'pseudothrombocytopenia'. Feline platelet concentrations are often falsely decreased because of platelet clumping when automated hematology analyzers are used. Furthermore, automated cell counters that have a threshold function to separate platelets and RBCs by volume are often inaccurate when used with cats, because a considerable overlap exists between platelet and RBC volumes in this species. Because of this, counting the number of platelets on a blood smear is always necessary for cats in which the automated platelet count is low. Ten to 20 platelets per oil immersion field (100x) are considered adequate (Callan, 2010). A marked lymphocytosis was seen in the cat of this report and has been reported to be present on the CBC of 32% of cats with primary IMHA (McManus *et al.*, 2001; Kohn *et al.*, 2006). It is remarkable that the lymphocyte counts remained high even after 5 months of treatment, while the PCV was within reference ranges. Husbands *et al.* (2002) reported a lymphocytosis that persisted in 2 of the 25 cats with primary IMHA, and that recurred with a relapse of anemia despite prednisolone therapy in 3 of the 25 cats. It is unclear why the lymphocyte counts remained persistently high in these cases. A possible explanation is chronic antigenic stimulation despite corticosteroid treatment.

The cat in this report only required one blood transfusion. Although the PCV after blood transfusion

was only 12.5%, the clinical signs of anemia, such as tachycardia and tachypnea, had resolved. Furthermore, the cat was bright and alert and it was considered safe to anesthetize the cat to perform a bone marrow aspiration. A combination of opioids (premedication) and propofol (induction and maintenance), was chosen because of the minimal cardiovascular side effects of these drugs. In the present case, PCR for hemotropic mycoplasma species was performed on bone marrow. In cases where bone marrow is not aspirated, the PCR assay can be performed on whole uncentrifuged blood on EDTA.

The cat in this report responded quickly to treatment with a rather low dosage of prednisolone. In the study of Kohn *et al.* (2006), the majority of cats (85%) required more than 14 days before the PCV returned to normal, while in this cat PCV was within reference ranges after 13 days of treatment.

As described in the literature, the dosage of prednisolone was slowly tapered down over a 5-month period. Two years after the initial diagnosis the cat was still clinically healthy.

CONCLUSION

In this report a case of a young male cat with non-regenerative primary IMHA was presented. Examination of the bone marrow revealed erythroid maturation arrest with mild myelodysplasia, which led to the conclusion that the non-regenerative anemia in this cat was probably a consequence both of the immune-mediated destruction of RBC precursors and of ineffective erythropoiesis.

REFERENCES

- Callan M.B. (2010). Petechiae and Ecchymoses. In: Ettinger S.J. and Feldman E.C. (editors). *Textbook of Veterinary Internal Medicine: Diseases of the Dog and the Cat*. Edition 7, Elsevier Incorporation, Missouri, p. 297.
- Husbands B.D., Smith S.A., Weiss D.J. (2002). Idiopathic immune-mediated hemolytic anemia (IMHA) in 25 cats. In: *Proceedings of the 20th Annual American College of Veterinary Internal Medicine Congress*. Dallas, United States of America.
- Kohn B., Weingart C., Eckmann V., Ottenjann M., Leibold W. (2006). Primary immune-mediated hemolytic anemia in 19 cats: diagnosis, therapy and outcome (1998-2004). *Journal of Veterinary Internal Medicine* 20, 159-166.
- McCullough S. (2003). Immune-mediated hemolytic anemia: understanding the nemesis. *The Veterinary Clinics of North America: Small Animal Practice* 33, 1295-1315.
- McManus P.M., Craig L.E. (2001). Correlation between leukocytosis and necropsy findings in dogs with immune-mediated hemolytic anemia: 34 cases (1994-1999). *Journal of the American Veterinary Medical Association* 218, 1308-1313.
- Reimer M.E., Troy G.C., Warnick L.D. (1999). Immune-mediated hemolytic anemia: 70 cases (1988-1996). *Journal of the American Animal Hospital Association* 35, 384-391.
- Slappendel R.J. (1986). Interpretation of tests for immune-

- mediated blood diseases. In: Kirk R.W. (editor.). *Kirk's Current Veterinary Therapy IX, Small Animal Practice*. W.B. Saunders Company, Philadelphia, p. 498-505.
- Weiss D.J. (1986). Antibody-mediated suppression of erythropoiesis in dogs with red cell aplasia. *American Journal of Veterinary Research* 47, 2646-2648.
- Weiss D.J., Aird B. (2001). Cytologic evaluation of primary and secondary myelodysplastic syndromes in the dog. *Veterinary Clinical Pathology* 30, 67-75.
- Weiss D.J. (2008). Bone marrow pathology in dogs and cats with non-regenerative immune-mediated haemolytic anaemia and pure red cell aplasia. *Journal of Comparative Pathology* 138, 46-53.

Persbericht

Merial lanceert Equioxx®: het eerste cox-1 sparende NSAID specifiek voor paarden.

Merial introduceert in het vierde kwartaal Equioxx: het eerste COX-1 sparende NSAID specifiek voor paarden. Equioxx kan worden voorgeschreven voor de verlichting van pijn en ontsteking, geassocieerd met osteoarthritis en vermindering van de daaraan gerelateerde kreupelheid bij paarden.

Equioxx combineert effectiviteit met een hoge mate van veiligheid. In vergelijking met traditionele NSAID's is Equioxx (firocoxib) 222 tot 643 keer selectiever voor COX-2 (cyclo-oxygenase-2) dan COX-1. Equioxx richt zich met name op de blokkade van COX-2, dat verantwoordelijk is voor ontsteking, pijn en koorts, terwijl COX-1, welke onder andere de maag- en darmwand beschermt, wordt gespaard.

Doeltreffend en veilig

Om de veiligheid en werkzaamheid van Equioxx aan te tonen zijn er klinische studies uitgevoerd op verschillende plaatsen in Europa waaronder Frankrijk, Duitsland en Nederland¹. Deze klinische studies zijn een aanvulling op onderzoek dat al eerder was verricht in de V.S. en Canada² waar Equioxx al in 2007 op de markt is gebracht.

Het effect van Equioxx op kreupelheid als gevolg van osteoarthritis werd geëvalueerd via de standaard vijfpunten-schaal van de AAEP (American Association of Equine Practitioners). Equioxx bleek de kreupelheid te verminderen met 0,5 punt op de eerste dag en met 1,1 punt zes dagen na de behandeling³. De verbetering is gewoonlijk te zien vanaf 12 uur na de eerste toediening en neemt in veel gevallen nog toe tot de 14^e dag.

Equioxx

Equioxx is verkrijgbaar als injecteerbare oplossing en orale pasta. De dosering is 0,1 mg/kg/dag voor de orale pasta en 0,09 mg/kg/dag voor de injecteerbare oplossing. Equioxx wordt éénmaal daags gegeven gedurende een periode van maximaal 14 dagen achtereenvolgend. De injectie wordt geleverd in een flacon van 25 ml (gemiddeld 9 doseringen). De orale pasta wordt geleverd in een voor de paardenwereld bekende injector en is geschikt voor paarden tot en met 600 kg.

Enkele bekende paardenproducten van Merial zijn Eqvalan, ProteqFlu en Gastrogard.

Voor meer informatie kunt u contact opnemen met Merial.

¹ Koene et al, *J Eq Vet Sci*, 2010 ;30 :237-243

² Doucet et al, *JAVMA*, 2008 ;232 :91-97

³ Back et al., *Equine Vet J*, 2009;41:309-312