

Immune-mediated hemolytic anemia (IMHA) in cats - part 1: a review

Immuungemedieerde hemolytische anemie bij katten - deel 1: een literatuuroverzicht

G. Paes, D. Paepe, J. Veldeman, M. Campos, S. Daminet

Department of Small Animal Medicine and Clinical Biology
Faculty of Veterinary Medicine, Ghent University
Salisburylaan 133, B-9820, Merelbeke, Belgium

geertpaes@ugent.be

ABSTRACT

In contrast to dogs, immune-mediated hemolytic anemia is rarely seen in cats and occurs most often secondary to an underlying infectious, neoplastic or inflammatory process. Clinical symptoms are often vague and are caused by severe anemia and the effect of hypoxia on organ systems. Laboratory abnormalities in cats with IMHA are comparable to those seen in dogs, with the exception of spherocytes, which are difficult to identify in cats. The diagnosis is based on hemolytic anemia in combination with a positive 'true' autoagglutination and/or a positive Coombs test. A search for underlying causes should always be performed and, because infections with hemotropic mycoplasma species are the most important underlying cause for IMHA in cats, a polymerase chain reaction test to detect these bacteria should be carried out. Treatment consists of immunosuppressive drugs, providing oxygen-carrying solutions, treating underlying causes and supportive care. In cats, IMHA carries a better prognosis than in dogs, although relapses are seen in equal frequency.

SAMENVATTING

Immuungemedieerde hemolytische anemie (IMHA) komt zelden voor bij katten en ontstaat meestal secundair aan onderliggende infectieuze, tumorale of inflammatoire processen. De klinische symptomen van IMHA zijn meestal vaag en worden veroorzaakt door erge anemie met secundair hypoxie van organen. De bevindingen bij labo-onderzoek zijn vergelijkbaar met deze die gezien worden bij honden, met uitzondering van de sferocyten, die bij katten moeilijk te identificeren zijn. De diagnose is gebaseerd op een combinatie van hemolytische anemie met een positieve 'echte' autoagglutinatie- en/of coombstest. Verder onderzoek naar onderliggende oorzaken is steeds noodzakelijk. Aangezien infecties met hemotrofe mycoplasmen de belangrijkste oorzaak van IMHA bij katten zijn, is het uitvoeren van een PCR-test ter detectie van deze bacterie aangewezen.

De behandeling bestaat uit het behandelen van onderliggende ziekten, het toedienen van immunosuppressieve geneesmiddelen en een ondersteunende behandeling met ondermeer bloedtransfusies. Katten met IMHA hebben een betere prognose dan honden met deze ziekte, hoewel het percentage patiënten dat hervalt, gelijk is voor beide diersoorten.

INTRODUCTION

Immune-mediated hemolytic anemia (IMHA) results from an immune-mediated destruction of red blood cells (RBCs) that causes a decrease in the total RBC mass and often leads to life threatening anemia. In dogs, IMHA is a frequent cause of anemia. In cats however, IMHA has been reported less often and, in contrast to dogs, the disease occurs most often secondary to a known underlying cause.

When an underlying cause is found to trigger the immune system to destroy the RBCs, a diagnosis of secondary IMHA is established. When, despite extensive research, no underlying cause of the immune-mediated destruction of the RBC's can be identified, a diagnosis of primary IMHA is made. Despite this clinical sub-

division, it is not excluded that in primary IMHA there is a trigger to the immune-mediated RBC destruction.

In this review a complete summary of IMHA in cats and the differences seen between cats and dogs are provided.

PATHOPHYSIOLOGY

The removal of aged RBCs occurs mainly within the spleen and to a lesser extent in the liver by cells of the mononuclear phagocytic system (MPS) that identify antibodies directed against senescent membrane antigens, such as the band 3 antigen (Cotter, 2001). IMHA is a pathologic process that results in the premature destruction of RBCs that are coated with immunoglobulins, complement or both. The disease is

caused by a type II hypersensitivity reaction in which antibodies (mainly IgG and IgM) are produced against normal RBCs (primary IMHA) or against RBCs of which surface antigens are altered through interaction with secondary causes such as drugs, infectious diseases and neoplasia (secondary IMHA) (McCullough, 2003). Red blood cell bound IgM antibodies are more frequently detected in cats with IMHA than in dogs with IMHA in which IgM antibodies are only present in about 8% of the cases (Klag *et al.*, 1993). In one study, IgM antibodies were detected in 8 of 15 Coombs-positive cats with primary IMHA (Kohn *et al.*, 2006). Because IgM is a large pentameric molecule that can directly agglutinate RBCs, autoagglutination, that persists after washing the RBCs ('true' autoagglutination), is often seen in cats with IMHA (in 4 of the 19 cats with IMHA in a study by Kohn *et al.* (2006)) (Gunn-Moore *et al.*, 1999; McCullough, 2003; Kohn *et al.*, 2006). Furthermore, complement activation is stronger for IgM immunoglobulins than for IgG isotype. IgG is a monomeric molecule with less agglutination capability. Hemolysis of antibody-coated RBCs can occur intra- or extravascularly in liver and spleen. Intravascular hemolysis is uncommonly seen in dogs (4% to 9%) and has not been reported in cats with IMHA yet (Klag *et al.*, 1993; Engelbrecht *et al.*, 2002; Kohn *et al.*, 2006). During phagocytosis of RBC by cells of the MPS (extravascular hemolysis), RBCs (normal RBC diameter: 7.0 μm in the dog and 5.8 μm in the cat) lose their redundant membrane, which results in the formation of spherocytes which are smaller than normal RBCs (less than two thirds of the normal diameter) and lack a central pallor (Walker, 1999) (Figure 1). In dogs, large amounts of spherocytes on a peripheral blood smear are highly indicative for IMHA. In cats however, spherocytes are difficult to identify, because normal cat RBCs are smaller and they often do not have a central pallor (Kohn *et al.*, 2006).

In contrast to dogs, in which primary IMHA represents 60-75% of all IMHA cases, most presentations of feline IMHA are secondary (McCullough, 2003). Secondary IMHA in cats can be triggered by infectious agents (e.g. feline leukemia virus (FeLV), feline infectious peritonitis (FIP), *Mycoplasma hemofelis*, *Babesia felis*), by drugs (eg. propylthiouracil), by neoplasia (eg. lymphoma), by inflammatory conditions (e.g. chronic cholangitis), by blood transfusions with incompatible donors and in rare cases by systemic lupus erythematosus (SLE) (Gunn-moore *et al.*, 1999; Messick, 2003; McCullough, 2003; Penzhorn *et al.* 2004; Norris *et al.* 2005; Kohn *et al.*, 2006).

Pure red cell aplasia (PRCA) is a well-recognized form of IMHA that occurs in both dogs and cats and that is characterized by a severe non-regenerative anemia and erythroid aplasia in the bone marrow (Gunn-moore *et al.*, 1999; Zini *et al.*, 2007; Weiss, 2008). Primary PRCA in cats is probably an immune-mediated disorder (Stokol, 1997; Weiss, 2008). A study in dogs with PRCA has shown antibodies capable of suppressing erythropoiesis (Weiss, 1986). Secondary PRCA

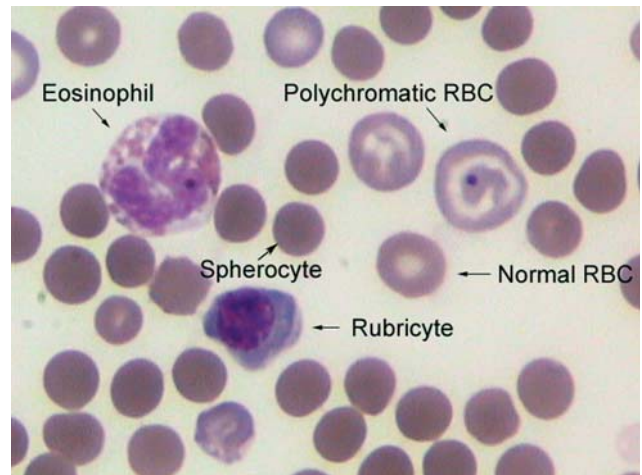


Figure 1. Diff-Quick stained blood smear of an anemic dog diagnosed with primary IMHA showing a spherocyte, a polychromatic cell (immature red blood cell or reticulocyte), an eosinophil and a rubricyte (red blood cell precursor).

occurs commonly in cats infected with feline leukemia virus (Abkowitz, 1987).

UNDERLYING CAUSES FOR IMHA IN CATS

Because IMHA is most often secondary in cats, a summary of the most important underlying causes will be given. Only when, despite extensive workup, no underlying cause can be identified, a diagnosis of primary IMHA is established.

Infectious agents

From the infectious agents, hemotropic mycoplasma infections (formerly *Haemobartonella*) have been most frequently associated with IMHA in cats (McCullough, 2003). Although significant geographic variations exist, the overall prevalence of hemotropic mycoplasma species in the blood of cats, measured by a real-time polymerase chain reaction (RT-PCR) test, has been reported to be as high as 12.5% and 18.5% in Switzerland and the United Kingdom, respectively. In addition, no significant difference in hemoplasma prevalence between healthy and ill cats was found (Messick, 2003; Willi *et al.*, 2006). Hemotropic mycoplasmas are epicytellar RBC bacteria and the route of transmission of these parasites is not yet completely understood (Duin *et al.*, 2009). Four existing types (*Mycoplasma hemofelis*, *Candidatus Mycoplasma hemominutum*, *Candidatus Mycoplasma turicensis* and *Candidatus Mycoplasma hematoparvum*) have been described in cats (Tasker, 2003; Willi, 2006), but only *Mycoplasma hemofelis* can cause severe hemolytic anemia, also known as feline infectious anemia. The other strains cause no or only minimal clinical illness in healthy cats. However, when complicated by co-infections with other strains or with retroviral infections or when the animal is immunosuppressed, these strains can also cause a significant drop in packed cell volume

(PCV) (Westfall *et al.*, 2001; Messick, 2003; Willi *et al.*, 2006). The mechanism by which *Mycoplasma hemofelis* induces anemia, is partially based on a direct damage of the RBC. However, immune-mediated injury of RBCs appears to be more important (Harvey, 2006). Co-infections with FeLV occur and generally result in more severe anemia (Messick, 2003). Other infectious agents that can cause IMHA in cats are FeLV (Gunn-Moore *et al.*, 1999; Kohn *et al.*, 2006) and rarely FIP and *Babesia felis* (Penzhorn *et al.*, 2004; Norris *et al.*, 2005).

Drugs

Several drugs (e.g. propylthiouracil, methimazole, famotidine) have been reported to cause IMHA in cats, although scientific evidence that proves the association between IMHA and the drug administration, most often lacks (Peterson *et al.*, 1984; de Brito Galvao *et al.*, 2008). The intravenous (IV) administration of famotidine has been anecdotally associated with feline IMHA (Plumb, 2002). Therefore, some veterinarians recommend injectable famotidine only by subcutaneous route in cats. The risk of such reaction has been evaluated in a recent retrospective study, which could not demonstrate a decrease in the PCV after IV famotidine (de Brito Galvao *et al.*, 2008). The authors therefore concluded that the IV route appeared to be safe if famotidine was administered over 5 minutes.

Neoplasia

Neoplastic diseases, such as lymphoma, were previously associated with IMHA in cats. Gunn-moore *et al.* (1999) reported IMHA in 2 sibling cats associated with multicentric lymphoblastic infiltration. They also suggested a genetic predisposition in these animals.

Vaccination

Finally, vaccination (< 1 month) in dogs has been suggested to trigger immune-mediated diseases, such as IMHA and polyarthritis (Duval *et al.*, 1996; Kohn *et al.*, 2003). Although recent vaccination against calicivirus was reported to cause polyarthritis in cats, no association between vaccination and IMHA has been described in cats (Dawson *et al.*, 1993; Kohn *et al.*, 2006).

EPIDEMIOLOGY

In a recent study, primary IMHA was mainly seen in young (average age of 3.2 years) domestic shorthair cats (59%). Furthermore, male cats (58%) were predisposed and the majority of the cats were kept strictly indoors (73%). According to these studies, outdoor access does not seem to be a risk factor for primary IMHA in cats. Also in other studies, a predisposition for young, male cats has been described for primary IMHA (Gunn-moore *et al.*, 1999, McCullough, 2003). In con-

trast to cats, mainly young to middle-aged female spayed dogs are affected by IMHA (McCullough, 2003; Miller *et al.*, 2004).

Feline PRCA is consistently diagnosed at a young age (8 to 36 months) (Stokol *et al.*, 1999; Zini *et al.*, 2007).

Secondary IMHA may affect cats of any age (Gunn-moore *et al.*, 1999). Infections with hemotrophic mycoplasmas have been associated with male gender, outdoor access and old age (Willi *et al.*, 2006).

CLINICAL PRESENTATION

Clinical signs may be acute or chronic and are often non-specific. In a study by Kohn *et al.* (2006), in 19 cats with primary IMHA the following signs were reported by the owners: lethargy (n=19), inappetence (n=13), pica (n=5), vomiting (n=2), pruritus (n=1), dyspnea (n=1), epistaxis (n=1), polydipsia (n=1) and obstipation (n=1). The cats were sick for a median of 8.5 days before presentation.

On physical examination, most abnormalities are caused by severe anemia and the effect of hypoxia on organ systems, such as liver, lungs, heart, kidney and intestines (McCullough, 2003). The physical examination of the previously described 19 cats with primary IMHA revealed pale mucous membranes (n=19), icteric mucous membranes (n=2), hypothermia (n=2), fever (n=4), a mild to moderate systolic heart murmur (n=8) and a mild generalized or focal lymphadenopathy (n=3).

In dogs, clinical symptoms of IMHA are comparable to those seen in cats. Vague signs, such as weakness, anorexia, pigmenturia, vomiting and diarrhea are mainly reported by the owner (Reimer *et al.*, 1999; Piek *et al.*, 2008). On physical examination, almost all dogs with IMHA have pale mucous membranes. Icterus, cranial abdominal organomegaly and systolic heart murmur are also frequent clinical signs, each present in 50% of the patients with IMHA. In approximately 30% of the dogs with IMHA, tachycardia and tachypnea are present (Reimer *et al.*, 1999; Piek *et al.*, 2008).

CLINICAL PATHOLOGY FINDINGS

Complete blood cell counts (CBC) and biochemistry profile most often reflect an acute hemolytic crisis in both dogs and cats. The majority of cats (79%) with IMHA are presented with a severe anemia (packed cell volume (PCV) <15%). While 70 to 80 % of the dogs with IMHA have a regenerative anemia, signs of regeneration are absent in more than half of the cats (58%) with IMHA (Klag *et al.*, 1993; Reimer *et al.*, 1999; McManus *et al.*, 2001; Kohn *et al.*, 2006). Until recently, 2 different hypotheses were postulated for the presence of non-regenerative IMHA in dogs and cats. According to the first hypothesis, it is assumed that, when a dog or cat becomes anemic, 3 to 5 days are required to develop a substantial reticulocyte response, meaning that in patients with peracute IMHA reticu-

locytes have not been released into the blood stream yet (McCullough, 2003; Weiss, 2008). According to the second hypothesis the antibody production against RBC precursors in the bone marrow can cause a non-regenerative anemia in patients that are anemic for more than 5 days (Kohn *et al.*, 2006; Weiss, 2008). However, in a recent study by Weiss (2008), in which bone marrow of dogs and cats with non-regenerative IMHA (of greater than 5 days duration) and PRCA was analyzed, it was found that the immune-mediated destruction of bone marrow erythroid precursor cells accounted for all of the cases of PRCA, but only for 14% of the cats and 30% of the dogs with non-regenerative IMHA. In the other dogs and cats with non-regenerative IMHA a bone marrow erythroid hyperplasia was present and the author postulated that the IMHA with erythroid hyperplasia may represent a unique subtype of IMHA. Dogs and cats with this type of IMHA had a relatively high incidence of neutropenia and thrombocytopenia and a variety of pathological changes in the bone marrow. Furthermore, in these patients a decreased survival of only 60 days was observed.

Other abnormalities that can be found in the CBC of cats with IMHA include lymphocytosis and thrombocytopenia. While the majority of dogs (74%) with IMHA have neutrophilia, often with a left shift, neutrophilia is only present in 10% of the cats with primary IMHA. In the study by Kohn, a marked lymphocytosis was present in the CBC of 32% and in the bone marrow of 86% of the cats with primary IMHA (McManus *et al.*, 2001; Kohn *et al.*, 2006, Weiss, 2008). Lymphocytosis may indicate a chronic antigen stimulation and has also been reported in cats with other types of hemolytic anemia, such as pyruvate kinase deficiency or hereditary increased erythrocyte osmotic fragility (OF), two conditions that have been described in young Abyssinian and Somali cats (Kohn *et al.*, 2000; Kohn *et al.*, 2008). In cats with bone marrow lymphoid hyperplasia, it might be difficult to differentiate between reactive lymphocytosis and chronic lymphocytic leukemia (CLL). Weiss (2005) found that a normal lymphocyte morphology, lymphocytes of B-cell origin and the organization of lymphocytes in aggregates are criteria that suggest reactive lymphocytosis instead of malignant lymphocytosis. In cats with chronic lymphocytic leukemia, lymphocytes were predominantly of T-cell origin and were slightly larger with cleaved or lobulated nuclei. Furthermore, they were diffusely distributed throughout the bone marrow (Weiss, 2005).

In the study by Kohn *et al.* (2006), thrombocytopenia was found in 8 of the 19 cats with primary IMHA. Thrombocytopenia can be caused by immune-mediated destruction, by consumption due to diffuse intravascular coagulation (DIC) or by sequestration in an enlarged spleen (Kohn *et al.*, 2006). Evans' syndrome occurs when a combination of immune-mediated destruction of RBCs and thrombocytes is present. In some studies, this disease has been reported to be present in up to one third of the dogs with IMHA (Engelbrecht *et al.*, 2002). However, it was only present in




Figure 2. Microhematocrite tube of a cat diagnosed with primary IMHA showing the icteric plasma due to extravascular hemolysis.

1 of the 8 cats with thrombocytopenia and IMHA in the study by Kohn *et al.* (2006).

In the serum biochemistry profile, hyperbilirubinemia is present in the majority of cats and dogs with IMHA and in dogs, a high bilirubin concentration is associated with a worse prognosis (Klag *et al.*, 1993; McCullough, 2003; Kohn *et al.*, 2006). In the study by Kohn *et al.* (2006) 7 of the 13 cats with hyperbilirubinemia also had increased liver enzyme activities, indicating that the hyperbilirubinemia is probably not only a consequence of hemolysis, but probably also of liver damage as a result of liver hypoxia (Figure 2). Other biochemistry abnormalities found in the 19 cats with primary IMHA in this study were hyperglobulinemia (n=10), hyperproteinemia (n=8), hypoalbuminemia (n=4), increased alkaline phosphatase (AF) (n=1), increased alanine transferase (ALT) (n=10), increased aspartate transferase (AST) (n=3) and a mildly increased blood urea nitrogen (BUN) (n=6). The hyperglobulinemia probably results from chronic antigen stimulation and has also been reported in cats with pyruvate kinase deficiency and in cats with hereditary increased erythrocyte osmotic fragility (Kohn *et al.*, 2000; Kohn *et al.*, 2008).

A coagulation profile can reveal increased clotting times, indicating the presence of DIC. In dogs, DIC is seen in 12 to 45% of the dogs with IMHA (Klag *et al.*, 1993; Scott-Moncrieff *et al.*, 2001; Engelbrecht *et al.*, 2002). In the study by Kohn *et al.* (2006), one cat was diagnosed with DIC (based upon the presence of thrombocytopenia with an increased prothrombin and activated partial thromboplastin time) and 2 other cats were suspected.

DIAGNOSIS

The diagnosis of IMHA in anemic cats is based on the presence of 'true' autoagglutination or on the detection of erythrocyte-bound immunoglobulin or complement with a direct Coombs test (Kohn *et al.*, 2006).

In IMHA, rouleaux formation is often superimposed upon agglutination. Furthermore, massive rouleaux formation can sometimes simulate 'true' autoagglutination. 'Pseudoagglutination', due to massive rouleaux formation will only disappear after washing the RBCs three times with physiological saline (Slappendel, 1986). In the study by Kohn *et al.* (2006), all of the 19 cats with IMHA showed varying degrees of agglutination. However, after washing the RBCs three times, the autoagglutination persisted in only 4 cats.

The direct antiglobulin test (DAT) or Coombs test has been associated with false negative results in 42 to 63% of dogs with IMHA (Jackson *et al.*, 1985; Reimer *et al.*, 1999; Quigley *et al.*, 2001). In these studies the Coombs test was performed as described by Slappendel, using antiserum that contained antidog IgM, IgG and C3b at 37°C and at 4°C. In the study by Quigley *et al.* the test was only performed at 37°C. The validity of the Coombs test in cats was tested by Kohn *et al.* (2006) and the test was negative in all healthy (n=5), in all sick non-anemic (n=9) and in 55 of the sick anemic cats (n=78). In cats with blood loss anemia, anemia due to renal failure, retrovirus infection or inflammatory disease and anemia due to hemolysis not related to immunological processes, the Coombs test was negative (n=55). A positive Coombs test was seen in 18 cats. Fifteen of these cats were diagnosed with primary IMHA and the other three with IMHA secondary to lymphoma (n=2) and cholangiohepatitis (n=1). Although the results of the Coombs test were very promising in this study, another study using a direct Coombs test with polyvalent antiserum found a positive test in 16 of 20 anemic cats. Of these 16 cats, only 3 cats that were infected with *Mycoplasma hemofelis* had hemolytic anemia. In the other 13 cats no signs of hemolysis were present (Dunn *et al.*, 1984). The authors concluded that positive test results in cats must be evaluated carefully. False positive Coombs test results may occur because circulating immune complexes may be present due to several clinical conditions, such as various infectious and neoplastic diseases and as a consequence of the administration of various drugs (Slappendel, 1986). Furthermore, false negative Coombs test results can also be seen in dogs or cats with IMHA and can be a consequence of improperly prepared non-species-specific antisera or improperly diluted antisera (Slappendel, 1986). Recently, flow cytometry was used in a large group of dogs with different diseases and had a higher sensitivity (87%) and specificity (74%) for detecting anti-RBC antibodies in dogs with IMHA than the Coombs test (Morley *et al.*, 2008). To the authors' knowledge, the use of flow cytometry has not been evaluated in a large group of cats yet.

As mentioned previously, the detection of spherocytes, which are pathognomonic for IMHA, is difficult in cats. Because spherocytes have an increased osmotic fragility due to a reduced volume-to-surface ratio, measuring the RBC osmotic fragility can be an additional diagnostic tool in cats (Slappendel 1986; Kohn *et al.*, 2006). The osmotic fragility test can be performed in daily practice by preparing a solution equivalent to 0.64% saline. Five drops of patients blood are added to 5 ml of this solution. Afterwards, the mixture is incubated for 5 minutes and centrifuged at 3500 rpm during 5 minutes. Osmotic fragility is normal when intact RBCs can be seen on the bottom of the tube and when the supernatant is clear. However, when spherocytes are present, free hemoglobin will stain the supernatant red. A second tube with blood of the patient in 0.9% NaCl should be used as a control. Osmotic fragility was measured in 10 of 19 cats with primary IMHA and was increased in all cats (Kohn *et al.*, 2006). However, an increased osmotic fragility is not specific for IMHA, as it can also be increased in other diseases, such as lymphoma, hypophosphatemia, FeLV infection, renal failure or certain inflammatory diseases (Kohn, 2006). Furthermore, an increased osmotic fragility has been reported in Abyssinian and Somali cats with hereditary increased erythrocyte osmotic fragility (Kohn *et al.*, 2000).

Because IMHA in cats most often occurs secondary to an underlying disease a thorough work up to search for underlying causes is very important. First of all, a complete history can evaluate a recent administration of certain drugs or vaccinations. Secondly, in any clinically anemic cat with outdoor access, infectious diseases should be excluded. FeLV and FIV can be excluded by using commercial available enzyme-linked immunosorbent assays (ELISA) that detect FeLV p27 antigen and FIV antibodies in blood (Arjona *et al.*, 2007). Because FeLV antigen may not be detected in latent infections when the virus is integrated in bone marrow, a polymerase chain reaction (PCR) test or viral culture, on a bone marrow aspirate, should be performed when the ELISA test is negative (Arjona *et al.*, 2007). Cytological examination of blood smears can sometimes identify hemotropic mycoplasmas on the surface of RBCs. However, the organism could only be detected in 37.5% of cats that were experimentally inoculated with *Mycoplasma hemofelis* and *Candidatus Mycoplasma hemominutum* (Westfall *et al.*, 2001). The low sensitivity of blood smear analysis is attributable to the fact that these organisms are extremely small and tend to become dissociated from the RBC surface making it difficult to identify them cytologically (Westfall *et al.*, 2001). Recently, real-time PCR assays specific for *M. hemofelis*, *Candidatus Mycoplasma hemominutum* en *Candidatus Mycoplasma turicensis* have been developed, and proved to be highly sensitive, specific and accurate for the diagnosis of feline hemoplasma infections (Tasker *et al.*, 2003; Willi *et al.*, 2006). Important to remember is that cats treated with antibiotics can become PCR-negative within

a few days after starting the treatment. However, the cat may become chronically infected without having overt clinical signs of infection and revert to a PCR-positive status shortly after a discontinuation of treatment. Therefore, a negative PCR test obtained during or shortly after treatment with antibiotics does not always rule out the possibility of a chronic hemoplasma infection (Messick, 2003).

Underlying neoplastic or inflammatory processes should be ruled out by using medical imaging techniques, such as thoracic and abdominal radiography and abdominal ultrasonography (McCullough, 2003). On abdominal ultrasound or radiology a splenomegaly can be detected in 42 to 60% of cats (Engelbrecht *et al.*, 2002; Kohn *et al.*, 2006). Splenomegaly can result from the infiltration of abnormal cells, inflammatory or infectious processes, congestion or hyperplastic splenomegaly (eg. related to hemolysis) and is also seen in cats with pyruvate kinase deficiency or hereditary increased erythrocyte osmotic fragility (Kohn *et al.*, 2006). Regarding the search for infectious causes of IMHA, it is interesting to note that the usual clinical workup is mainly focused on FIV, FeLV and hemotropic mycoplasmas. Additionally, medical imaging of the thorax and abdomen helps ruling out hidden infections. However, future research might indicate that other infectious agents are involved.

Finally, cytological and/or histopathological examination of a bone marrow aspirate should be performed in cases in which there is a presence of non-regenerative anemia (for a duration of more than 5 days), when a destruction of erythroid precursors is suspected or when other cytopenias are present on the CBC (McCullough, 2003). In some cases it can be difficult to differentiate cats with myelodysplastic syndromes from cats with IMHA and secondary dysmyelopoiesis. In such cases, the clinical response to immunosuppressive treatment may be useful to differentiate both diseases (Weiss, 2006).

TREATMENT

Immunosuppressive therapy

Immunosuppressive dosages of corticosteroids (prednisolone, prednisone, dexamethasone and methylprednisolone) are the treatment of choice for primary IMHA in cats. Corticosteroids suppress the activity of macrophages of the MPS, decrease the production of immunoglobulins, inhibit the complement cascade, enhance reticulocytosis and inhibit the production of several cytokines necessary for T-cell generation and function (Baschant and Tuckermann, 2010). The dosage of prednisolone advised in cats is 1-2 mg/kg per os (PO) twice daily (Kohn *et al.*, 2006). It takes 3 to 14 days before the PCV increases (McCullough, 2003). The PCV should be checked twice weekly until it stabilizes and then weekly for the duration of treatment (McCullough, 2003). After the stabilization of the PCV, the therapy should be tapered slowly (approx-

mately 25% every 2-4 weeks) over a 3 to 6-month period. Abrupt changes may lead to relapse. Evidence about the use of cytotoxic drugs in cats is limited. In dogs, azathioprin, a purin analogue that interferes with DNA and RNA synthesis, is often used in the treatment of IMHA. In cats, however, azathioprine can give bone marrow and hepatic toxicity and therefore, the drug should be avoided or given at a reduced dosage (0.3 mg/kg/day) (Beale *et al.*, 1992).

Oxygen-carrying support

If the cat is severely anemic or when severe tissue hypoxia is expected, the patient should receive an oxygen-carrying fluid. In cats, most often whole blood or a packed red blood cell transfusion is given. Often more than one transfusion is needed (Kohn *et al.*, 2006; Weingart *et al.*, 2004, Klaser *et al.*, 2005). In two recent retrospective studies evaluating the use of blood transfusions in 91 and 126 cats from which 6 and 3 cats respectively had IMHA, blood transfusions were well tolerated and resulted in mild transient transfusion reactions in only 2 and 11 cats respectively (Weingart *et al.*, 2004; Klaser *et al.*, 2005). It is of major importance that blood typing or cross matching are always performed. Incompatible transfusions can result in life-threatening complications, because of the natural occurrence of anti-RBC antibodies in cats. Furthermore, it is advised to regularly test donor cats for the presence of hemotropic mycoplasmas. The prevalence of infection among feline blood donors was recently reported to be 7.5% for *Candidatus Mycoplasma hemominutum* and 2.3% for *M. hemofelis* (Messick, 2003).

The use of an ultrapurified, polymerized bovine hemoglobin solution (HBOC) was evaluated in 72 cats with anemia (Gibson *et al.*, 2002). Because adverse effects were present in 44 cats and pulmonary edema and pleural effusion (due to circulatory overload) was seen in 35% of all cats, the authors concluded that further research is needed to determine the safety and the ideal dose and rate of administration of HBOC, before the use of the solution can be recommended in anemic cats.

Treating for underlying diseases

Because the list of underlying causes of IMHA is too broad to discuss all treatment protocols in detail, only the treatment of hemotropic mycoplasma infections will be discussed. Doxycycline (5-10 mg/kg PO SID or BID for up to 21 days) has been the antibiotic of choice for years for the treatment of feline mycoplasma infections. However, doxycycline only rarely clears this organism from the body and can cause side effects such as oesophageal strictures in cats (Ishak *et al.*, 2008). More recently, the use of different types of fluoroquinolones (enrofloxacin, marbofloxacin and pradofloxacin) have been studied in cats infected with *M. hemofelis*. Enrofloxacin (5-10 mg/kg PO SID for 14 days) was shown to be equal or superior to doxycycline

for the treatment of mycoplasma infections, but it can be associated with retinal degeneration in some cats (Ishak *et al.*, 2008). Marbofloxacin (2.75 mg/kg PO SID for 14 days) was administered to 14 cats that were experimentally infected with *M. hemofelis* and appeared to be safe and resulted in hematological, however without clinical improvement (Ishak *et al.*, 2008). Finally, the use of pradofloxacin (5-10 mg/kg PO SID) was evaluated in 23 experimentally infected cats and the drug proved to cause no side effects and have anti-*M. hemofelis* effects similar to those of doxycycline. Furthermore, it appeared to be more effective than doxycycline at long-term clearance of the organism. Because fluoroquinolones only have to be given once daily and because they give similar results as doxycycline, the use of this class of antibiotics might be preferred to treat feline mycoplasma infections (Messick, 2003).

Supportive care

IMHA patients can be at risk for developing gastric ulcerations as a consequence of poor gastro-intestinal perfusion combined with long-term administration of corticosteroids. Therefore, gastric protectants (histamine blockers, prostaglandin analogues, proton pump inhibitors and ulcer-coating medications) may sometimes be required (McCullough, 2003).

In contrast to dogs with IMHA, complications as DIC and thromboembolic events do not often occur and the use of anticoagulants is not part of the standard treatment of IMHA in cats (Kohn *et al.*, 2006).

Novel treatments

Human intravenous immunoglobulin (hIVIG) is a preparation of polyspecific human IgG that blocks the Fc receptors of macrophages, modulates T-lymphocyte function, decreases natural killer cell activity, blocks complement-mediated cell damage, neutralizes autoantibodies and modulates the release and function of proinflammatory cytokines (Byrne, 2002). Although hIVIG has been used successfully in humans and dogs with IMHA, the use of hIVIG has only been described in one cat with erythroid and megakaryocytic aplasia and in one cat with erythema multiforme. Further research is needed on the use of this drug in cats (Zini *et al.*, 2007, Byrne, 2002).

PROGNOSIS

The possibly fatal complications in dogs with primary IMHA, such as DIC and thromboembolism are seldom seen in cats. Furthermore, cats appear to tolerate severe anemia better than dogs (Kohn *et al.*, 2006). Because of this, the mean mortality rate for IMHA is lower in cats (24%) than in dogs, in which mortality rates of 30-70%, depending on the study, have been described (Reimer *et al.*, 1999; Kohn *et al.*, 2006).

In cats with primary IMHA, relapses have been re-

ported to occur in almost 30% of cats, compared to 38% in a study of dogs (Engelbrecht *et al.*, 2002; Kohn *et al.*, 2006).

The prognosis for cats with secondary IMHA depends on the underlying cause. If treated correctly, the outcome for hemotropic mycoplasma infections in cats is good, but recovering cats generally remain chronic carriers and remain sensitive for new infections (Messick, 2003).

CONCLUSION

IMHA is less frequently seen in cats than in dogs and the majority of IMHA cases in cats are secondary to an underlying cause. This is also the case in dogs, but in this species the trigger often disappears, which makes the link with the autoimmune disease less clear. Clinical symptoms and clinical pathological findings in cats with IMHA are comparable to those seen in dogs, with the exception of spherocytes, which are difficult to identify in cats. A diagnosis of IMHA is based on the presence of 'true' autoagglutination and/or a positive Coombs test. A search for possible underlying causes should always be performed. Treatment consists of immunosuppressive drugs, providing oxygen-carrying solutions, treating underlying causes and supportive care. In cats, IMHA carries a better prognosis than in dogs, possibly due to a lower incidence of thromboembolic complications.

REFERENCES

- Abkowitz J.L., Holly R.D., Grant C.K. (1987). Retrovirus-induced feline pure red cell aplasia. *The Journal of Veterinary Clinical Investigation* 80, 1056-1063.
- Arjona A., Barquero N., Doménech A., Tejerizo G., Collado V.M., Tournal C., Martin D., Gomez-Lucia E. (2007). Evaluation of a novel nested PCR for the routine diagnosis of feline leukemia virus (FeLV) and feline immunodeficiency virus (FIV). *Journal of Feline Medicine and Surgery* 9, 14-22.
- Baschant U., Tuckermann J. (2010). The role of the glucocorticoid receptor in inflammation and immunity. *Journal of Steroid Biochemistry and Molecular Biology*. Epub ahead of print.
- Beale K.M., Altman D., Clemmons R.R., Bolon B. (1992). Systemic toxicosis associated with azathioprine administration in domestic cats. *The American Journal of Veterinary Research* 53, 1236-1240.
- Byrne K.P. (2002). Use of human immunoglobulin for treatment of severe erythema multiforme in a cat. *Journal of American Veterinary Medicine Association* 220, 197-201.
- de Brito Galvao J.F., Trepanier L.A. (2008). Risk of hemolytic anemia with intravenous administration of Famotidine to hospitalized cats. *Journal of Veterinary Internal Medicine* 22, 325-329.
- Dawson S., McArdle F., Bennett D., Carter S.D., Bennett M., Ryvar R., Gaskell R.M. (1993). Investigation of vaccine reactions and breakdowns after feline calicivirus vaccination. *The Veterinary Record* 132, 346-350.
- Dowers K.L., Tasker S., Radecki S.V., Lappin M.R. (2009). Use of pradofloxacin to treat experimentally induced *My-*

- coplasma hemofelis* infection in cats. *The American Journal of Veterinary Research* 70, 105-111.
- Duin M.B., Moyaert H., Pasmans F., Boyen F. (2009). Hemotrofe mycoplasmen bij katten. Deel 1: literatuuroverzicht. *Vlaams Diergeneeskundig Tijdschrift* 78, 143-154.
- Duval D., Giger U. (1996). Vaccine-associated immune-mediated hemolytic anemia in the dog. *Journal of Veterinary Internal Medicine* 10, 290-295.
- Engelbrecht R., Kohn B., Leibold W., Giger U. (2002). Klinische Befunde, Diagnostik und Behandlungserfolge bei der primären und sekundären immunhämolytischen Anämie beim Hund. *Kleintierpraxis* 47, 264-278.
- Gibson G.R., Callan M.B., Hoffman V., Giger U. (2002). Use of a hemoglobin-based oxygen-carrying solution in cats: 72 cases (1998-2000). *Journal of American Veterinary Medicine Association* 221, 96-102.
- Gunn-Moore D.A., Day M.J., Graham M.E.A., Cue S.M., Harbour D.A. (1999). Immune-mediated haemolytic anaemia in two sibling cats associated with multicentric lymphoblastic infiltration. *Journal of Feline Medicine and Surgery* 1, 209-214.
- Harvey J.W. (2006). Hemotropic Mycoplasmosis (Hemobartonellosis). In: Greene C.E. (Ed.) *Infectious Diseases of the Dog and Cat*. Edition 3. Elsevier Incorporation, Philadelphia, p. 252-260.
- Husbands B.D., Smith S.A., Weiss D.J. (2002). Idiopathic immune-mediated hemolytic anemia (IMHA) in 25 cats. In: *Proceedings of the 20th Annual American College of Veterinary Internal Medicine Congress*. Dallas, United States of America.
- Ishak A.M., Dowers K.L., Cavannaugh M.T., Powell C.C., Hawley J.R., Radecki S.V., Lappin M.R. Marbofloxacin for the treatment of experimentally induced *Mycoplasma haemofelis* infection in cats. *Journal of Veterinary Internal Medicine* 22, 288-292.
- Jackson M.L., Kruth S.A. (1985). Immune-mediated hemolytic anemia and thrombocytopenia in the dog: a retrospective study of 55 cases diagnosed from 1979 through 1983 at the Western College of Veterinary Medicine. *The Canadian Veterinary Journal* 26, 245- 250.
- Klag A.R., Giger U., Shofer F.S. (1993). Idiopathic immune-mediated hemolytic anemia in dogs: 42 cases (1986-1990). *Journal of the American Veterinary Medical Association* 202, 783-788.
- Klaser D.A., Reine N.J., Hohenhaus A.E. (2005). Red blood cell transfusions in cats: 126 cases (1999). *Journal of the American Veterinary Medical Association* 226, 920-923.
- Kohn B., Goldschmidt M.H., Hohenhaus A.E., Giger U. (2000). Anemia, splenomegaly and increased osmotic fragility of erythrocytes in Abyssinian and Somali cats. *Journal of the American Veterinary Medical Association* 217, 1483-1491.
- Kohn B., Garner M., Lübke S. (2003). Polyarthritis following vaccination in four dogs. *Veterinary and Comparative Orthopaedics and Traumatology* 16, 6-10.
- Kohn B., Weingart C., Eckmann V., Ottenjann M., Leibold W. (2006). Primary immune-mediated hemolytic anemia in 19 cats: diagnosis, therapy and outcome (1998-2004). *Journal of Veterinary Internal Medicine* 20, 159-166.
- Kohn B., Fumi C. (2008). Clinical course of pyruvate kinase deficiency in Abyssinian and Somali cats. *Journal of Feline Medicine and Surgery* 10, 145-153.
- McCullough S. (2003). Immune-mediated hemolytic anemia: understanding the nemesis. *The Veterinary Clinics Small Animal Practice* 33, 1295-1315.
- McManus P.M., Craig L.E. (2001). Correlation between leukocytosis and necropsy findings in dogs with immune-mediated hemolytic anemia: 34 cases (1994-1999). *Journal of the American Veterinary Medical Association* 218, 1308-1313.
- Messick J.B. (2003). New perspectives about Hemotropic mycoplasma (formerly, *Haemobartonella* and *Eperythrozoon* species) infections in dogs and cats. *The Veterinary Clinics Small Animal Practice* 33, 1453-1465.
- Miller S.A., Hohenhaus A.E., Hale A.S. (2004). Case-control study of blood type, breed, sex and bacteremia in dogs with immune-mediated haemolytic anemia. *Journal of the American Veterinary Medical Association* 224, 232-235.
- Morley P., Mathes M., Guth A., Dow S. (2008). Anti-erythrocyte antibodies and disease associations in anemic and nonanemic dogs. *Journal of Veterinary Internal Medicine* 22, 886-892.
- Norris J.M., Bosward K.L., White J.D., Baral R.M., Catt M.J., Malik R. (2005). Clinicopathological findings associated with feline infectious peritonitis in Sydney, Australia: 42 cases (1990-2002). *Australian Veterinary Journal* 83, 666-673.
- Ottenjann M., Weingart C., Arndt G., Kohn B. (2006). Characterization of the anemia of inflammatory disease in cats with abscesses, pyothorax or fat necrosis. *Journal of Veterinary Internal Medicine* 20, 1143-1150.
- Penzhorn B.L., Schoeman T., Jacobson L.S. (2004). Feline Babesiosis in South Africa: A review. *Annals New York Academy of Sciences* 1026, 183-186.
- Piek C.J., Junius G., Dekker A., Schrauwen E., Slappendel R.J., Teske E. (2008). Idiopathic immune-mediated hemolytic anemia: treatment, outcome and prognostic factors in 149 dogs. *Journal of Veterinary Internal Medicine* 22, 366-373.
- Plumb D. (2002). *Veterinary Drug Handbook*. 4th Edition, Iowa State University Press, p. 852.
- Quigley K.A., Chelack B.J., Haines D.M., Jackson M.L. (2001). Application of a direct flow cytometric erythrocyte immunofluorescence assay in dogs with immune-mediated hemolytic anemia and comparison to the direct antiglobulin test. *Journal of Veterinary Diagnostic Investigation* 4, 297-300.
- Reimer M.E., Troy G.C., Warnick L.D. (1999). Immune-mediated hemolytic anemia: 70 cases (1988-1996). *Journal of the American Animal Hospital Association* 35, 384-391.
- Scott-Moncrieff J.C., Treadwell N.G., McCullough S.M., Brooks M.B. (2001). Hemostatic abnormalities in dogs with primary immune-mediated hemolytic anemia. *Journal of the American Animal Hospital Association* 37, 220-227.
- Slappendel R.J. (1986). Interpretation of tests for immune-mediated blood diseases. In: Kirk R.W. (editor). *Kirk's Current Veterinary Therapy IX, Small Animal Practice*. W.B. Saunders Company, Philadelphia, p. 498-505.
- Stokol T., Blue J.T. (1999). Pure red cell aplasia in cats: 9 cases (1989-1997). *Journal of the American Veterinary Association* 214, 75-79.
- Sykes J.E., Drazenovich N.L., Ball L.M., Leutenegger C.M. (2007). Use of conventional and real-time polymerase chain reaction to determine the epidemiology of Hemoplasma infections in anemic and nonanemic cats. *Journal of Veterinary Internal Medicine* 21, 685-693.
- Tasker S., Helps C.R., Day M.J., Gruffydd-Jones T.J., Harbour D.A. (2003). Use of real-time PCR to detect and quantify *Mycoplasma haemofelis* and 'Candidatus My-

- coplasma haemominutum' DNA. *Journal of Clinical Microbiology* 41, 439-441.
- Walker D. (1999). Peripheral blood smears. In: Cowell, R.L., Tyler, R.D., Meinkoth, J.H. (eds). *Diagnostic Cytology and Hematology of the Dog and Cat*. Second edition, Mosby, St. Louis, p. 269-270.
- Weingart C., Giger U., Kohn B. (2004). Whole blood transfusions in 91 cats: a clinical evaluation. *Journal of Feline Medicine and Surgery* 6, 139-148.
- Weiss D.J. (1986). Antibody-mediated suppression of erythropoiesis in dogs with red cell aplasia. *American Journal of Veterinary Research* 47, 2646-2648.
- Weiss D.J. (2005). Differentiating benign and malignant causes of lymphocytosis in feline bone marrow. *Journal of Veterinary Internal Medicine* 19, 855-859.
- Weiss D.J. (2006). Evaluation of dysmyelopoiesis in cats: 34 cases (1996-2005). *Journal of the American Veterinary Medical Association* 228, 893-897.
- Weiss D.J. (2008). Bone marrow pathology in dogs and cats with non-regenerative immune-mediated haemolytic anaemia and pure red cell aplasia. *Journal of Comparative Pathology* 138, 46-53.
- Westfall D.S., Jensen W.A., Reagan W.J., Radecki S.V., Lappin M.R. (2001). Inoculation of two genotypes of *Hemobartonella felis* (California and Ohio variants) to induce infection in cats and the response to treatment with azithromycin. *American Journal of Veterinary Research* 62, 687-691.
- Willi B., Boretti F.S., Cattori V., Tasker S., Meli M.L., Reusch C., Lutz H., Hoffman-Lehmann R. (2005). Identification, molecular characterization and experimental transmission of a new hemoplasma isolate from a cat with hemolytic anemia in Switzerland. *Journal of Clinical Microbiology* 43, 2581-2585.
- Willi B., Boretti F.S., Baumgartner C., Tasker S., Wenger B., Cattori V., Meli M.L., Reusch C.E., Lutz H., Hofmann-Lehmann R. (2006). Prevalence, risk factor analysis, and follow-up of infections caused by three feline hemoplasma species in cats in Switzerland. *Journal of Clinical Microbiology* 44, 961-969.
- Willi B., Tasker S., Boretti F.S., Doherr M.G., Cattori V., Meli M.L., Lobetti R.G., Malik R., Reusch C., Lutz H., Hofmann-Lehmann R. (2006). Phylogenetic analysis of "Candidatus Mycoplasma turicensis" isolates from pet cats in the United Kingdom, Australia and South Africa, with analysis of risk factors for infection. *Journal of Clinical Microbiology* 44, 4430-4435.
- Wills T.B., Wardrop K.J. (2008). Pseudothrombocytopenia secondary to the effects of EDTA in a dog. *Journal of the American Hospital Association* 44, 95-97.
- Zini E., Hauser B., Meli M.L., Glaus T.M. (2007). Immune-mediated and megakaryocytic aplasia in a cat. *Journal of the American Veterinary Medical Association* 230, 1024-1027.



Vlaamse land- en tuinbouwbeurs



iedereen wint

13-16 januari 2011

Flanders Expo Gent







www.agriflanders.be

