

Anesthetic and analgesic management of a skunk (*Mephitis mephitis*) undergoing a laminectomy for cauda equina compression

Anesthesie en analgesie voor laminectomie als behandeling van cauda equina compressie bij een stinkdier (Mephitis mephitis)

¹M. Gozalo Marcilla, ²T. Bosmans, ³T. Hellebuyck, ²S. De Decker, ⁴A. Van Caelenberg, ¹S. Schauvliege

¹Department of Surgery and Anesthesia of Domestic Animals, Faculty of Veterinary Medicine, Ghent University, Salisburylaan 133, 9820 Merelbeke, Belgium

²Department of Medicine and Clinical Biology of Small Animals, Faculty of Veterinary Medicine, Ghent University, Salisburylaan 133, 9820 Merelbeke, Belgium

³Department of Pathology, Bacteriology and Poultry Diseases, Faculty of Veterinary Medicine, Ghent University, Salisburylaan 133, 9820 Merelbeke, Belgium

⁴Department of Medical Imaging of Domestic Animals and Orthopedics of Small Animals, Faculty of Veterinary Medicine, Ghent University, Salisburylaan 133, 9820 Merelbeke, Belgium

miguel.gozalomarcilla@ugent.be

ABSTRACT

A 6-year-old, male striped skunk (*Mephitis mephitis*) weighing 5.9 kg was anesthetized for diagnostic imaging procedures and subsequently for a laminectomy at level L6/S1 as treatment of lumbosacral stenosis. On both occasions, anesthesia was induced by a face mask using 5% isoflurane in oxygen. After endotracheal intubation, anesthesia was maintained with isoflurane in oxygen. When necessary, intermittent positive pressure ventilation was instituted.

For the surgical intervention, analgesia was provided with pre-operative carprofen, perioperative intravenous infusion of fentanyl and postoperative buprenorphine. The constant rate infusion of fentanyl provided a sufficient level of analgesia and reduced the amount of isoflurane needed. Hypoxemia occurred at the end of surgery and was successfully treated using a vital capacity manoeuvre. The recovery from both anesthetic procedures was smooth and uneventful and the surgical intervention was successful. Three weeks after surgery the skunk was able to move the pelvic limbs voluntarily.

SAMENVATTING

Een 6 jaar oud mannelijk stinkdier (*Mephitis mephitis*) van 5,9 kg werd onder anesthesie gebracht voor diagnostische beeldvorming en een tweede maal voor een laminectomie ter hoogte van L6/S1, ter behandeling van lumbosacrale stenose. De anesthesie werd telkens geïnduceerd met 5% isofluraan in zuurstof, via een masker. Na endotracheale intubatie werd de anesthesie onderhouden met isofluraan in zuurstof. Wanneer nodig was, werd het dier kunstmatig beademd. Voorafgaand aan de chirurgische interventie werd carprofen toegediend als analgeticum. Tijdens de anesthesie werd een fentanylinfuus gegeven en postoperatief werd buprenorphine toegediend. Het infuus met fentanyl zorgde voor bijkomende analgesie, om de benodigde hoeveelheid isofluraan te verminderen. Hypoxemie trad op op het einde van de ingreep, maar werd succesvol behandeld met een *vital capacity manoeuvre*. Drie weken na de operatie was het dier terug in staat de achterpoten te bewegen.

CASE REPORT

A 6-year-old, male striped skunk (*Mephitis mephitis*), weighing 5.9 kg was referred to the Faculty of Veterinary Medicine of Ghent University with a two-week history of progressive bilateral pelvic limb ataxia and paralysis of the left hind limb, unresponsive to conservative treatment. The neurological examination suggested a lumbosacral spinal cord/cauda equina lesion. It was decided to anesthetize the animal for diagnostic imaging.

Water was freely available, but food was removed 6 hours prior to the anesthetic procedure. After pre-

anesthetic examination and classification as ASA II (American Society of Anesthesiologists), the patient was anesthetized via a face mask using 5% isoflurane (Isoflo, Abbott Laboratories Ltd., Queenborough,, ME11 5EL, Kent, UK) vaporized in oxygen (2 L/min). The induction was smooth and uneventful. Once the jaw tone and eyelid reflexes were lost, lidocaine (Xyllocaine 2%, AstraZeneca NV/SA, B-1180, Brussels, Belgium) was sprayed on the larynx to prevent laryngeal spasm, and a 3.5 mm I.D. cuffed endotracheal tube was placed using a laryngoscope with straight Miller n°1 blade. A 22G intravenous catheter was aseptically placed into the cephalic vein and fluids (NaCl 0.9%,

Viaflo, Baxter S.A., B-7860, Lessines, Belgium) were administered at a rate of 10 mL/kg/hour.

Anesthesia was maintained with isoflurane vaporized in oxygen using a standard 22 mm circle system (Narkosespiromat 656, Drägerwerk AG & Co., 23542, Lübeck, Germany) equipped with pediatric-sized (12 mm) smooth-bore breathing tubes and a pediatric Y piece. Diagnostic imaging procedures were performed over the following 75 minutes. Monitoring included a pulse oximeter (Nellcor Puritan Bennett, INC., Pleasanton, CA 94588, U.S.A.) with the probe placed on the tongue (Figure 1) and an anesthetic gas monitor (Capnomac Ultima, Datex-Ohmeda, FIN-00031, Helsinki, Finland) for the measurement of inspiratory and expiratory oxygen, carbon dioxide and isoflurane concentrations. The patient was allowed to breathe spontaneously until the end-tidal concentration of CO₂ exceeded 8 kPa (50 minutes after the start of the anesthesia), when intermittent positive pressure ventilation (IPPV) was initiated to maintain normocapnia (4.66–6.00 kPa) (10 mL/kg tidal volume, 10 cm H₂O peak inspiratory pressure). The end-tidal isoflurane concentration (FE_{ISO}) ranged from 1.5 to 2.2 vol %. Fifteen minutes after the end of anesthesia, the patient was able to swallow and the endotracheal tube was removed. The recovery was smooth and uneventful, except for minor regurgitation (saliva). The post-anesthetic rectal temperature was 34.5°C (pre-anesthetic temperature was 37.1°C). Surgical gloves filled with warm water were placed in contact with the animal to restore normal body temperature.

Radiographs and CT images revealed a reduced length ($\pm 30\%$) and dorsal displacement of L6 with a narrowed intervertebral disk space between L6 and S1. New bone formation was present at the ventral and lateral aspects of L6. The bony changes were more clearly visible on the CT images. MRI confirmed these changes and showed an additional degeneration and protrusion of the L6/S1 intervertebral disk, resulting in a severe compression of the cauda equina at the caudal aspect of L6 and at L6/S1 (Figure 2). A right lateralized disk herniation of the intervertebral disk with mild compression was also seen. A final diagnosis of lateralized disk herniation at the level of L5/L6 and a generalized lumbosacral disk herniation was made. After the owner's approval, the patient was scheduled for lumbosacral laminectomy with preservation of the articular facets the following day.

Twenty four hours later, following a fastening period of 6 hours (but with free access to water), anesthesia was induced again following the same protocol. After intubation, enrofloxacin 10 mg/kg intramuscularly (IM) (Baytril 2.5%, Bayer NV/SA, B-1050, Brussels, Belgium), carprofen 4 mg/kg subcutaneously (Rimadyl 5%, Pfizer Animal Health S.A., B-1348, Louvain-la-Neuve, Belgium) and NaCl 0.9% intravenously (IV) at a rate of 10 mL/kg/hour were administered. Forty minutes after induction, after the preparation of the surgical field, the patient was transferred to the surgical theatre, positioned in sternal recum-

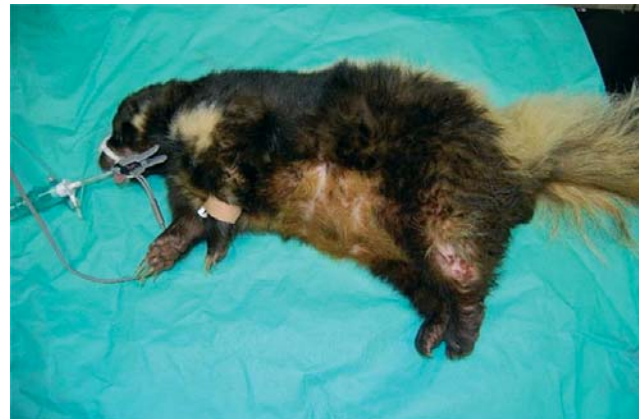

Figure 1. 6-year-old anesthetized male skunk before the surgical intervention (lumbosacral laminectomy). The animal is intubated and a 22 G IV catheter is placed into the left cephalic vein. A pulse oximeter probe is positioned on the tongue. Note the skin lesions of the left hind limb due to the paralysis of this limb.

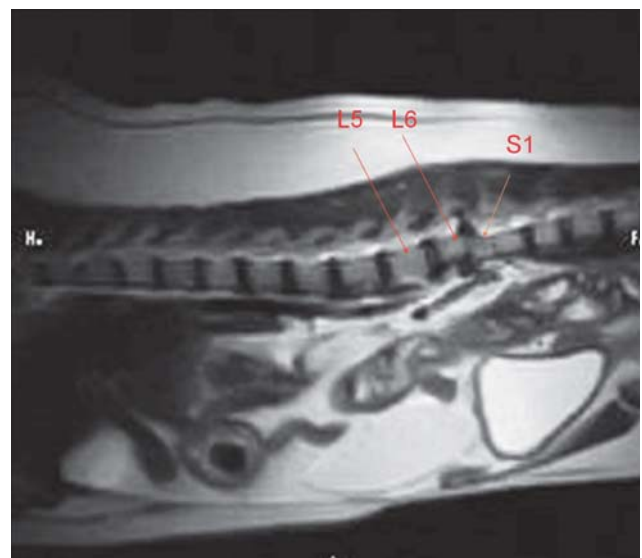


Figure 2. Sagittal T2-weighted MR image: abnormal shape and dorsal displacement of L6. Narrowed intervertebral disk space with subsequent protrusion of the L6-S1 intervertebral disk, resulting in cauda equina compression.

bency on a warmed operating table and connected to an anesthetic rebreathing system. Anesthesia was maintained with isoflurane and fentanyl (Fentanyl-Janssen, Janssen-Cilag, NV/SA, B-2600, Bergem, Belgium) IV (loading dose 1 µg/kg, followed by a constant rate infusion (CRI) at 5 µg/kg/hour, adjusted when needed).

The infusion and monitoring were similar to those used in the first anesthetic episode. Additionally, a 3-lead electrocardiogram (Life Scope 6, Nihon Kohden Corporation, Tokyo 161, Japan) was obtained.

The total anesthetic time was 3 hours 40 minutes. The adjustments of the fentanyl infusion rate (2-10 µg/kg/hour) were based on responses to noxious stimulation, such as an increase in heart rate (after shallow anesthesia was ruled out). The end-tidal isoflurane concentration ranged from 0.95 to 1.8 vol%.

A sudden drop in SpO₂ (below 90%) was observed

20 minutes before the end of surgery. Failure of the pulse oximeter was excluded, so the drop was deemed to indicate a true desaturation. A vital capacity recruitment manoeuvre was applied (closing the pop-off valve and using the reservoir bag to obtain an increased inspiratory pressure of 15 cm H₂O for 3 to 4 seconds), which was successful in restoring SpO₂ in a minimal period of time.

During surgery, abnormalities demonstrated by the medical imaging procedures were confirmed. After completion of the laminectomy, excessive new bone, entrapping a part of the cauda equina, was removed by curettage. The intervertebral disk was not fenestrated.

After skin closure, the patient was allowed to breathe spontaneously and the fentanyl CRI and administration of isoflurane were stopped. After the restoration of spontaneous respiration, buprenorphine 0.03 mg/kg (Temgesic, Schering-Plough NV/SA, Brussels, B-1180, Belgium) was administered IV. The patient was extubated 25 minutes later and transported to a heated cage because of the presence of hypothermia (34.1°C). The body temperature normalized after 5 hours. After surgery, the skunk was treated for 7 days with enrofloxacin (10 mg/kg, BID, orally) and for 3 days with buprenorphine (0.03 mg/kg, IM, TID during the first 2 days and BID during the third day). During the first 2 days the skunk showed signs of pain on manipulation although behavior, drinking, eating, urination and defecation were normal. The patient was discharged from hospital 4 days after the surgical intervention.

Three weeks after surgery, the patient started to improve and gradually regained voluntary motor function in both pelvic limbs. Two months postoperatively, the skunk was able to rise and ambulate independently. Five months after surgery, the skunk still demonstrated a minor intermittent hind limb ataxia. At the moment of writing, 11 months postoperatively, this mild ataxia was still present.

DISCUSSION

Information on anesthetic procedures in skunks is sparse. A number of injection protocols have been described for short surgical interventions, including the removal of the scent glands in young domesticated animals (Fowler, 1978). Intramuscular ketamine, alone or in combination with acepromazine maleate (Ramsden *et al.*, 1976) or xylazine (Carpenter and Brunson, 2007), have been described. Intraperitoneal pentobarbital (Carpenter and Brunson, 2007) and the combination of IM zolazepam/tiletamine (Schobert, 1987) have also been reported. In contrast, more information is available in other mustelids, especially ferrets, which are commonly kept as pets. Biological similarities between ferrets and skunks were considered when formulating an appropriate anesthetic and analgesic regimen in this case.

Both anesthetic procedures were estimated to be relatively long, because the surgical procedure was ex-

pected to be painful. An adequate anesthetic and analgesic plan based on the use of volatiles in combination with pre-emptive, intra- and post-operative analgesia was considered essential in this case.

In general, rapidly acting volatile anesthetics, such as isoflurane or sevoflurane, are preferred for anesthetizing small mammals. Isoflurane can be administered to ferrets via a face mask as previously described (Heard, 2004; Schoemaker, 2002). The use of sevoflurane in ferrets is not associated with significant differences compared to isoflurane (Lawson *et al.*, 2006).

In the present case, 5 vol% isoflurane in 100 % oxygen (2 L/minute) delivered by a face mask was used for the anesthetic induction. This induction technique, used twice within 24 hours, was found to be highly satisfactory, with a good tolerance of the face mask and no signs of distress. The induction time ranged from 3 to 4 minutes in both anesthetic procedures.

After the induction of anesthesia, the intubation was easy to perform using a laryngoscope with a straight Miller n°1 blade after the loss of jaw tone and eyelid reflexes, as reported in ferrets (Longley, 2008). Lidocaine was sprayed onto the larynx to desensitize the arytenoid cartilages and epiglottis in order to prevent possible laryngospasm in response to the endotracheal intubation.

Anesthesia was maintained with isoflurane in 100 % O₂. Inhalation anesthesia presents no special features in ferrets and skunks (Hall *et al.*, 2001). The minimal alveolar concentration (MAC) of isoflurane is usually between 1.5 and 2.0 vol% and the vaporizer settings for isoflurane can vary from 2.0 to 2.5 vol% in small mammals (Heard, 2004). The end-tidal isoflurane concentration ranged from 1.5 to 2.2 vol% in the first diagnostic procedure, but was clearly lower during the second procedure, despite surgical stimulation (FE_iISO ranged from 0.95 to 1.8 vol%), most likely because a balanced anesthetic technique, using a fentanyl CRI, was applied.

An IV catheter should preferably be placed during any anesthetic procedure. Cephalic, lateral saphenous or jugular veins may be accessed for IV catheterization in small mammals (Schoemaker, 2002). In the present case, a 22 G catheter was placed without problems in the cephalic vein after the induction of anesthesia on both occasions.

A standard monitoring protocol including pulse oximetry and analysis of respired gases was used during both anesthetic procedures. Additionally, an ECG device was attached during the second intervention. The blood pressure was not measured due to technical limitations. However, blood pressure measurements are highly informative, especially in hypovolemic patients (Longley, 2008). Indirect methods have been described in ferrets using a pneumatic cuff and ultrasonic Doppler flow detector placed on the digital branch of the radial artery (Lichtenberger, 2004).

Systemic administration of antibiotics is a useful prophylactic strategy prior to major surgery or if contamination of the operative site is anticipated, even in

smaller mammals. Enrofloxacin was administered before the surgical procedure in the skunk based on the guidelines for antibiotic therapy in ferrets (Carpenter, 2005).

Analgesia was provided prior to the surgical procedure with carprofen (Carpenter 2005). Furthermore, a fentanyl CRI was included. Similar to analgesic protocols in dogs (Kästner, 2007) and cats (Mendes and Selmi, 2003), the fentanyl CRI was started initially at 5 µg/kg/hour, and adjusted as needed according to changes in the heart rate. Buprenorphine was administered postoperatively according to doses previously reported in ferrets (Flecknell, 2009). This opioid has a prolonged duration of action in many smaller species and is accepted to control pain of mild to moderate intensity with less respiratory depression compared with full alpha 2-agonists (Lamont and Mathews, 2007).

Although an acceptable level of analgesia based on the assessment of the animal's behavior, posture and appetite was observed in the skunk after surgery, an increase in the dose or frequency of the administration of buprenorphine, or the use of more potent analgesics, such as morphine or methadone, might have been justified, since the skunk still showed signs of pain on manipulation. However, after 2 days this was no longer the case and buprenorphine was given BID the next day.

Pulse oximetry is a reliable method for the non-invasive estimation of arterial oxygen saturation in most species. At the end of the second anesthetic procedure, a sudden drop in SpO₂ was observed. Technical failures caused by incorrect placement of the probe were excluded, so the drop was highly indicative of desaturation. Although desaturation can be induced by numerous factors, regional lung atelectasis resulting in right-to-left shunting of blood is a common problem in anesthetized humans and animals, especially when 100 % oxygen is used as carrier gas (Rosa *et al.* 2006). Although this phenomenon was not confirmed by CT-scan or radiographs in the present skunk, a vital capacity recruitment manoeuvre (Rothen *et al.* 1999) was applied, which was successful in restoring SpO₂ in a minimal period of time, suggesting that any collapsed alveoli were re-expanded by this intervention. The use of a lower inspired percentage of oxygen in skunks might be justified, as recommended in other species to avoid atelectasis (Rothen *et al.* 1995).

Hypothermia often occurs in small mammals, which have a relatively larger body surface area/weight ratio, and is a frequent cause of anesthetic death, since it prolongs recovery time and increases the potency of volatile anesthetics (Regan and Eger 1967). The normal body temperature is reported to range between 37.8 and 40°C in ferrets (Longley, 2008). The pre-anesthetic body temperature of the skunk was 37.1°C. In the present case, low body temperatures were noticed after both anesthetic procedures, stressing the importance that efforts should be made to maintain a physiological body temperature intraoperatively.

CONCLUSION

Anesthesia can be induced in the skunk using isoflurane vaporized in oxygen delivered by a face mask. For surgical procedures, the same volatile agent can be used, preferably with a low % of oxygen as carrier gas. A fentanyl CRI is justified to provide analgesia with a subsequent reduction of the requirement for volatile agents. Finally, efforts should be made to maintain a normal body temperature.

ACKNOWLEDGEMENTS

The authors would like to thank Chris Seymour from the Royal Veterinary College of London for his critical reading of this case report.

REFERENCES

- Carpenter J.W. (2005). Exotic animal formulary. In: Carpenter J.W. (ed.). *Exotic Animal Formulary*. Third edition, Elsevier Saunders, St. Louis Missouri, p. 445-463.
- Carpenter R.E., Brunson D.B. (2007). Exotic and zoo animal species. In: Tranquili W.J., Thurmon J.C., Grimm K.A. (editors). *Lumb and Jones Veterinary Analgesia and Analgesia*. Fourth edition, Blackwell Publishing, Iowa, p. 785-805.
- Flecknell P. (2009). Analgesia and post-operative care. In: Flecknell P. (editor). *Laboratory Animal Anaesthesia*. Third edition. Elsevier, London, p. 139-179.
- Fowler E.F. (1978). Descending carnivores. In: Fowler E.F. (editor). *Zoo and Wild Animal Medicine*. First edition. W. B. Saunders Co., Philadelphia, p. 623-625.
- Hall L.W., Clarke K.W., Trim C.M. (2001). Birds, laboratory and wild animals. In: Hall L.W., Clarke K.W., Trim C.M. (editors). *Veterinary Anaesthesia*. Tenth edition. W.B. Saunders Company, p. 463-479.
- Heard D.J. (2004). Anesthesia, analgesia and sedation of small mammals. In: Quesenberry K.E., Carpenter J.W. (editors). *Ferrets, Rabbits and Rodents. Clinical Medicine and Surgery*. Second edition. Saunders, St. Louis, p. 356-369.
- Kästner S.B. (2007). Intravenous anaesthetics. In: Seymour C., T. Duke-Novakovski (editors). *BSAVA Manual of Canine and Feline Anaesthesia and Analgesia*. Second edition. British Small Animal Veterinary Association, Gloucester, p. 133-149.
- Lawson A.K., Lichtenberger M., Day T., Ko J., Kirby R. (2006). Comparison of sevoflurane and isoflurane in domestic ferrets (*Mustela putorius furo*). *Veterinary Therapeutics* 7, 207-12.
- Lamont L.A., Mathews K.A. (2007). Opioids, nonsteroidal anti-inflammatories and analgesic adjuvants. In: Tranquili W.J., Thurmon J.C., Grimm K.A. (editors). *Lumb and Jones Veterinary Analgesia and Analgesia*. Fourth edition, Blackwell Publishing, Iowa, p. 241-271.
- Lichtenberger M. (2004). Principles of shock and fluidtherapy in special species. *Seminars in Avian and Exotic Pet Medicine* 13, 142-153.
- Longley L.A. (2008). Ferret anaesthesia. In: Longley L.A. (editor). *Anaesthesia of Exotic Pets*. First edition. Elsevier Saunders, Philadelphia, p. 85-95.
- Mendes G.M., Selmi A.L. (2003). Use of a combination of

- propofol and fentanyl, alfentanil or sufentanil for total intravenous anaesthesia in cats. *Journal of the American Veterinary Medicine Association* 223, 1608-1613.
- Ramsden R.O., Coppin P.F., Johnston D.H. (1976). Clinical observations on the use of ketamine hydrochloride in wild carnivores. *Journal of Wildlife Diseases* 12, 221-225.
- Regan M.J., Eger E.I. (1967). The effect of hypothermia in dogs on anaesthetising and apnoeic doses of inhalation agents. *Anesthesiology* 28, 689-700.
- Rosa A.L., Mota P.C., Castiglia Y.M. (2006). Right-to-left shunt determination in dog lungs under inhalation anaesthesia with rebreathing and non-rebreathing system. *Acta Cirurgica Brasileira* 21, 374-379.
- Rothen H.U., Sporre B., Engberg G., Wegenius G., Reber A., Hedenstierna G. (1995). Prevention of atelectasis during general anaesthesia. *Lancet* 345, 1387-1391.
- Rothen H.U., Neumann P., Berglund J.E., Valtysen J., Magnusson A., Hedenstierna G. (1999). Dynamics of reexpansion of atelectasis during general anaesthesia. *British Journal of Anaesthesia* 82, 551-556.
- Schobert E. (1987). Telazol use in wild and exotic animals. *Veterinary Medicine*. 82, 1080.
- Schoemaker N.J. (2002). Ferrets. In: Meredith A., Redrobe S. (eds). *Manual of Exotic Pets*. Fourth edition. British Small Animal Veterinary Association, Gloucester, p. 93-101.



Diergeneeskundige analyses uitgevoerd onder toezicht van **ervaren dierenartsen**.

Een team van **diergeneeskundige pathologen**, zowel voor histologie als cytologie.

Persoonlijke service en klinische interpretatie.

medvet | diergeneeskunde

Emiel Vloorsstraat 9 BE-2020 Antwerpen
 T +32 3 30 30 800 F +32 3 30 30 880
 S www.medvet.be E info@medvet.be

