

Dental pathology in chinchillas

Tandproblemen bij chinchilla's

¹V. Derbaudrenghien, ²A. Van Caelenberg, ³K. Hermans, ²Ingrid Gielen, ³A. Martel

¹ Vetcare Center, Alsembergsesteenweg 439, B-1653 Dworp

² Department of Medical Imaging and Small Animal Orthopedics

³ Department of Pathology, Bacteriology and Poultry Diseases

Faculty of Veterinary Medicine, Ghent University, Salisburylaan 133, B-9820 Merelbeke

v_derbaudrenghien@netcourrier.com

ABSTRACT

Chinchillas are prone to develop a wide range of dental pathologies. The most common one is malocclusion, a condition in which the teeth are misaligned and/or incorrectly positioned in relation to one another. Odontomas, caries, tooth resorption, and periodontal and endodontic diseases have also been reported. This article presents an overview of the specific anatomy and the most common dental pathologies of chinchillas, including the various aspects of the clinical symptoms, diagnosis and treatment of these pathologies.

SAMENVATTING

Tandproblemen komen vaak voor bij chinchilla's. Naast malocclusie worden ook odontoma's, cariës, tandresorptie, periodontale en endodontale ziekten beschreven. In dit overzicht wordt eerst de normale tandanatomie beschreven. Daarna komen de meest voorkomende pathologieën, de klinische symptomen, diagnose en de behandeling aan bod.

INTRODUCTION

Originating from South America, chinchillas were domesticated in the early 20th century. Their natural diet, based on fibrous plants, is optimally digested thanks to a well-developed cecum and coprophagy. Nowadays they have entered our households as pets and gradually became part of the veterinarian's clientele.

While field veterinarians will generally state that oral pathology is widespread in pet chinchillas, prevalence research on the issue is very limited. The most extensive study known so far was carried out by Crossley in 1997 and 1999 in the United Kingdom, where chinchillas are commonly kept as pets (Crossley, 2001). The results of the study are stunning: of the 651 presumed healthy chinchillas subjected to examination, 35% showed external evidence of dental abnormalities. Conscious clinical examination identified a variety of conditions, including palpable deformity of the ventral side of the mandible (39% of the patients), incisor overgrowth (31%) and palpable abnormal cheek teeth occlusion (28%). On radiological examination, incisor elongation, cheek teeth root elongation and coronal cheek teeth overgrowth were found in 100, 94 and 69% of the cases, respectively (Crossley, 1995).

Domestication (including changes of diet, housing and reproduction compared to wild individuals), genetics and trauma are the main factors contributing to dental problems in chinchillas, and unsuitable diets are the number one cause. A market survey carried out by the authors highlighted the fact that none of the cur-

rently available chinchilla feeds in Belgian pet shops meet the specific nutritional recommendations found in the scientific literature. The diets are generally too rich in protein and carbohydrates, with insufficient crude fiber content.

Owners presenting their chinchilla with dental problems on consultation typically complain about lowered feed intake, decreased stool production, reduced activity and weight loss. Consequential to dental problems, secondary pathologies can develop, which often cast a cloud over the prognosis.

Besides external evaluation of the facial and jaw area and intraoral inspection, medical imaging is a must for diagnosing dental pathologies in chinchillas. A usual chinchilla dental radiography protocol includes dorsoventral, right lateral and rostrocaudal views. Computed tomography (CT), magnetic resonance imaging (MRI) and ultrasonography (US) can be used to obtain complementary and/or more detailed information.

Once a diagnosis is established, and if the prognosis is favorable, treatment can be considered. It generally involves drugs, diet change and surgery, if required. The surgery may include trimming, occlusal equilibration and the extraction of teeth. This is done under general anesthesia and should be postponed if the animal's condition is too poor. Possible complications include tooth fracture, hemorrhage, tooth regrowth and post-anesthetic ileus. Therefore special attention must be paid to encourage eating, before and as quickly as possible after intervention. Postoperative care is essential; it consists of the administration of antibiotics

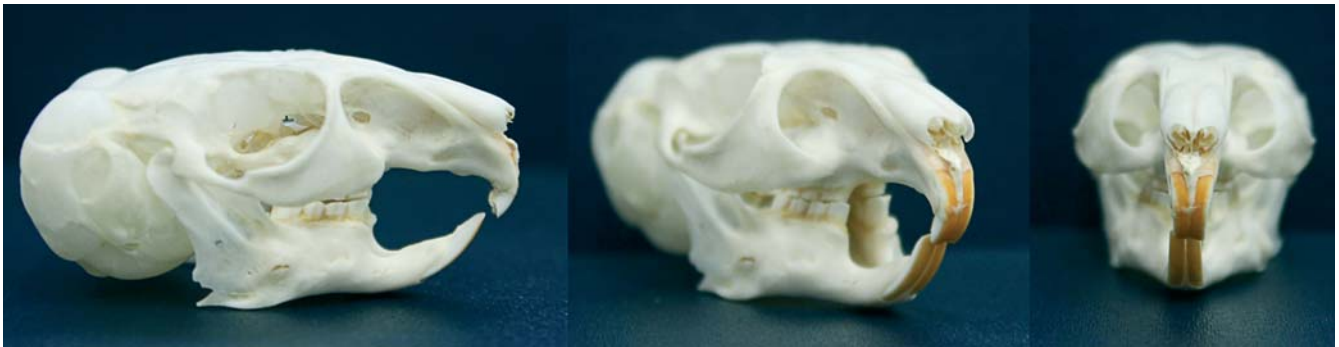


Figure 1. Lateral, oblique rostrocaudal, and rostrocaudal view of a normal chinchilla skull.

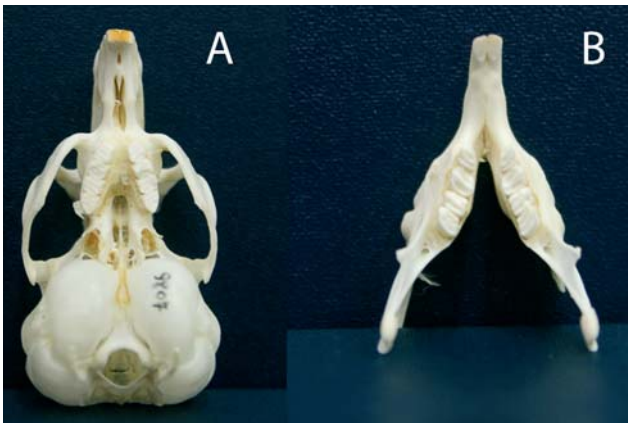


Figure 2. Normal chinchilla. A. Ventrodorsal view of the maxilla - B. Dorsoventral view of the mandibula. The cheek teeth arcades diverge from rostral to caudal.

and analgetics, and often force-feeding.

The determining prognostic factor for dental disease in chinchilla is the stage in which it is diagnosed. Too often, owners are unaware of the problem and animals are presented in end-stage conditions, for which palliative care or euthanasia are the only humane options. In view of this fact, veterinarians have a crucial role to play in raising the awareness of owners and educating them. This should include basic knowledge of the species and its natural habitat, nutritional needs and the importance of hay and gnawing opportunities. A set of preventive measures drawn up for the owners' use is presented in this document.

NORMAL DENTAL ANATOMY

The dental formula of chinchillas is $2(I\ 1/1, C\ 0/0, P\ 1/1, M\ 3/3) = 20$ (Crossley, 1995). They have a monophyodont, full elodont or aradicular hypsodont dentition. A single set of teeth is present during the whole life of the animal, without deciduous precursors (Verstraete, 2003). A full aradicular hypsodont dentition is characterized by incisors and cheek teeth that continue to erupt during the whole life of the animal. Aradicular teeth have no true root structure (Capello, 2008). Hence, chinchilla teeth have long crowns with no anatomic roots. The embedded subgingival tooth segment is called the "reserve crown", as opposed to the exposed or clinical crown (Wiggs and Lobprise, 1997). This 'reserve crown' provides the

necessary tooth material for continuous eruption to compensate the ongoing tooth wear. The aradicular hypsodont teeth in the chinchilla present particular characteristics, perfectly matching their shape and purpose. The periodontal ligament, for instance, does not bridge the entire distance from bone to tooth as it conventionally does. A middle or intermediate bundle of collagen fibers attaches either to the alveolar bone or to the cementum, but not to both. On the whole, the aradicular hypsodont teeth in the chinchilla are less solidly anchored.

This adaptation may possibly provide added tooth movement for growth (Wiggs and Lobprise, 1997; Van Foreest, 1999). Chinchillas have large, chisel-shaped yellow to orange incisor teeth (Figure 1). This pigmentation, not yet present at birth, is due to a superficial layer of enamel (Capello and Gracis, 2005). Teeth discoloration is common and not pathological (Capello and Gracis, 2005). Most rodents, including chinchillas, are simplicidentata with a standard single row of maxillary incisors (Wiggs and Lobprise, 1997). In chinchillas, the radius of curvature of the mandibular incisor is more than double that of the maxillary incisor teeth (Capello, 2008). At rest, most rodents place their lower jaw retrognathically, in so doing, separating their incisor teeth. Chinchillas' incisors grow at a yearly rate of 5.5 to 6.5 cm (Hoefer, 1994). In comparison, this rate is around 2 mm per week for guinea pigs and rats (Osofsky and Verstraete, 2006). A large gap or diastema exists between incisors and premolars. Since it is impossible to anatomically differentiate premolars from molars, they are commonly referred to as "molariforms" or "cheek teeth". The latter have a folded structure with large grinding surfaces, as an adaptation to a voluminous food intake. As a consequence of the chinchilla's strictly herbivorous diet, the occlusal surfaces are rough and uneven, with a succession of enamel crests and dentinal grooves (Figure 2). The cheek teeth are evenly lined up with one another. Unlike in rabbits, the occlusal surfaces are (nearly) horizontal and do not present a "zigzag" pattern (Verhaert, 2004; Capello, 2008). In normal dentition, the mandibular cheek teeth apices should not reach the ventral mandibular border. The maxilla of chinchillas is narrower than the mandible, and the occlusal plane is slightly angled from buccal to lingual. This characteristic, however, is much less pronounced than in guinea pigs (Lobprise, 2007; Sulik, *et al.* 2007). Along with relatively little lateral

movement, the temporomandibular joint tolerates a large range of rostrocaudal motion (Verstraete, 2003). During mastication, the mandibular condyles glide in long gutter-like mandibular fossae, pulled by masticatory muscles, mainly the masseter. There is no subluxation of the articulation during physiological lower jaw movements (Reiter, 2008).

DENTAL PATHOLOGIES

Malocclusion

The condition of malocclusion can be described as a misalignment of the teeth or an incorrect relationship between the maxillary and the mandibular teeth. It is the most widespread and common disorder in strictly herbivorous rodents such as chinchillas and guinea pigs. In chinchillas, malocclusion can be seen in animals as young as 6 months of age (Stroke *et al.*, 1996). As both the incisor and the cheek teeth of chinchillas are continuously growing, one can easily imagine that any disturbance in the normal attrition pattern is potentially an open door to overgrowth problems and malocclusion (Wiggs and Lobprise, 1997). Malocclusion can be limited either to incisors only or to cheek teeth only, or it can involve both incisors and cheek teeth.

Incisor malocclusion

Mandibular incisors tend to grow in a dorsofacial direction, while the intrinsically more curved maxillary incisors logically twist and curl into the oral cavity, which means that the condition of the maxillary incisors can possibly deteriorate to the point where skull, sinuses or ocular sockets are penetrated if the condition is left untreated. As a result of teeth overgrowth, the animal will be unable to eat properly, it will mainly drop its food (“quidding”), and it will traumatise its tongue and have excessive salivation (ptyalism or “slobbers”). In contrast to rabbits, incisor malocclusion seldom occurs as a single entity in rodents. Incisor malocclusion may indeed be either consequential to, or occur alongside premolar-molar malocclusion, especially in older chinchillas, where the condition is generally linked with molariform abnormalities. In view of this fact, a thorough and full oral examination is a real must in patients with incisor malocclusion. Early age incisor malocclusion, generally due to a genetic maxillary brachygnathia, is uncommon in rodents (Verstraete, 2003).

Cheek teeth malocclusion

Cheek teeth malocclusion as a stand-alone problem also occurs in chinchillas (Figure 3). Typically, the reserve crown elongates, with extension of its apical portion into the surrounding periapical tissues. Consequently, distortions of the ventral mandibular border and the maxillary alveolar bullae can be observed (Cappello and Caudoro, 2008) (Figure 4).

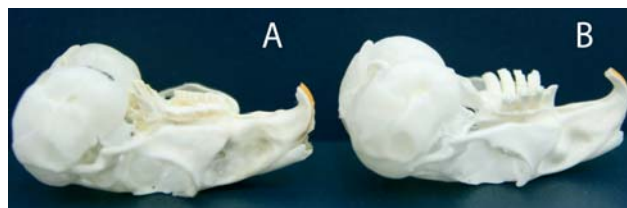


Figure 3. Lateral view of a normal maxilla (A) and maxilla with cheek tooth malocclusion (B) in two chinchillas.

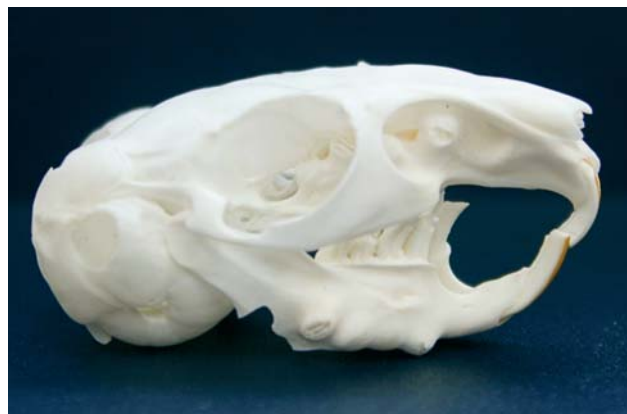

Figure 4. Advanced stage of cheek teeth malocclusion. Jaw of a chinchilla in lateral view. Notice the consequential maxillary and mandibular bulging.

Incisor-molariform or incisor-cheek teeth malocclusion syndrome

Typically occurring in species with full aradicular hypsodont dentition, this dental syndrome encompasses various components that may appear simultaneously:

- incisor malocclusion or elongation
- “step-mouth”, “spikes”: molariform occlusal plane irregularity with sharp points, typically on the mandibular lingual and the maxillary buccal teeth facet
- intraoral molariform elongation, with or without elongation of clinical crowns; possibly lingual or buccal deviation and possibly “bridging” over the tongue
 - apical reserve crown elongation
 - premolar and/or molar periapical changes, with possible cortex perforation
 - periodontal disease, with increased premolar and/or molar mobility
 - secondary soft tissue lesions of the mucosa; oral pain
 - submandibular, maxillofacial or retrobulbar abscesses
 - osteomyelitis (Verstraete, 2003).

These aspects are not necessarily all present; each patient develops its own set of problems.

Periodontal and endodontic disease

Although *Actinomyces viscosus* can induce primary periodontal disease in laboratory rats, this condition is uncommon in rodents, including chinchillas (Wiggs and Lobprise, 1997; Legendre, 2003). Secondary pe-

riodontal disease, on the other hand, can regularly be seen as a result of malocclusion or trauma. Aradicular hypsodont teeth are more susceptible to periodontal loosening (and infection), as the particular periodontal ligament already provides extra tooth movement capacity. In tooth displacement consequent to crown elongation, and occasionally to trauma, the interproximal space is widened, allowing impaction of food and debris (Crossley, 1995). As a result, abscesses easily develop. Damaged incisors can lead to endodontic abscessation, generally extending to the level of the premolars (Legendre, 2003). Infectious processes or trauma in rodents can bring about secondary gingivitis, stomatitis with ulceration, and periodontitis (Van Foreest, 1999).

Oral trauma

A large range of oral fractures are described in chinchillas, varying from simple mandibular symphyseal dislocation to complex jaw fractures with involvement mainly of the incisor teeth. Oral fractures are generally caused by gnawing on hard objects (Legendre, 2003).

Less common dental pathologies

Caries, tooth resorption and odontomas have also been reported to occur in chinchillas (Crossley *et al.*, 1997).

Caries appears as areas of brown staining on the occlusal and/or interproximal tooth surfaces, resulting from pigment uptake by the altered dentine. These lesions are much more common in captive animals than in wild animals, probably as a combined result of diet, salivary pH and tooth anatomy. Commercially available chinchilla foods generally have much higher sucrose and refined starch contents than the diets of wild animals (Legendre, 2003). However, in chinchillas caries remain less common than other dental problems. Some authors suggest that continuous molariform growth and consequential constant attrition reduces the occurrence of caries simply because the occlusal surface is worn away too quickly for caries to occur (Sone *et al.*, 2004).

Odontoclastic tooth resorption is set off by periodontal inflammation. Initially, lacunae appear in the tooth, into which granulation tissue moves in an endeavor to promote healing. Although repair sometimes is done, the lost dentin is never replaced. Instead, a composite of bone-like and cementum-like tissue fills in the gap, with a resulting ankylosis of the tooth to the jaw. The presence of deep periodontal pockets in many specimens with this condition shows that the animals have been affected by several episodes of inflammation of the periodontal ligaments, which occurs during the development of malocclusion. Hence, it could be concluded that this periodontal inflammation triggers odontoclastic resorption. However, the true pathogenesis has not yet been determined and other hypotheses remain plausible, including the possibility that the

periapical bone remodeling needed to allow reserve crown elongation could accidentally be redirected towards the tooth itself (Crossley 1997). Mandibular abscesses are regularly seen in end-stage dental disease (Figure 5).

Odontomas are neoplastic processes in which well differentiated epithelial and mesenchymal cells of all different dental tissue types can be identified. These

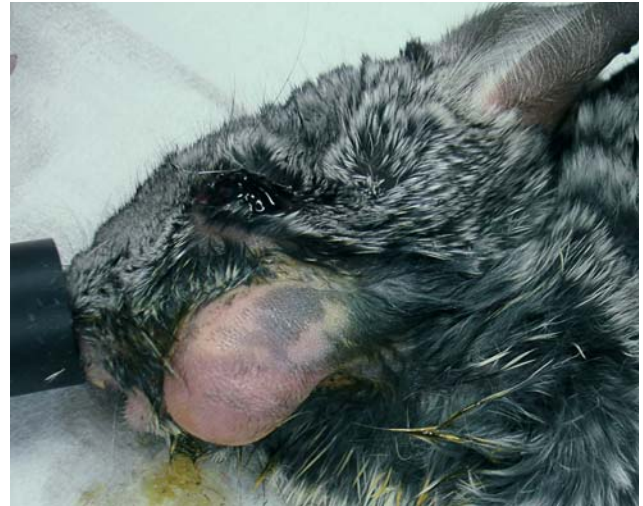

Figure 5. Chinchilla in end-stage dental disease, showing a mandibular abscess. External aspect after shaving of the left cheek.

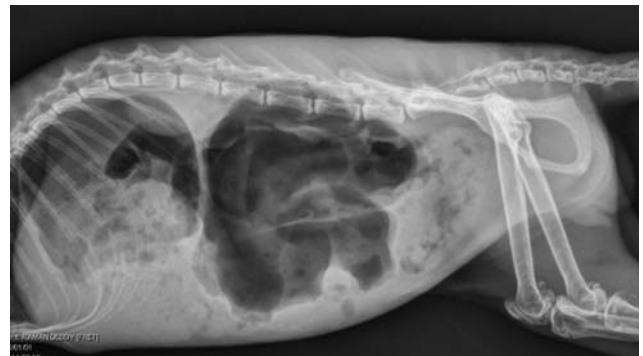

Figure 6. Latero-lateral x-ray of a chinchilla with gastrointestinal stasis, impaction and tympani secondary to dental disease.



Figure 7. Chinchilla with the "slobbers" condition.

tumors of odontogenic origin have been diagnosed in young rodents, but are generally rare in chinchillas (Wagner *et al.*, 1999).

Pathologies secondary to dental disease

As chewing becomes too painful or impossible, anorexia progressively appears, with subsequent weight loss seen in 79% of the animals. Since the animals reduce their fiber intake or, worse, fail to eat, the digestive system cannot function properly. Fecal droppings typically become smaller; tympany and constipation can occur (Figure 6). Oral discomfort or pain, abnormal occlusion and/or restricted jaw movement induce excessive salivation (“slobbers”), which brings about perioral and forelimb saliva staining, and/or perioral skin disease (Crossley *et al.*, 1997) (Figure 7). Maxillary reserve crown elongation can specifically cause pressure, deformation and even obstruction of the bony lacrimal canal (Crossley and Roxburgh, 1999). Tears are not evacuated, which results in epiphora and altered periorbital hair patterns. Moreover, secondary eye pathology and periocular skin disease can develop (Anonymous, 1988; Crossley, 1995). Reserve crowns occasionally grow into the orbital area, inducing local inflammation, possible retrobulbar abscedation and exophthalmia.

FACTORS PREDISPOSING TO DENTAL DISEASE

Various factors, including husbandry and genetic and traumatic influences, have been identified as playing a role in the development of dental problems in chinchillas.

Insufficient or incomplete cheek tooth wear as a result of an unsuitable diet is the primary cause of dental pathology in chinchillas (Capello, 2008). In captivity, these rodents are habitually fed with grain or pellets, and their access to hay is generally limited. The vegetal ingredients processed in these feeds are cultivated under far more optimal conditions than the vegetation found in their natural mountain environment. The mountain vegetation is more fibrous, tougher, con-

taminated with soil and richer in silicate phytolith, all increasing its abrasive character. All of this means that the commercial diets are much higher in energy and lower in fiber content. Wild animals need to consume large volumes of the relatively low-energy mountain vegetation to meet their nutritional requirements. As animals in captivity chew smaller quantities of less abrasive food, dental elongation can appear. All recommendations regarding the specific requirements for chinchillas point in the direction of high overall dietary fiber content. On a dry matter basis, the pellets should contain 18 to 20% crude protein, 15 to 35% crude fiber and 4% fat (Hand and Thatcher, 2000). Crude fiber structure should be taken into consideration, as well-structured feeds increase the level of ingestion activity and feeding, with positive impact on attrition rates (Wolf *et al.*, 2003). A large variety of pellets, treats, mineral supplements and hay are available for the consumer to choose from. Within the framework of this article, a market survey of foods specifically available for chinchillas in Belgium was carried out (Table 1). Only feeds labeled on the package as “complete foods” were considered. Products available on the internet were not surveyed.

When comparing the nutritional composition of these feeds to the above mentioned advised requirements, it appears that none of the pet foods for chinchillas available in Belgium meet the above standards. All feeds are either lacking in the crude protein and crude fiber that are essential to avoid or limit dental problems, or they barely reach the lower limit of the requirements. “Chinchilla Complete[®]” and “Pellets[®]” are the only ones providing reasonable amounts of crude fiber. Among the feeds available, only half of them (“Chinchilla Complete[®]”, “Pellets[®]”, “Selective[®]” and “Chinchilla Duo[®]”) contain similarly looking pellets. The pellets in the others have a heterogeneous appearance, with various different ingredients the animal can consciously choose between. Practically, this translates into chinchillas eating a lot of high-starch and sucrose components, and leaving the harder and less tasty bits, such as alfalfa pellets, behind. This results in a dramatic drop in the overall crude fiber intake, espe-

Table 1. Overview of the nutritional composition of chinchilla foods available on the Belgian market (May 2009).

Brand	Versele laga				Vitakraft	Supreme Pet Foods		Beduco	Recommended requirements
Commercial name	Chinchilla complete	Chinchilla Nature	Snack Nature	Chinchilla Duo	Pellets	Charlie Chinchilla food	Selective	Deli Nature	
Nutritional composition (% of dry matter)									
Crude protein	16	14.5	11	15.5	16	16	16	16	18 to 20%
Crude fat	3.5	3	3	3	2.8	3	3	3	4%
Crude ash	8	7	3	9	10	7	7	6	-
Crude fiber	20	14	10	16	18.5	16	19	14	15 to 35%
Target animal	Chinchilla	Chinchilla	Chinchilla Rabbit Guinea pig	Chinchilla Degu	Chinchilla	Chinchilla	Chinchilla	Chinchilla	

cially if the owners refill the feeding pot, throwing away the leftovers. Finally, none of the packages provide guidelines regarding the daily recommended quantities to provide, nor is anything mentioned concerning the importance of providing hay.

Chinchillas, as all rodents, need to have access to various materials they can chew on without risk of trauma. In addition to their indispensable wearing effect on the teeth, these gnawing opportunities will contribute to increased general activity levels and to avoiding boredom and its related stress. In chinchillas, stress is typically exteriorized in “fur-chewing”, a behavioral condition in which the animal bites off areas of its own or some other animal’s fur (Ponzio *et al.*, 2007).

The domesticated chinchilla was established out of a very small original group of 11 wild-caught individuals exported from Chile to California in 1923 (Tremblay, 2000). In this situation, the founder effect must probably be considered to be a significant factor. This translates into a loss of genetic variation, which has an effect on gene frequency and the prevalence of genetic diseases. In this small population, one can assume there is an increased risk for genetic drift and inbreeding. Tooth development being in some degree genetically controlled, genetic drift could explain the higher incidence of dental problems in captive-bred animals (Kraft, 1994; Silverman and Tell, 2005).

Every so often, dental problems can be triggered by trauma. This can bring about dental tissue damage, including tooth bud relocation. Subsequently, the corresponding lower and upper teeth are no longer correctly aligned, and abnormal tooth elongation can appear. Most commonly, the incisors are affected (Reiter, 2008).

DIAGNOSING TOOTH PROBLEMS IN CHINCHILLAS

History

Although early identification is crucial, detecting dental conditions in chinchillas is tricky, even more so for non-trained or non-experienced owners. On the one hand, most signs of dental disease in rodents are non-specific and difficult to see; on the other hand, patients with tooth abnormalities can be asymptomatic during the initial phases of the disease. Commonly, chinchillas indeed show clinical signs only in an advanced stage of dental disease (Crossley, 1995; Brenner *et al.*, 2005). In view of this fact, regular follow-up and education of owners by the veterinarian are essential in early diagnosis. In order to identify oral disorders, the history should cover various aspects such as:

- housing: type of housing, risk of trauma, recent changes
- feeding habits: food type(s); quantities and frequency, recent changes in feeding habits
- eating patterns: quantities eaten (overall and of each type of food), leftovers, changes in preference of foods/ingredients, changes in chewing patterns

- defecation: changes in quantity, shape and aspect of droppings
- general health: disease history, weight loss, salivation, ocular discharge, fur changes.

General clinical symptoms

Reduced activity, lower food intake and decreased stool production are by far the most common signs of dental disease in chinchillas. In addition, wet fur around the mouth, chin and forepaws can be observed as a result of pain-induced increased pawing and ptyalism (Capello and Gracis, 2005). Initially, the animal may have a selective appetite, generally preferring softer bits and leaving out high fiber content foods (Hofer, 1994). When chinchillas receive mixed pellets, for the owner, this early stage may practically mean finding more alfalfa pellets as leftovers. Some animals present bruxism or teeth grinding due to discomfort (Crossley, 1995). Frequent later sequels of dental disease in chinchillas are weight loss and emaciation, however hard they are to detect in this densely-furred animal, where only regular weighing ensures effective weight follow-up (Capello, 2008). Yet another factor makes the discovery of the problem even harder. Animals with sore teeth, jaws or oral mucosa are often unable toprehend, chew or swallow food properly. As the chinchilla’s painful eating attempts generally result in food scattering, the bowls do become empty, despite the very low food intake. While food intake decreases, fecal droppings initially become smaller. Later, fecal output may totally cease (Crossley, 1995). Chinchillas with teeth problems no longer use their mouth for grooming, with the resulting dull-looking and tangled fur.

Clinical examination

As the physical presentation of a condition involving the teeth can vary, a holistic approach, including an assessment of the general condition, external evaluation of the facial and jaw area and, finally, intraoral inspection, is essential for a correct screening of the animal.

Weight loss is the most frequent sign identified during general physical examination. A thorough visual inspection of the facial area and the jaw should include:

- overall shape and symmetry of the head and mouth
- position of the mandible and mouth opening, and observation of the masticatory movements
- external appearance of the incisors
- nasal plateau and perinasal area
- position and shape of the eyes, the periocular area.

Following inspection, a careful maxillofacial palpation should be done, including evaluation of the mandibular lymph nodes, mandibular/sublingual glands, zygomatic arch, orbit, temporomandibular joints and mandibles. For the mandibles, special attention should be given to evaluating the surface for bone deformities. Incisor and cheek teeth occlusion as

well as jaw movement capacity must also be evaluated (Capello and Gracis, 2005). Chinchillas are known to be pretty tough rodents with quite high pain thresholds. The absence of pain reaction when examining the animal can in no circumstance exclude a dental condition. Epiphora and ventral mandible bone deformities, on the other hand, are two typical clinical signs that, in the vast majority of cases, will direct the clinician towards dental problems. These symptoms are indeed typical telltale signs of maxillary and mandibular cheek teeth deformation, respectively (Capello, 2008). Epiphora is due either to obstruction of the lacrimal canal or to pain-induced increased tear production (typically with mucosal or bone pain). It can appear as a stand-alone symptom or be accompanied by exophthalmos and/or conjunctivitis. These two conditions develop when the orbit floor and the zygomatic process of the maxilla become involved. In this case, severe ptialism is often noticed (Crossley *et al.*, 1997). Dacryocystitis – or nasolacrimal sac infection – can appear secondary to lacrimal canal obstruction, provoking pain, swelling of the inner lower eyelid and epiphora. Commonly, these infections are associated with *Staphylococcus aureus*, *Streptococcus pneumoniae* or *Pseudomonas* species. Blepharospasms with partial closing of the eye are sometimes present (Capello and Gracis, 2005). In any case, ocular (or nasal) discharge should include dental disease in its differential diagnosis (Crossley, 1995). Regularly found on clinical examination, facial abscesses appear as unilateral swellings. It is generally taken for granted that a cheek tooth is responsible, whereas in chinchillas, incisor-related endodontic abscedation can actually reach up to the premolar level (Legendre, 2003).

Oral inspection of the conscious chinchilla is complicated by the animal's size (small mouth opening, narrow oral cavity, long tongue) and the fact that it is rather difficult to restrain. Although it may possibly result in a lot of struggling, escape endeavors and fur slips, oral inspection should however be attempted during every physical examination as a first step in evaluating the oral health of the animal. To do so, the chinchilla is ideally restrained in physiological standing position and examination is performed by means of an otoscope or a lighted bivalve pediatric speculum, carefully inserted in the mouth (Osofsky and Verstraete, 2006). If the patient is too agitated, it should be deeply sedated or anesthetized (for information on sedation and anesthesia, please see below). Nevertheless, the procedure remains difficult, and this probably accounts for the small amount of information available describing dental lesions in chinchillas. When the animals are anesthetized/sedated, incisor speculums and cheek pouch dilators of the smallest size can be used in chinchillas for optimal visualization (Brenner, *et al.* 2005; Capello and Gracis, 2005) (Figure 8). Once the instruments are in place, feed residues are first removed. A proper examination of the oral cavity is done by systematically inspecting each quadrant and tooth. The use of periodontal probes is questionable, because of the trauma they can induce (Verstraete, 2003; Brenner, *et*

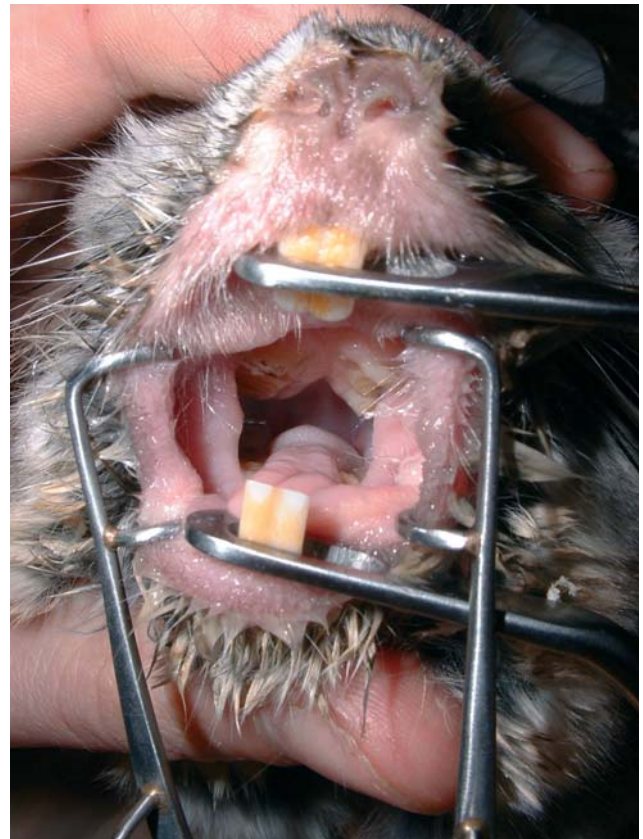


Figure 8. Oral exam of an anesthetised chinchilla; pouch dilator and incisor speculum in place.

al. 2005). Intraoral examination should include checking:

- the integrity and mobility of each single tooth
- the appearance of the occlusal surfaces: enamel crests, dentinal grooves, spikes, occlusal angle
- the orientation and length of the clinical crowns, the size of the interproximal spaces, the feed impaction
- the presence of periodontal pockets, the appearance of the periodontal tissues.

In Crossley's study (Crossley, 2001), incisor overgrowth was found in 55% of the cases. In one-third of the affected animals, abnormal incisor wear patterns could be identified, when in cheek teeth this was only the case for 16% of the patients. Less than 10% of the chinchillas examined showed spikes and feed impaction (Crossley, 1995). The clinical examination might be misleading, and a relatively minor molariform malocclusion should be considered an important clinical finding.

Anesthesia

Dental interventions on chinchillas require general anesthesia to control stress and pain, to minimize operation time and to allow the surgeon to work in the safest conditions possible. A pre-anesthetic evaluation is highly recommended. Especially in very weak patients, full-body radiography can help in evaluating the overall condition and, more specifically, to see if there is secondary gastro-intestinal stasis. In the event of an inconclusive pre-anesthetic evaluation, and if an animal

is too debilitated to undergo surgery, this surgery should be postponed when possible. Post-anesthetic ileus is a common complication in rodents, therefore long-lasting fasting is contraindicated and special attention should be given to encourage the animal to eat, both before and as quickly as possible after the intervention. In any case, fasting should not exceed one hour in young chinchillas to avoid hypoglycemia. Due to their small size and difficult or impossible intubation, it can be difficult to induce anesthesia in rodents. Longer and more intrusive procedures require inhalation anesthesia after induction. This method implies the use of a tight-fitting anesthetic mask, which is repeatedly put on and off, thus both enabling anesthesia of the animal and enabling the surgeon to work (Osofsky and Verstraete, 2006). A small nasal mask can possibly be used. Injection anesthesia does not allow fine, quick control over the anesthetic depth and it also requires a mask for the oxygen supply. The following anesthesia protocols can be used (Carpenter, 2005):

isoflurane 2-5 % induction; 0.25-4.0% maintenance (anesthesia of choice/or short interventions)

ketamine 40 mg/kg + Acepromazine 0.5 mg/kg IM
ketamine 20-40 mg/kg + Diazepam 1-2 mg/kg IM

The consequential shortcomings such as prolonged surgery time, risk of inhalation of the anesthetic gas by the operator, and potential unnecessary pain and stress for the animal can be bypassed through nasal intubation (Legendre, 2003). The monitoring of rodents during anesthesia should focus especially on respiration, heart rate and body temperature. Hypoventilation and apnea are common; satisfactory ventilation can be maintained by adjusting the head position and anesthetic depth. Insufficient anesthesia increases pain and stress, which often translates into tachycardia. Heat packs ought to be used, as small animals are prone to hypothermia (Osofsky and Verstraete, 2006).

Medical imaging

Studies have shown that during mouth inspection in conscious and in anesthetized rabbits, respectively, only 35 and 50% of oral lesions are detected. Chinchillas and guinea pigs are no exception to this rule. Disregarding the fact that visual observation is complicated by the small oral cavity and the narrow mouth opening, one should keep in mind that the tooth portion that is actually visible above the gingival margins (i.e. the clinical crown) represents only a small part of the tooth, the tip of the iceberg. Most of the tooth structure is located below the gingival margin and is not visible during oral examination (Crossley and Miguez, 2001; Lobprise, 2007). In view of this fact, medical imaging is an absolute must in diagnosing and understanding dental pathology in rodents in general, and in chinchillas in particular (Gracis, 2008). The imaging techniques used currently in rodent dentistry include oral endoscopy, radiology, computed tomography and magnetic resonance imaging. Unless the animal is really calm and used to physical manipulation, sedation or anesthesia is preferable for precise and effective den-

tal medical imaging (Brenner *et al.*, 2005).

In comparison with direct visual inspection, images obtained through oral endoscopy are of much better quality and the capacity for detecting oral lesions is greatly enhanced. Chinchillas are ideal candidates for oral endoscopy as the horizontal occlusal surface facilitates the examination. This examination includes thorough inspection of the appearance of the gingival and oral mucosa, the length of the cheek teeth clinical crowns, the appearance of the occlusal surface, the size of the interproximal space, and the appearance of each tooth. Abnormalities such as crown elongation, alteration of the enamel crests and dentinal grooves, lingual or buccal deviation of the cheek teeth (with or without lesions of the mucosa), and widening of the interproximal spaces with consequent feed impaction can be seen (Capello and Gracis, 2005). At present, radiography remains the principal diagnostic tool. Various lesions such as dental resorptive lesions, bone resorption and lysis, cortical perforation, apical elongation, tooth fractures and missing teeth can be properly diagnosed with it. However, it is important to emphasize the fact that a normal radiography does not exclude the presence of pathologies. Small or specific hard tissue lesions can indeed be missed, though still found on autopsy (Gracis, 2008). Magnification radiography techniques, using units with small focal spots (0.1mm) and a 100-mA capacity can compensate for size. A usual chinchilla skull and dental radiography study includes right lateral, dorsoventral and rostral-caudal views. An ideal laterolateral (LL) positioning results in a perfect overlapping of the left and right tympanic bullae, optic foramen, orbits, temporomandibular joints and ventral mandibular margins (Verstraete, 2003; Gracis, 2008). In the LL projection, seen by the majority of authors as the most useful one, both incisor and cheek teeth are evaluated. The maxillary incisors' reserve crown should not reach further than two-thirds of the length of the diastema, while that of the mandibular incisors ought not to grow beyond the second cheek teeth (Wiggs and Lobprise, 1997). The incisors occlusal surface is normally chisel-shaped; the wearing angle is generally more pronounced in maxillary teeth. Flat occlusal surfaces are indicative of dental disease and/or intervention. Possible maxillary incisor hard palate perforation consequent to overgrowth can be seen on this projection (Capello and Gracis, 2005; Gracis, 2008). Typically, the chinchilla cheek teeth occlusal plane should be flat, nearly horizontal and parallel to the ventral mandibular border on a LL projection. The surface should form a regular smooth palisade. In order to evaluate whether the animal is suffering from maxillary cheek tooth elongation, a virtual line is drawn from the tympanic bullae hilus to the dorsal aspect of the maxillary incisor tooth (Figure 9). Apices above this line are indicative for disease. Mandibular cheek teeth apices reach close to the ventral mandibular cortex, which should be thin, smooth and without deformities. The presence of bone deformities or so-called "bulging" is extremely suggestive for mandibular cheek teeth elongation. Finally, the loss of pa-

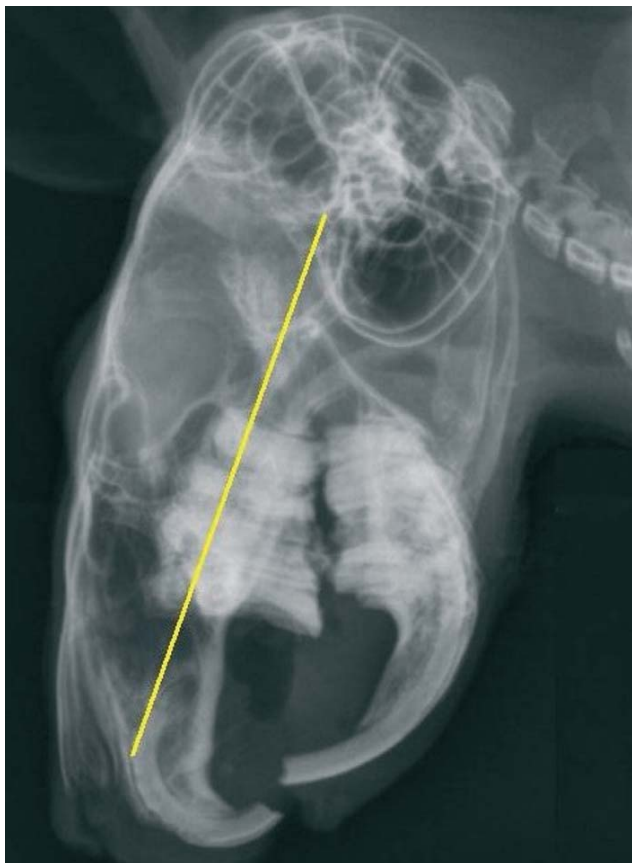


Figure 9. Radiograph of a chinchilla skull with graphic overlay, showing the above limit for maxillary teeth apices.

parallelism between the maxillae and mandibles in this view is a third indicator for coronal elongation (Figure 10). Dorsoventral (DV) projections generally are favored over ventro-dorsal (VD) because they are done in ventral recumbency, thus decreasing respiratory complication risks. Good quality DV radiographies should have a perfect symmetry (between the right and left sides of the skull). Through this projection, the maxillary and mandibular bone edges as well as the skull-mandible connection and the orbital cavities can be properly evaluated. Abnormalities such as cheek teeth elongation or orientation changes can be quite easily pointed out (Figures 11 and 12). On the other hand, DV views are not suitable for incisor evaluation. Rostrocaudal (RC) projection is taken with animals in dorsal recumbency (Verhaert, 2004; Capello and Gracis, 2005). The mouth is closed and the head straightened up at an angle of 90°C. Bohmer suggests open-mouth RC for specific assessment of maxillary cheek teeth overgrowth and temporomandibular joints (Bohmer, 2001a, 2001b). RC views provide valuable complementary information, facilitating a three-dimensional understanding of the possible pathology. The existence of spurs and spikes, bridging, coronal and apical elongation, or cortical perforation can be highlighted, and the angles of the cheek teeth and the occlusion surface area can be measured.

The small size of these rodents combined with the dental quadrant superposition increase the difficulty of

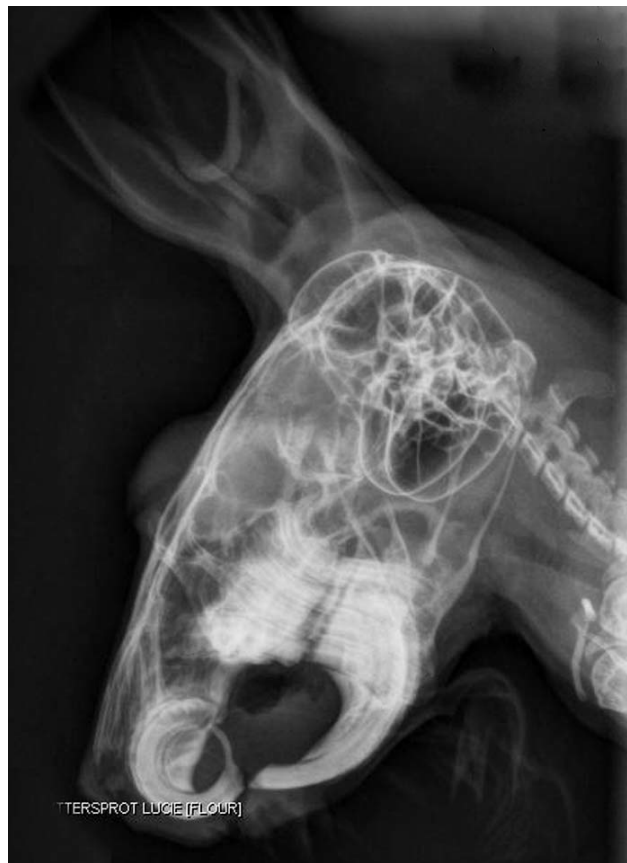

Figure 10. Lateral view of a chinchilla with pronounced cheek teeth and incisive teeth malocclusion. At the level of the cheek teeth abnormal occlusal plane, abnormal delineation and growth direction of the cheek teeth roots, and bulging and thinned mandibular cortices were seen. Severe maxillary incisor curling with crowns and roots impinging on the hard palate.

radiologic interpretation. For this reason, two obliques (left and right) as well as intraoral projections are recommended for an in-depth evaluation of the mandibles, maxillae and teeth (Verstraete, 2003; Gracis, 2008). Lateral oblique (LO) views are useful for evaluating the mandibular and maxillary cheek teeth apices and reserve crowns. The mandibular cheek teeth of one side (closest to the film) and the contralateral maxillary cheek are visualized. Individual incisor apices are generally clearer in this projection than on the LL. Intraoral projections, where non-screen films are placed directly in the mouth of the patient, are also mentioned in the literature. This technique generally provides radiographies with very fine resolution and high diagnostic value (Verhaert, 2004; Capello and Gracis, 2005; Gracis, 2008). However, to properly place small films in the equally small oral cavities of chinchillas is a real challenge, and it sometimes cannot be done.

Even though radiography remains the primary diagnostic tool in chinchilla dentistry, it often fails in the early detection of pathologies such as cheek tooth elongation. The reasons for this shortcoming lie essentially in the difficulty of avoiding superposition when taking skull x-rays, as well as in the insufficient detail

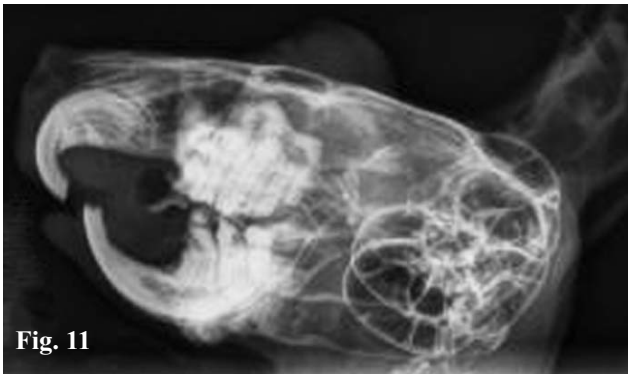


Fig. 11

Figures 11 and 12. Lateral and dorso-ventral view of a chinchilla with extensive overgrowth of the mandibular and maxillary cheek teeth, spike formation and secondary incisor teeth pathology and exophthalmia.

and soft tissue contrast it produces, which does not enable the detection of the subtle tissue changes of early-stage dental disease (Crossley *et al.*, 1998; Capello and Caudoro, 2008). Nonetheless, despite the fact that chinchillas will often only show clinical signs in a quite advanced stage, early diagnosis remains absolutely crucial. Furthermore, early screening and consequent breeding pool selection paves the way to a healthier future chinchilla population (Crossley *et al.*, 1998). Various studies have highlighted the improved diagnostic capabilities of CT in comparison with traditional radiography for rabbits and rodents, including chinchillas (Gracis, 2008). Especially in small species such as these, CT offers:

- enhanced sensitivity, especially for temporomandibular joints and tympanic bullae
- greater capacity to detect fine or nearly imperceptible skeletal changes
 - a much higher level of detail of the teeth
 - a higher level of detection of both soft and hard tissue modifications (Brenner *et al.*, 2005; Crossley *et al.*, 1998).

CT of a normal chinchilla skull allows clear visualization of the mandible, maxilla, zygomatic arch, temporomandibular joint, parietal and nasal bones, tympanic bullae, sinuses and teeth. Abnormalities such as coronal and root elongation, deformities and/or perforation of the cheek bone, as well as caries can be seen even in the early stages (Capello and Caudoro, 2008) (Figure 13). Moreover, the three-dimensional reconstruction and rendering features of modern CT are highly valuable for the additional information they provide that is relevant for diagnosis and treatment, as well as for educating the owners (Capello, 2008). Finally, MRI and US are used every now and then for the specific evaluation of soft tissues such as muscles, salivary glands and the orbital area (Gracis, 2008). In comparison with MRI and CT, US offers the double advantage that it is relatively cheaper and it is more applicable to field conditions. Despite the obvious advantages presented by modern medical imaging, these techniques are unfortunately still scarce and generally only available in research or university structures, and

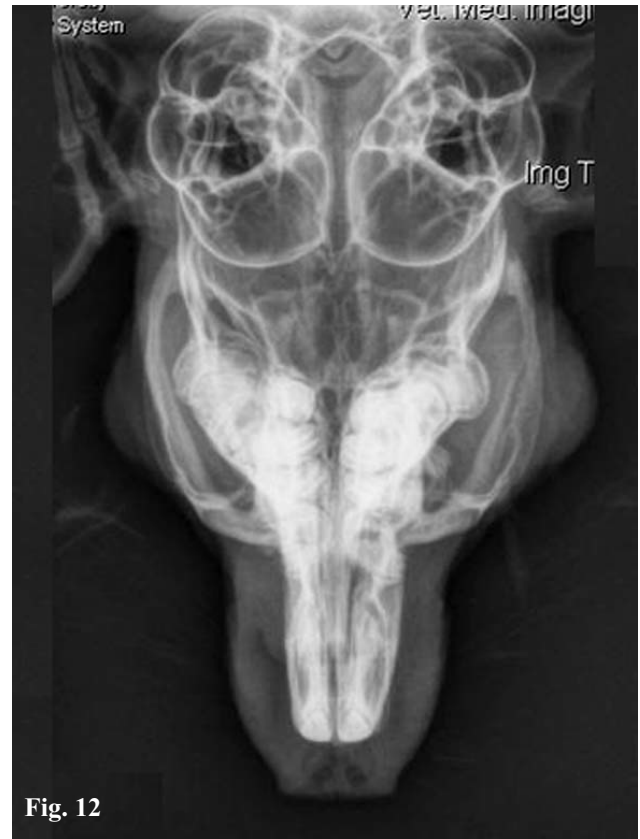

Fig. 12

even there the higher cost is often a major hindrance (Brenner *et al.*, 2005; Gracis, 2008).

TREATMENT

Incisor teeth treatment

Before addressing incisor tooth problems in chinchillas, it is crucial to bear in mind that incisor overgrowth seldom appears as a stand-alone problem in rodents. In any case, a thorough mouth examination needs to be carried out to identify possible underlying causes and allow a correct diagnosis and prognosis.

In the case of overgrowth, or when they are partially broken as a result of trauma, incisors need trimming or tooth-height reduction (Legendre, 2003; Capello and Gracis, 2005). Prior to trimming, and with the aim of avoiding injury to the soft tissues of lip and tongue, a split tongue depressor is positioned caudally to the incisors, in the diastema space (Legendre, 2003). Tooth-height reduction of incisors is ideally carried out with a cylindrical diamond bur fitted onto a high-speed dental handpiece. Dremel® tools or cutting disks mounted on a surgical handpiece are to be avoided, as they are oversized and easily induce soft tissue trauma. Cutters or nail clippers are contraindicated as they often induce diagonal fractures and tooth splitting, possibly with pulp exposure (Legendre, 2003). This very painful consequence can lead to periapical pathosis (Verstraete, 2003). Reduction ought to be performed delicately to avoid too extensive trimming and, above all, thermal damage to the pulp. When nasal intubation is used, cooling fluid can be considered on condition

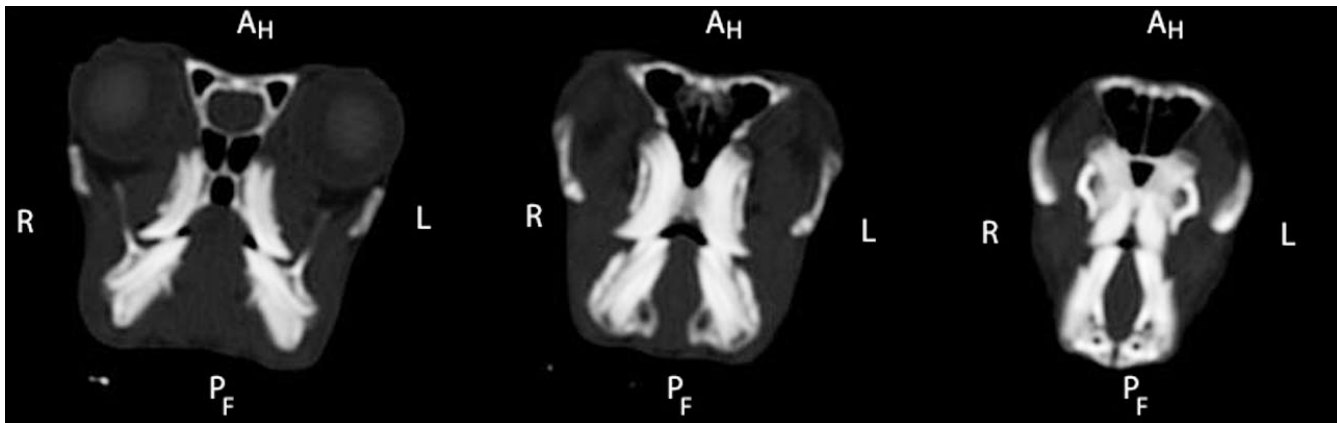

Figure 13. CT of the skull of a chinchilla with extended cheek teeth overgrowth. CT images (from left to right, taken from the nares to the orbital area) show elongation of maxillary and mandibular cheek teeth roots, the presence of cheek teeth spikes in both the labial and the buccal directions, and thinning of the mandibular cortex.

that the oropharynx is packed. While trimming, it is important to restore the incisors' normal chisel-shaped occlusal angulation in order to restore them to the most normal condition possible. This procedure is carried out on the basis of need, generally every 3 to 6 weeks. Pulpal exposure is a possible complication of the intervention, which requires partial pulpectomy and pulp capping. The pulp cavity opening is filled with intermediate restorative material (IRM[®], Dentsply International, York, USA). Composites or other harder fillings are not recommended as they disturb the physiological tooth abrasion (Lobprise, 2007). In some cases, incisor malocclusion or overgrowth cannot be corrected by trimming alone, or the required intervention frequency to achieve an acceptable condition is not feasible. In these circumstances, although far more seldom than in rabbits, incisor extraction can be considered in chinchillas (Lobprise, 2007; Capello, 2008). Due to the very long incisors, the intervention is often tricky but can generally be done via non-surgical extraction (Verstraete, 2003; Osofsky and Verstraete, 2006). As for any other tooth, extraction is based on luxation. A small luxator or a bent hypodermic needle of appropriate size is brought carefully into the periodontal space. Once in place, a constant pressure is applied in the apical direction for 20 to 30 seconds. This procedure is alternatively repeated at the mesial and distal tooth facet, i.e. the sides of the teeth. Wiggling of the tooth should be avoided as this is precisely the type of effort that the periodontal ligament is designed to resist. Gradually, the luxator moves deeper and deeper, the periodontal ligament ruptures and the tooth becomes loose (Wiggs and Lobprise, 1997; Verstraete, 2006). Before fully extracting the tooth, it is first pushed back and twisted slightly. This crucial step produces damage to the germinal tissue, which will prevent the tooth from growing back (Legendre, 2003).

When incisor extraction is done as part of incisor malocclusion treatment, the removal of all 4 incisors is advised. On the other hand, extraction of the opposing incisor is not needed when just 1 incisor is removed. In the latter case, the remaining incisors are sufficiently worn off through the lateral occlusion movements

(Osofsky and Verstraete, 2006). Patience, delicacy and careful handling are essential when operating on patients of this size. Various complications such as tooth fracture, hemorrhage and tooth regrowth do occur. Tooth fractures, and in particular root fractures, commonly happen, leaving behind fragments which can generally not be recovered. These fragments can cause tooth regrowth and abscedation. In the event of root fracture without regrowth, an x-ray is advisable a few weeks after surgery to verify the absence of dysplastic apical growth, which requires surgery. Small bleedings frequently crop up during surgery, but are generally harmless. Unless an iatrogenic alveolar bone fracture takes place during extraction, profuse hemorrhage is uncommon (Legendre, 2003). Chinchillas adapt quite well to incisor extraction, although less so than rabbits, as they tend to chew more with their incisors than lagomorphs (Capello, 2008).

Cheek tooth treatment

Occlusal leveling of cheek teeth clinical crowns includes height reduction as well as the removal of spikes and spurs. The same remarks regarding the choice of instruments for incisor reduction apply here as well (Verstraete, 2003). A full dental check-up, including dental radiography is strongly advised prior to trimming in order to have an overall picture of the mouth (Capello and Gracis, 2005). While leveling the teeth, the practitioner should give attention to restoring the physiological horizontal occlusal plane, as well as the incisor occlusion. If needed, a normal skull can be used as reference during the intervention (Verstraete, 2003). The same precautions as for incisors need to be taken regarding pulp exposure. In chinchillas, cheek teeth coronal reduction can be hindered by reason of gingival proliferation coexisting with the elongation of the clinical crown. Gingivectomy is needed when coronal reduction is required beyond the pathological gingival margin (Capello and Gracis, 2005). Some cases of incapacity to close the mouth after occlusal adjustment have been reported, but only in guinea pigs (Legendre, 2003).

Cheek tooth extraction should be considered in

Table 2. Antibiotics, analgetics and anti-inflammatory drugs that can be used for chinchillas. Recommended active substances and posology (Quensberry, 2003).

Active substance	Posology
Carprofen	4 mg/kg per os (po) SID
Buprenorphine	0.05 mg/kg subcutaneous (sc) BID-TID
Enrofloxacin	5-15 mg/kg po, intramuscular (im) or (sc) BID
Metronidazole	10-20 mg/kg po BID
Marbofloxacin	5 mg/kg im sc po BID
Meloxicam	0.2 mg/kg im sc po BID

cases involving ectopic, fractured or unstable teeth (Legendre, 2003). It can be done using either an intra-oral or an extraoral technique (Verstraete, 2003).

The intraoral non-surgical method can be applied to any cheek tooth and is in principle the less traumatic one. It requires an experienced and skilled hand and is not applicable in cases involving tooth ankylosis or pronounced elongation (Legendre, 2003). The technique is similar to that used for any tooth. Special attention is required to avoid tooth fracture. Once the periodontal ligament is severed, the straight walls of the healthy aradicular hypsodont cheek tooth facilitates its final removal (Legendre, 2003).

The extraoral surgical approach is an option only for mandibular cheek teeth (Capello, 2008). An incision is made in the cheek over the ventro-lateral portion of the mandibula. A gingival flap of the affected tooth is lifted aside to expose alveolar bone. This bone is cut away by means of a bone chisel or bur. Care should be taken at this level to avoid local nerves and blood vessels. The accessible part of the periodontal ligament is severed and the bare roots loosened with luxators. Once this is done, final extraction can either be performed through the buccotomy opening, or else the tooth can be repulsed into the oral cavity as in equine dentistry. The affected area is curetted. Finally, the defect is filled with osteoconductive material, and the soft tissues are sutured (Legendre, 2003). In order to prevent infection, and unless significant hemorrhage is present, it is recommended to flush the sockets and leave them open for drainage (Wiggs and Lobprise, 1997). The extraction of aradicular hypsodont cheek teeth remains a challenging and quite risky intervention. Besides the narrow access and the limited space in which to maneuver, chinchilla cheek teeth are also fairly close to one another and their embedded portion is much larger than the supragingival portion. Tooth fracture during extraction is a common complication. Furthermore, as the bone plates are very thin, the space between alveoli and the orbit / nasal cavity (maxillary teeth) or the cortical margin of the mandibula (mandibular cheek teeth) is extremely small. Needless to say, in these circumstances the risk for iatrogenic damage is real, and even more so in the case of bone lysis secondary to dental pathology (Verstraete, 2003; Osofsky and Verstraete, 2006). Incomplete healing of the socket with conse-

quent feed impaction and fistulation to the skin surface are described (Legendre, 2003). In addition, overgrowth of the opposite teeth is frequent and will require life-long regular trimming. Local instability can appear in neighboring teeth with possible reoccurring periodontal disease and step-mouth development.

As the mandibular and maxillary cheek teeth are not exactly positioned facing each other, extraction of the opposing teeth provides no solution. Quite to the contrary, this intervention frequently even exacerbates the malocclusion problem (Legendre, 2003). In the event of abscedation, specific treatment including drainage and in-depth debridement is required. Abscesses and osteomyelitis caused by periapical lesions or involving both periodontal and endodontal pathologies will generally not heal unless the diseased tooth is extracted or any other cause identified and dealt with. Some authors suggest packing the abscess cavity with calcium hydroxide paste instead. However, this method is not advisable as it does not address the cause and exposes the animal to tissue necrosis due to the caustic nature of calcium hydroxide. A long-term antibiogram-based antibiotherapy is in any case required. Antibiotic impregnated polymethyl-methacrylate beads can also be used (Verstraete, 2003).

Postoperative care

Postoperative care is of major importance when chinchillas are hospitalized for dental problems. In any event, antibiotics and analgetics should be provided, especially to extraction patients on account of the traumatic nature of the procedure, and to debilitated animals which are more prone to infections (Table 2).

It is essential to proceed with caution when choosing the antibiotic type, dose and period of administration for rodents, as life-threatening complications such as diarrhea may arise (Van Foreest, 1999), (Verstraete, 2003). Moreover, anti-inflammatory drugs are required in the event of periodontal inflammation or any other ongoing inflammatory process. Secondary stomatologic (gingivitis, stomatitis, ptyalism, etc.) or ophthalmologic pathologies (lacrimal duct obstruction, dacryocystitis, conjunctivitis, retrobulbar abscesses, etc.) need specific treatment when present. They generally clear up once the initial problem is taken care of. In the case of moist dermatitis secondary to ptyalism, it is advised to clip the perioral area. In this case, antibiotics should be provided, as cases of associated *Pseudomonas* infection have been reported (Wiggs and Lobprise, 1997). While patients generally tend to resume eating within a few hours after the intervention, some chinchillas with painful mouths remain anorectic. If the situation persists, force-feeding may be required. Critical Care® (Oxbow Animal Health, Murdock, USA), or simply pureed vegetables or fruits like apples and carrots can be given through a syringe. In many instances, although not all, force-feeding stimulates the gastrointestinal system, and the animals start eating spontaneously (Wiggs and Lobprise, 1997). For patients admitted in very poor condition, this conva-

lescence diet can be provided for a longer period of time, possibly in addition to spontaneous eating. Once the condition of the animal improves, the diet can gradually be replaced by a more abrasive, low-energy and voluminous one (Legendre, 2003). Bringing the chinchilla back as soon as possible into its own environment, with the familiar noises and odors, and where it can benefit from TLC (Tender, Loving and Care), is another positive factor in stimulating appetite and accelerating recovery (Van Foreest, 1999). When the patient is handed over to the owner, the owner should be reminded of possible post-operative complications and specific signs to watch for in coming days (Wiggs and Lobprise, 1997). Ideally, a recheck visit should be planned 10 to 14 days following the intervention to ensure that the healing is going as planned. From that point on, regular controls are often required (Van Foreest, 1999). If a one-off surgery and dietary change can be curative in patients where inappropriate feed was the underlying cause of the dental problem, re-elongation resumes in a number of cases because the animal is unable or not eager to have a normal chewing pattern. In this case, dental intervention may be needed every 4 to 8 weeks (Legendre, 2003).

Prognosis

The prognosis for dental disease in rodents is generally more cautious than for rabbits (Capello, 2008). The stage in which the dental disease is diagnosed remains the crucial and determining point for prognosis in chinchillas. Sadly, because owners' awareness of the problem is often limited or inexistent, at first presentation chinchillas are far too frequently diagnosed with severe to end-stage malocclusion, which requires recurrent dental intervention or, for which in the worst cases, only palliative care can be offered. The fact that chinchillas seem to have a much higher pain tolerance threshold than guinea pigs, for instance, unfortunately works against them, as they will often only show clinical symptoms in the late stages of the disease (Capello, 2008). The prognosis is most guarded for chinchillas presented with poor overall health conditions, marked anisognathism or gingival proliferation (Legendre, 2002). By contrast, patients brought in for uncomplicated mastication difficulties have higher chances of being definitively cured. However, in view of the fact that dental pathologies can present various forms and complication levels, it is advisable to formulate a prognosis on a case-by-case basis (Capello, 2008).

Disease prevention and client education

Even though some owners are obviously making efforts to learn how to properly care for their animal and to monitor it on a regular basis, the veterinary client's awareness regarding animal health in general, and chinchillas in particular, is astonishingly poor in the vast majority of cases. It is not exceptional to have owners presenting pets with obvious incisor overgrowth,

for instance, consulting because they are not sure if "that white thing there is normal or not..." . Likewise, prolonged anorexia and poor or absent dropping production are not of an alarming nature for a lot of owners.

The authors believe the veterinarians can play a major education role in this matter.

The owners could, for example, consult the veterinarian before or directly after the purchase of a chinchilla, to obtain the necessary information on how to keep their new pet in perfect health. In this best case scenario, the veterinarian can take the opportunity to educate the owner regarding the specific tendency of chinchillas to develop dental pathology. The information provided ought to cover basic knowledge of the species and its natural environment, nutritional requirements and especially the importance of fodder and fiber, as well as aspects of housing, including the provision of gnawing opportunities. Owners should be made aware of the need for a regular dental check-up plan, in the same way as dogs and cats have their annual health visit. Furthermore, one could come up with a set of "golden rules" or preventive measures that can be applied to minimize the onset of dental problems. These could, for instance, include:

- avoid breeding with animals with a family history of dental pathology
- consider hay as the chinchillas' primary food, which should always be available
- hay intake can be stimulated by offering a variety of the types currently available
- limit pellets to 2-3 tablespoons a day per animal
- prefer feed in which the pellets are all the same, with high crude fiber content
- be sure to provide gnawing materials in sufficient quantity and variety. Wooden sticks (preferably untreated willow, beech, hazelnut, or fruit tree), coconut shells or cardboard, for instance, can be offered on a regular basis (Tremblay, 2000)
- avoid high sucrose content treats
- consult a veterinarian without delay if the quantity of droppings declines, if the chinchilla starts slavering a lot, if it often drops its feed, or if it eats less or becomes fussy regarding its hay (Osofsky and Verstraete, 2006).

In cases of poor dental condition, the owners should be assisted on how to manage the problem and reduce its progression (Crossley, 1995; Legendre, 2003). Diet changes are to be suggested, ranging from more abrasive food to soaked pellets or adapted semi-liquid formulations in the worst cases. At this stage it is important to inform the clients that if a diet change can in some cases resolve the problem, in other, more severe situations, it will not, and more invasive measures such as surgery may have to be considered. For these more serious cases, the veterinarian needs to emphasize the fact that dental diseases in chinchillas are often of a chronic nature and do require regular intervention or a long-term commitment on the part of the owner (Osofsky and Verstraete, 2006). In cases where the animals are extremely weak, are suffering despite me-

dication and have a clearly reduced quality of life, euthanasia ought to be presented as a humane option (Wiggs and Lobprise, 1997).

REFERENCES

- Anonymous. (1988). Zusammenhang zwischen Augenkrankheiten und Zahnfehler beim Chinchilla. *Deutsche Pelztierzüchter* 5, 39-40.
- Bohmer E. (2001a). Röntgendiagnostik bei Zahn – sowie Kiefererkrankungen der Hasenartigen und Nager – Teil 1: Tierartsspezifische Zahn- und Kieferanatomie sowie Pathologie, Indikationen für die Röntgendiagnostik. *Tierärztliche Praxis* 29 (K), 316-327.
- Bohmer E. (2001b). Röntgendiagnostik bei Zahn – sowie Kiefererkrankungen der Hasenartigen und Nager – Teil 2: Interpretation von Röntgenaufnahmen und tierartspezifische Fallbeispiele. *Tierärztliche Praxis* 29 (K), 369-383.
- Brenner S.Z.G., Hawkins M.G., Tell L.A., Hornof W.J., Plopper C.G., Verstraete F.M. (2005). Clinical anatomy, radiography, and computed tomography of the Chinchilla skull. *Compendium on Continuing Education for the Practicing Veterinarian* 27 (12), 933-943.
- Capello V., Gracis M. (2005). In: Capello V. and Gracis M. (editors). *Rabbit and Rodent Dentistry Handbook*. Zoological Education Network, Iowa State University Press, Ames, p. 187-189, p. 211-212, p. 249-273.
- Capello V. (2008). Diagnosis and treatment of dental disease in pet rodents. *Journal of Exotic Pet Medicine* 17 (2), 114-123.
- Capello V., Caudoro A. (2008). Application of computed tomography for diagnosis of dental disease in the rabbit, guinea pig, and chinchilla. *Journal of Exotic Pet Medicine* 17 (2), 93-101.
- Carpenter J.W. (2005). Rodents. In: Carpenter J.W. (editor). *Exotic Animal Formulary*. 3th Ed., Elsevier Saunders, Philadelphia, p. 377-408.
- Crossley D.A. (1995). Clinical aspects of rodent dental anatomy. *Journal of Veterinary Dentistry* 12(4), 131-135.
- Crossley D.A., Dubielzig R.R., Benson K.G. (1997). Caries and odontoclastic resorptive lesions in a chinchilla (*Chinchilla lanigera*). *The Veterinary Record* 141 (13), 337-339.
- Crossley D.A., Jackson A., Yates J., Boydell I.P. (1998). Use of computed tomography to investigate cheek tooth abnormalities in chinchillas (*Chinchilla laniger*). *Journal of Small Animal Practice* 39 (8), 385-389.
- Crossley D.A., Roxburgh G. (1999). The site of obstruction of the lacrimal drainage system in chinchillas (*Chinchilla lanigera*) with “wet eye”. In: *Proceedings of the British Small Animal Veterinary Association Congress*, p. 21-22.
- Crossley D.A. (2001). Dental disease in chinchillas in the UK. *Journal of Small Animal Practice* 42 (1), 12-19.
- Crossley D.A., Miguelez M.D. (2001). Skull size and cheek-tooth length in wild-caught and captive-bred chinchillas. *Archives of Oral Biology* 24 (10), 919-928.
- Gracis M. (2008). Normal dental radiography of rabbits, guinea pigs, and chinchillas. *Journal of Exotic Pet Medicine* 17 (2), 78-86.
- Hand M. S., Thatcher C. D. (2000). Feeding small mammals, reptiles and birds. In: Hand M.S., Thatcher C.D., Remillard R., Roudebush P. (editors). *Small Animal Clinical Nutrition*. 4th Edition, Morris, New York, p. 956-957.
- Hoefler H.L. (1994). Chinchillas. *Veterinary Clinics of North America: Small Animal Practice* 24 (1), 103-111.
- Kraft H. (1994). Krankheiten. In: Kraft H. (editor). *Krankheiten der Chinchillas*. 5th Ed., Ferdinand Enke Verlag, München, p. 34-37.
- Legendre L.F. (2002). Malocclusions in guinea pigs, chinchillas and rabbits. *Canadian Veterinary Journal*, 43 (5), 385-390.
- Legendre L.F. (2003). Oral disorders of exotic rodents. *Veterinary Clinics of Exotic Animal Practice*, 6(3), 601-628.
- Lobprise H. (2007). Rodent and lagomorph insisor overgrowth. In: Lobprise H. (editor). *Blackwell's Five Minute Veterinary Consult Clinical Companion: Small Animal Dentistry*. Blackwell, Iowa, USA, p. 361-369.
- Osofsky A., Verstraete F.J.M. (2006). Dentistry in pet rodents. *Compendium on Continuing Education for the Practicing Veterinarian* 28 (1), 61-73.
- Ponzio M.F., Busso J.M., Ruiz R.D., de Cuneo M.F. (2007). A survey assessment of the incidence of fur-chewing in commercial chinchilla (*Chinchilla lanigera*) farms. *Animal Welfare* 16 (4), 471-479.
- Reiter A.M. (2008). Pathophysiology of dental disease in the rabbit, guinea pig, and chinchilla. *Journal of Exotic Pet Medicine* 17 (2), 70-77.
- Silverman S., Tell L. (2005). Domestic Chinchilla (*Chinchilla lanigera*). In: Silverman S., Tell L. (editors). *Radiology of Rodents, Rabbits and Ferrets: an Atlas of Normal Anatomy and Positioning*. Elsevier Saunders, Philadelphia, p. 67-104.
- Sone K., Koyasu K., Tanaka S., Oda S. (2004). Effects of diet on the incidence of dental pathology in free living caviomorph rodents. *Archives of Oral Biology* 50 (3), 323-331.
- Stroke J.G., Davis L.A., LaRegina M., Boschert K.R. (1996). Chinchillas. In: Laber-Laird K., Swindle M.M., Flecknell P. (editors). *Handbook of Rodent and Rabbit Medicine*. 1st Ed., Elsevier Science Ltd, Oxford, p. 151-182.
- Sulik M., Sobolewska E., Seremak B., Ey-Chmielewska H., Fraczak B. (2007). Radiological evaluation of chinchilla mastication organs. *Bulletin of the Veterinary Institute of Pulawy*, 51 (1), 121-124.
- Tremblay, M. (2000). Le Chinchilla. In: Tremblay M. (editor). *Le Chinchilla*. Le Jour Editeur, France, p. 135.
- Van Foreest A. (1999). Specifieke gebitsproblemen bij konijnen en herbivore knaagdieren. In: Van Foreest A. (editor). *Tandheelkunde bij Gezelschapdieren*. Elsevier, Maarssen, p. 311-338.
- Verhaert L. (2004). Dental diseases in lagomorphs and rodents. In: Gorrel C. (editor). *Veterinary Dentistry for the General Practitioner*. Saunders, China, p. 175-195.
- Verstraete F.J.M. (2003). Advances in diagnosis and treatment of small exotic mammal dental disease. *Seminars in Avian and Exotic Pet Medicine* 12 (1), 37-48.
- Wagner R.A., Garman R.H., Collins B.M. (1999). Diagnosing odontomas in Prairie Dogs. *Exotic DVM* 1.1, 7-10.
- Wiggs R. B., Lobprise H. B. (1997). Dental and oral diseases in rodents and lagomorphs. In: Wiggs R.B. and Lobprise H.B. (editors). *Veterinary Dentistry, Principles and Practice*. Lippincott-Raven, Philadelphia, p.518-537.
- Wolf P., Schröder A., Wenger A., Kamphues J. (2003). The nutrition of the chinchilla as a companion animal - basic data, influences and dependences. *Journal of Animal Physiology and Animal Nutrition* 87(3-4), 129-133.