

Parafilaria in a Belgian Blue breeding bull in Flanders

Parafilariose bij een Belgisch witblauwe dekstier in Vlaanderen

¹B. Pardon, ⁴I. Zwaenepoel, ³G. Vercauteren, ²E. Claerebout, ¹P. Deprez

¹ Department of Internal Medicine and Clinical Biology of Large Animals,

² Department of Virology, Parasitology and Immunology,

³ Department of Pathology, Bacteriology and Avian Diseases,

Faculty of Veterinary Medicine, Ghent University, Salisburylaan 133, B-9820 Merelbeke, Belgium

⁴ Dierenartsenpraktijk Animo, Damse Vaart Zuid 75, B-8310 Sint-Kruis (Brugge), Belgium

Bart.Pardon@UGent.be

ABSTRACT

In March 2009 a three-year-old Belgian Blue breeding bull in Western Flanders demonstrated multiple nodules on the withers, shoulders and neck. Some of them were bleeding. The bull had been imported from the south of Belgium in the summer of 2008. Serohaemorrhagic exsudate from one of the nodules was examined under the light microscope and a larva and embryonated egg of *Parafilaria bovicola* could be identified. On histopathology a eosinophilic dermatitis was present and after serial sectioning an adult female filarid was found in the superficial dermis. The animal was treated with moxidectin and the skin lesions disappeared within a week. This is the first diagnosed case of bovine parafilaria in Flanders. Nine months later, no additional cases were identified neither on the farm nor on the neighbouring farms.

SAMENVATTING

In maart 2009 vertoonde een drie jaar oude Belgisch witblauwe dekstier in West-Vlaanderen meerdere nodulen op de huid van de schoft, schouders en de nek. Sommige nodulen bloedden. De stier werd in de zomer van 2008 geïmporteerd uit Wallonië. In het serohemorragische exsudaat van één van de nodulen konden één larve en één geëmbryoneerd ei van *Parafilaria bovicola* onder de lichtmicroscop geïdentificeerd worden. Het histopathologisch onderzoek toonde een eosinofiele dermatitis aan en in seriële coupes was een volwassen, vrouwelijke filaride in de oppervlakkige dermis te zien. Het dier werd behandeld met moxidectine en de huidletsels verdwenen binnen een week. Dit is het eerste gerapporteerde geval van parafilariose bij een rund in Vlaanderen. Tijdens een opvolgingsperiode van 9 maanden werden geen bijkomende gevallen gediagnosticeerd, noch op het bedrijf noch op de bedrijven in de buurt.

INTRODUCTION

Parafilaria is a vector-borne parasitic infection of cattle and buffalo caused by the filaroid nematode *Parafilaria bovicola* (family Filariidae, subfamily Filariinae), which is characterized by hemorrhagic nodules ('bleeding spots') on the skin and bruise-like lesions in the subcutaneous and intramuscular tissues of affected carcasses (Fraser *et al.*, 1991). *P. bovicola* is known to be present in Asia, Africa and some European countries (Bulgaria, Romania, France) (Faure, 1935; Metianu, 1949; Patnaik and Pande, 1963; Pienaar *et al.*, 1964; Bussieras *et al.*, 1987). The parasite was introduced by the import of infected bulls in Canada, Ireland, Sweden and the Netherlands (Webster and Wilkins, 1970; Lundquist, 1983; Torgerson *et al.*, 1998; Borgsteede *et al.*, 2009), but could only establish its life cycle in Sweden. In 2009 parafilaria proved to be endemic in an area situated in the southern part of Belgium (Wallony) (Losson and Saegerman, 2009). In this article the first case of parafilaria in Flanders is described.

CASE DESCRIPTION

Case history

In March 2009 a 3-year-old Belgian Blue breeding bull was referred with complaints of cutaneous bleeding. The farm was situated in West-Flanders, in the region of Bruges. The animal had been imported in the summer of 2008 from the southern part of Belgium (Wallony, Namen), near the French border. Upon arrival, the animal was in a good body condition and had a normal libido. In March 2009 the animal was bleeding from the skin, and according to the owner the bleeding often began shortly after mating.

Clinical examination

The bull had a normal body condition score and no abnormalities were detected on clinical examination, except for cutaneous lesions. The most prominent finding was the presence of multiple nodules on the withers, shoulders and the neck on both sides (Figures 1 and 2). The nodules were 2 to 4 cm in diameter, ede-

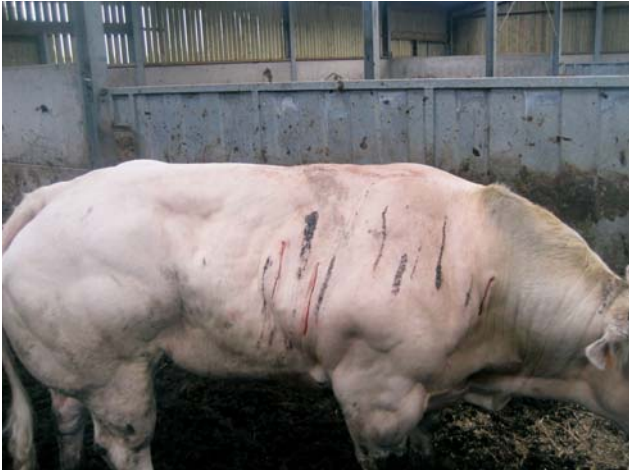

Figure 1. Multiple nodules and three 'bleeding spots' on withers, shoulders and neck of a 3-year-old Belgian Blue breeding bull with parafilariasis.



Figure 2. Details of bleeding *Parafilaria bovicola* nodules (bleeding spots) on the shoulders of a 3-year-old Belgian Blue breeding bull.

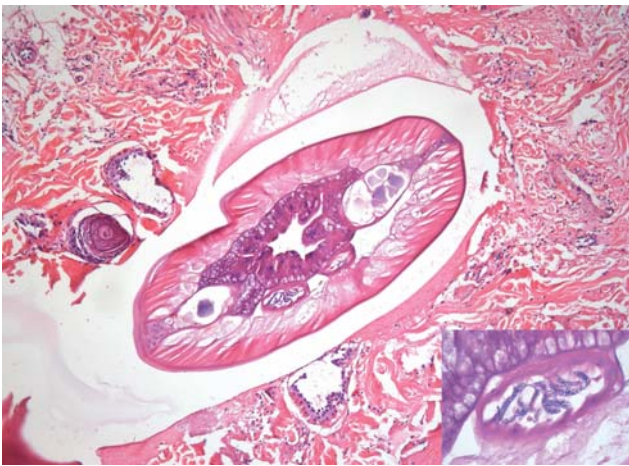


Figure 3. Female filarid in a biopsy section of a nodular lesion (HE, 100x) - Inset: Uterus containing microfilariae (HE, 1000x).

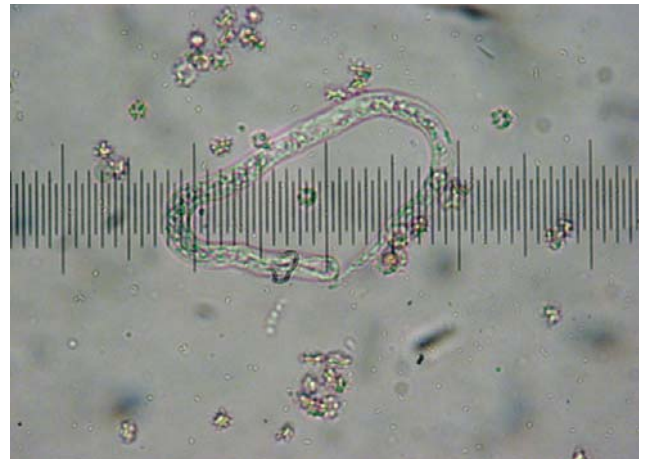


Figure 4. Larva of *Parafilaria bovicola* (light microscopy, 400x).

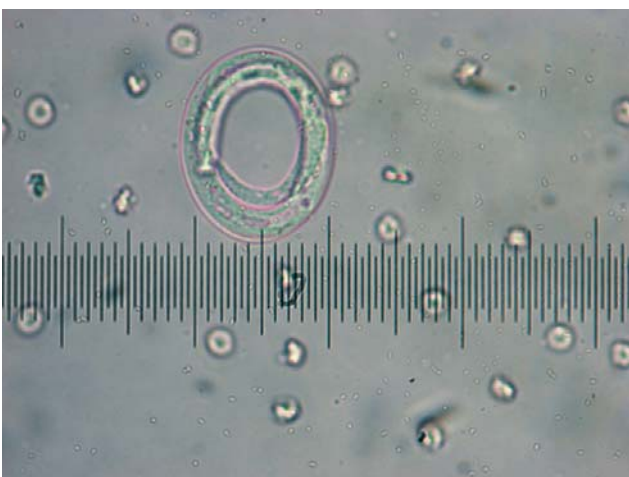

Figure 5. Embryonated egg of *Parafilaria bovicola* (light microscopy, 400x).

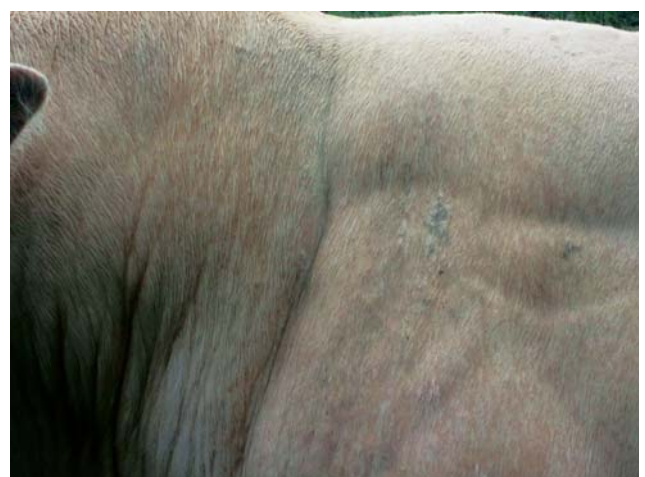

Figure 6. Complete recovery of parafilariasis lesions on the withers, shoulders and neck in a Belgian Blue breeding bull, one week after treatment with moxidectin injectable.

matous and painful on palpation. Several nodules had discharged blood which had dried and matted the hairs. Three nodules were still bleeding. On some nodules a small central opening could be seen. When manual pressure was applied upon the nodules, serohemorrhagic exudate could be evacuated. The lymph nodes were not enlarged and there was no pruritus. The skin of all the cattle on the farm was inspected for the presence of similar lesions, but there were no other cases. No other herds were affected in the practice of the referring veterinarian.

Blood examination, histology and parasitologic examination

Jugular blood samples (ethylenediaminetetraacetic acid (EDTA) and citrate) were taken for standard hematology and coagulation tests. The total white blood cell count was 5.2×10^9 cells/ml (6-9), with 55.1% granulocytes and monocytes (25-55), and 44.9% lymphocytes (45-75). The packed cell volume was 31.1 ml/ml (25-35). The number of platelets was 229×10^9 platelets/ml (100-800). The coagulation tests (prothrombine coagulation time (PT) and activated partial thromboplastine time (APTT)) were normal, as was fibrinogen (313 mg/dl (100-460)).

A 10-mm-punch biopsy was taken from a nodule. The biopsy was formalin fixed, paraffin wax embedded, sectioned at 4µm and stained with hematoxylin and eosin (HE) according to a standard protocol. On histopathology, dense perivascular to interstitial infiltrations of mainly eosinophils and some lymphocytes, plasma cells and macrophages were seen. The dermal blood vessels showed multifocal fibrinoid necrosis of the vessel walls sometimes associated with neutrophilic vasculitis. After serial sectioning, an adult female filarid was found in the superficial dermis. A cuticle, coelomyarian musculature, a simple intestine and a uterus filled with microfilariae could be discerned (Figure 3). The presence of these microfilariae identifies the metazoan parasite as a filarial nematode.

Additionally, the content of one nodule was evacuated by manual pressure. The material was collected in 4 ml of a physiological saline solution (0.9% NaCl) and transferred to the laboratory. The sample was allowed to sediment for 12 hours at 4 °C. The pellet was pipetted onto a glass slide and was observed under the light microscope at 100x and 400x. One first stage larva (Figure 4) and one embryonated egg (Figure 5) of *Parafilaria bovicola* could be seen.

Treatment and further evolution

The bull was injected subcutaneously with 0.2 mg/kg moxidectin (Cydectin® 1%, Fort Dodge). One week later, all lesions had disappeared (Figure 6). The animal remained in good health. No other cases occurred on the farm.

DISCUSSION

Parafilariasis is a vector-borne parasitic infection of cattle and buffalo caused by the filaroid nematode *Parafilaria bovicola* (family Filariidae, subfamily Filariinae) (Fraser *et al.*, 1991). In Europe the vector is the head fly (*Musca autumnalis*), which was the only *Muscida* species to be infected with nematodes (*Parafilaria bovicola*, *Theilazia*, *Heterotylenchus autumnalis*) in a Swedish study (Chirico, 1994b). Head flies feed on infected lesions on cattle skin and ingest first stage larvae. In the intermediate host the larvae further develop into the infective third stage larvae in 10 to 12 days (Fraser *et al.*, 1991). On subsequent feedings of the flies these infective larvae are transmitted to the definitive host (cattle) and penetrate the skin. The parasite produces subcutaneous nodules in the dorsal parts of the body: the head, neck, withers, shoulders and possibly also the sides of the body. Further development (third and fourth moult) takes about 240 days. After mating the adult female worms (5-6 cm long) start oviposition. The female adult migrates to the skin surface, which leads to the formation of a subcutaneous nodule and makes an opening (0.5-1 mm) on the summit. This causes bleeding ('bleeding spots') and eggs are discharged in a serohemorrhagic exudate. The nodules develop rapidly and the bleeding stops within 24-48 hours (Fraser *et al.*, 1991). In Europe these bleeding spots first appear in late winter (March), reach a peak in April and May and then decline (Bech-Nielsen *et al.*, 1982; Lundquist, 1983). Later in the season, only sterile or calcified nematodes are found in healing or healed lesions (Bech-Nielsen *et al.*, 1982). Over winter survival of the parasite in the vector has been demonstrated (Chirico, 1994a).

P. bovicola is endemic in Africa (Faure, 1935; Pienaar *et al.*, 1964), Asia (Patnaik and Pande, 1963) and in European countries, such as France, Bulgaria (Busieras *et al.*, 1987) and Romania (Metianu, 1949). The parasite was introduced in Canada (Webster and Wilkins, 1970), Ireland (Torgerson *et al.*, 1998) and in 2007 also in the Netherlands (Borgsteede *et al.*, 2009). In all three countries the cases were imported breeding bulls from France and the parasite did not become endemic. Unfortunately, the import of a breeding bull from France in 1978 led to the establishment of the parasite in Sweden (Lundquist, 1983). This example illustrates the possibility of establishment of *P. bovicola* in regions with a moderate climate, such as Belgium, if the vector is present. Recently, the endemic presence of the parasite has been confirmed in Wallony, the southern part of Belgium (Losson and Saegerman, 2009). Clinical signs of parafilariasis were observed in 76 out of 562 herds (14.1%) in the region of Liège. Although the breeding bull in Flanders was imported from a region near to the known endemic region, and no other cases were found in the immediate proximity, the parasite may also become endemic in Flanders, since the vector is present and since there are no big differences between the climates of Flanders, Wallony and France.

For parafilariasis no breed predilection is reported

(Fraser *et al.*, 1991). In Belgium however, mainly Belgian Blue livestock was affected, whereas only one infected Holstein-Friesian cow was reported (Losson and Saegerman, 2009). Although the Belgian Blue breed is known to be very susceptible to another skin pathogen, e.i. *Psoroptes ovis*, breed predisposition to *P. bovicola* infection seems unlikely (Vercruyssen *et al.*, 2008). In the region studied (Liège and environment), the density of Belgian Blue cattle is much higher than the density of dairy cattle. Moreover, the bleeding spots are more easily identified in light colored breeds, such as the Charolais or the Belgian Blue (Losson and Saegerman, 2009). These factors may explain the higher incidence in Belgian Blue cattle reported in Belgium. In general, no age predilection is reported, but in South Africa a predisposition of male animals, younger than two years old has been reported (Nevill, 1984). The breeding bull in Flanders was 3 years old, which is similar to the cases reported by Losson and Saegerman (2009) in the south of Belgium. In their survey, most affected animals were older than two years. The apparent predilection of older Belgian Blue cattle is most likely due to the higher frequency of anti-parasitic treatment in young animals because of the mange problems in this breed (Fraser *et al.*, 1991; Losson and Saegerman, 2009).

The major economic importance of parafilariasis is skin damage, which implies unsuitability for the leather industry. Additional economical damage is caused by the irregular, edematous, greenish yellow lesions on the carcass that resemble bruises but have a characteristic, disagreeable, metallic smell. The trimming of these lesions from the carcasses can lead to a considerable loss of saleable meat (Fraser *et al.*, 1991). These lesions appear more frequently in bulls than in cows (Fraser *et al.*, 1991).

Although clinical signs are very typical, the definitive diagnosis should be based on the demonstration of the parasite or its embryonated eggs in lesions or exudate, as demonstrated in this article. It is however not always possible to confirm the diagnosis in this way (Borgsteede *et al.*, 2009). On histology (post mortem or skin biopsy) sections of the parasite can be seen (Borgsteede *et al.*, 2009) and the perivascular and/or interstitial eosinophilic infiltration is suggestive for a parasitic origin (Lundquist, 1983). An antigen ELISA was developed in Sweden, but is no longer available (Sundquist *et al.*, 1988).

Parafilariasis can be treated with levamisole (10-12 mg/kg injectable during 5 days or pour on 2.5% (Johansson, 1984)) or macrocyclic lactones. Injectable macrocyclic lactones seem to be more effective than oral or pour-on formulations. Treatment with injectable ivermectin (0.2 mg/kg) resulted in a rapid cure of the lesions and reduced the mean mass of the affected tissue trimmed in several trials (Soll *et al.*, 1991; Swan *et al.*, 1983, 1991; Borgsteede *et al.*, 2009), whereas oral treatment with ivermectin was ineffective (Iida and Taira, 1994). Similarly, treatment with 0.5 mg/kg moxidectin pour-on was unsuccessful (Borgsteede *et al.*, 2009), while the injectable formulation of moxi-

dectin proved to be efficient in the present case. Although the visible cutaneous lesions disappear within two weeks after treatment, it is advised to slaughter the animals not until 70-90 days after treatment (Fraser *et al.*, 1991). This period allows sufficient time for the lesions to resolve. Because anthelmintic treatment is not effective against *P. bovicola* larvae, it is advised to slaughter before 120 days after treatment, because new lesions can arise from surviving worms (Fraser *et al.*, 1991).

Preventive measures focus on a strategic treatment of the animals and on vector control. Eartags, impregnated with cypermethrin or fenvalerate have proved to be very efficient in diminishing the number of face flies on cattle (Williams *et al.*, 1981).

CONCLUSION

In conclusion this case report illustrates the presence of *Parafilaria bovicola* in the north-western part of Belgium. It remains to be determined whether this is a single imported case, or whether the parasite will become endemic in Flanders. Evolution towards an endemic situation is possible, as the parasite is present in the southern part of Belgium and the vector is ubiquitous in Flanders.

REFERENCES

- Bech-Nielsen S., Sjogren V., Lundquist H. (1982). *Parafilaria bovicola* (Tubanguï 1934) in cattle: Epizootiology-disease occurrence. *American Journal of Veterinary Research* 43, 945-947.
- Borgsteede F., van Wuijckhuise L., Peutz J., Roumen T., Kock P. (2009). Import of *Parafilaria bovicola* in the Netherlands. *Veterinary Parasitology* 161, 146-149.
- Bussieras J., Chermette R., Gresset M., Mas M. (1987). New observations on summer sores in cattle in eastern France. *Recueil de Médecine Vétérinaire* 163, 163-853-856.
- Chirico J. (1994a). Prehibernating *Musca autumnalis* (Diptera: Muscidae) - an overwintering host for parasitic nematodes. *Veterinary Parasitology* 52, 279-284.
- Chirico J. (1994b). A Comparison of sampling methods with respect to cattle-visiting Muscidae and their nematode infections. *Medical and Veterinary Entomology* 8, 214-218.
- Faure L. (1935). Dermatorrhagie parasitaire des bovins nord-africains due à *Setaria haemorrhagica*. *Annales de Parasitologie Humaine et Comparée* 13, 113-115.
- Fraser C.M., Bergeron J.A., Mays A., Aiello S.E. (1991). Parafilariasis infection. In: Fraser C.M., Bergeron J.A., Mays A., Aiello S.E. (editors). *The Merck Veterinary Manual*. 7th Ed., p. 809-810.
- Iida M., Taira N. (1994). Two cases of parafilariasis in dairy cattle and treatment of hemorrhage with levamisole topical application. *Journal of Veterinary Medical Science* 56, 203-205.
- Johansson T. (1984). An attempt to combat *Parafilaria bovicola* in cattle. *Svensk Vet Tidning* 36, 133-135.
- Losson B., Saegerman C. (2009). First isolation of *Parafilaria bovicola* from clinically affected cattle in Belgium. *The Veterinary Record* 164, 623-626.
- Lundquist H. (1983). *Parafilaria bovicola* (Tubanguï 1934)

- established in Swedish cattle. *Nordisk Veterinaer Medicin* 35, 57-68.
- Metianu T. (1949). Haemorrhagic dermatitis in Roumania caused by *Parafilaria bovicola*. *Annales de Parasitologie Humaine et Comparée* 24, 54-59.
- Nevill E.M. (1983). Seasonal abundance and distribution of *Parafilaria bovicola* ovipositional blood spots on cattle in South Africa. *Onderstepoort Veterinary Journal* 51, 107-114.
- Patnaik M.M., Pande B.P. (1963). A note on parafilariasis in buffalo, *Bos (Bubalus) bubales*. *Journal of Helminthology* 37, 343-348.
- Pienaar J.C., van den Heever L.W. (1964). *Parafilaria bovicola* (Tubanguï 1934) in cattle in the Republic of South Africa. *Journal of the South African Veterinary Medicine Association* 35, 181-184.
- Soll M.D., Carmichael I.H., Barrick R.A. (1991). Ivermectin treatment of feedlot cattle for *Parafilaria bovicola*. *Preventive Veterinary Medicine* 10, 251-256.
- Sundquist B., Zakrisson G., Bech-Nielsen S., Bianco A.E. (1988). Preparation and evaluation of the specificity of *Parafilaria bovicola* antigen for detection of specific antibodies by ELISA. *Veterinary Parasitology* 28, 223-235.
- Swan G.E., Soll M.D., Carmichael I.H., Schroder J. (1983). Efficacy of ivermectin against *Parafilaria bovicola*. *The Veterinary Record* 133, 260.
- Swan G.E., Soll M.D., Gross S.J. (1991). Efficacy of ivermectin against *Parafilaria bovicola* and lesion resolution in cattle. *Veterinary Parasitology* 40, 267-272.
- Robertsson J.A. (1986). The spread of *Parafilaria* and the consequences for animal production from the regional standpoint. *Svensk Vet Tidning* 38, 473-478.
- Torgerson P.R., Doherty M.L., Healy A.M. (1998). Bovine haemorrhagic parafilariosis in an imported charolais bull. *Irish Veterinary Journal* 51, 27-29.
- Vercruysse J., Deprez P., Everaert D., Bassissi F., Alvineria M. (2008). Breed differences in the pharmacokinetics of ivermectin administered subcutaneously to Holstein and Belgian Blue calves. *Veterinary Parasitology* 25, 136-40.
- Webster W.A., Wilkins D.B. (1970). The recovery of *Parafilaria bovicola* Tubanguï 1934 from an imported Charolais bull. *Canadian Veterinary Journal* 11, 13-14.
- Williams R.E., Westby E.J., Hendrix K.S., Lemenager R.P. (1981). Use of insecticide-impregnated ear tags for the control of face flies and horn-flies on pastured cattle. *Journal of Animal Science* 53, 1159-1165.
-