

General anesthesia for the surgical repair of a tarsometatarsal fracture in a Harris's Hawk (*Parabuteo unicinctus*)

Anesthesie voor de chirurgische behandeling van een tarsometatarsaal fractuur bij een woestijnbuizerd (Parabuteo unicinctus)

¹Y. Hoybergs, ¹T. Bosmans, ²M. Risselada, ²A. Van Caelenberg, ¹I. Polis

¹ Department of Small Animal Medicine and Clinical Biology

² Department of Medical Imaging of Domestic Animals

Faculty of Veterinary Medicine, Ghent University, Salisburylaan 133, 9820 Merelbeke, Belgium

yveshoybergs@telenet.be

ABSTRACT

A Harris's Hawk was referred for severe lameness of the left pelvic limb. Clinical examination and radiography revealed an open transverse diaphyseal fracture in the proximal third of the tarsometatarsal bone. Anesthesia was induced and maintained with isoflurane in oxygen after premedication with buprenorphine intramuscularly. Closed reduction and stabilization using a Type IIa external skeletal fixation device was performed during anesthesia lasting 70 minutes. Recovery was fast, uneventful and complete 15 minutes after isoflurane was stopped. Meloxicam (0.5mg/kg bid) was administered as analgesic and marbofloxacin (15mg/kg bid) as antibiotic therapy during the post-operative period.

SAMENVATTING

Een woestijnbuizerd werd aangeboden met een erg manke linkerpoot. Ter hoogte van de linkertarsometatarsus was een wond aanwezig. Radiografisch werd een dwarse diafyseaire fractuur in het proximale derde van de tarsometatarsus vastgesteld. Na premedicatie met buprenorfine intramusculair werd de anesthesie geïnduceerd en onderhouden met isofluraan en zuurstof. Na gesloten reductie werd de fractuur met een externe fixatie (Type IIa) gestabiliseerd. De anesthesie duurde 70 minuten. De recovery verliep vlot en reeds 15 minuten na de stopzetting van de anesthesie was de woestijnbuizerd volledig hersteld. Postoperatief werd meloxicam (0,5 mg/kg bid) toegediend als analgeticum en marbofloxazine (15 mg/kg bid) als antibioticum.

INTRODUCTION

Raptors or birds of prey were very popular in the medieval period in Europe, and in the last three decades the sport of falconry has again gained popularity (Redig and Ackermann, 2000). In Latin 'rapere' means 'to seize', which refers to the strong, grasping feet of the birds of prey.

Over the last 20 years, the Harris's Hawk (*Parabuteo unicinctus*), which is a member of the order Falconiformes, family Accipitridae (hawks), subfamily Buteoninae, has become the most popular species in falconry (Borch, 2005). Their natural habitat reaches from the southwestern United States through Central America and into the drier parts of South America (Chili and central Argentina) (Bednarz, 1988). The Harris's Hawk is imported or bred in Europe for falconry.

Fractures in raptors often occur during hunting sessions, mostly as a result of the bird's high kinetic energy (high velocity) and the unpredictable movements of the prey, but fractures also often occur when raptors try to fly away when there are tied with jesses

(Harcourt-Brown, 1996) or lures. Complete anatomical and functional repair is essential in raptor medicine to guarantee survival in wild living species and normal activity in falconry birds. Anesthesia is essential to allow the required surgical interventions.

From the late 1940s, veterinarians were anesthetizing different avian species for surgical procedures. Initially, ether was used with an open face-mask delivery system, but difficulties controlling the depth of anesthesia and the resulting high mortality rates made this volatile agent less suitable for avian anesthesia. The introduction of methoxyflurane and halothane in 1962 reduced the induction and recovery periods and the mortality rates during and after surgery. Isoflurane was introduced in 1985 and is currently the first choice for the induction of anesthesia in birds (Altman, 1998).

Difficulties encountered during avian – and especially raptor – anesthesia include stress from handling, overdosing, hypothermia, hypoventilation and regurgitation. The present case report describes the successful surgical treatment of an open tarsometatarsal fracture in a Harris's Hawk.

CASE HISTORY

A 2-year-old captive bred female Harris's Hawk (*Parabuteo unicinctus*) weighing 1.150 kg was referred with a history of acute left pelvic limb lameness after a hunting session. The bird appeared bright and alert, and it was not dehydrated. The left tarsometatarsal region was swollen in the proximal third and there was a wound at the cranial aspect of the swelling. Radiography performed using manual restraint revealed a fracture of the tarsometatarsal bone (Figure 1). Together with the clinical findings, the diagnosis

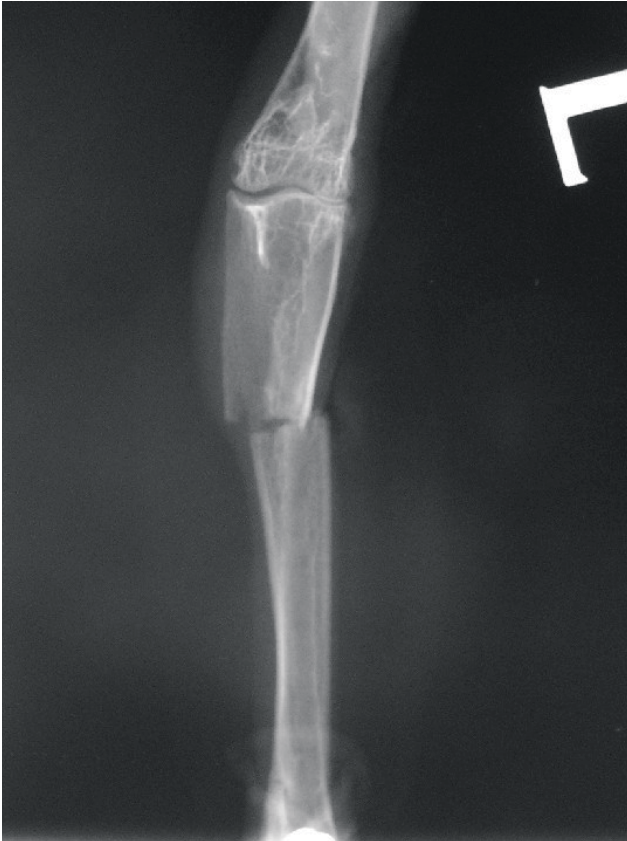

Figure 1. The craniocaudal radiograph reveals an open, transverse tarsometatarsal fracture of proximal third of the diaphysis.

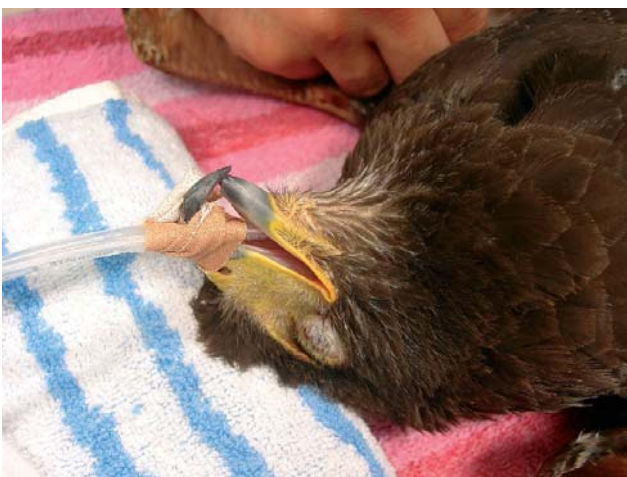

Figure 2. After intubation, the endotracheal tube is fixed to the upper part of the beak.

of an open proximal tarsometatarsal fracture was made. Surgery was advised to achieve anatomical and functional repair.

ANESTHESIA

As the food status food was uncertain and surgery was required, no fastening period was applied. The handler accompanied the bird until anesthesia was induced, thus allowing minimal and stress-free handling.

Premedication with 20 µg/kg buprenorphine (Temgesic®, Schering-Plough, Hull, UK) was administered intramuscularly in the pectoral muscle.

After 5 minutes, anesthesia was induced by face mask using 5% isoflurane (Isoba Vet®, Schering Plough, Hull, UK) in oxygen (3L/min). The bird was positioned in sternal recumbency, and after visualization of the glottis, a cuffed, 3 mm endotracheal (ET) tube (GlobalVeterinary Products, Waukesha, USA) was inserted into the trachea and taped to the upper part of the beak (Figure 2). The cuff was not inflated. Anesthesia was maintained with isoflurane in oxygen, using a 10mm diameter pediatric circle system (Dräger, Lubeck, Germany) mounted on an anesthetic machine (Spiromat® 656, Dräger, Lubeck, Germany) with an out-of-circuit vaporizer (Vapor® 19.3, Dräger, Lu-

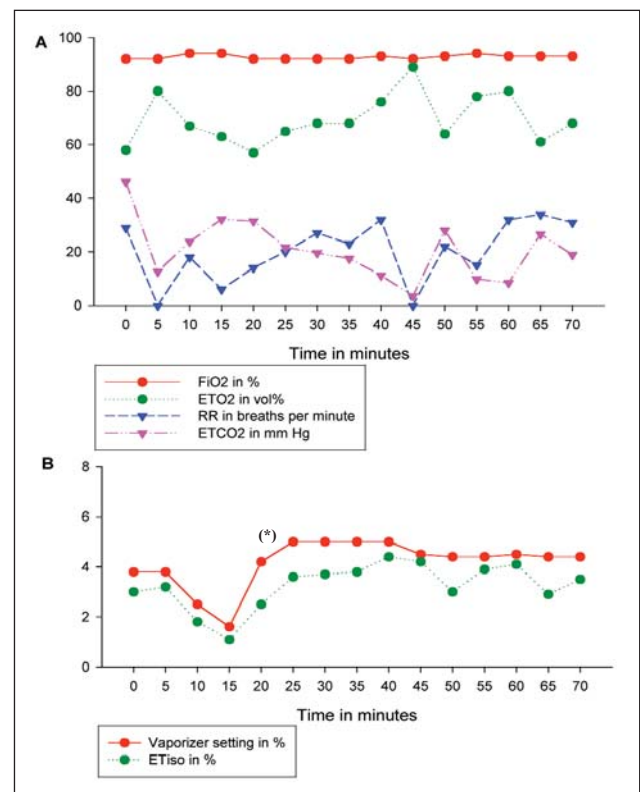


Figure 3. A. Gas analysis during the entire surgical procedure demonstrates a highly fluctuating respiration rate, end tidal CO₂ (ETCO₂) and end tidal O₂ levels. B. Vaporizer setting with end tidal isoflurane concentration (ETiso) was decreased during the first 15 minutes of the anesthesia. At the point where intensive manipulation of the fracture site started (*), the animal showed slight head movements. Administration of isoflurane was increased until the end of the procedure.

beck, Germany). The vaporizer settings during surgery are shown in Figure 3.

Anesthesia monitoring included clinical parameters together with anesthetic gas analysis. The anesthesia level was considered sufficient when noxious stimuli (feather plucking and toe pinch) no longer elicited a response. Breathing quality, corneal reflex and pupillary size were evaluated during the procedure. Inspiratory CO₂ (FiCO₂), end-tidal CO₂ concentration (ET CO₂ %), inspiratory and expiratory oxygen fraction (FiO₂-ETO₂), inspiratory and expiratory isoflurane concentrations (Fi_{iso} - Et_{iso}) and respiration rate were monitored using a side-stream multi-anesthetic gas analyzer (Capnomac Ultima®, Datex Engstrom Instrumentation Corp., Helsinki, Finland) with a low dead space neonatal adapter (Datex-Ohmeda, Instrumentation Corp., Helsinki, Finland). These findings are shown in Figure 3. Several attempts to measure peripheral hemoglobin saturation and pulse rate with pulse oximetry were unsuccessful.

A 22G over-the-needle catheter was aseptically placed in the right ulnar vein and NaCl 0.9% was infused intravenously during the anesthesia. The catheter was fixed to the feathers using tape. The infusion was pre-

warmed to 40°C and administered at a rate of 10 ml/kg/h (11ml/h). The animal was placed on a circulating warm water blanket. Because the food status was unknown and to prevent regurgitation and hypoventilation, the body was inclined with the head upwards.

After the surgery and anesthesia, which lasted 70 minutes, the recovery went smoothly. To prevent self inflicted trauma during recovery, the bird was wrapped in a towel and kept in a horizontal position until the head started to move. After the ET tube was removed and the mouth was inspected for accumulations of mucus, the animal was placed in sternal sitting position in a cage and monitored until it was standing. Recovery was complete 15 minutes after disconnection of the anesthetic machine.

Postoperative analgesia was provided by oral meloxicam (Metacam®, Boehringer Ingelheim, Rhein, Germany) at a dosage of 0.5 mg/kg twice daily for 4 days. Marbofloxacin 15 mg/kg orally (Marbocyl®, Vetoquinol, Aartselaar, Belgium) was provided twice daily as anti-microbial therapy.

SURGERY

With the animal in dorsal recumbency, the left tarsometatarsus was prepared for surgery by plucking the feathers from the surgical site and applying a betadine ointment (Isobetadine® Dermicum, Mundipharma AG, Basel, Switzerland). Draping was performed aseptically using plastic surgical drape (Buster®, Kruuse, Denmark). Four transverse surgical stainless steel pins (each 1.2 mm diameter) were inserted into the tarsometatarsus in a lateral to medial direction. Two pins were positioned in the proximal part and two in the distal part of the tarsometatarsus. The pins were angled in a proximo-distal direction to prevent early removal of the External Skeletal Fixation (ESF). The four pins were connected bilaterally with a 2 mm bar with Meynard clamps, resulting in the construction of a Type IIa ESF. The limb was held in traction during the fastening of the pins, thus aiding in achieving alignment and correct reduction of the fracture.

Postoperative radiographs revealed good alignment, good reduction (over 90% bone to bone contact) and correct pin placement (Figure 4).

Six weeks after surgery, radiography was performed to assess fracture healing and to evaluate the possibility of removing the external fixation. The radiographs showed a good fracture healing with medium graded osteolysis around the distal pin and low graded osteolysis around the proximal pin (Figure 5). It was concluded that fracture healing was sufficient enough to remove the External Skeletal Fixation.

DISCUSSION

Raptor anesthesia, like all avian anesthesia, is subject to a variety of difficulties. Birds of prey are difficult to anesthetize, and the anesthetic risks are high (Paddleford, 1986), mainly due to problems associa-

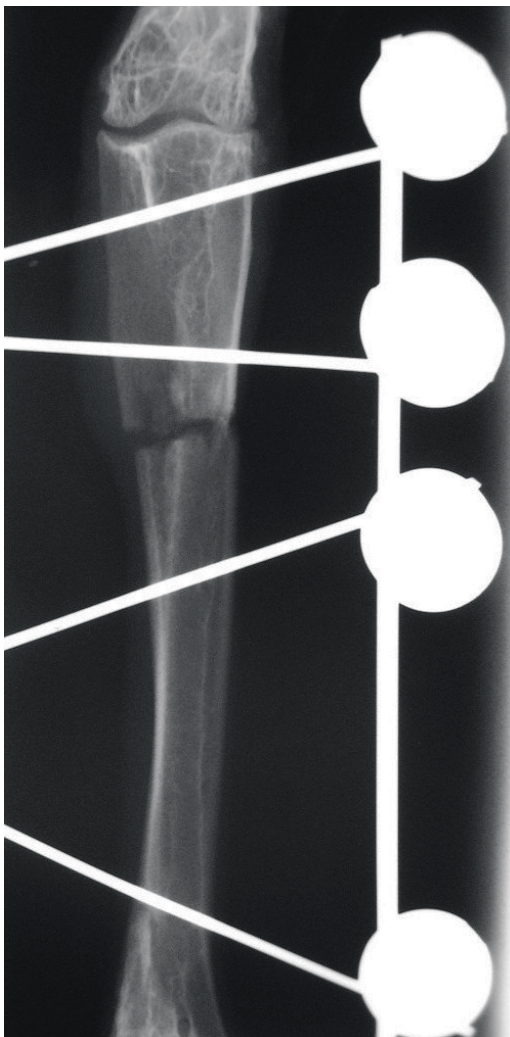


Figure 4. The postoperative radiograph confirms the correct alignment, reduction and pin placement.

ted with improper handling, shock and regurgitation (Lawton, 1996).

Raptors, whether wild or captive, are not accustomed to veterinary procedures and can react defensively. Proper and stress-free handling can be carried out by the owner or by trained staff (Heidenreich, 1997). In the present case, the handler restrained the animal during the examination, radiography and premedication until the induction of anesthesia was complete. Nevertheless, the advantages of stress reduction by general anesthesia, especially in wild captive birds, usually outweigh the potential risk of anesthesia (Redig), and it should be noted that the bird in this case had to be anesthetized to obtain stress-free, high quality x-rays.

Another precaution is to weigh the bird accurately in order to allow correct dosing of premedications, antibiotics and analgesics. Nevertheless, the effective doses tend to be highly variable between bird species, which makes efficacy very unpredictable (Langlois *et al.*, 2003). Although Harris's Hawks do not seem sensitive to certain groups of medical compounds (Redig, 2000), this dose variability among different species is the main reason why inhalants are first choice anesthetics in raptor anesthesia.

Buprenorphine was administered as analgesic premedication. Buprenorphine is often used in avian anesthesia (Lawton, 1996), but the use of opioids in general remains controversial. Pharmacokinetic studies have demonstrated that pigeons have more kappa than mu-opioid receptors (Mansour *et al.*, 1988). This could explain why birds respond less to mu-agonists compared to mammals and why kappa-opioids, such as butorphanol and buprenorphine, are more efficient analgesics in birds (Paul-Murphy and Fialkowski, 2001). As mu-agonists are strong respiratory depressants, it is advisable to use opioid drugs with a more pronounced kappa selectivity.

In mammalian species it has been demonstrated that injectable and inhalant anesthetics, through central and peripheral chemoreceptors, significantly depress ventilatory responses to hypoxia and hypercarbia. In birds, the same physiologic components cause hypoventilation during anesthesia (Ludders *et al.*, 1995) and, as both inspiration and expiration require muscle activity, anything that depresses muscle function will negatively affect ventilation (Ludders and Matthews, 1996). Birds are also very susceptible for hypoventilation due to dorsal recumbency positioning. This position causes visceral compression of the air sacs and can result in an overall 10-60% decrease in minute ventilation (Ludders and Matthews, 1996; Ellis, 2004). This can even be worsened if birds have food in their stomach. Complications of hypoglycemia and ketosis due to fasting are uncommon in larger raptors (O'Donnell and Morzenti, 1978), but they occur frequently in smaller sized species (Hall *et al.*, 2001). This is probably due to the high liver gluconeogenic enzyme activity of carnivorous birds (Migliorine *et al.*, 1973). Fasting in medium-large birds of prey, like the Harris's Hawk, is recommended during at least 4 to 6 hours before induction of anesthesia (Fitzgerald and Blais, 1993).

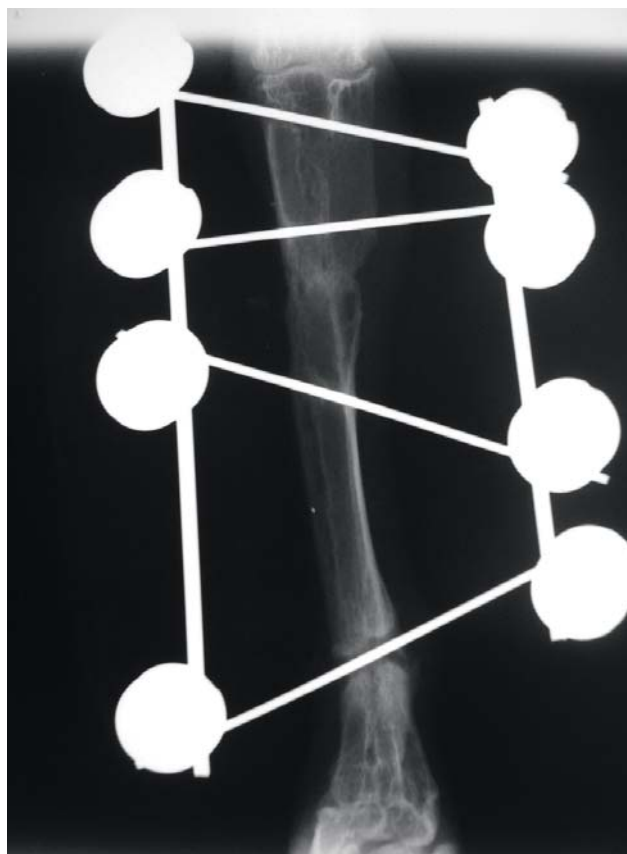


Figure 5. Follow-up radiographs 6 weeks after surgery showed a good fracture healing. Note the osteolysis mainly around the distal pin.

If the food status is unknown or when food has not been withheld in the hours leading up to surgery, precautions must be taken to prevent regurgitation and aspiration of food, which are frequent complications in raptors. These include intubation, blocking the pharynx with sponges, inclining the body and holding the patient in a vertical position during recovery (Redig, 2000). Because the food status was unknown in our patient and surgery was required, intubation and inclining the body to a more upward position were logical precautions to prevent regurgitation.

For birds, inhalation anesthesia offers several advantages compared to injectable anesthetics, including rapid induction and recovery, easier to control anesthetic depth and concurrent oxygen administration (Paul-Murphy and Fialkowski, 2001). Isoflurane is the first choice in birds due to the low blood/gas solubility, the lower myocardial irritability, the minimal liver metabolism and the fast recovery (Edling *et al.*, 2001) compared to halothane (Ludders and Matthews, 1996). Sevoflurane has comparable benefits but is less used as it is more expensive due to higher MAC (Naganobu *et al.*, 2000) and because of the possible nephrotoxicity of compound A, a substance that is produced by a reaction of sevoflurane with the carbon dioxide absorber in rebreathing circuits (Goldberg *et al.*, 1999; Ellis, 2004). IPPV (intermittent positive pressure ventilation) is only required if hypercapnea is present.

The volatile anesthetic can be delivered to the bird by mask, by endotracheal tube or by air sac perfusion. Induction masks are often used for short procedures, as well as for diagnostic procedures and small surgery (Lawton, 1996). Endotracheal intubation is easy to perform in birds, it is not invasive and it allows accurate ventilation monitoring. Air sac perfusion or air sac cannulation anesthesia is used when intubation is not possible or contraindicated, in emergency cases (Brown, 2006) or in intraocular surgery in birds (Korbel, 2002). A breathing tube is then placed in the caudal thoracic air sac (Mader, 2006) and oxygen with isoflurane is administered. Isoflurane is passed directly into the lungs and out of the glottis. Birds will not actually breathe during anesthesia because of the continuous flow of the anesthetic gas mixture (Mader, 2006). Endotracheal intubation was preferred in this case, as a mask would result in difficult ventilatory monitoring and high flow rates, while air sac perfusion would be too difficult in hind limb surgery.

As with all birds, raptors should be intubated with an uncuffed or an uninflated cuffed tube due to their closed tracheal cartilage rings (Ellis, 2004). Because of anesthetic gas leakage between ET tube and trachea, a higher flow of oxygen and a higher isoflurane concentration is necessary.

Hypothermia is a severe problem that can arise very suddenly, especially in smaller species and in combination with some anesthetics, such as acepromazine or other derivatives of the phenothiazine group (Pugh, 1964). Hypothermia affects the normal metabolic rate, resulting in peripheral vasoconstriction, bradycardia, hypotension and a long recovery (Ludders and Matthews, 1996). If severe ($<32^{\circ}\text{C}$), it can contribute to the development of ventricular fibrillation (Weinberg, 1993). Without the prevention of heat loss, the cloacal temperature in pigeons decreases from 41.0 to 32.7°C after one hour of anesthesia at room temperature (23°C) (Atalan *et al.*, 2002). Atalan *et al.* also reported a mean decrease in cloacal temperature of 4.5°C during the first 10 minutes of anesthesia. Electric heating pads and heat lamps are contra-indicated in birds because of the possibility of causing burns and hyperthermia. Circulating warm water blankets are considered a better alternative (Ellis, 2004) and were used in the case presented. Moreover, preheated saline was administered intravenously.

During the first 15 minutes, an attempt to lower the inspiratory fraction of isoflurane was made. The vaporizer setting was decreased from 3.8% to 1.6% , with a reduction in end tidal (ET) isoflurane concentration from 3.2% to 1.1% . The plane of anesthesia became too superficial and the bird showed slight movements, so the vaporizer setting was quickly increased to 5% resulting in an ET isoflurane concentration of up to 4.4% (Figure 3B). Although the minimum alveolar concentration (MAC) of isoflurane for birds is between 1.32% and 1.44% (Ludders *et al.*, 1990), the leakage of the tube, combined with a very light premedication, necessitated high isoflurane concentrations to maintain an adequate level of anesthesia.

Pulsoximetry is a non-invasive technique for measuring heart rate and oxygenation of the arterial blood. Probes can be applied to different anatomical locations to obtain reliable readings, but in birds the region around the gastrocnemius muscle is the preferred site (Korbel *et al.*, 1997). However, due to the movements during surgery, this region could not be used and attempts were made to apply the probes to the tongue and the wing. These attempts proved unsuccessful in terms of obtaining any measurement results. As birds have a very high heart rate (above 250) and pulsoxymeters are usually limited in readings, pulsoximetry often fails in the avian species. Generally, birds with a body weight of over 1000g have a heart rate that is less than 200 beats per minute (Harrison and Ritchie, 1994). Technically, therefore, it should have been possible to use pulsoximetry, and the reason for failure remains unknown.

In Figure 3 the respiratory parameters during the entire surgical procedure are shown. The diagram indicates that these parameters fluctuated over time. End tidal CO_2 concentration (ETCO_2) varied between 6.6% and 0.5% , with a respiration rate of between 0 and 34 breaths per minute (bpm). The variation in ETCO_2 can be explained not only by the respiration rate changes, but also by the aforementioned endotracheal tube leakage.

As birds have a very small tidal volume, but high respiratory frequency, an increase of inspiratory CO_2 fraction (FiCO_2) must be avoided. For this reason, high oxygen flows or non-rebreathing open or semi-open anesthetic circuits are advised for birds (Hall *et al.*, 2001). The FiCO_2 concentration in the case presented is negligible, which demonstrates that a low resistance pediatric rebreathing circle system with a small dead space can be used to anesthetize larger birds.

Meloxicam (0.5 mg/kg) was administered as post-operative analgesic. In avian species, little is known about the use of NSAID's (non-steroidal anti-inflammatory drugs), especially in raptors. The pharmacokinetics of a NSAID is different for each bird species, and dose extrapolation between species is not usable (Baert and De Backer, 2003). Meloxicam, orally and parenterally, is accepted to be less toxic for scavenging birds compared to carprofen, diclofenac (Cuthbert *et al.*, 2006) and flunixin (Clyde and Murphy, 1999). An acceptable dosage of meloxicam was derived empirically and appeared to be 0.5 mg/kg body weight once daily (Cuthbert *et al.*, 2006).

CONCLUSION

This report demonstrates the difficulties and possible solutions in avian, and more specific raptor, anesthesia. The use of an analgesic premedication followed by induction and maintenance of anesthesia by isoflurane resulted in a smooth induction, a relatively stable plane of anesthesia and an impeccable recovery.

REFERENCES

- Altman B.R. (1998). Twenty years of progress in avian anesthesia and surgery. *Journal of the American Veterinary Medical Association* 212, 1233-1235.
- Atalan G., Uzun M., Demirkan I., Yildiz S., Cenesiz M. (2002). Effect of Medetomidine-Butorphanol-Ketamine Anesthesia and Atipamezole on Heart and Respiratory Rate and Cloacal Temperature of Domestic Pigeons. *Journal of Veterinary Medicine A* 49, 281-286.
- Baert K., De Backer P. (2003). Comparative pharmacokinetics of three non-steroidal anti-inflammatory drugs in five bird species. *Comparative Biochemistry and Physiology Part C* 134, 25-33.
- Bednarz J.C. (1988). Cooperative Hunting Harris' Hawks (Parabuteo unicinctus). *Science* 239, 1525-1527.
- Borch J.E. (2005). Harris' Hawk - Parabuteo unicinctus. <http://users.cybercity.dk/~ccc12787/raptors/parabuteo.html>
- Brown C., Pilny A.A. (2006). Air sac cannula placement in birds. *Lab Animal* 35, 23-24.
- Clyde V.L., Murphy J. (1999). Avian analgesia. In: Fowler M.E., Miller R.E. (Editors). *Zoo and Wild Animal Medicine: Current Theory*. Saunders, Philadelphia, United States, 309-314.
- Cooper J.E. (1978). Anesthesia and surgery. In: Cooper J.E. (Editor). *Veterinary Aspects of Captive Birds of Prey*. Standfast Press, Gloucestershire, England, 143-155.
- Cuthbert R. Parry-Jones J., Green R.E., Pain D.J. (2006). NSAIDs and scavenging birds: potential impacts beyond Asia's critically endangered vultures. *Biology Letters* 22, 90-93.
- Edling T. M., Degernes L.A., Flammer K., Horne W.A. (2001). Capnographic monitoring of anesthetized African Grey Parrots receiving intermittent positive pressure ventilation. *Journal of the American Veterinary Medical Association* 219, 1714-1718.
- Ellis C. (2004). Avian Anesthesia. In: *Seminar Proceedings, Savab-Flanders Weekend*, Antwerp, 16.
- Fitzgerald G., Blais D. (1993). Inhalation anesthesia in birds of prey. In: Redig P. (Editor). *Raptor Biomedicine*. University of Minnesota Press, Minneapolis, 128-135.
- Goldberg M.E., Cantillo J., Gratz I., Deal E., Vekeman D., McDougall R., Afshar M., Zafeiridis A., Larijani G. (1999). Dose of compound A, not sevoflurane, determines changes in the biochemical markers of renal injury in healthy volunteers. *Anesthesia Analgesia*, 88, 437-445.
- Hall L.W., Clarke K.W., Trim C.M. (2001). Anesthesia of the species – birds. In: Hall L.W., Clarke K.W., Trim C.M. (Editors). *Veterinary Anesthesia*. 10th Edition. W.B. Saunders Company, Philadelphia, 472-475.
- Harcourt-Brown N.H. (1996). Foot and leg problems. In: Beynon P.H. (Editor). *Manual of Raptors, Pigeons and Waterfowl*. 1st Edition. BSAVA, Gloucestershire, England, 155.
- Harrison G.J., Ritchie B.W. (1994). Making distinctions in the physical examination. In: Ritchie G.J., Harrison G.J., Harrison L.R. (Editors). *Avian Medicine: Principles and Application*. Wingers, Lake Worth, 83.
- Heidenreich M. (1997). Anesthesia. In: Heidenreich M. (Editor). *Birds of Prey*. Blackwell Science, Oxford, England, 221-226.
- Korbel R., Lendl C., Baumgartner K., Gauckler A. (1997). Referenzschema für Anästhesie bei Zoo- und Wildvögeln. In: *Verhandlungen über das 38. Internationale Symposium über die Erkrankungen der Zoo- und Wildtiere*, Zürich, 195-204.
- Korbel R.T. (2002). Avian ophthalmology – principles and applications. In: *Proceedings of the World Small Animal Veterinary Association Congress*. Granada, Spain.
- Langlois I., Harvey R.C., Jones M.P., Schumacher J. (2003). Cardiopulmonary and anesthetic effects of isoflurane and propofol in hispaniolan amazon parrots (*Amazona ventralis*). *Journal of Avian Medicine and Surgery* 17, 4-10.
- Lawton M.P.C. (1996). Anesthesia. In: Beynon P.H. (Editor). *Manual of Raptors, Pigeons and Waterfowl*. 1st Edition. BSAVA, Gloucestershire, England, 79-88.
- Ludders J.W., Mitchell G.S., Rode J. (1990). Minimal anesthetic concentration and cardiopulmonary dose response of isoflurane in ducks. *Veterinary Surgery* 19, 304-307.
- Ludders J.W., Seaman G.C., Erb H.N. (1995). Inhalant Anesthetics and Inspiratory Oxygen: Implications for Anesthesia in Birds. *Journal of the American Animal Hospital Association* 31, 38-41.
- Ludders J.W., Matthews N. (1996). Anesthesia and immobilization of specific species: Birds. In: Thurmon J.C. (Editor). *Lumb and Jones' Veterinary Anesthesia*. Williams and Wilkins, Baltimore, 645-669.
- Mader G.D. (2006). Anesthesia in exotic pets. In: *Proceedings of the Latin American Veterinary Conference*. Lima, Peru, 39-52.
- Mansour A., Khachaturian H., Lewis M.E. Anatomy of CNS opioid receptors. *Trends in Neurosciences* 11, 308-314.
- Migliorini R.H., Linder C., Moura J.L., Veiga J.A.S. (1973). Gluconeogenesis in a carnivorous bird (black vulture). *American Journal of Physiology* 225, 1389-1392.
- Naganobu K., Fujisawa Y., Ohde H., Matsuda Y., Sonoda T., Ogawa H. (2000). Determination of the minimum anesthetic concentration and cardiovascular dose response for sevoflurane in chickens during controlled ventilation. *Veterinary Surgery* 29, 102-105.
- O'Donnell J.A., Garbett R., Morzenti A. (1978). Normal fasting plasma glucose levels in some birds of prey. *Journal of Wildlife Diseases* 14, 479-481.
- Paddleford R. (1986). Anesthetic management for birds of prey. In: Fowler M.E. (editor). *Zoo and Wild Animal Medicine*. 2nd Edition, WB Saunders, Philadelphia.
- Paul-Murphy J., Fialkowski J. (2001). Injectable anesthesia and analgesia of birds. In: Gleed R.D., Ludders J.W. (editors). *Recent Advances in Veterinary Anesthesia and Analgesia: Companion Animals*. International Veterinary Information Service, Ithaca. http://www.ivis.org/advances/Anesthesia_Gleed/paul/chapter_firm.asp?LA=1
- Pugh D.M. (1964). Acepromazine in veterinary use. *The Veterinary Record* 76, 439.
- Redig P.T. Anesthesia for raptor and swans with general principles applicable to other species of birds. http://www.cvm.umn.edu/academics/course_web/current/CVM6882/ANESTHE.htm
- Redig P.T., Ackermann J. (2000). Raptors. In: Dorrestein G.M., Lawton M., Tully T. (Editors). *Handbook of Avian Medicine*. Elsevier Science B.V., 180-214.
- Weinberg A.D. (1993). Hypothermia. *Annals of Emergency Medicine* 22, 370-377.