

Infectious coccygeal discospondylitis in an adult trotter horse

Infectieuze discospondylitis ter hoogte van de staartwervels bij een volwassen draver

¹M. Oosterlinck, ¹F. Pille, ¹F. Gasthuys, ²J. H. Saunders

¹ Faculty of Veterinary Medicine, Department of Surgery and Anaesthesiology of Domestic Animals, Ghent University, Salisburylaan 133, B-9820 Merelbeke, Belgium.

² Faculty of Veterinary Medicine, Department of Medical Imaging of Domestic Animals, Ghent University, Salisburylaan 133, B-9820 Merelbeke, Belgium.

maarten.oosterlinck@ugent.be

ABSTRACT

This case describes the clinical and radiographic appearance, medical treatment and long-term follow-up of a 6-year-old French trotter stallion that was referred with an acute onset of pain and swelling at the tail-head without a history of traumatic insult. Radiographic examination revealed multiple semicircular and millet-sized radiolucencies at the endplates of several adjacent caudal vertebrae, indicative of infective discospondylitis. The horse made a full clinical recovery after 7 weeks of antibiotic treatment with oral trimethoprim-sulfonamides and successfully resumed its athletic activities. Follow-up radiography after one year showed only slight residual irregularity at the epiphyses, without exuberant new bone formation or persisting radiolucencies.

SAMENVATTING

Een zesjarige Franse draverhengst werd aangeboden in de kliniek Heelkunde van de Faculteit Diergeneeskunde te Merelbeke (UGent) omwille van acute pijn en zwelling ter hoogte van de staartbasis zonder bekende traumatische oorzaak. Op het radiografisch onderzoek werden verschillende halfcirkelvormige en korrelvormige radiolucente zones aangetoond ter hoogte van de epifysen van aangrenzende staartwervels, indicatief voor infectieuze discospondylitis. De klinische symptomen verdwenen volledig na 7 weken antibioticumbehandeling met trimethoprim-sulfonamide. Het paard kon zijn sportieve carrière voortzetten. Op de radiografische controle één jaar later waren slechts milde overblijvende onregelmatigheden zichtbaar ter hoogte van de epifysen van de wervellichamen, zonder overvloedige nieuwbeenvorming noch duidelijke persisterende radiolucente zones.

INTRODUCTION

Discospondylitis is an inflammatory disorder that involves adjacent vertebral bodies and the interposed disc space (Denoix, 2007). This condition is rarely diagnosed in horses (Dyson, 2003; Stumpf and Litzke, 2005; Denoix, 2007) and its clinical and pathological features may overlap with vertebral body osteomyelitis (Markel *et al.*, 1986). Nevertheless, discospondylitis usually involves progressive degenerative changes at the level of the intervertebral disc and adjacent endplates in adult horses, while vertebral osteomyelitis is typically associated with juvenile sepsis and multiple site infections at the level of vertebral bodies in immunosuppressed foals (Markel *et al.*, 1986; Markel, 1992; Colbourne *et al.*, 1997; Hendrickson, 2002; Nixon, 2002; Pirie, 2003). The clinical significance of the degenerative disc lesions in adult horses remains

unclear since one study reported 103 cases with severe discospondylitis without clinical symptoms (Bollwein and Hänichen, 1989). The typical histological features in these cases were age-related disintegration of connective tissue fibers at the level of the intervertebral disc (Yovich *et al.*, 1985; Bollwein and Hänichen, 1989), together with a decreased cellularity (Yovich *et al.*, 1985).

Discospondylitis in adult horses rarely has an infective origin. Although extension of a local infection and traumatic events have been implicated in the development of discospondylitis, hematogenous bacterial spread is considered to be the most common route of intervertebral disc infection (Alward *et al.*, 2007). The isolated, tortuous, low blood flow regions of the vertebrae may be predisposed for localization of infection (Olchoway, 1994; Alward *et al.*, 2007), whereby trauma and subsequent disruption of circulation and

ultimately necrosis may be an inciting cause for deposition of bacteria (Adams *et al.*, 1985).

The symptoms of infective discospondylitis can be variable, including pain, stiffness, heat, swelling and sometimes intermittent fever (Sweers and Carstens, 2005). Secondary to spinal cord compression ataxia, weakness or spasticity may be present (Nixon, 2002). The appearance of neurological signs depends on the site of infection within the vertebral column and the degree of compression on the spinal cord (Chaffin *et al.*, 1995; Nixon, 2002). Compressive lesions in the caudal region can result in the "cauda equina syndrome" (Pirie, 2003).

Discospondylitis is most frequently localized in the cervical region (Foss *et al.*, 1983; Stadler *et al.*, 1988; Furr *et al.*, 1991; Markel, 1992; Giguère and Lavoie, 1994; Colbourne *et al.*, 1997; MacGillivray *et al.*, 2003; Sweers and Carstens, 2005; Speltz *et al.*, 2006), although thoracic (Markel *et al.*, 1986; Olchow, 1994; Hillyer *et al.*, 1996; Alward *et al.*, 2007), lumbar (Markel *et al.*, 1986, Giguère and Lavoie, 1994; Sweers and Carstens, 2005), sacral (Chaffin *et al.*, 1995) and coccygeal (Stumpf and Litzke, 2005) localizations have been described in horses. To the author's knowledge, only one case of coccygeal vertebral discospondylitis in an adult horse has been reported (Stumpf and Litzke, 2005). Important differences between the present case and the one previously reported will be discussed.

CASE REPORT

Case history

A 6-year-old French trotter stallion was referred to the equine hospital. The horse had not suffered from specific health problems or lameness in the past, and had been a successful athlete to that point. Twelve days prior to referral, the horse showed an acute onset of pain and a diffuse swelling at the tail-head without a history of a traumatic insult.

Clinical examination

On admission, the horse was found to be in good physical condition with normal body temperature and normal respiratory and cardiovascular auscultation. A diffuse swelling was present at the base of the tail. This swelling was localized at the dorsal midline, without concurrent fistula or draining tracts indicative of a perivertebral abscess. The horse clamped its tail tightly against the perineum when manipulation was attempted. The lumbar reflex was negative, while the tail and anal sphincter tones were normal. Transrectal palpation did not reveal any abnormalities. No lameness could be observed upon walking or trotting. It was concluded that the physical abnormalities were confined to the tail-head.

Radiographic examination

A left-to-right lateral radiographic projection of the coccygeal vertebrae (from Cd 3 to Cd 8) was obtained (Figure 1). The vertebral space between the third and fourth vertebrae was enlarged, while the space between the fifth and sixth vertebra appeared narrowed. The cranial end of the third coccygeal vertebra was slightly osteolytic and showed adjacent sclerosis. The caudal end of the third coccygeal vertebra showed a semicircular radiolucency (5 x 3 mm) and the fourth coccygeal vertebra showed a circular radiolucency (5 x 3 mm) at its cranial border. The adjacent coccygeal vertebrae (Cd 4-7) showed millet sized radiolucencies in their endplates, which created a moth-eaten-like aspect. New bone formation was not visible.

Other diagnostic procedures

Aerobic bacterial culturing of a blood sample did not yield bacterial growth. Blood hematology and biochemistry were within the normal limits.

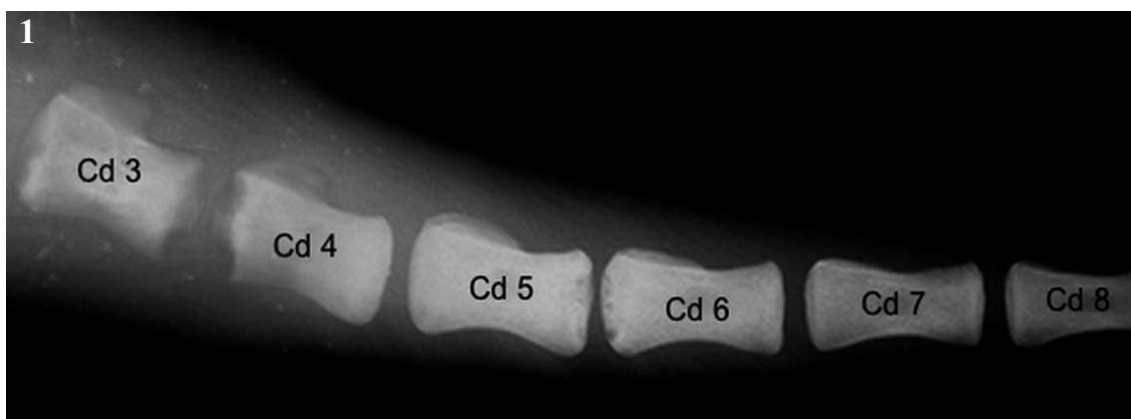


Figure 1. Left-right lateral projection from the third (Cd 3) to the eight (Cd 8) coccygeal vertebrae. The vertebral space between the third and fourth vertebrae is enlarged while the space between the fifth and sixth vertebra is narrowed. The cranial end of the third coccygeal vertebra is slightly osteolytic and shows adjacent sclerosis. The caudal end of the third coccygeal vertebra shows a semicircular radiolucency (5 x 3 mm) and the fourth coccygeal vertebra shows a circular radiolucency (5 x 3 mm) at its cranial border. The adjacent coccygeal vertebrae (Cd 4-7) present millet sized radiolucencies in their endplates which create a moth-eaten-like aspect.

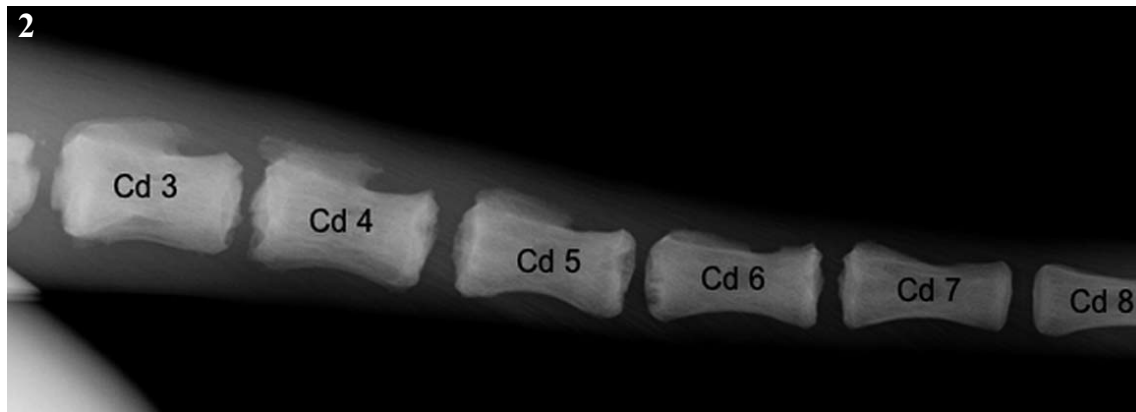


Figure 2. Follow-up left-right lateral projection of the same region as Figure 1 obtained 1 year after initial presentation. The intervertebral space between the third (Cd 3) and the fourth (Cd 4) coccygeal vertebrae is narrowed while it was enlarged on initial presentation. The end plates on the intervertebral spaces between the fourth and the fifth vertebrae and between the sixth and the seventh vertebrae are slightly irregular while they were normally outlined on the initial radiographs. The intervertebral space between the fifth and the sixth vertebrae is unchanged. Globally, the end plates from the third to the seventh vertebrae are slightly irregular due to non-active new bone formation.

Diagnosis

Based on the anamnesis, the clinical examination and the pathognomonic radiographic signs, the diagnosis of infective coccygeal discospondylitis was made.

Treatment

The horse was hospitalized and treated with trimethoprim-sulfonamide (Emdotrim® 60% Mix, Ecuphar, Oostkamp, Belgium, 30 mgkg⁻¹ bwt twice daily, orally) and non-steroidal anti-inflammatory drugs (flunixin meglumine, Finadyne® oral paste, Schering Plough Animal Health, Brussels, Belgium, 1.1 mgkg⁻¹ bwt, orally). No obvious clinical improvement was seen after 7 days. The horse was discharged from the clinic and confined to a little paddock. Antibiotic treatment was continued for another 6 weeks. The swelling at the tail-head subsided after 3 weeks of antibiotic treatment; pain on palpation remained obvious for another 4 weeks. After this period, a gradual improvement was seen and the horse resumed training and competition.

Long-term follow-up

One year after initial presentation, the horse has already won two out of five races. Radiographically, only a slightly irregular delineation was visible at the endplates of several coccygeal vertebrae, with mild new bone formation and adjacent sclerosis at the location of the previous osteolytic lesions on the third and fourth coccygeal vertebrae (Figure 2). The endplates between the sixth and the seventh vertebrae showed an irregular delineation, which had not been seen in such a pronounced form on the first radiographs.

DISCUSSION

Diagnosis

This discospondylitis case presented an acute onset of inflammatory symptoms (severe pain, swelling, loss of function) and radiological findings compatible with infection. No neurological symptoms indicative of ‘cauda equina syndrome’ were noticed. The outcome of this case precludes neoplasia as a differential diagnosis. However, the possibility of a neoplastic lesion should never be overlooked since vertebral body hemangiosarcoma has been described in the cervical spine of a 16-year-old donkey (MacGillivray *et al.*, 2003).

In the present case, the diagnosis was based primarily on the radiological findings. In other reports of vertebral osteomyelitis, radiographic lesions were described as not being evident for 2 to 8 weeks after the onset of clinical signs (Chaffin *et al.*, 1995; Hendrickson, 2002). In the present horse, radiographic lesions were already clearly visible 12 days after onset of clinical symptoms. In contrast to another report on coccygeal discospondylitis (Stumpf and Litzke, 2005), osteolytic lesions rather than progressive new bone formation were seen. The overall evolution of the radiographic signs at the one-year follow-up was considered to be remarkably favorable.

In the present case, no other imaging modalities than radiography were used. In horses, radiography remains the primary diagnostic tool in the diagnosis of discospondylitis (Hendrickson, 2002), mainly because of financial and practical limitations. Nevertheless, early diagnosis of an infective spinal column lesion might require the use of nuclear scintigraphy with ciprofloxacin, which is a specific tracer for infectious lesions (Hendrickson, 2002). Without the use of ciprofloxacin, targeted radiography is essential to confirm diagnosis since normal bone-phase scintigraphy is sensitive but fairly non-specific (Markel *et al.*, 1986;

Hillyer *et al.*, 1996). Ultrasonography is indicated in the presence of a perivertebral abscess (Hendrickson, 2002; Nixon, 2002) whereby ultrasound-guided needle-aspiration can be attempted (Sweers and Carstens, 2005). In horses with neurologic signs, myelography has been used to document spinal cord compression (Foss *et al.*, 1983). The use of computed tomography for the diagnosis of vertebral body osteomyelitis has been reported in a foal (Stewart *et al.*, 2007).

Treatment

Successful treatment of infective spinal column lesions generally depends on timely diagnosis, isolation of the causative organism(s), appropriate antimicrobial treatment and, in some cases, surgical decompression of the spinal cord, curettage of infected bone or amputation. Tail amputation was not considered to be an option in this stallion because trotters wear a 'crupper' during training and competition. This 'crupper' is the part of the harness that attaches to the back of the harness and runs along the horse's back and under his tail; it is essential to hold the harness in place. Surgical curettage was considered too invasive.

Isolation of the causative bacteria in discospondylitis is often unsuccessful (Adams *et al.*, 1985; Olchowy, 1994). Also in the present case, blood culture revealed no pathogens after 7 days of incubation. Culture directly from biopsies obtained by ultrasound-guided needle aspiration was not attempted.

This case clearly illustrates the dilemma that most veterinarians experience almost daily: one must always strive for the most accurate diagnosis, but at the same time veterinary medicine very often has to cope with economic constraints. In the present case, it would have been scientifically more correct to make every attempt to obtain a bacterial culture, but the high probability of obtaining false negative results, the additional costs and the invasiveness of these procedures were limiting factors. However, it is clear that in the event of positive culture and subsequent antibiotic sensitivity results, treatment could have been optimized. In the absence of culture and antibiotic susceptibility testing results, broad-spectrum antibiotic therapy was initiated. With discospondylitis, a wide variation of offending organisms has been described and long-term antibiotic treatment (3 to 6 months) is recommended (Markel *et al.*, 1986; Markel, 1992; Hillyer *et al.*, 1996). In the previously reported case of coccygeal discospondylitis (Stumpf and Litzke, 2005), no bacterial culture was obtained and treatment with enrofloxacin was instituted. However, this antibiotic should be preserved for the treatment of infections caused by Gram-negative bacteria resistant to alternative, first-choice drugs (Walker and Dowling, 2006). Furthermore, the use of enrofloxacin is considered "off-label" in horses, though the legal considerations may vary between countries. Typically, broad-spectrum antibiotic therapy in horses involves the combination of a beta-lactam antibiotic (e.g. penicillin G) and an aminoglycoside (e.g. gentamicin), a 3rd- or 4th-

generation cephalosporin or a combination of trimethoprim and sulfonamides (Giguère, 2006). The ease of oral administration, together with the limited costs even after several weeks of treatment, favored the use of a trimethoprim-sulfonamide combination in the present case. Potentiated sulfonamides have the advantage of good distribution into tissues, safety, a relatively broad-spectrum, bactericidal activity, and oral administration. A disadvantage is the antagonism of action by infected tissue debris (Prescott, 2006). Furthermore, trimethoprim-sulfonamide combinations have already been used successfully to treat equine discospondylitis (Hillyer *et al.*, 1996). We used a twice daily protocol, despite the once-daily registration recommendations for the use of potentiated sulfonamide products, because previous studies have demonstrated that in the case of diaminopyrimidines (i.e. trimethoprim), therapeutic plasma concentrations are attained only with twice daily dosing (Bertone *et al.*, 1988; Gustafsson *et al.*, 1999; Dowling, 2004). Although 7 weeks of antibiotic treatment was successful in this case, discontinuation of antibiotic treatment with trimethoprim-sulfonamides after six weeks has been associated with recidivism of discospondylitis (Hillyer *et al.*, 1996).

CONCLUSION

This case report illustrates that infectious coccygeal discospondylitis with clear osteolytic changes can develop in a healthy adult horse, without concurrent wounds or fistulation. After 7 weeks of antibiotic treatment with trimethoprim-sulfonamides (30 mg/kg⁻¹ bwt twice daily, orally), the clinical and radiographic evolution was remarkably positive.

REFERENCES

- Adams S.B., Steckel R., Blevins W. (1985). Diskospondylitis in five horses. *Journal of the American Veterinary Medical Association* 186, 270-272.
- Alward A.L., Pease A.P., Jones S.L. (2007). Thoracic discospondylitis with associated epiaxial muscle atrophy in a Quarter horse gelding. *Equine Veterinary Education* 19, 67-71.
- Bertone A.L., Jones R.L., McIlwraith C.W. (1988). Serum and synovial steady-state concentrations of trimethoprim and sulfadiazine in horses with experimentally induced infectious arthritis. *American Journal of Veterinary Research* 49, 1681-1686.
- Bollwein A., Hänichen T. (1989). Altersabhängige Veränderungen an den Zwischenwirbelscheiben der Halswirbelsäule des Pferdes. *Tierärztliche Praxis* 17, 73-76.
- Chaffin M.K., Honnas C.M., Crabill M.R., Schneiter H.L., Brumbaugh G.W., Briner R.P. (1995). Cauda equine syndrome, discospondylitis, and a paravertebral abscess caused by *Rhodococcus equi* in a foal. *Journal of the American Veterinary Medical Association* 206, 215-220.
- Colbourne C.M., Raidal S.L., Yovich J.V., Howell J.Mc.C., Richardson J.L. (1997). Cervical diskospondylitis in two horses. *Australian Veterinary Journal* 75, 477-479.
- Denoux J.M. (2007). Discovertebral pathology in horses. *Equine Veterinary Education* 19, 72-73.

- Dowling P. (2004). Potentiated sulfonamides. In: Bertone J.J. and Horspool L.J. (eds.). *Equine Clinical Pharmacology*, W.B. Saunders Co, London, pp. 35-38.
- Dyson S.J. (2003). The cervical spine and soft tissues of the neck. In: Ross M.W. and Dyson S.J. (eds.). *Diagnosis and Management of Lameness in the Horse*, W.B. Saunders Co, Philadelphia, pp. 529.
- Foss R.R., Genetzky R.M., Riedesel E.A., Graham C. (1983). Cervical intervertebral disc protrusion in two horses. *Canadian Veterinary Journal* 24, 188-191.
- Furr M.O., Anver M., Wise M. (1991). Intervertebral disk prolapse and diskospondylitis in a horse. *Journal of the American Veterinary Medical Association* 198, 2095-2096.
- Giguère S. (2006). Antimicrobial drug use in horses. In: Giguère S., Prescott J.F., Baggot J.D., Walker R.D., Dowling P.M. (eds.). *Antimicrobial Therapy in Veterinary Medicine*. 4th ed., Blackwell Publishing, Iowa, pp. 456.
- Giguère S., Lavoie J.P. (1994). Rhodococcus equi vertebral osteomyelitis in 3 Quarter Horse colts. *Equine Veterinary Journal* 26, 74-77.
- Gustafsson A., Baverud V., Franklin A., Gunnarson A., Ögren G., Ingvast-Larsson C. (1999). Repeated administration of trimethoprim/sulfadiazine in the horse-pharmacokinetics, plasma protein binding and influence on the intestinal microflora. *Journal of Veterinary Pharmacology and Therapeutics* 22, 20-26.
- Hendrickson D.A. (2002). The thoracolumbar spine. In: Stashak T.S. (ed.). *Adams' Lameness in Horses*. 5th Ed., Lippincott Williams & Wilkins, Philadelphia, pp. 1059-1060.
- Hillyer M.H., Ines J.F., Patteson M.W., Barr A.R. (1996). Diskospondylitis in an adult horse. *The Veterinary Record* 139, 519-521.
- MacGillivray K.C., Sweeney C.R., McLearn R., Habecker P.L. (2003). Vertebral body hemangiosarcoma in a 16-year-old miniature Sicilian donkey. *Veterinary Radiology and Ultrasound* 44, 429-432.
- Markel M.D. (1992). Diseases of the spine. In: Robinson N.E. (ed.). *Current Therapy in Equine Medicine*. 3th Ed., W.B. Saunders Co, Philadelphia, pp. 109-113.
- Markel M.D., Madigan J.E., Lichtensteiger C.A., Large S.M., Hornof W.J. (1986). Vertebral body osteomyelitis in the horse. *Journal of the American Veterinary Medical Association* 188, 632-634.
- Nixon A.J. (2002). Wobbler syndrome. In: Stashak T.S. (ed.). *Adams' Lameness in Horses*. 5th Ed., Lippincott Williams & Wilkins, Philadelphia, pp. 1073-1074.
- Olchoway T.W. (1994). Vertebral body osteomyelitis due to Rhodococcus equi in two Arabian foals. *Equine Veterinary Journal* 26, 79-82.
- Pirie R.S. (2003). Bladder, rectal, anal, and tail paralysis; perineal hypalgesia; and other signs of cauda equine syndrome. In: Robinson N.E. (ed.). *Current Therapy in Equine Medicine*. 5th Ed., W.B. Saunders Co, St. Louis, pp. 755-760.
- Prescott J.F. (2006). Sulfonamides, diaminopyrimidines, and their combinations. In: Giguère S., Prescott J.F., Baggot J.D., Walker R.D., Dowling P.M. (eds.). *Antimicrobial Therapy in Veterinary Medicine*. 4th Ed., Blackwell Publishing, Iowa, pp. 249-262.
- Speltz M.C., Olson E.J., Hunt L.M., Pool R.R., Wilson J.H., Carlson C.S. (2006). Equine intervertebral disk disease: a case report. *Journal of Equine Veterinary Science* 26, 413-419.
- Stadler P., Van Den Berg S.S., Tustin R.C. (1988). Servikale intervertebrale diskus prolaps in 'n perd. *Journal of the South African Veterinary Association* 5, 31-32.
- Stewart A.J., Salazar P., Waldrige B.M., Hathcock J., Whitley E.M., Welles E.G. (2007). Computed tomographic diagnosis of a pathological fracture due to rhodococcal osteomyelitis and spinal abscess in a foal. *Equine Veterinary Education* 19, 231-235.
- Stumpf G., Litzke F. (2005). Diskospondylitis an der Schwanzwirbelsäule beim Pferd. *Tierärztliche Praxis* 34, 52-55.
- Sweers L., Carstens A. (2005). Imaging features of diskospondylitis in two horses. *Veterinary Radiology and Ultrasound* 47, 159-164.
- Walker R.D., Dowling P.M. (2006). Fluoroquinolones. In: Giguère S., Prescott J.F., Baggot J.D., Walker R.D., Dowling P.M. (eds.). *Antimicrobial Therapy in Veterinary Medicine*. 4th ed., Blackwell Publishing, Iowa, pp. 280.
- Yovich J.V., Powers B.E., Stashak T.S. (1985). Morphologic features of the cervical intervertebral disks and adjacent vertebral bodies of horses. *American Journal of Veterinary Research* 46, 2372-2377.

Pluimveepraktijk Zuid Nederland BV

Pluimveepraktijk Zuid-Nederland BV is een organisatie van gespecialiseerde, erkende pluimveedierenartsen. Ter versterking van ons enthousiaste team, zijn we op dit moment op zoek naar een.....

Pluimvee dierenarts m/v

Wij zoeken een enthousiaste dierenarts, met uitgebreide interesse (ervaring niet noodzakelijk) in de pluimvee, met goede contactuele eigenschappen en die in staat is te anticiperen in een markt die continue in beweging is.

Wij zijn een praktijk met een vooruitstrevende visie, waarin advies, management en laag diergeneesmiddel verbruik hoog in het vaandel staat. Een pluimveedierenarts binnen PZN bv is verantwoordelijk voor zijn eigen groep klanten, ondersteund door een management programma en een uitgebreide database. Daarnaast is PZN bv actief in diverse projecten in het buitenland.

Sollicitatie en informatie

Wilt u meer informatie over deze vacature of wilt u reageren? Neem dan contact op met Dhr. AHJ Weekers, telefoon 06 51403392 of via pzn@poultry.nl. Zie voor meer informatie ook op www.pluimveepraktijken.nl