

A transposition flap for reconstructing a large skin defect over the stifle and proximal tibia in a dog after removal of a hemangiopericytoma

Een transpositieflap voor de reconstructie van een uitgebreid huiddefect na de verwijdering van een hemangiopericytoom rond het kniegewricht en de proximale tibia bij een hond

¹J.P. de Vos, ²J. Butinar

¹De Ottenhorst, Clinic for Companion Animal Medicine and Veterinary Oncology Referral Center, van Diemenstraat 83, 4535 AR Terneuzen, The Netherlands

² Animal Hospital Postojna, Cesta v Staro vas 14, 6230 Postojna, Slovenia

jpdevos@zeelandnet.nl

ABSTRACT

A 10-year-old female Belgian Malinois shepherd dog was presented because of an advanced recurrence of an intra- and subcutaneous hemangiopericytoma on the cranial aspect of the stifle. Ultrasound examination revealed a multi-lobular well demarcated mass. The tumor was excised with wide margins and the defect of around 300 degrees of circumference on the lateral, cranial, and medial part of the stifle and proximal tibial area was covered with a transposition skin flap, originating from the cranio-medial thigh and inguinal region. Healing was uncomplicated and 13 months after surgery there was still no evidence of recurrence of the tumor.

To the authors' knowledge, this is the first report to describe this reconstructive surgical technique around the knee joint in a dog.

SAMENVATTING

Een Mechelse Herder teef van 10 jaar oud werd aangeboden voor onderzoek en behandeling van een uitgebreid recidief van een intra- en subcutaan hemangiopericytoom. De tumor was gelokaliseerd op de voorzijde van de knie en de proximale tibia. Op echografisch onderzoek werd een multilobulaire en duidelijk afgegrensde massa getoond. Het gezwel werd chirurgisch verwijderd met ruime marges. Het ontstane huiddefect strekte zich 300 graden rondom het kniegewricht en de proximale tibia uit. Het werd bedekt met een geometrisch complexe transpositieflap, afkomstig van het cranio-mediale deel van de huid van de linkerdijs- en -lies. Het genezingsproces verliep zonder complicaties en 13 maanden na chirurgie was de tumor nog steeds in volledige remissie.

Voor zover bekend bij de auteurs, is dit de eerste keer dat een dergelijke chirurgische reconstructie rond de knie bij een hond wordt beschreven.

INTRODUCTION

Removal of large soft tissue sarcomas on the extremities of dogs and cats can be a challenge to the surgeon and often require major reconstructive procedures. On the distal part of the extremities, simple reconstructive techniques such as undermining, and single and multiple relaxing incisions may solve wound closing problems in minor to moderate defects. Axial pattern flaps are often applicable for reconstructive purposes in the proximal parts of the limbs. A reverse saphenous conduit flap is able to cover more distally located lesions on the hind leg, and in short legged dogs occasionally a caudal superficial epigastric flap can also cover defects on distal parts of this limb. For large defects, local flaps or free skin grafts can be used. Examples of all the axial pattern

skin flaps, of which the vascular territories or angiosomes are clearly defined by arborizing direct cutaneous vessels, can be found in prominent surgical textbooks. However, vascularization of local flaps relies on the subdermal vascular plexus, which is inconsistent compared to the vessels incorporated in the axial pattern flaps. Design of subdermal plexus flaps relies on the imagination and experience of the surgeon, besides sparse literature describing their geometry (Pavletic, 1999).

The purpose of this report is to describe the surgical management of a large hemangiopericytoma on the cranial part of the stifle joint in a dog, using a transposition skin flap to cover the surgically created defect. The geometry of this subdermal plexus flap was complex but crucial for a successful outcome.

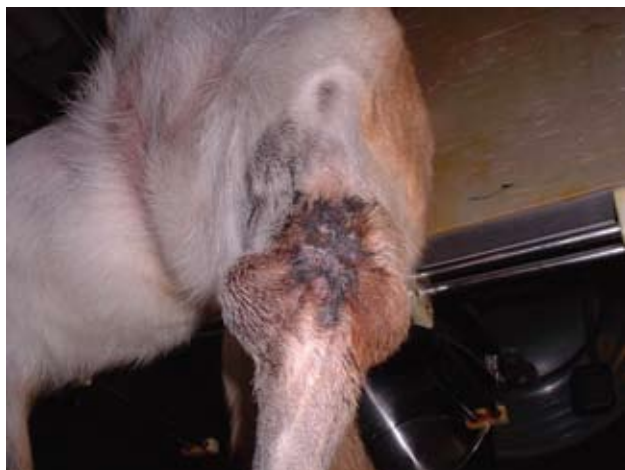

Figure 1. Location of the hemangiopericytoma on the cranial part of the left stifle before surgery.

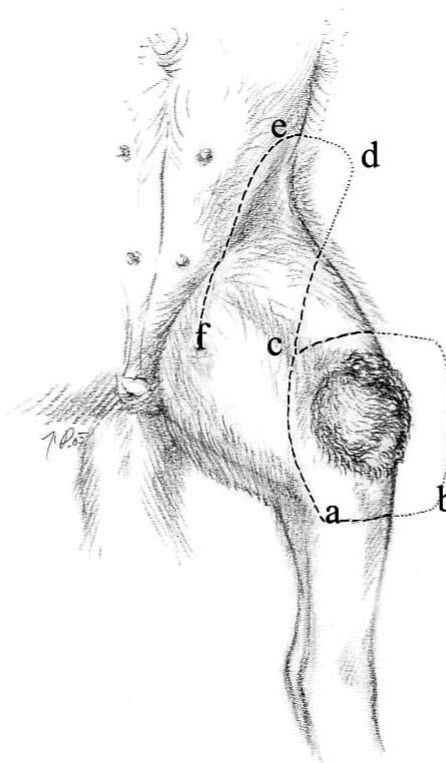


Figure 2. Planning of the surgical removal of the tumor and origin of the transposition flap. The length of the flap was determined by measuring the transverse distance a-b of the primary defect. For additional reserve in length, half of the longitudinal distance a-c was added. The total length a-d of the flap was approximately 25 cm. The width of the flap was half of the length, consequently 2 cm less compared to the longitudinal distance of the primary defect. The medial border of the flap was parallel to the lateral border. (drawing by Janez Plestenjak)

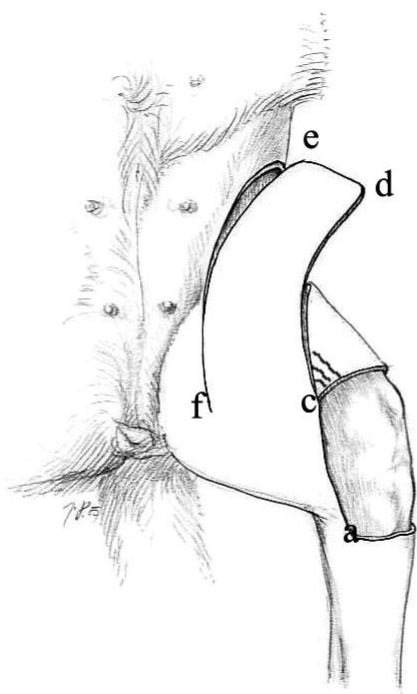


Figure 3. The first incision for harvesting the transposition flap was made through a proximal extension of the medial incision line a-c of the primary defect. The most lateral border a-d of the flap curved from medial to lateral over the cranial thigh, terminating into the flank fold. Subsequently the most proximal incision d-e, determining the top of the flap, was made. The medial incision e-f was made stepwise in a proximal to distal direction, followed by careful undermining of the successively created parts of the flap with Metzenbaum scissors. The extent of the medial incision was not made longer than necessary to transpose the flap into the primary defect and also undermining of the base of the flap was prevented. This guaranteed a broad base with maximum blood supply of the flap. To prevent necrosis, the shaded marked skin area proximo-lateral of point c was removed, creating a rounded wound edge. (drawing by Janez Plestenjak)

MATERIAL AND METHODS

A 10-year-old, 32-kg, spayed female Belgian Malinois shepherd dog was referred to De Ottenhorst

Clinic for Companion Animals in Terneuzen, The Netherlands. The dog had a recurrence of a hemangiopericytoma on the medial, cranial and lateral aspect of the left stifle and proximal tibia (Figure 1). The tumor was initially removed by the referring veterinarian 14 months earlier and the diagnosis hemangiopericytoma was confirmed at that time by histopathology. According to the owner, first there was dehiscence of the suture line, within the first week after initial surgery and then recurrence of the tumor became visible within a few months.

At time of presentation the multi-lobular mass measured 13 cm in the transversal direction, and 8 cm in the longitudinal direction of the limb. Regional lymph nodes were not enlarged, and additional clinical exam, including three-view thoracic X-rays, showed no evidence of metastatic tumor disease. The owner declined CT or MRI imaging to accurately determine the extent of the mass, but agreed with an ultrasound examination. Ultrasound showed a multi-lobular process with a homogeneous hypo-echogenic appearance. There was a clear separation visible between the tumor and the deep structures underneath the tumor. Ultrasound also showed no evidence of metastases in the abdominal cavity. A needle core biopsy of the tumor was submitted for histopathology, which confirmed the mass to be a hemangiopericytoma again. A routine complete blood count and

biochemical blood exam showed no abnormalities.

Based on the tumor type and location, wide surgical excision with reconstruction of the surgically created defect, was planned. The adverse movement associated with a peri-articular area poses a challenge to avoid tension and also required a well perfused flap for the reconstruction. Two techniques were assessed. A classical caudal superficial epigastric flap, consisting of 3.5 mammary glands was pre-measured and considered to be of insufficient length to cover the complete defect. Therefore the final decision was to close the defect with a non-conventional transposition skin flap originating from the left cranio-medial thigh and inguinal region.

The dog was pre-medicated with acepromazine, methadone, and atropine^a i.m., was induced with sodium-thiopental^b i.v. and was maintained on O₂ and isoflurane. Pre-operatively 4 mg/kg carprofen^c and 20 mg/kg amoxicillin/clavulanic acid^d were delivered i.v. Anesthesia and recovery were uneventful.

The tumor was surgically removed with 2 cm lateral and medial margins, and 3 cm distal and proximal margins, creating a 300 degrees rectangular skin defect with rounded corners, extending from the patellar region to the proximal half of the tibial area (Figures 2 and 3). To guarantee removal of the deep tumor barriers, the dissection plane included the fascia lata, the superficial fascia of the tibialis anterior, sartorius and gracilis muscles. In the areas where no muscle fascia was present under the mass, the superficial layer of the joint capsule and patellar ligament were removed.

A skin flap for transposition into the surgically created primary defect, with a broad base dorso-medial to the wound, was harvested from the cranio-medial thigh and inguinal area. The outlining of the flap was marked on the skin with waterproof ink. Detailed information regarding the planning and incisional procedure is depicted in Figures 2 and 3.

The cutaneous muscle was saved in the more proximal parts of the flap and proceeding distally, where this muscle was not visible anymore, undermining was carried out deeply to the level of the fascia of the underlying muscles. This way, the subdermal vascular plexus in the flap was preserved during undermining.

Handling and fixating the flap during the harvesting and suturing procedure was done without using forceps, only touching the flap and skin edges manually. The reason for this was to prevent crushing of the micro-vasculature in the flap and adjacent skin edges, which may lead to wound dehiscence. Hemostasis in the wound bed was achieved using bipolar electrocautery. After harvesting, arterial bleeding was noticed at all cut edges of the flap, indicating sufficient blood supply for survival.

The secondary defect was closed with a simple in-

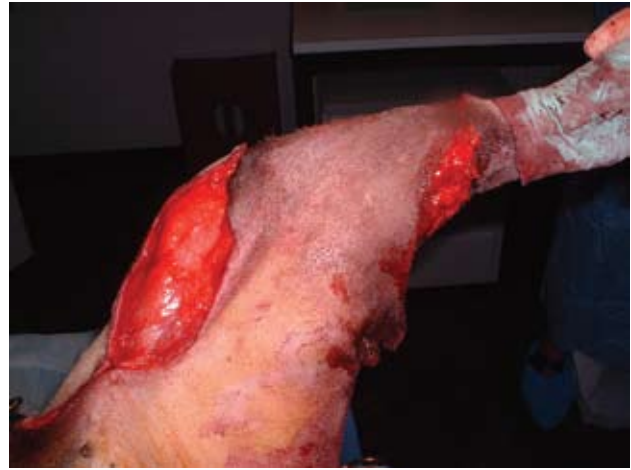


Figure 4. Transposition of the flap into the surgically created defect after tumor removal.

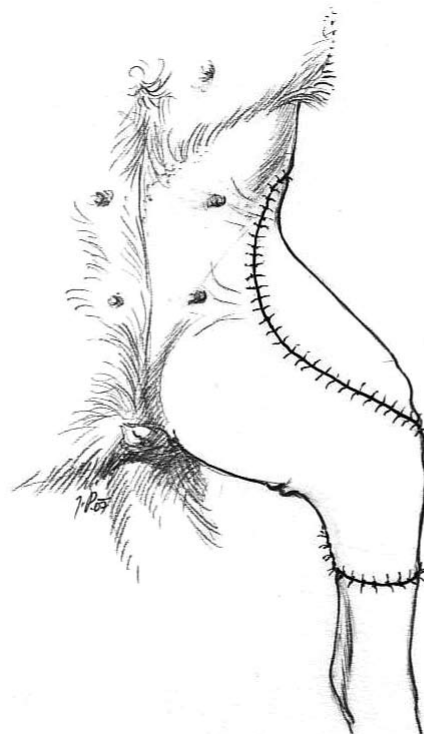


Figure 5. Schematic drawing of the transposition flap sutured into the surgically created defect and closure of the secondary defect. (drawing by Janez Plestenjak)

errupted subcutaneous suture line of 3/0 polyglactin910^e suture material and simple interrupted polyglactin910^e 3/0 skin sutures. The flap then was sutured into the primary defect. First, the proximal and distal wound edges of the primary defect were undermined and advanced with subcutaneous walking sutures of 3/0 polyglactin910^e for 2 cm towards the centre of the defect. This way the proximo-distal distance of the primary defect equalized the width of

THERAPEUTICALS USED

^a Acetadon (Eurovet Animal Health, The Netherlands), ^b Pentothal (Abbott BV, Hoofddorp, The Netherlands), ^c Rimadyl injection fluid (Pfizer, Capelle a/d IJssel, The Netherlands), ^d Augmentin 500/100 (GlaxoSmithKline BV, Zeist, The Netherlands), ^e Vicryl Ethicon (Johnson & Johnson, Belgium), ^f Monocryl Ethicon (Johnson & Johnson, Belgium), ^g Rimadyl tablet 50 mg (Pfizer, Capelle a/d IJssel, The Netherlands), ^h Synulox tablet 250 mg (Pfizer, Capelle a/d IJssel, The Netherlands), ⁱ Baytril tablet 150 mg (Bayer BV, Animal Health Division, Mijdrecht, The Netherlands), ^j Cremor Triamcinoloni 0,1% (Pharmachemie BV, Haarlem, The Netherlands)

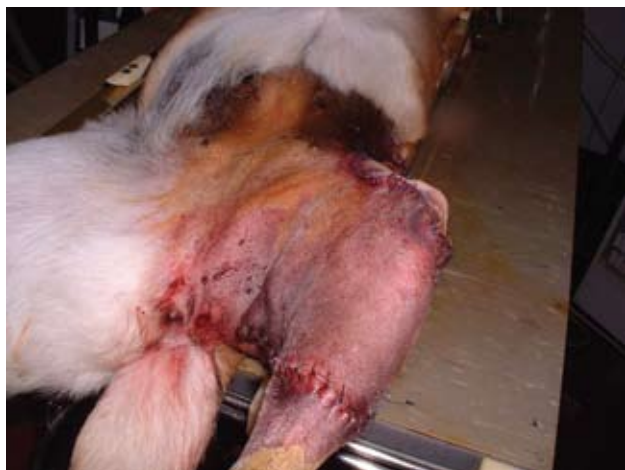

Figure 6. Direct post-operative medial view, indicating the broad base of the transposition flap.

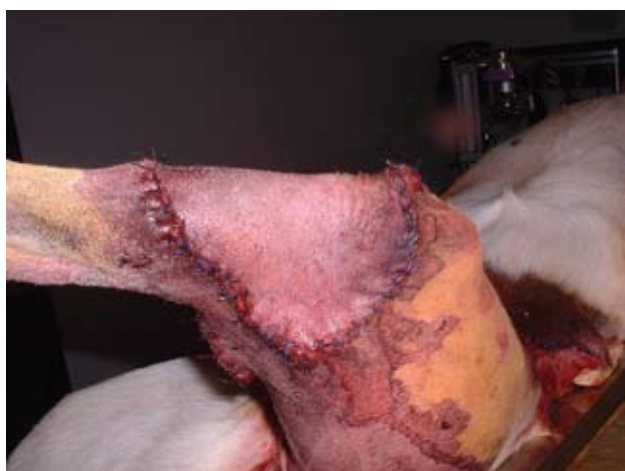

Figure 8. Direct post-operative lateral view of the transposition flap. Clearly visible is the small bridge of pre-existing skin in the caudal bend of the knee.

the flap and made tensionless suturing of the flap into the primary defect possible. Apposition of the subcutaneous layers at the edges of the flap and the primary defect was achieved with simple interrupted sutures of 3/0 polyglactin910° suture material. Approximation of the skin edges was performed with simple interrupted poliglecaprone25^f 3/0 sutures (Figures 5, 6, 7 and 8). No sutures were placed between the flap and the underlying muscles and a drain was not used. A “dog-ear” was created at the distal base of the flap (Figure 7). This area was supporting the blood supply of the flap and therefore could not be removed. A supportive bandage consisted of dry gauze compresses, cotton wool and an elastic bandage. The bandage was changed every 48 hours for a period of 10 days post-operative. The dog had to wear an Elizabethan collar, and received 2 mg/kg carprofen^g twice daily, 12.5 mg/kg amoxicillin/clavulanic acid^h twice daily and 5 mg/kg enrofloxacinⁱ once daily per os during 10 days.

Histopathology of the excised tumor confirmed the diagnosis hemangiopericytoma and the margins were considered free of neoplastic cells. Healing was uncomplicated (Figures 9 and 10). The only problem encountered was the dog creating 3 months after surgery a chronic well demarcated lick dermati-

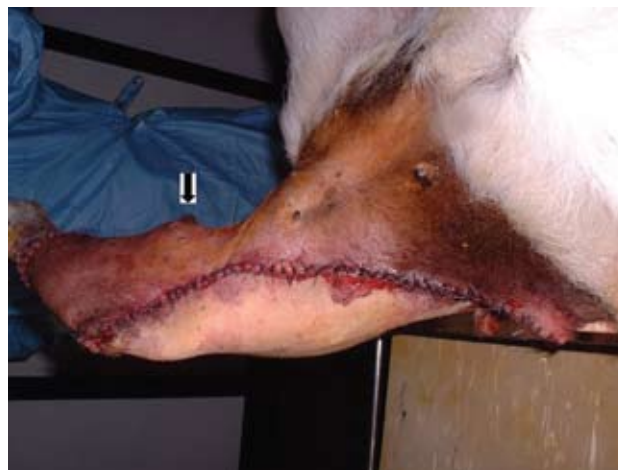

Figure 7. Direct post-operative cranio-medial view of the transposition flap. The arrow indicates a “dog-ear” in the distal part of the base of the flap, originating from point a in figures 2 and 3 and supporting the blood supply of the flap.

tis, located in the most proximal part of the flap and the adjacent skin (Figure 11). This had to be treated with local application of triamcinolon crème^j twice daily during 6 weeks. During this period the dog had to wear an Elizabethan collar on a regular base to prevent licking. 13 months after surgery clinical exam still showed no evidence of recurrence of the tumor but the owner reported incidental recurrence of licking on the same spot.

DISCUSSION

Fundamental to any reconstructive surgical wound repair are careful planning, meticulous atraumatic tissue handling, and good hemostasis with bipolar electrocautery.

Subdermal plexus flaps belong to the armamentarium of the surgical oncologist and proved to be useful for reconstruction of defects on head, trunk and limbs. The most commonly employed local flaps are advancement, rotation and transposition flaps. Rotation and transposition flaps have in common a pivot point and an arc through which the flap is rotated. The radius of this arc is the line of greatest tension of the flap, thus requiring special attention to ensure that the line of greatest tension from the pivot point to the most distal part of the flap, indicated in Figures 2 and 3 by the line **f-d** becoming **f-b** after transposition, is of sufficient length. Outlining of the flap to be transferred from a distance should also be done with an additional reserve in length, so that the base of the flap will not be kinked or under undue tension during transfer (Pavletic, 1999).

The precarious nature of the blood supply of subdermal plexus flaps severely limits flap design. In areas of the body where cutaneous muscle exists, vessels of the subdermal plexus run superficial and deep of this muscle and nourish the skin. However, where the cutaneous muscle is lacking, such as on limbs, vessels of this plexus lie deep in the loose subcutaneous tissue. When a random flap is raised on these locations, the position of the plexus dictates undermining deep to the level of the fascia to include these

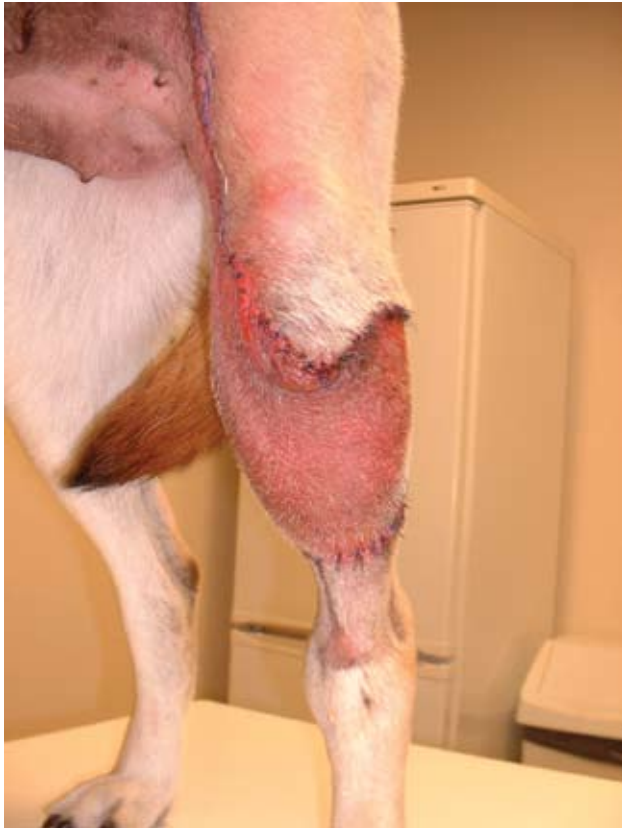

Figure 9. Cranial view of the surgical area 10 days post-operative. The hyperemia of the transposition flap indicates good perfusion and vitality.

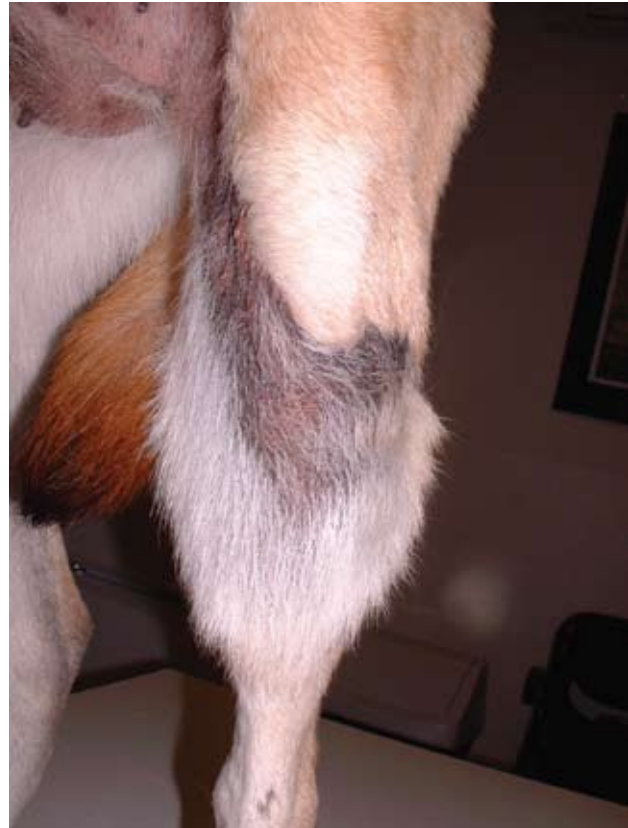

Figure 10. Cranial view of the surgical area 3 months post-operative with abundant hair growth.

capillary vessels in the loose areolar tissue (Pavletic, 1999).

Vascularization of random flaps may be improved when a branch or even a vascular pedicle of any direct axial vessel is fortuitously or deliberately included into the base of the flap. It must also be stressed that widening of the base of the flap does not automatically increase the surviving length of the flap unless, again, a branch of a direct cutaneous vessel is included through this widening of the base. Because of local, but unknown differences within regional cutaneous circulation, a standard width:length ratio is not available for this type of flaps (Pavletic, 1999).

Transposition flaps are developed where sufficient local skin is available in the immediate vicinity and within 90 degrees to the axis of the wound, and then moved laterally or medially into the primary defect. Bridging or overriding some skin to place the flap into its new location, sometimes may be necessary. The optimal rotation for transposition flaps is 90 degrees. Vessel kinking and shortening through rotation and transposition become major obstacles when these types of flaps are rotated more than 90 degrees. The geometrical aspects of safe planning involve recognition of the fact that the point around which the transposed flap pivots in its transfer is not the apex or corner of the defect but is the other side of the base of the flap (f in Figures 2 and 3). The effect of these planning requirements is that the flap generally is considerably larger than might otherwise be expected, and the created secondary defect is usually longer than necessary. This enables avoiding tension across the

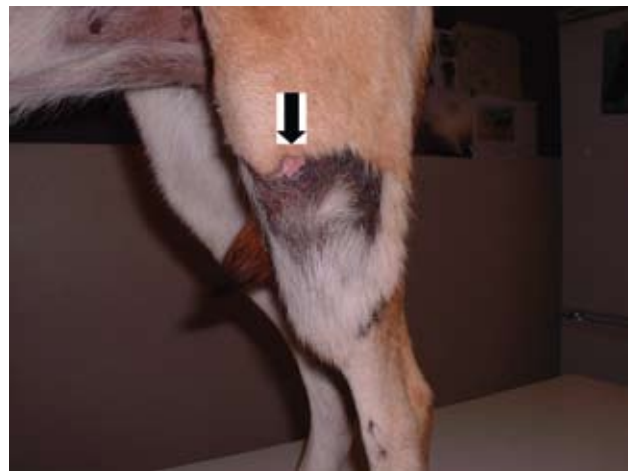

Figure 11. Cranio-lateral view of the surgical area 3 months post-operative. The arrow indicates the pink region of lick-dermatitis.

flap and tailors it after transfer is completed.

The authors find transposition flaps to be particularly useful on distal aspects of the limbs to cover moderate size defects. The only prerequisites are availability of sufficient skin and to design a transposition flap on a limb always proximal to the primary defect. Looseness of the skin on a limb becomes greater, the more proximal the origin of the flap is situated, enabling primary closure of the secondary defect. In breeds with an excess of skin on the extremities, transposition flaps are used by the authors to cover even defects on the metacarpal or metatarsal areas.

In reconstructions like this, suturing is carried out

mostly in two layers, using subdermal stitches with synthetic absorbable mono- or polyfilament suture material to ensure wound tensile strength, adding loose simple interrupted or continuous skin sutures with synthetic monofilaments. Small transposition flaps on distal parts of a limb do not require any drainage, as they fit snugly into the recipient bed, obstructing dead space. More proximal flap design may include bigger tissue volume transfer, sometimes necessitating some kind of drainage for a short period of time. As with any local flap, wide undermining and advancement of the surrounding tissues towards the centre of the defect with subcutaneous sutures may be part of the closing procedure of the primary defect and the donor site (Pavletic, 1999). It must be emphasized again not to undermine the base of the flap.

The technique employed in the dog described in this article, to broaden the base of the flap while raising it, was to create the caudo-medial incision no longer than strict necessarily, and try to transpose the flap in stages until it fitted well in the primary defect. This makes the base tangential and broader, with more opportunities to include additional small axial vessels. Some fortuitously included minor axial vessels into the base of the flap, which have no anatomical names but arose most probably from the femoral artery and vein, must have significantly improved the surviving length of the flap.

Hemangiopericytomas, of which the nomenclature is under debate, are presently considered as peripheral nerve sheath tumors (Liptak *et al.*, 2007). They account for 4.4 % of all skin tumors in dogs. Although they can occur at any location in the body, they are more often found on the limbs. Hemangiopericytomas display an infiltrative behavior at the microscopic level into the surrounding tissues. The macroscopically visible pseudo-capsule of the tumor is composed of compressed but viable tumor cells. This tumor type is considered malignant, but their metastasizing rate is low and depending on the histologic grade (Kuntz *et al.*, 1997; Liptak *et al.*, 2007). Therefore the tumor carries a good prognosis so long as local control can be achieved. Their local biologic behavior necessitates aggressive and wide surgery, which still remains the major treatment option for this tumor type. A study in 41 dogs with inadequate resection of soft tissue sarcomas indicated that re-excision of local tissue should be performed, even if excisable tissue margins appear narrow. A long-term favorable prognosis is attainable for this group of patients, without additive treatment modalities (Bacon *et al.*, 2007).

One previous study also mentioned surgical removal of large hemangiopericytomas in the upper part of the hind limb in 4 dogs. However, in all these dogs the tumor was located in the biceps femoris muscle, more proximal compared to the tumor described in this case report. After surgical tumor removal, 3 dogs had primary wound closure and in 1 dog the defect was closed using a flank fold skin flap. In 2 of the dogs who had primary wound closure, major dehiscence occurred, indicating the need for other reconstruction techniques (Connery *et al.*, 2002).

In case adjunctive therapy is a serious consideration, radiation therapy can be involved in the treatment of

hemangiopericytomas. Although, in general, soft-tissue sarcomas are considered radiation-resistant, a combination of surgery and radiation therapy has helped prevent or delay local recurrence (Forrest *et al.*, 2000; McKnight *et al.*, 2000). Radiation therapy has the greatest efficacy when used in combination with surgical cytoreduction of the tumor, and is less effective for bulky disease. The combination of radiation therapy and surgery can be used in cases with incomplete surgical margins, where postoperative radiation therapy is able to prevent the multiplication of tumor cells left behind on a microscopic level. Radiation therapy may also be utilized pre-operatively. Advantages to pre-operative radiation include a smaller radiation field, allowing for a smaller amount of normal tissue to be radiated. Possible stabilization or shrinkage of the tumor can make surgical excision with wider margins possible. Other advantages include an undisturbed tumor bed and blood supply, which enhances the ability of radiation to control tumor growth. Disadvantages associated with pre-operative radiation therapy include the possibility of poor or delayed wound healing in the irradiated field (Ehrhart *et al.*, 2005; Forrest *et al.*, 2000; McKnight *et al.*, 2000).

Soft-tissue sarcomas are considered slow to metastasize, but high histologic grade has been associated with an increased risk of metastasis and decreased survival time (Coindre *et al.*, 2001; Kuntz *et al.*, 1997). In veterinary oncology, chemotherapy is often recommended as an additive treatment for these high-grade soft tissue sarcomas because of their increased metastatic rate compared to lower and intermediate grade soft tissue sarcomas. Chemotherapy is best used in combination with radiation therapy and/or surgery. Chemotherapy alone does not seem to be effective for measurable soft-tissue sarcomas. Chemotherapy may help prevent or delay metastasis, so it is most commonly used after surgical removal of a high-grade soft-tissue sarcoma. Single-agent doxorubicin is used most commonly in veterinary medicine (Ehrhart, 2005; Kuntz *et al.*, 1997; Selting *et al.*, 2005).

In human oncology over the last 30 years there have been numerous studies attempting to determine whether neo-adjuvant or adjuvant systemic chemotherapy in combination with surgery does lead to an improved survival time in patients with localized soft tissue sarcomas. Modest benefit in survival time has been shown for doxorubicin-based chemotherapy protocols in patients who have localized soft tissue sarcomas with high-risk features on the extremities. In general, treatment with different chemotherapeutic agents did not improve the cure rate in the last 2 decades in people with localized soft tissue sarcomas (Scurr *et al.*, 2005).

CONCLUSION

To the authors' knowledge this is the first report of the use of a large transposition skin flap to cover a defect on the cranial part of the stifle and proximal tibia in a dog. In breeds like this Belgian Shepherd dog, this kind of flap probably is better suited for reconstructive purposes in this area compared to a caudal superficial epigastric flap.

ACKNOWLEDGMENTS

We acknowledge Mr. Janez Plestenjak from Slovenia for drawing the diagrams and Dr. Malcolm Brearley from the United Kingdom for manuscript review.

REFERENCES

- Bacon N.J., Dernell W.S., Ehrhart N., Powers B.E., Withrow S.J. (2007). Evaluation of primary re-excision after recent inadequate resection of soft tissue sarcomas in dogs: 41 cases (1999-2004). *Journal of the American Veterinary Medical Association* 230, 548-555.
- Coindre J.M., Terrier P., Guillou L., Le Doussal V., Collin F., Ranchère D., Sastre X., Vilain M.O., Bonichon F., N'Guyen Bui B. (2001). Predictive value of grade for metastasis development in the main histologic types of adult soft tissue sarcomas: a study of 1240 patients from the French Federation of Cancer Centers Sarcoma Group. *Cancer* 91, 1914-1926.
- Connery N.A., Bellenger C.R. (2002). Surgical management of haemangiopericytoma involving the biceps femoris muscle in four dogs. *Journal of Small Animal Practice* 43, 497-500.
- Ehrhart N. (2005). Soft-Tissue Sarcomas in Dogs: A Review. *Journal of the American Animal Hospital Association* 41, 241-246.
- Forrest L.J., Chun R., Adams W.M., Cooley A.J., Vail D.M. (2000). Postoperative radiotherapy for canine soft tissue sarcoma. *Journal of Veterinary Internal Medicine* 14, 578-582.
- Kuntz C.A., Dernell W.S., Powers B.E., Devitt C., Straw R.C., Withrow S.J. (1997). Prognostic factors for surgical treatment of soft-tissue sarcomas in dogs: 75 cases (1986-1996). *Journal of the American Veterinary Medical Association* 21, 1147-1151.
- Liptak J.M., Forrest L.J. (2007). Soft tissue sarcomas. In: Withrow S.J. and Vail D.M. (editors). *Small Animal Clinical Oncology*, 4th ed. Saunders Elsevier, St. Louis, Missouri, p. 428.
- McKnight J.A., Mauldin G.N., McEntee M.C., Meleo K.A., Patnaik A.K. (2000). Radiation treatment for incompletely resected soft-tissue sarcomas in dogs. *Journal of the American Veterinary Medical Association* 217, 205-210.
- Pavletic M.M. (1999). Local Flaps. In: Michael M., Pavletic M. (editors). *Atlas of Small Animal Reconstructive Surgery*, 2nd ed. W.B. Saunders Co, Philadelphia, p. 191-209.
- Scurr M., Judson I. (2005). Neoadjuvant and adjuvant therapy for extremity soft tissue sarcomas. *Hematology/Oncology Clinics of North America* 19, 489-500.
- Selting K.A., Powers B.E., Thompson L.J., Mittleman E., Tyler J.W., Lafferty M.H., Withrow S.J. (2005). Outcome of dogs with high-grade soft tissue sarcomas treated with and without adjuvant doxorubicin chemotherapy: 39 cases (1996-2004). *Journal of the American Veterinary Medical Association* 227, 1442-1448.

Biopharmaceutische innovatie!
Ook uw uitdaging ?

Brumedine N.V.

Voor uitbreiding van ons team zijn wij op zoek naar een (m/v):

Dierenarts
met een wetenschappelijke postdoctorale opleiding

In een kader van GCP, GLP en GMP werkt u mee aan het organiseren, het uitvoeren, het opvolgen en het rapporteren van formele klinische studies betreffende de veiligheid en doeltreffendheid van een innovatief immunologisch product bij melkvee.

- Wij bieden :
- een contract van onbepaalde duur
 - een degelijk salaris
 - een aangename werksfeer in een jong en dynamisch team
 - de mogelijkheid tot het opbouwen van een duurzame loopbaan
 - de uitdaging om een jonge KMO mee uit te bouwen

Interesse ? Stuur uw sollicitatiebrief met CV naar Brumedine N.V.,
t.a.v. Dr. B. De Cueninck, Gedelegeerd-bestuurder, Zeelaan 7, B-9900 Eeklo