

## Equine sarcoids - part 1: clinical presentation and epidemiology

### *Equine sarcoïden – deel 1: klinisch voorkomen en epidemiologie*

L. Bogaert, A. Martens, P. Depoorter, F. Gasthuys

Department of Surgery and Anesthesiology of Domestic Animals, Faculty of Veterinary Medicine, Ghent University, Salisburylaan 133, B-9820 Merelbeke, Belgium

lies.bogaert@UGent.be

#### ABSTRACT

**Equine sarcoids are the most common skin tumors in horses and other equids. In their pathogenesis, the bovine papillomavirus (BPV) plays a major role. Many clinical manifestations have been described, ranging from small single lesions to multiple aggressively growing masses. Histopathologically, it is considered as a biphasic tumor with epidermal hyperplasia and subepidermal proliferation of transformed fibroblasts. The diagnosis can be made clinically, histopathologically and/or by detection of BPV DNA. Sarcoids can appear on any part of the body, but they are mostly localized on the ventral abdomen, the paragenital region, head and limbs. Sarcoids occur independent of breed, coat color, sex or age, but they develop more commonly in young adults and certain families and breeds are more vulnerable than others. Transmission of BPV is supposed to happen from cattle to horse or from horse to horse, possibly via insects.**

#### SAMENVATTING

Equine sarcoïden zijn de meest voorkomende tumoren bij paarden en andere paardachtigen. Het bovine papillomavirus (BPV) speelt een belangrijke rol in de pathogenese. Verschillende klinische vormen worden beschreven gaande van kleine enkelvoudige laesies tot multipele agressief groeiende gezwellen. Histopathologisch worden sarcoïden beschouwd als bifasische tumoren met epidermale hyperplasie en subepidermale proliferatie van getransformeerde fibroblasten. De diagnose wordt gesteld aan de hand van een klinisch onderzoek, histopathologie en/of de detectie van BPV DNA. Sarcoïden kunnen op het hele lichaam voorkomen, maar meestal zijn ze terug te vinden onderaan de buik, in de paragenitale regio, op het hoofd en op de ledematen. Sarcoïden komen wereldwijd voor onafhankelijk van het ras, de haarkleur, het geslacht of de leeftijd maar ontstaan toch voornamelijk bij jong volwassen dieren. Bepaalde lijnen en rassen zijn eveneens meer gevoelig dan andere. De transmissie van BPV gebeurt vermoedelijk zowel van rund naar paard als tussen paarden onderling, eventueel via insecten.

#### INTRODUCTION

Equine sarcoids are the most common skin tumors in horses and other equids like donkeys, mules and zebras (Jackson, 1936; Ragland, 1970; Lazary *et al.*, 1985; Nel *et al.*, 2006). They were described for the first time by Jackson (1936), who considered the tumors as sarcoma-like mixed (fibro-epithelial) tumors. Equine sarcoids are observed worldwide, independent of breed, coat color, sex or age (Ragland, 1970; Tarwid *et al.*, 1985). Nevertheless, certain breeds and families are more vulnerable than others (Ragland *et al.*, 1966; Brostrom *et al.*, 1988; Lazary, 1988; Gerber, 1989; Marti *et al.*, 1993) and sarcoids occur most commonly in young adults, between 3 and 6 years (Marti *et al.*, 1993; Torrontegui and Reid, 1994).

Clinically and pathologically, sarcoids present most of the features of a true neoplasm. The predominant cell type is a malignant/transformed fibroblast. Sarcoids generally have a high capacity for local tissue invasion into the dermis and subcutis but true metas-

tatic dissemination does not occur (Pascoe and Knottenbelt, 1999). The clinical presentation of an equine sarcoid can vary a lot between different individuals and even within the same individual. The number of tumors per horse varies from one single sarcoid over a few to more than 100 lesions (Pascoe and Knottenbelt, 1999). A sarcoid can remain stable for years or it can show a rapid and aggressive growth with infiltration of surrounding skin (Ragland, 1970; Marti *et al.*, 1993). The reason for these large differences in clinical presentation is presently not known. The infiltrative behavior together with the infectious etiology is responsible for the frequent recurrences after treatment. Sarcoids themselves are never lethal, but failure to treat them and the functional impairment they cause may result in euthanasia or slaughtering. The economic repercussion can be great: besides the cosmetic aspect, the normal use of the horse can be hindered, especially when tumors are located at the level of the girth and bridle, distal limbs, corner of the mouth and eyelids. Moreover a genetic component

has a role in the development of the disease, diminishing the breeding value of affected animals (Lazary *et al.*, 1985; Meredith *et al.*, 1986; Gerber *et al.*, 1988). Diseased horses are therefore difficult to sell (Gerber, 1989).

In the pathogenesis, the bovine papillomavirus (BPV) plays a major role. Papillomaviruses are normally strictly species-specific, but equine sarcoids result from a natural cross-species infection. Although no intact viral particles have been demonstrated in sarcoids so far, DNA, RNA and proteins of the virus can be found (Amtmann *et al.*, 1980; Trenfield *et al.*, 1985; Otten *et al.*, 1993; Teifke *et al.*, 1994; Nasir and Reid, 1999; Carr *et al.*, 2001b). Moreover, many similarities can be observed between equine sarcoids and papillomatosis in other species: fast growth, tendency for multiplicity and spreading by contact over different parts of the body (Jackson, 1936). Epizootics have been described in closed herds of horses and zebras, pointing to an infectious agent (Ragland *et al.*, 1966; Nel *et al.*, 2006).

## CLINICAL PRESENTATION OF EQUINE SARCOIDS

### Clinical types

Many clinical manifestations of equine sarcoids are known. They can be single or multiple, small to very large, stable or aggressively growing. At cross-section sarcoids appear as dermal thickening with a pale yellow color and a firm texture due to fibroblastic proliferation and a small number of capillaries within the tumor (Foy *et al.*, 2002). The epidermis varies from thick, rough and hyperkeratotic to thinned or ulcerated. A classification based on morphological features has been proposed by Pascoe and Knottenbelt (1999) and will be followed throughout this paper.

Verrucous sarcoids (Figure 1) have a typical wart-like appearance with a rough, thickened, scabby surface above the fibroblastic part of the tumor (Knottenbelt *et al.*, 1995). They can appear as small exophytic growing masses or as flat, often extended, scaly areas of skin with multiple smaller wart-like lesions on the surface. Common differential diagnoses for this sarcoid type are warts (induced by equine papillomavirus), aural plaque, chronic sweet itch and chronic blistering (Pascoe and Knottenbelt, 1999).

Nodular sarcoids (Figure 2) are subcutaneous, easily moveable nodules, often but not always spherical, covered by intact, apparently normal skin (Foy *et al.*, 2002). In some cases, however, the overlying skin can be thinner, shiny and adherent to the tumor (Knottenbelt *et al.*, 1995). Differential diagnoses include eosinophilic granuloma, melanoma and other nodular diseases (Knottenbelt *et al.*, 1995).

Occult sarcoids (Figure 3) are flat circular to oval areas characterized by alopecia and a roughened or scaly appearance (Knottenbelt *et al.*, 1995). Sometimes small cutaneous nodules can be observed (Pascoe and Knottenbelt, 1999). In some cases, occult sarcoids can be very subtle, displaying no more than a slightly thickened skin with a thin hair coat and slight changes in pigmentation. This relatively be-

nign type can evolve rapidly towards a more aggressive type, either spontaneously or following injury such as biopsy or an erroneous treatment. Common differential diagnoses are dermatophytosis, chronic skin rubbing, alopecia areata and vitiligo (Knottenbelt *et al.*, 1995).

Fibroblastic sarcoids (Figure 4) are large fibrous masses with an ulcerated surface. This is the most aggressive sarcoid type and can evolve from any other type after accidental or iatrogenic manipulation, including biopsy (Knottenbelt *et al.*, 1995; Foy *et al.*, 2002). In these cases it is observed that the original tumor starts to grow very quickly and begins to ulcerate. Skin wounds, especially at the distal limbs, are also at risk for development of fibroblastic sarcoids. Both dehiscence of the suture line after surgery without an apparent reason as well as the presence of a slow healing hypergranulating wound can be suggestive of sarcoid development (Pascoe and Knottenbelt, 1999). Fibroblastic sarcoids are liable to trauma, haemorrhage and local infection with bacteria or maggots. Fibroblastic sarcoids can be sessile with an invasive character or pedunculated with a small base. Differential diagnoses are exuberant granulation tissue, botryomycosis, squamous cell carcinoma and habronemiasis in warmer climates (Knottenbelt *et al.*, 1995).

Mixed sarcoids (Figure 5) are a combination of two or more of the above mentioned types. They can represent a progressive or transient state between the verrucous/occult types and the fibroblastic/nodular types (Pascoe and Knottenbelt, 1999).

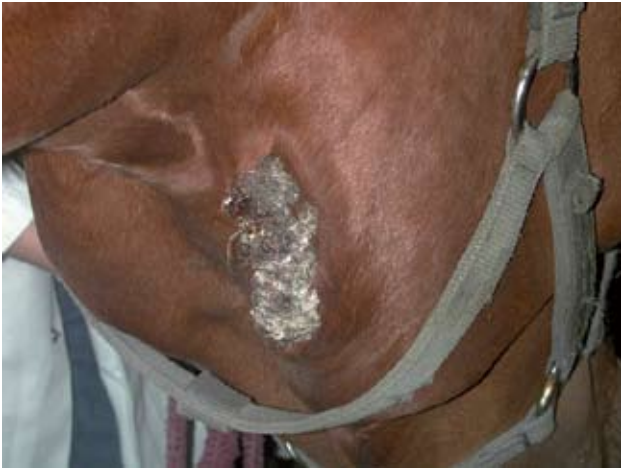Malevolent sarcoids are very rare and have been described only by one group (Knottenbelt *et al.*, 1995). These tumors infiltrate in lymphatic vessels resulting in multiple nodular or fibroblastic masses along these vessels. Local lymph nodes might also be involved. This type of sarcoid usually evolves from any of the other types following repeated injury, although spontaneous transformation is also possible.

In our clinic, sarcoids infiltrating the underlying muscles have occasionally been observed. These sarcoids can arise spontaneously or following failure of treatment resulting in deterioration of the tumor.

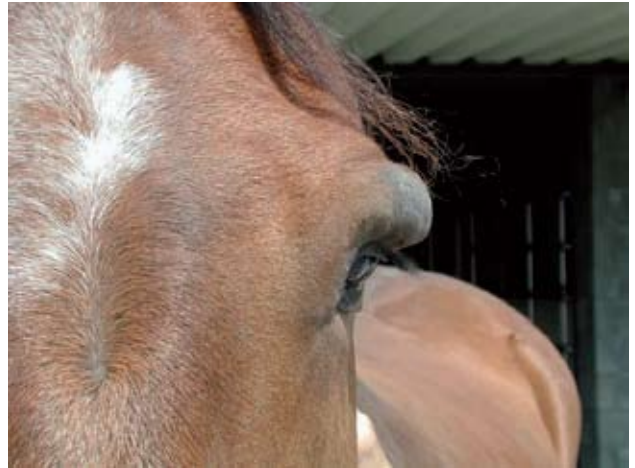This classification into different types is also reflecting the clinical behavior of the tumors: occult types are the most stable tumors, nodular and verrucous sarcoids display a moderate growth, fibroblastic sarcoids are often fast growing and malevolent and infiltrating sarcoids, although rarely seen, are the most aggressive sarcoid types.

## HISTOPATHOLOGICAL PROPERTIES

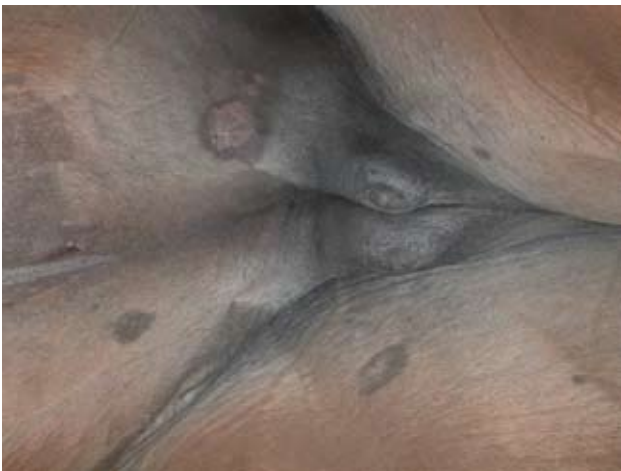Jackson (1936), who described the equine sarcoid for the first time, considered it as a biphasic tumor with an epidermal and dermal component. Typical changes are subepidermal proliferation of spindle-shaped to fusiform fibroblasts showing hyperchromasia with a moderate to high cell density (Tarwid *et al.*, 1985; Goodrich *et al.*, 1998). These immature fibroblasts show a higher density in the superficial part of the tumor compared to the deeper layers (Martens *et al.*, 2000). The fibroblasts are fusiform to spindle-shaped, forming whorls, interlacing bundles and



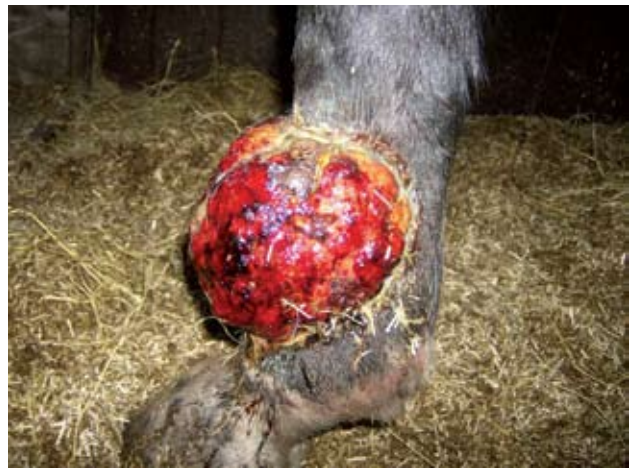**Figure 1. Verrucous sarcoid on the right mandible.**



**Figure 2. Nodular sarcoid on the upper eyelid.**

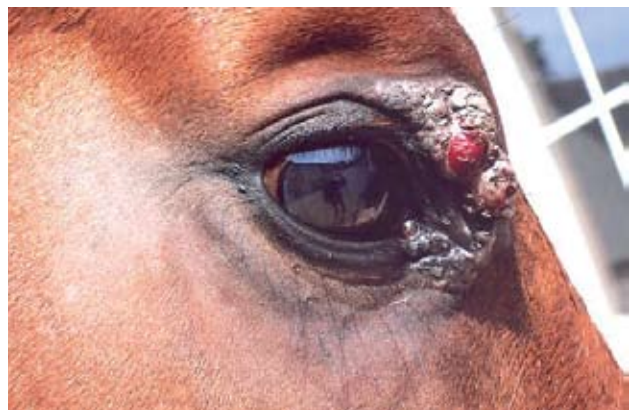

**Figure 3. Occult sarcoids in the paragenital region of a mare (ventral abdomen and medial side of the thigh).**



**Figure 4. Fibroblastic sarcoid on the dorsolateral aspect of the metacarpus.**

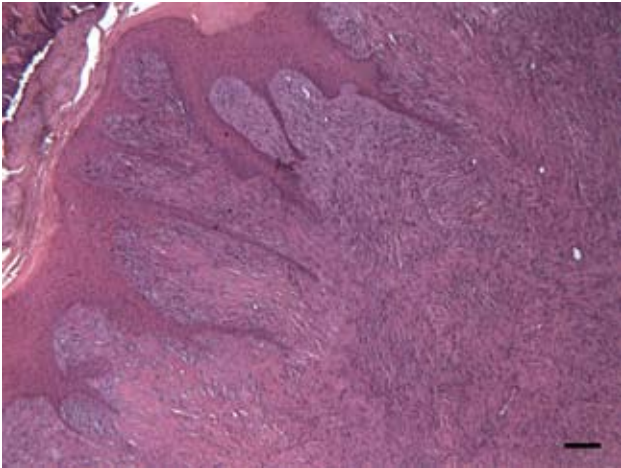
haphazard arrays with one another (Goodrich *et al.*, 1998). At the dermo-epidermal junction fibroblasts are oriented perpendicular to the basement membrane, which is known as a picket-fence pattern (Ragland, 1970; Tarwid *et al.*, 1985; Scott and Miller, 2003; Pulley and Stannard, 1990; Marti *et al.*, 1993). The mitotic rate is invariably low (Goodrich *et al.*, 1998; Martens *et al.*, 2000). The amount of collagen varies considerably between tumors (Goodrich *et al.*, 1998). In between the fibroblasts of the deeper layers of the dermis, large polygonal cells with large basophilic nuclei can be found. These are infiltrating dendritic cells that have an antigen presenting function suggesting an immune mediated defence against virus infected cells (von Tscharner *et al.*, 1996; Lepage *et al.*, 1998). Sometimes small epithelial inclusion cysts are found (Ragland, 1970; Tarwid *et al.*, 1985; Pulley and Stannard, 1990). In the most typical cases, pseudoepitheliomatous hyperplasia and hyperkeratosis are observed. There is marked formation of rete pegs, which are broad invaginations (up to more than 20 cells) of epidermal cells into the dermis (Goodrich *et al.*, 1998). However, in less typical sarcoids the epidermal component can be normal, atrophic or even absent (Marti *et al.*, 1993; Lepage *et al.*, 1998; Martens *et al.*, 2000). In situ hybridization for BPV DNA of tissue sections from sarcoids reveals viral DNA in the dermal layer within the fibroblasts but not within the epithelial cells (Lory *et al.*, 1993;



**Figure 5. Mixed sarcoid (verrucous – fibroblastic) on the upper eyelid.**

Teifke *et al.*, 1994; von Tscharner *et al.*, 1996). Epithelial changes seen in sarcoids are likely the result of growth-promoting factors expressed by the neoplastic fibroblasts that stimulate proliferation of surrounding epithelial cells (Carr *et al.*, 2001a).

The histological properties seem to be mainly dependent of the clinical type (Martens *et al.*, 2000). Most of the verrucous and mixed sarcoids display the histological features as described above (Figure 6). In verrucous sarcoids, the epithelial component is much more important than the dermal, sometimes only lying as a small band of active fibroblasts

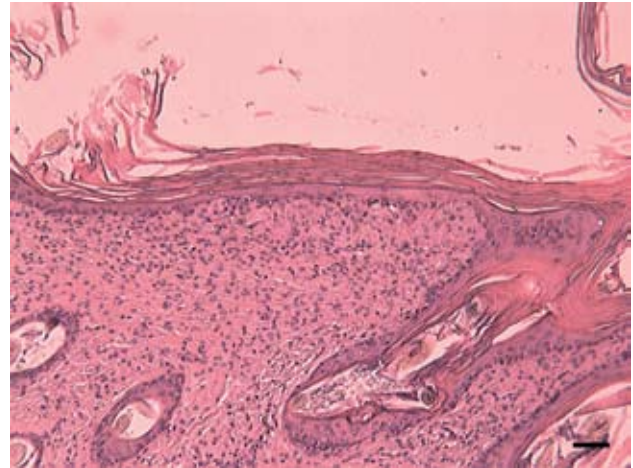


**Figure 6. Histological view of a verrucous sarcoid. Note the irregular hyperplasia of the epidermis, that forms deep rete ridges in the superficial dermis. The dermis is replaced by a highly cellular mass, arranged in short interlacing and palisading bundles of small moderately pleiomorphic spindle cells surrounded by a basophilic matrix (bar = 250  $\mu$ m).**

against the epidermis (Pulley and Stannard, 1990). In the fibroblastic type there is always partial or total ulceration of the epidermis with infiltration of polymorphonuclear cells (Martens *et al.*, 2000). The epidermis just next to the ulcerative lesions is more or less hyperplastic. In nodular sarcoids the epidermis is often thinned (Martens *et al.*, 2000). If rete pegs are present, they are short. If the dermal proliferation is not making contact with the epidermis, the latter is normal. In occult sarcoids (Figure 7) the epidermis is usually normal or only displaying slight changes. The only typical aspect of this sarcoid type is the increased density of subepidermal fibroblasts infiltrating between a reduced number of hair follicles and sweat glands (Martens *et al.*, 2000). They do not show a typical morphology or specific whorling distribution pattern. The density of dermal fibroblasts is also lower compared to the other types of sarcoids. The only common property for all types of sarcoids is the increased density of dermal fibroblasts compared to normal skin (Martens *et al.*, 2000). Nodular sarcoids can mimic schwannomas although their clinical appearance and the presence of BPV demonstrate the sarcoid origin of the tumor (Vanheerden, in preparation).

## DIAGNOSIS

Diagnosis can be made in three ways: clinical examination, histopathology and detection of BPV DNA. A thorough clinical examination combined with a focused anamnesis (duration of problems, localization of lesions, age, breed, evolution, multiplicity of lesions...) should be sufficient in the majority of cases. Lack of clinical experience or atypical tumor characteristics may cause confusion and necessitate lab-assisted diagnosis. Histopathological examination is often diagnostic, but it should be remarked that taking a biopsy, in particular of small stable lesions, may induce rapid growth and ulceration. If a non-excisional biopsy must be performed, sites within the mass must be carefully chosen to minimize the con-



**Figure 7. Histological view of an occult sarcoid. Only an increased density of subepidermal fibroblasts can be seen together with diffuse orthokeratotic hyperkeratosis of the overlying epidermis (bar = 250  $\mu$ m).**

found factors of surrounding inflammation and granulation and to include intact epidermis (Goodrich *et al.*, 1998). Possible deterioration of the sarcoid following biopsy is the reason why taking a biopsy of verrucous, occult and small nodular lesions is contra-indicated, even if making a definitive diagnosis is not possible in such cases (Pascoe and Knottenbelt, 1999). Another possibility is to perform a full surgical excision as if the lesion was a sarcoid, including excision of wide margins of normal skin and non-touch approach, followed by histological confirmation afterwards. This allows the pathologist to observe the range of morphological characteristics of the tumor allowing a correct diagnosis (Goodrich *et al.*, 1998).

A more recent approach in diagnosing equine sarcoids is the detection of BPV DNA in lesions by means of polymerase chain reaction (PCR). This can be performed on histopathological samples of tissue suspected of equine sarcoid but not displaying the typical histological features (Angelos *et al.*, 1991). A new approach is the detection of BPV DNA by means of PCR in the limited amount of material obtained by swabbing or scraping the lesions. This technique is especially valuable for the diagnosis of equine sarcoid tissue in non-healing wounds and in case of recurrences after former surgery (Martens *et al.*, 2001). PCR detection of BPV DNA has many advantages: it is not invasive, sampling is easy and the trauma to the tumor is minimal. Disadvantages are the unsuitability for diagnosing occult sarcoids, the lower sensitivity compared to clinical diagnosis and the low specificity due to high prevalence of BPV DNA in the normal skin of horses (Martens *et al.*, 2001; Bogaert *et al.*, 2007a).

## EPIDEMIOLOGICAL FACTORS

### Prevalence

The equine sarcoid is the most common tumor in horses, donkeys, mules and zebras. Depending on the study, they represent 12 to 67 % of all equine tumors and 70 % of all skin tumors in horses (Jackson, 1936;

Ragland, 1970; Miller and Campbell, 1982; Teifke *et al.*, 1994; Lepage *et al.*, 1998). A prevalence of 0.6 to 2 % in clinical populations has been reported (Ragland, 1970; Mohammed *et al.*, 1992; Goodrich *et al.*, 1998). In our clinic, 2.2 % of the patients are admitted for treatment of equine sarcoids. This percentage is biased, since it can be higher than the true prevalence because veterinary referral hospitals can be specialized in sarcoid treatment and thus have a high case load. On the other hand, not all horses with sarcoids are referred to the clinic: small tumors are often treated at home by local practitioners or are left untreated. Recent studies conducted on three-year-old horses presented for field tests in Switzerland showed a prevalence of 12 % in the Swiss Warmblood Horse and the Freiburger (Mele *et al.*, 2007; Studer *et al.*, 2007), which might be a more accurate estimation of the true population prevalence. In populations of Cape mountain zebras in South Africa the prevalence of equine sarcoids mounted up to 53 %, but this high prevalence could be influenced by a high degree of inbreeding (Zimmerman, 2004; Nel *et al.*, 2006).

## LOCALIZATION OF TUMORS

Sarcoids can appear on any part of the body, but they are mostly localized on the ventral abdomen, the paragenital region, head and limbs (Jackson, 1936; Pulley and Stannard, 1990; Torrontegui and Reid, 1994; Goodrich *et al.*, 1998; Piscopo, 1999; Bogaert *et al.*, 2007b). On the head, most tumors develop at the eyelids, ears and commissure of the lips (Foy *et al.*, 2002). Sarcoids are least common on the dorsum of the trunk (Knottenbelt *et al.*, 1995). In northern regions, lesions occur predominantly on the head and abdomen while in warmer climates the limbs are more often involved (Marti *et al.*, 1993). Apart from these predilection sites, sarcoids can develop at any site in injured skin (Torrontegui and Reid, 1994; Foy *et al.*, 2002). The location of sarcoids has a significant relationship to their size: sarcoids on the head are mostly smaller whereas sarcoids on the limbs are larger when compared to all other sites (Brostrom, 1995). Sarcoids can appear singly or in clusters (Brostrom, 1995; Goodrich *et al.*, 1998). Horses with multiple lesions tend to have larger-sized tumors compared to horses with a single sarcoid (Brostrom, 1995).

## RISK FACTORS

### Age

In contrast to most tumors observed in man and animals, the equine sarcoid predominantly develops in young adults. The majority of affected horses are younger than 6 years, with a peak incidence between 3 and 6 years (Miller and Campbell, 1982; Scott and Miller, 2003; Marti *et al.*, 1993; Torrontegui and Reid, 1994; Brostrom, 1995; Piscopo, 1999; Foy *et al.*, 2002). The mean age of sarcoid development is 3.5 to 4 years (Brostrom, 1995; Studer *et al.*, 2007). Nevertheless, also younger and older horses can develop sarcoids. According to Mohammed *et al.* (1992) a gradual increase in incidence is observed up to the age of 15 years, followed by a decreasing in-

cidence. A study on a large group of donkeys revealed that mainly males between 0.5 and 3 years were at high risk (Reid and Gettinby, 1996). An obvious reason for this age distribution has not been demonstrated yet, but possibly older horses acquire a certain level of immunity which results in spontaneous regression of existing tumors and prevention of new tumor development. Another hypothesis is that genetically susceptible animals develop tumors early in life (Torrontegui and Reid, 1994).

### Sex

Most authors do not assume that there is a gender predisposition for sarcoid development (Ragland, 1970; Miller and Campbell, 1982; Pulley and Stannard, 1990; Torrontegui and Reid, 1994). However, others claim that geldings are more susceptible than stallions and mares. Mohammed *et al.* (1992) observed that the risk for geldings to develop sarcoids was twice as high compared to stallions and mares. In donkeys, a predisposition in males was observed (Reid *et al.*, 1994; Reid and Gettinby, 1996). A possible explanation is that in castrated males a wound is created which is a possible entrance for BPV (Reid *et al.*, 1994). On the other hand, in spite of the frequent localization of sarcoids in the paragenital region, the castration wound itself is only seldom affected. Another hypothesis is that female animals have protective factors, rather than a predisposition in males (Reid and Mohammed, 1997).

### Breed

There is clear breed predisposition for the development of equine sarcoids (Marti *et al.*, 1993). In North America, Quarter Horses are twice as likely to develop sarcoids compared to Thoroughbreds (Angelos *et al.*, 1988). Also Appaloosas and Arabian Horses are more frequently affected than Thoroughbreds (Angelos *et al.*, 1988; Mohammed *et al.*, 1992). Standardbreds on the other hand are rather resistant (Meredith *et al.*, 1986; Mohammed *et al.*, 1992; Brostrom, 1995). A possible explanation is that Quarter Horses and Appaloosas are often used on large cattle farms which results in a higher risk to get in contact with BPV (Mohammed *et al.*, 1992). Moreover they often work on rough surfaces resulting in frequent injury to the limbs and the possibility for sarcoid development in these wounds (Brostrom, 1995). Another more plausible explanation for breed predisposition can be found in the different genetic background of these breeds (Lazary *et al.*, 1985; Meredith *et al.*, 1986).

## Genetic background

The most important genes known to play a role in sarcoid development are those of the major histocompatibility complex (MHC), but also other genes are involved. The genes of the MHC code for proteins involved in the immune response and for protein components of the complement system (Piscopo, 1999). In horses these proteins are called equine leucocyte antigens (ELA). Three major classes of MHC genes

exist (Lazary *et al.*, 1994): class I genes code for glycoproteins on the cell wall of most nucleated cells. They have a role in recognition and killing of virus infected cells. Seventeen internationally accepted alleles (A1-10, A14-15, A19, W16-18, W20) and 5 regional variants (Be22, Be24-26, Be108) are distinguished serologically in the horse. Class II proteins are expressed on the cell surface of antigen presenting cells. Within this class the DQB gene is highly polymorphic. In the horse 3 internationally accepted alleles (W13, W22-23) and 2 local variants (BeVI-II, Be200) can be determined serologically (Lazary, 1988; Hesford *et al.*, 1989). To date, the complete sequence coding the ELA-DQB gene is known (Szalai *et al.*, 1994) and more than 23 DQB sequences have been reported in domestic horses (Gyllensten *et al.*, 1990; Szalai *et al.*, 1993; Horin and Matiasovic, 2002), but not all reported sequences can be assigned to a serological specificity (Villegas-Castagnasso *et al.*, 2003). Recent evidence suggests the presence of at least two copies of the horse DQB gene (Horin and Matiasovic, 2002; Villegas-Castagnasso *et al.*, 2003), one of them probably being a pseudogene. This genome organisation hampers an easy classification of DQB variants with modern molecular techniques such as PCR-RFLP. Class III genes encode several proteins involved in the complement system, but these are not associated with predisposition for sarcoids.

In most breeds such as the Swiss Warmblood, the Irish Warmblood, the Swedish Halfbred and the Selle Français, the presence of equine sarcoids is strongly correlated with ELA W13 (Meredith *et al.*, 1986; Brostrom *et al.*, 1988; Gerber *et al.*, 1988; Lazary *et al.*, 1994; Brostrom, 1995). A higher percentage of recurrences is also observed in the presence of this allele (Brostrom, 1995). Standardbreds lack W13, which might be a reason for the low prevalence of equine sarcoids in this breed (Meredith *et al.*, 1986). In the Freiburger, a Swiss draft horse, W13 is also lacking, but a higher sensitivity for sarcoid development is correlated with Be108, a local variant (Lazary *et al.*, 1994). In the Selle Français, A3 is correlated with a higher prevalence of sarcoids, but this could be due to linkage disequilibrium with W13 (Lazary *et al.*, 1994). Indeed, ELA A3W13 is frequently seen as one of the paternal haplotypes in families where equine sarcoids are more commonly observed than in others (Brostrom *et al.*, 1988; Gerber *et al.*, 1988). A5 would be correlated with early onset of sarcoids (Brostrom, 1995). The association of equine sarcoids with certain antigens is however not absolute. A large proportion of horses are carriers of W13, but only a small part of them will develop sarcoids (Goodrich *et al.*, 1998). On the other hand, also horses lacking W13 may be affected by sarcoids. Maybe these alleles are only markers of other susceptibility genes in linkage disequilibrium with the MHC, with a more direct influence on the pathogenesis (Brostrom *et al.*, 1988; Gerber *et al.*, 1988; Lazary *et al.*, 1994). Still it seems plausible that genes coding for proteins regulating the immune system can also influence the susceptibility for certain diseases (Piscopo, 1999). Indeed, in virus-induced tumors the virus-infected cells express new cell wall antigens, both virus specific

and virus induced non-viral products. These foreign antigens should normally be recognized by the immune system resulting in destruction of tumor cells. If a failure occurs in the immune system, recognition and destruction of tumoral cells may also fail. In man and rabbits, a linkage between papillomavirus induced cancer and MHC alleles has also been observed (Wank and Thomssen, 1991; Han *et al.*, 1992).

In Arabian Horses a significant correlation exists between presence of equine sarcoids and heterozygosity for the defective DNA protein kinase catalytic subunit (DNA-PKcs) allele, which is in homozygous condition responsible for severe combined immunodeficiency. In a population of Arabian Horses, 8.7 % of the animals were carriers of the defective DNA-PKcs allele, compared to 18.6 % of the equine sarcoid affected animals (Ding *et al.*, 2002).

## TRANSMISSION

The way horses get infected with BPV is not yet clarified. Possible transmission routes are direct contact with cattle (Jackson, 1936), indirect transmission from cattle to horses (e.g. housing of horses in cattle stables, transmission by caretakers of the animals) and transmission from horses with sarcoids to other horses (direct or indirect via caretaker, tack, grooming equipment, common rubbing posts) (Bogaert *et al.*, 2005; Bogaert *et al.*, 2007a). In donkeys it is known that animals having close contact with affected animals are at higher risk for development of sarcoids (Reid *et al.*, 1994). Epidemiological data, multiplicity of tumors on one horse, spontaneous development of sarcoids on intact skin and absence of contact with cattle or affected horses suggest that flies or other insects may play an important role as mechanical vector in BPV infection of the horse (Voss, 1969; Reid *et al.*, 1994; Torrontegui and Reid, 1994; Knottenbelt *et al.*, 1995; Pascoe and Knottenbelt, 1999). Recently, Kemp-Symonds and Kirk (2007) have demonstrated the presence of BPV-1 and -2 in *Musca autumnalis* face flies infesting sarcoid affected horses. Moreover, it is observed that in one specific region identical variants of BPV are seen both in horses and in cattle, also pointing into the direction of a flyborn transmission (Otten *et al.*, 1993). In case of a skin wound, BPV coincidentally present in the environment of the horse can immediately come into contact with the subepidermal fibroblasts via insects (Reid *et al.*, 1994; Torrontegui and Reid, 1994; Knottenbelt *et al.*, 1995; Pascoe and Knottenbelt, 1999). Furthermore, cell growth is already stimulated as part of wound regeneration. This can eventually lead to malignant transformation of these cells (Phelps *et al.*, 1999; Foy *et al.*, 2002).

## ACKNOWLEDGMENTS

Prof. Dr. Hilde De Cock (University of Antwerp) is greatly acknowledged to provide us with Figures 6 and 7.

## LITERATURE

- Amtmann E., Muller H., Sauer G. (1980). Equine Connective-Tissue Tumors Contain Unintegrated Bovine Papilloma-Virus DNA. *Journal of Virology* 35, 962-964.
- Angelos J., Oppenheim Y., Rebhun W., Mohammed H., Antczak D.F. (1988). Evaluation of Breed As A Risk Factor for Sarcoid and Uveitis in Horses. *Animal Genetics* 19, 417-425.
- Angelos J.A., Marti E., Lazary S., Carmichael L.E. (1991). Characterization of BPV-like DNA in equine sarcoids. *Archives of Virology* 119, 95-109.
- Bogaert L., Martens A., De Baere C., Gasthuys F. (2005). Detection of bovine papillomavirus DNA on the normal skin and in the habitual surroundings of horses with and without equine sarcoids. *Research in Veterinary Science* 79, 253-258.
- Bogaert L., Martens A., Van Poucke M., Ducatelle R., De Cock H., Dewulf J., De Baere C., Peelman L., Gasthuys F. (2007a). High prevalence of bovine papillomaviral DNA in the normal skin of equine sarcoid affected and healthy horses. *Veterinary Microbiology*, in press.
- Bogaert L., Van Poucke M., De Baere C., Dewulf J., Peelman L., Ducatelle R., Gasthuys F., Martens A. (2007b). Bovine papillomavirus load and mRNA expression, cell proliferation and p53 expression in four clinical types of equine sarcoid. *Journal of General Virology* 88, 2155-2161.
- Brostrom H. (1995). A clinical and epidemiologic study in relation to equine leukocyte antigens (ELA). *Acta Veterinaria Scandinavica* 36, 223-236.
- Brostrom H., Fahlbrink E., Dubath M.L., Lazary S. (1988). Association between equine leukocyte antigens (ELA) and equine sarcoid tumors in the population of swedish halfbreds and some of their families. *Veterinary Immunology and Immunopathology* 19, 215-223.
- Carr E.A., Theon A.P., Madewell B.R., Griffey S.M., Hitchcock M.E. (2001a). Bovine papillomavirus DNA in neoplastic and nonneoplastic tissues obtained from horses with and without sarcoids in the western United States. *American Journal of Veterinary Research* 62, 741-744.
- Carr E.A., Theon A.P., Madewell B.R., Hitchcock M.E., Schlegel R., Schiller J.T. (2001b). Expression of a transforming gene (E5) of bovine papillomavirus in sarcoids obtained from horses. *American Journal of Veterinary Research* 62, 1212-1217.
- Ding Q., Bramble L., Yuzbasiyan-Gurkan V., Bell T., Meek K. (2002). DNA-PKcs mutations in dogs and horses: allele frequency and association with neoplasia. *Gene* 283, 263-269.
- Foy J.M., Rashmir-Raven A.M., Brashier M.K. (2002). Common equine skin tumors. *Compendium on Continuing Education for the Practicing Veterinarian* 24, 242.
- Gerber H. (1989). The Genetic-Basis of Some Equine Diseases. *Equine Veterinary Journal* 21, 244-248.
- Gerber H., Dubath M.L., Lazary S. (1988). Association between predisposition to equine sarcoid and MHC in multiple-case families. In: *Proceedings of the 5th International Conference on Equine Infectious Diseases* 272-277.
- Goodrich L., Gerber H., Marti E., Antczak D.F. (1998). Equine sarcoids. *Veterinary Clinics of North America-Equine Practice* 14, 607-623.
- Gyllensten U.B., Lashkari D., Erlich H.A. (1990). Allelic Diversification at the Class-Ii Dqb Locus of the Mammalian Major Histocompatibility Complex. In: *Proceedings of the National Academy of Sciences of the United States of America* 87, 1835-1839.
- Han R., Breitburd F., Marche P.N., Orth G. (1992). Linkage of Regression and Malignant Conversion of Rabbit Viral Papillomas to Mhc Class-Ii Genes. *Nature* 356, 66-68.
- Hesford F., Lazary S., Curtyhanni K., Gerber H. (1989). Biochemical-Evidence That Equine Leukocyte Antigens W13, W22 and W23 Are Present on Horse Major Histocompatibility Complex Class-Ii Molecules. *Animal Genetics* 20, 415-420.
- Horin P., Matiasovic J. (2002). A second locus and new alleles in the major histocompatibility complex class II (ELA-DQB) region in the horse. *Animal Genetics* 33, 196-200.
- Jackson C. (1936). The incidence and pathology of tumours of domesticated animals in South Africa. *The Onderstepoort Journal of Veterinary Science and Animal Industry* 6, 375-385.
- Kemp-Symonds J.G., Kirk S. (2007). Detection and sequencing of bovine papillomavirus type 1 and type 2 DNA from *Musca autumnalis* face flies infesting sarcoid-affected horses. In: *Proceedings 46th Congress British Equine Veterinary Association, 12-15th September, Edinburgh* 427-428.
- Knottenbelt D.C., Edwards S., Daniel E. (1995). Diagnosis and treatment of the equine sarcoid. *In Practice* 17, 123-129.
- Lazary S. (1988). Studies on Susceptibility to Equine Sarcoid. *Der Praktische Tierarzt* 69, 12-13.
- Lazary S., Gerber H., Glatt P.A., Straub R. (1985). Equine leukocyte antigens in sarcoid-affected horses. *Equine Veterinary Journal* 17, 283-286.
- Lazary S., Marti M., Szalai G., Gaillard C., Gerber H. (1994). Studies on the frequency and associations of equine leukocyte antigens in sarcoid and summer dermatitis. *Animal Genetics* 25, 75-80.
- Lepage M.F., Carstanjen B., von Tscharnner C. (1998). Equine sarcoid (part I): causes, diagnosis, differential diagnosis. *Praktische Tierarzt* 79, 627-636.
- Lory S., Vontscharner C., Marti E., Bestetti G., Grimm S., Waldvogel A. (1993). In situ hybridization of equine sarcoids with bovine papilloma-virus. *The Veterinary Record* 132, 132-133.
- Martens A., De Moor A., Demeulemeester J., Ducatelle R. (2000). Histopathological characteristics of five clinical types of equine sarcoid. *Research in Veterinary Science* 69, 295-300.
- Martens A., De Moor A., Ducatelle R. (2001). PCR detection of bovine papilloma virus DNA in superficial swabs and scrapings from equine sarcoids. *Veterinary Journal* 161, 280-286.
- Marti E., Lazary S., Antczak D.F., Gerber H. (1993). Report of the 1St International Workshop on Equine Sarcoid. *Equine Veterinary Journal* 25, 397-407.
- Mele M., Gerber V., Straub R., Gaillard C., Jallon L., Burger D. (2007). Prevalence of hereditary diseases in three-year-old franchises-montagnes horses. *Schweizer Archiv für Tierheilkunde* 149, 151-159.
- Meredith D., Elser A.H., Wolf B., Soma L.R., Donawick W.J., Lazary S. (1986). Equine leukocyte antigens - Relationships with sarcoid tumors and laminitis in 2 pure breeds. *Immunogenetics* 23, 221-225.

- Miller R.I., Campbell R.S.F. (1982). A survey of granulomatous and neoplastic diseases of equine skin in North Queensland. *Australian Veterinary Journal* 59, 33-37.
- Mohammed H.O., Rebhun W.C., Antczak D.F. (1992). Factors Associated with the Risk of Developing Sarcoid Tumors in Horses. *Equine Veterinary Journal* 24, 165-168.
- Nasir L., Reid S.W.J. (1999). Bovine papillomaviral gene expression in equine sarcoid tumours. *Virus Research* 61, 171-175.
- Nel P.J., Bertschinger H., Williams J., Thompson P.N. (2006). Descriptive study of an outbreak of equine sarcoid in a population of Cape mountain zebra (*Equus zebra zebra*) in the Gariiep Nature Reserve. *Journal of the South African Veterinary Association-Tydskrif Van Die Suid-Afrikaanse Veterinere Vereniging* 77, 184-190.
- Otten N., Vontscharner C., Lazary S., Antczak D.F., Gerber H. (1993). DNA of bovine papillomavirus type-1 and type-2 in equine sarcoids - PCR detection and direct sequencing. *Archives of Virology* 132, 121-131.
- Pascoe R.R., Knottenbelt D.C. (1999). Neoplastic conditions. In: Pascoe R.R. and Knottenbelt D.C. (editors). *Manual of Equine Dermatology*. Saunders, London, p. 244-252.
- Phelps W.C., Bream G.L., McBride A.A. (1999). Papillomaviruses - Animal. In: Granoff A. and Webster R.G. (editors). *Encyclopedia of Virology. Academic Press Limited*, London, p. 1121-1130.
- Piscopo S.E. (1999). The complexities of sarcoid tumors. *Equine Practice* 21, 14-18.
- Pulley L.T., Stannard A.A. (1990). Skin and soft tissues. In: Moulton J.E. (editors). *Tumours in domestic animals*. University of California Press, Los Angeles, p. 27-31.
- Ragland W.L. (1970). Equine sarcoid. *Equine Veterinary Journal* 2, 2-11.
- Ragland W.L., Keown G.H., Gorham J.R. (1966). An epizootic of equine sarcoid. *Nature* 210, 1399.
- Reid S.W.J., Gettinby G. (1996). Statistical assessment of risk for the clinical management of equine sarcoids in a population of *Equus asinus*. *Preventive Veterinary Medicine* 26, 87-95.
- Reid S.W.J., Gettinby G., Fowler J.N., Ikin P. (1994). Epidemiologic observations on sarcoids in a population of donkeys (*Equus-Asinus*). *The Veterinary Record* 134, 207-211.
- Reid S.W.J., Mohammed H.O. (1997). Longitudinal and cross-sectional studies to evaluate the risk of sarcoid associated with castration. *Canadian Journal of Veterinary Research-Revue Canadienne de Recherche Veterinaire* 61, 89-93.
- Scott D.W., Miller W.H. (2003). Neoplastic and non-neoplastic tumours - Equine sarcoids. In: Scott D.W., Miller W.H. (editors). *Equine Dermatology*. Saunders, St-Louis, p. 719-731.
- Studer S., Gerber V., Straub R., Brehm W., Gaillard C., Luth A., Burger D. (2007). Prevalence of hereditary diseases in three-year-old Swiss Warmblood horses. *Schweizer Archiv für Tierheilkunde* 149, 161-171.
- Szalai G., Antczak D.F., Gerber H., Lazary S. (1994). Molecular-Cloning and Characterization of Horse Dqβ Cdn. *Immunogenetics* 40, 458-458.
- Szalai G., Bailey E., Gerber H., Lazary S. (1993). Dna-Sequence Analysis of Serologically Detected Ela Class-II Haplotypes at the Equine Dq-Beta Locus. *Animal Genetics* 24, 187-190.
- Tarwid J.N., Fretz P.B., Clark E.G. (1985). Equine Sarcoids - A Study with Emphasis on Pathologic Diagnosis. *Compendium on Continuing Education for the Practicing Veterinarian* 7, S293-S300.
- Teifke J.P., Hardt M., Weiss E. (1994). Detection of bovine papillomavirus DNA in formalin-fixed and paraffin-embedded equine sarcoids by polymerase chain reaction and non-radioactive in situ hybridization. *European Journal of Veterinary Pathology* 1, 5-10.
- Torrontegui B.O., Reid S.W.J. (1994). Clinical and pathological epidemiology of the equine sarcoid in a referral population. *Equine Veterinary Education* 6, 85-88.
- Trenfield K., Spradbrow P.B., Vanselow B. (1985). Sequences of papillomavirus DNA in equine sarcoids. *Equine Veterinary Journal* 17, 449-452.
- Villegas-Castagnasso E.E., Diaz S., Giovambattista G., Dulout F.N., Peral-Garcia P. (2003). Analysis of ELA-DQB Exon 2 polymorphism in Argentine creole horses by PCR-RFLP and PCR-SSCP. *Journal of Veterinary Medicine Series A-Physiology Pathology Clinical Medicine* 50, 280-285.
- von Tscharnner C., Affolter V.K., Wyder M., Suter M.M., Moore P.F. (1996). Involvement of dermal dendritic cells in the pathogenesis of equine sarcoids. In: Kwochka K.W., Willemsse T., von Tscharnner C. (editors). In: *Proceedings of the 3rd World Congress of Veterinary Dermatology*. Edinburgh, p. 561.
- Voss J.L. (1969). Transmission of equine sarcoid. *American Journal of Veterinary Research* 30, 183-191.
- Wank R., Thomssen C. (1991). High-Risk of Squamous-Cell Carcinoma of the Cervix for Women with Hla-Dqw3. *Nature* 352, 723-725.
- Zimmerman D. (2004). Summary report and draft action plan for the equine sarcoid problem in cape mountain zebra at Bontebok NP. In: *Internal report, November 2004, Veterinary Wildlife Unit, South African National Parks Board*. Kimberly.

## OPROEP

### Onderzoek naar equine sarcoïd

Op de Vakgroep Heelkunde en Anesthesie van de Huisdieren van de Faculteit Diergeneeskunde te Merelbeke loopt momenteel een onderzoek naar de transmissie van het boviene papillomavirus. Hiervoor zijn we op zoek naar proefpaarden met equine sarcoïden, evenals naar paarden die vroeger reeds behandeld werden voor sarcoïden maar nu sarcoïd-vrij zijn. Deze paarden zullen gebruikt worden om de exacte manier van transmissie te ont-rafelen, uitgaande van viraal materiaal afkomstig van zowel runderen als van paarden. Opgelet: deze paarden zullen worden overgekocht door de vakgroep en kunnen dus niet in het bezit blijven van de eigenaar! Indien u in uw cliënteel dergelijke dieren hebt die anders toch moeten geëuthanaseerd of geslacht worden, kunt u ons steeds contacteren voor overname van deze dieren.

Contact: Pieter Depoorter (pieter.depoorter@UGent.be), Lies Bogaert (lies.bogaert@UGent.be)