

Ectopic thymic carcinoma in the nasopharynx of a Golden Retriever

Ectopisch thymuscarcinoom in de nasopharynx van een golden retriever

¹T.W.J. Willemse, ²T. Scase, ³J. Marti, ³A. Di Bella

¹Small Animal Department, Faculty of Veterinary Medicine, Ghent University, Salisburylaan 133, B-9820 Merelbeke, Belgium

²Pathologicus Ltd., Paulton House, Old Mills, Paulton, Bristol, BS39 7SX, United Kingdom

³Southern Counties Veterinary Specialists, Unit 6, Forest Corner Farm, Hangersley, Ringwood BH24 3JW, United Kingdom

Tijmen.willemse@ugent.be

ABSTRACT

An eleven-year-old, male, neutered Golden Retriever was referred for a chronic history of stertorous breathing, inspiratory stridor and mucopurulent discharge from the left nostril. A computed tomographic (CT) scan of the head, neck and thorax revealed a nasopharyngeal mass causing bone lysis of the hard palate. There were no signs of local or distant metastatic disease. Nasopharyngoscopy confirmed a large mass, occluding the entire nasopharynx. Histopathological analysis of the biopsies was indicative of a chronic inflammatory polyp. The mass was surgically removed through a ventral approach to the nasopharynx. Histopathological examination of the mass identified it as a thymic carcinoma arising from ectopic thymic tissue. The dog recovered well but died of unknown causes one year later.

SAMENVATTING

Een elf jaar oude, mannelijke, gecastreerde golden retriever werd doorverwezen vanwege een voorgeschiedenis van stridor sinds zes maanden en unilaterale purulente neusvloeï. Een computertomografische scan (CT) van het hoofd, de nek en de thorax toonde een nasofaryngeale massa die de volledige nasofarynx obstrueerde. Er werden geen tekenen van metastase gezien. Histopathologisch onderzoek van bipten van de massa was indicatief voor een chronische inflammatoire poliep. De massa werd via een ventrale benadering verwijderd. Tijdens het histopathologisch onderzoek werd de tumor geïdentificeerd als een thymuscarcinoom uitgaande van ectopisch thymusweefsel. De hond herstelde goed, maar overleed een jaar na de operatie door een onbekende oorzaak.

INTRODUCTION

Nasosinal and nasopharyngeal tumors account for around 1% of all neoplasms in dogs, with carcinomas, squamous cell carcinomas and undifferentiated carcinomas representing two-thirds of these tumors (Turek and Lana, 2013). The other third is comprised by mostly sarcomas and round-cell tumors such as mast-cell tumors and lymphoma, although the latter are rare (Turek and Lana, 2013). Other tumors reported in this site are melanomas, neuroendocrine carcinomas, multilobular osteochondrosarcomas, nerve sheath tumors, hamartomas, hemangiosarcomas, neuroblastomas, fi-

brous hystiocytomas, rhabdomyosarcomas and leiomyosarcomas (Turek and Lana, 2013).

Most of the described thymic epithelial tumors (TETs) are located in the cervical region, lungs and pleura, but they have occasionally been reported in the thyroid gland, pericardium, mediastinum and other intrathoracic locations (Weissferdt and Moran, 2016). To the best of the authors' knowledge, there are no reports in human medicine of thymic carcinomas in the nasopharynx. In veterinary medicine, reports of ectopic TETs are limited. An ectopic cervical thymoma has been described in an eleven-year-old, female, spayed Domestic Shorthair that showed a mid-cer-

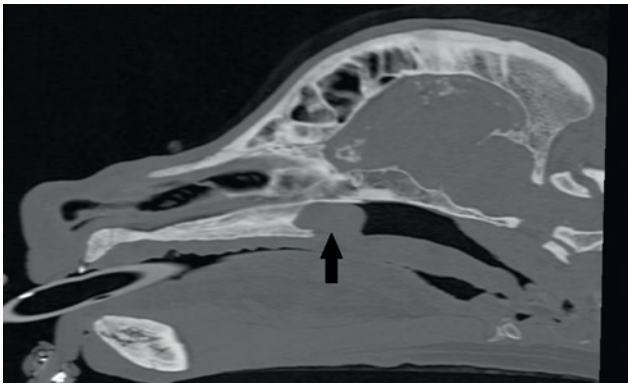


Figure 1. Computed tomography (CT) image (left parasagittal plane, bone window) showing an ectopic thymic carcinoma in the center, arising from the nasopharyngeal mucosae and occluding the nasopharynx. The black arrow shows the location of the ectopic thymic carcinoma.

vical mass and had a history of stertorous breathing. The mass was surgically removed and the cat did well at a sixteen-months' re-examination (Lara-Garcia et al., 2008). In a study by Faisca et al. (2011), a thymic carcinoma in a ten-year-old, neutered, male German Shepherd presenting with cervical mass and respiratory distress has been described. The dog was diagnosed with a carcinoma on the base of cytology of FNA samples and was treated with doxorubicin, firocoxib and cyclophosphamide. This did not improve the dog's clinical condition, after which he was euthanized. Post-mortem examination was performed and histopathological analysis showed the carcinoma was of ectopic thymic origin (Faisca et al., 2011).

CASE DESCRIPTION

An eleven-year-old, male, neutered Golden Retriever of 36.3 kg was presented with a progressively increasing stertorous breathing noise, inspiratory stridor and mucopurulent discharge coming from the left nostril. Airflow was absent from both nostrils and the dog was obligatory mouth breathing. Stertorous breathing had been going on for six months and the dog had lost weight. At the referring veterinarian, the dog was treated with metronidazole (13.8 mg/kg PO BID, Metrobactin, Dechra Veterinary Products, United Kingdom) and meloxicam (0.1 mg/kg PO SID, Metacam, Boehringer Ingelheim Animal Health UK Ltd), which provisionally alleviated the clinical signs. The dog was re-examined by the referring veterinarian one month later. A laryngoscopic examination of the larynx and thoracic radiographs were performed, which revealed no further abnormalities. As the clinical signs worsened, the dog was referred to Southern Counties Veterinary Specialists (UK). A complete hematological examination was performed. Hematology and biochemistry revealed mildly elevated liver enzymes (ALT 149 U/L, reference range 10-125 U/L). The animal was anesthetized, and a CT-scan of the

head, thorax and abdomen revealed a nasopharyngeal mass causing mild bone lysis of the hard palate and moderate lysis of the left turbinates (Figure 1). No signs of nodal or distant metastasis were seen on the CT-scan. Nasopharyngoscopy confirmed a large mass occluding the entire nasopharynx. Biopsies were taken and histopathological examination was indicative of a chronic hyperplastic inflammatory polyp of mixed histiocytic and lymphocytic origin with mucosal erosion from the nasopharynx. There was no evidence of a neoplastic population within the sample but given the degree of bone lysis, an underlying neoplastic process could not be ruled out. The sample was stained for cytokeratin, which showed several small clusters of cells deep within the tissue that were deemed to be either an entrapped submucosal gland or an invagination of the epithelial surface. Based on these results, surgical excision of the mass was performed. The dog was premedicated with 0.3 mg/kg of methadone (Comfortan, Dechra Veterinary Products, United Kingdom) and 10 mcg/kg of acepromazine. He was induced with 2 mg/kg of propofol and was put on volatile anesthesia with isoflurane. A maxillary block with 1.0 ml of 0.5% bupivacaine (Marcain polyamp, Astra Zeneca, United Kingdom) was performed to improve analgesia. The dog was placed in dorsal recumbency, with his mouth fully open. The neck was extended and both front limbs tied caudally. A ventral rhinotomy was performed by a midline incision through the mucosa of the hard and soft palate (Figure 2). The mass was easily isolated from the underlying palate by blunt and sharp dissection and by using a bone burr on the caudal edge of the palatine bone. In this way, the mass could be removed using an "en-bloc" method, along with the portion of affected bone. The incision site was closed in three layers using 3-0 monocryl (Ethicon) in the soft palate and hard palate mucosa. The dog recovered well. Postoperative analgesia was provided in the form of methadone (0.2 mg/kg IV q4h, Comfortan, Dechra Veterinary Products, United Kingdom) for the first day. One day after surgery, the dog was stable and could return home on meloxicam (0.1 mg/kg PO SID, Meloxicam, Boehringer Ingelheim, United Kingdom).

The excised mass was fixed in a formaldehyde solution (formalin, Reagent) and sent for histopathological analysis. Histopathology revealed a large population of small, generally regularly sized lymphocytes infiltrating the submucosa of the nasopharynx. Furthermore, a population of neoplastic cells, supported by a small amount of well-vascularized connective tissue, was causing extensive bone destruction. These cells were polygonal, with distinct cell borders and contained moderate to large amounts of eosinophilic cytoplasm. The cells exhibited several criteria of malignancy; large nuclei, approximately two times the size of the surrounding lymphocytes, stippled to dispersed chromatin and large, pronounced nucleoli. Approximately three mitotic figures were seen per high-powered field. The neoplastic population extended

into the surgeon-cut edges of the incision, indicating an incomplete resection.

Additional immunohistochemistry was performed and showed a variable, weak to intense staining for cytokeratin within the population of neoplastic cells. The surrounding lymphocytes stained positive for CD3, which is typical for T-cells, as would be expected in thymic tissue. Based on these results and the arrangement of neoplastic cells, an ectopic thymic neoplasm was diagnosed. The occasional mitotic figures and invasive nature of the neoplastic cells were consistent with a thymic carcinoma, rather than a more benign thymoma.

Follow-up was performed by telephone four weeks after the surgical procedure. The dog was doing well without any clinical signs. One year later, contact by telephone revealed that the dog had died spontaneously from unknown causes, a post-mortem examination was not performed.

DISCUSSION

Thymic epithelial tumors (TETs) are a group of tumors originating from the thymic epithelium and include thymomas and thymic carcinomas (Friedrich and Young, 2013; Burgess et al., 2016). Multiple putative mechanisms for the development of ectopic thymic tissue have been reported, with two predominant theories: The first is the displacement of parts of the thymus in the caudal migration of the thymus during embryonic development. The second theory is that ectopic TETs differentiate from stem cells present in the tissues (Weissferdt and Moran, 2016). While there is no consensus, the first putative etiology does not explain the localization of all previously described ectopic thymomas, including the one presented here, as the nasopharynx is not localized near the normal migratory path.

Historically, classification was based solely on clinical features of invasiveness, with benign tumors being resectable, well encapsulated and non-invasive, while more malignant tumors were unresectable due to invasion of the surrounding tissues (Friedrich and Young, 2013; Burgess et al., 2016). Human TETs are histologically classified based on the WHO classification although a more simple histological classification system is also available (Burgess et al., 2016). The latter divides TETs in three categories: thymomas, atypical thymomas and thymic carcinomas, and is also used for canine TETs (Burgess et al., 2016). Unlike in humans, there is no clear correlation between histopathological grade and prognosis in canine TETs (Burgess et al., 2016). Thymomas are rare in humans, with a prevalence of 0.13-0.15 cases per 100.000 individuals (Weissferdt and Moran, 2016). Thymic carcinomas are even more rare, accounting for less than 0.06% of tumors of thymic origin (Chung, 2000). Both tumors are also uncommon in dogs (Burgess et al., 2016; Yale et al., 2021). The reported median age

of presentation in dogs is nine years, without report of breed or sex predisposition in most studies (Friedrich and Young, 2013; Burgess et al., 2016). Thymic carcinomas have been very rarely reported, mostly in single case reports (Burgess et al., 2016). In a recent study, it has been shown that when using a classification system based on the current human WHO classification system, six out of 31 tumors previously diagnosed as a thymoma would be classified as a thymic carcinoma. This would suggest that the incidence of thymic carcinomas might be underreported (Burgess et al., 2016).

The authors believe that while canine ectopic thymic carcinomas have been very rarely described, their incidence might be underreported if the histologic classification described by Burgess et al. (2016) was not followed. The presenting localization makes this case worth reporting, as it is a clear and striking example of the large anatomical area where TETs can be a differential diagnosis for a present mass. While this dog eventually died due to an unknown cause, the prognosis was likely guarded due to the tumor cells extending into the surgical margins, its locally aggressive behavior, and the expected progression of disease, despite surgical removal being the treatment of choice for TETs. No signs of metastatic disease were seen on the CT-scan. However, in a recent report by

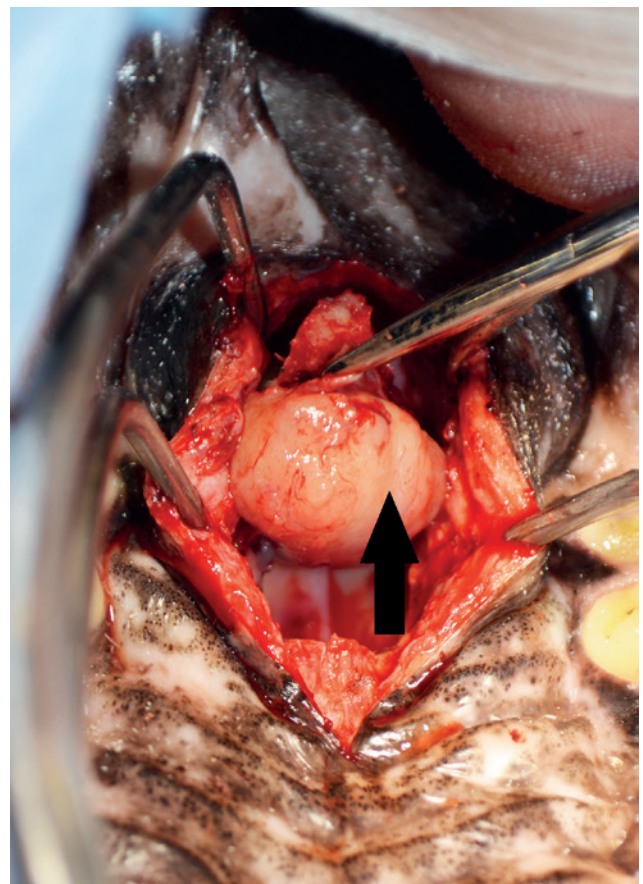


Figure 2. View of the hard palate (front) and the incision made through the caudal part of the hard palate mucosa and the soft palate with the mass visible in-situ. The black arrow shows the location of the mass.

Yale et al. (2021), it was found that lymphadenomegaly was only noted in 38.4% of the cases where there was histological evidence of nodular metastasis (Yale et al., 2021). In the same study, 27.4% of the patients had metastatic disease at the time of diagnosis, 25.4% showed metastasis to the local lymph nodes and 7.8% showed distant metastasis to the lungs and pleura. Additionally, repeat surgical treatment was not possible due to the location of the tumor, and radiotherapy and chemotherapy were declined by the owner.

REFERENCES

- Aronsohn M. (1985). Canine thymoma. *Veterinary Clinics of North America Small Animal Practice* 15 (4), 755-767.
- Burgess K.E., DeRegis C.J., Brown F.S., (2016). Histologic and immunohistochemical characterization of thymic epithelial tumours in the dog. *Veterinary and Comparative Oncology* 14(2), 113-121.
- Chung D.A. (2000). Thymic carcinoma - analysis of nineteen clinicopathological studies. *The Journal of Thoracic and Cardiovascular Surgery* 48(2), 114-119.
- De Mello Souza C.H. (2013). Thymoma. In: Withrow S.J., Vail D.M., Page R.L. (editors). *Withrow and MacEwen's Small Animal Clinical Oncology*. Fifth edition, Elsevier-Saunders, Philadelphia, p.688-691.
- Faisca P., Henriques J., Dias T.M. (2011). *Ectopic cervical thymic carcinoma in a dog*. *Journal of Small Animal Practice* 52, 266-270.
- Friedrichs K.R., Young K.M. (2013). Diagnostic cytopathology in clinical oncology. In: Withrow S.J., Vail D.M., Page R.L. (editors). *Withrow and MacEwen's Small Animal Clinical Oncology*. Fifth edition, Elsevier-Saunders, Philadelphia, p.111-130.
- Lara-Garcia A., Wellman M., Burkhard M.J., (2008). Cervical thymoma originating in ectopic thymic tissue in a cat. *Veterinary Clinical Pathology* 37(4), 397-402.
- Patnaik A.K., Lieberman P.H., Erlandson R.A. (2003). Feline cystic thymoma: a clinicopathologic, immunohistologic, and electron microscopic study of 14 cases. *Journal of Feline Medicine and Surgery* 5(1), 27-35
- Turek M.M., Lana S.E. (2013). Nasosinal tumors. In: Withrow S.J., Vail D.M., Page R.L. (editors). *Withrow and MacEwen's Small Animal Clinical Oncology*. Fifth edition, Elsevier-Saunders, Philadelphia, 2013, p. 435- 451
- Weissferdt A., Moran C.A. (2016). The spectrum of ectopic thymomas. *Virchows Archives* 469, 245-254.
- Yale A.D., Priestnall S.L., Pittaway R. (2021). Thymic epithelial tumours in 51 dogs, histopathologic and clinicopathologic findings. *Veterinary Clinical Pathology* 20(1), 50-58.



© 2022 by the authors. Licensee Vlaams Diergeneeskundig Tijdschrift, Ghent University, Belgium. This article is an open access article distributed under the terms and conditions of the Creative Commons Attribution (CC BY) license (<http://creativecommons.org/licenses/by/4.0/>).

uit het verleden

MIXTEPAARDEN

Het was destijds voldoende dat een boer 's zondags zijn labeurpaard in de speelkar spande om met zijne huisgenooten naar de kerk te rijden, om aangeslagen te worden door den ontvanger om 58,10 fr. belasting te betalen. Talrijke klachten rezen op, en de Kamer stemde den 10 december 1905 de volgende wet:

“Worden niet als mixtepaarden aanzien, alle labeurpaarden gehouden door de landbouwers en soms gebruikt als zadel- of rijtuigpaarden. Uit hoofde van dat bijgevoegd gebruik moet geene belasting voor dergelijke paarden betaald worden.”

Tengevolge dezer wet bestaat het “mixte- of luxepaard” voor den landbouwer niet meer, en de landbouwer kan vrij naar de markt rijden in eene naburige gemeente of voor zaken op de baan komen, zonder dat hij voor het betalen van belasting aangesproken worde.

Niet dat sommige al te ieverige agenten der belasting geene goesting hebben den landbouwer de afgeschafte 58,10 fr. te doen betalen. Zij doen meer: in plaats van een mixtepaard beproeven zij thans sommige landbouwers een vol “prachtpaard” te doen betalen, dat wil zeggen aan te slaan voor 144 fr.

Uit: de *Thouroutsche Bode* van 25 januari 1908.

Johan De Smet