

Successful treatment of an open incisive bone fracture in a horse using a locking compression plate combined with intraoral cerclage wiring

Succesvolle behandeling van een open os incisivumfractuur van de bovenkaak met een compressieplaat met vergrendelde schroeven in combinatie met intraorale cerclage bij een paard

¹A. Leps, ¹H. Haardt, ²K. Vanderperren, ¹L. Vlaminck, ¹A. Martens

¹Department of Large Animal Surgery, Anesthesia and Orthopedics, Faculty of Veterinary Medicine, Ghent University, Salisburylaan 133, 8920 Merelbeke, Belgium

²Department of Morphology, Imaging, Orthopedics, Rehabilitation and Nutrition, Faculty of Veterinary Medicine, Ghent University, Salisburylaan 133, 9820 Merelbeke, Belgium

Alexis.Leps@UGent.be; Hanna.Haardt@UGent.be

ABSTRACT

A seven-year-old warmblood mare presented with bilateral epistaxis, facial swelling and deviation of the nose and upper lip. Upon clinical and computed tomographic examination, a complete, oblique, open and displaced fracture of the nasal process of the incisive bone of the left and right maxilla was found. The fracture was treated surgically with a 3.5 narrow locking compression plate on the dorsolateral aspect of the incisive bone in combination with oral cerclage wiring after temporary retention with cerclage wire connecting the incisors of the mandible and maxilla. The intraoral cerclage wiring was removed twelve weeks post surgery, while the plate remained in situ. There were only minor postsurgical complications, which consisted of transient facial nerve paralysis and swelling. Follow-up radiographs taken eight weeks after surgery documented good fracture healing. Nine months after surgery, the mare returned to her intended use, and showed excellent cosmesis.

SAMENVATTING

Een zeven jaar oude warmbloedmerrie werd aangeboden met bilaterale epistaxis, zwelling ter hoogte van de bovenkaak en deviatie van de neus en bovenlip. Bij klinisch en computertomografisch onderzoek werd een volledige, schuine, open en verplaatste fractuur van het os incisivum van de bovenkaak vastgesteld. De breuk werd tijdelijk gereduceerd door met een cerclagedraad de snijtanden van de boven- en onderkaak aan elkaar te verbinden. Aansluitend werd de fractuur gefixeerd met een 3,5 smalle compressieplaat met vergrendelde schroeven aangebracht op het dorsolaterale aspect van het os incisivum in combinatie met orale cerclage. De intraorale cerclage werd twaalf weken na de operatie verwijderd, terwijl de plaat in situ bleef. De postoperatieve complicaties waren beperkt en bestonden uit voorbijgaande n. facialisverlamming en lokale zwelling. Op de röntgenfoto's acht weken na de operatie was er een goede vordering van de heling te zien. Negen maanden na de operatie kon de merrie opnieuw normaal functioneren en was het cosmetisch resultaat uitstekend.

BACKGROUND

Fractures of the mandible are the most common head injury reported in horses (Auer, 2019). This type of fracture is often caused by excessive forces on the mandibular rami for example when incisors

get trapped in between bars of the stall wall and the horse pulls back its head until the bone breaks. Another cause of these injuries is trauma inflicted by other horses. Mandibular fractures can affect the interdental space, the horizontal rami as well as the vertical rami, and the coronoid process of the mandibula

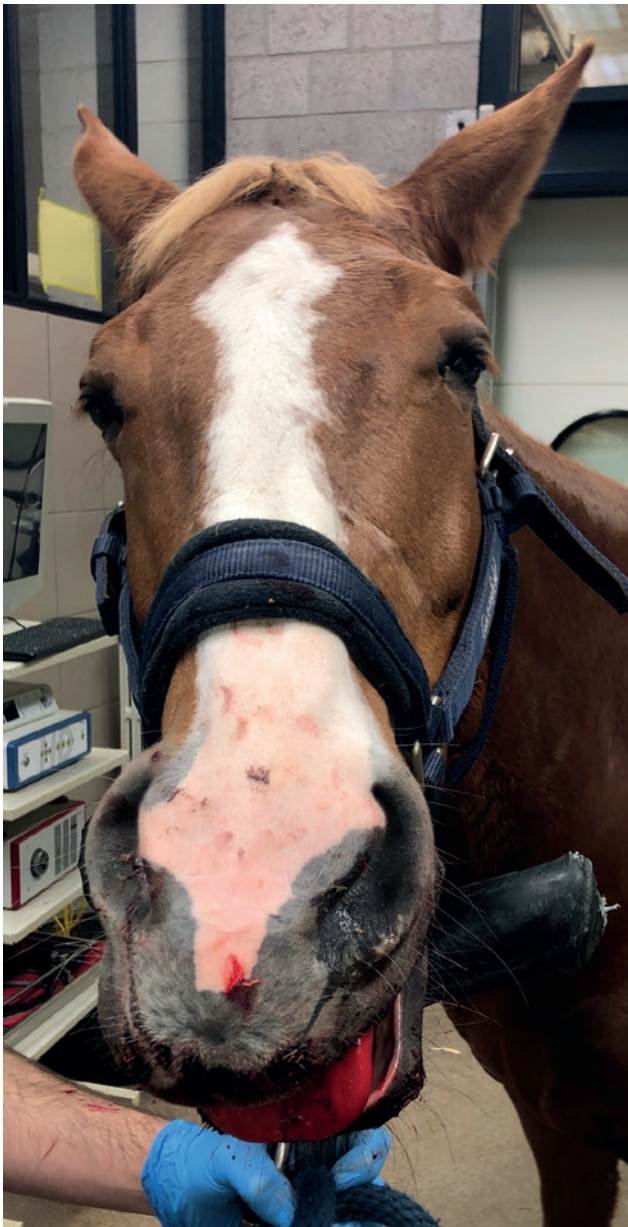

Figure 1. Clinical presentation of the mare. The upper lip points to the right, there is bilateral nasal muco-hemorrhagic discharge and the tongue is sticking out of the mouth.

(Henninger et al., 1999; Auer, 2019). Similar fractures affecting the maxilla and premaxillary bone are less common, and are infrequently reported.

Many mandibular and maxillary fractures are stable, because of the support of surrounding bony and dental tissues. However, this is not the case for complete fractures of the incisive bone or the rostral mandible. In these cases, surgical intervention is necessary (Dixon et al., 2008). Computed tomography is a valuable tool in the diagnosis of head fracture as well as for presurgical planning of fracture repair (Crijns et al., 2019; Nixon, 2020).

Nowadays, surgeons have many options for treatment of jaw fractures in horses, including both internal and external fixation as well as tension band wiring. The choice of repair modality depends on many

different factors including configuration, contamination and stability of the fracture (Beard, 2009; Henninger et al., 1999).

The objective of this report is to describe the successful surgical treatment of a complete, open, bilateral and severely displaced incisive bone fracture of the maxilla using a locking compression plate (LCP) in combination with intraoral cerclage wiring.

CASE HISTORY

A seven-year-old warmblood mare was presented for evaluation of an incisive bone fracture. The owner found the mare in her box in the morning with her nose and upper lip displaced towards the right (Figure 1). A large amount of blood was found on the bars of the hay rack and on the floor right next to it.

CLINICAL FINDINGS

On physical examination, the mare was quiet, alert and responsive. Her heart rate was 48 bpm, her temperature 37.8°C and the respiratory rate 10 bpm. The mucous membranes were pink and moist, with a capillary refill time of two seconds. The upper lip was diffusely swollen and displaced towards the right. The tongue was sticking out of the mouth and there was bilateral nasal muco-hemorrhagic discharge. The horse was sedated with detomidine (Zoetis, the Netherlands; 0.01 mg/kg, IV) to further assess the injury. A complete, open fracture of the left nasal process of the incisive bone at the level of the interdental space, just caudal to 203 was diagnosed on visual inspection. There was displacement to the right and disruption of the mucosa on the left side.

An intravenous catheter was aseptically placed in the left jugular vein to administer sodium penicillin (Kela, Belgium; 22000 UI/kg BDW IV), gentamycin (Emdoka, Belgium; 6.6 mg/kg BDW IV) and flunixin meglumine (Emdoka, Belgium, 1.1 mg/kg BDW IV). Fluid therapy was started at maintenance rate for support of the cardiovascular system (Ringer Lactate at 5mL/kg BDW/h IV).

MEDICAL IMAGING

Standing computed tomography (CT) examination of the head was performed four hours after the initial clinical evaluation using a 320-row scanner (Aquilion One, Canon Medical Systems, Tokyo, Japan). The following parameters were used for the CT image acquisition: slice thickness 0.5 mm, rotation time 0.5 s, field-of-view 50 cm, exposure settings 250 mA and 135 kV, 512x512 matrix. Deep sedation was achieved following intramuscular administration acepromazine (Kela, Belgium; 0.02 mg/kg IM) twenty minutes prior to the procedure, followed by intravenous injection of

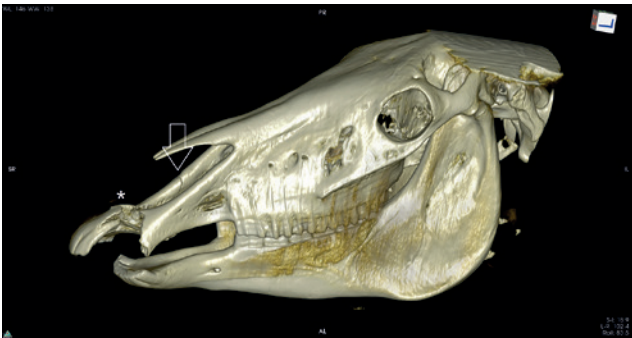

Figure 2. 3D reconstructed CT image showing a complete, oblique and displaced fracture of the left incisive bone (asterisk) as well as a second oblique fracture line on the right nasal process of the incisive bone (arrow).

detomidine (Zoetis, the Netherlands; 0.015 mg/kg IV) and butorphanol (Zoetis, the Netherlands; 0.025 mg/kg IV).

The fracture was characterized by a complete oblique interruption of both cortices of the incisive bones, extending from the alveolar bone distal and lingual to element 203 on the left side to the interdental space on the right side with the presence of multiple adjacent small sharply delineated bone fragments (Figure 2). The detached rostral part of the incisive bone was markedly displaced, with the most rostral aspect rotated to the right side (clockwise when viewed from dorsally) (Figures 3A and 3B). The surrounding soft tissues were moderately swollen. Multiple gas attenuating regions of different sizes and shapes were

identified adjacent to and within the fracture gap. An additional oblique complete hypoattenuating line was present within the dorso-caudal aspect of the right nasal process of the incisive bone caudal to the main region of disruption, coursing in a rostral right lateral to caudo-axial direction over a distance of 3.5 cm. There was minimal displacement (Figure 3C). A circular gas attenuating region was present in the medullary bone at this level.

SURGICAL TREATMENT

Food was withheld for twelve hours prior to surgery while the horse had free access to water. Fluid therapy and antibiotic treatment were continued throughout the night. Temporary tracheotomy was performed at the time of premedication to allow endotracheal intubation using a 20 mm diameter endotracheal tube. This was done to avoid interference of the endotracheal tube while working in the mouth. The mare was premedicated with romifidine (Dechra, UK; 0.08 mg/kg BDW IV) and morphine (Sterop, Belgium; 0.1 mg/kg, IV). She received flunixin meglumine (Emdoka, Belgium; 1.1 mg/kg IV), gentamycin (Franklin Pharmaceuticals, Ireland; 6.6 mg/kg IV) and sodium penicillin (Kela, Belgium; 22000 IU/kg IV) preoperatively. A bilateral maxillary nerve block using 5 mg of bupivacaine hydrochloride (Aspen, South Africa) on each side was performed according to the technique described by Staszuk et al. (2008). The mare was then induced with ketamine (Ecuphar, Belgium;

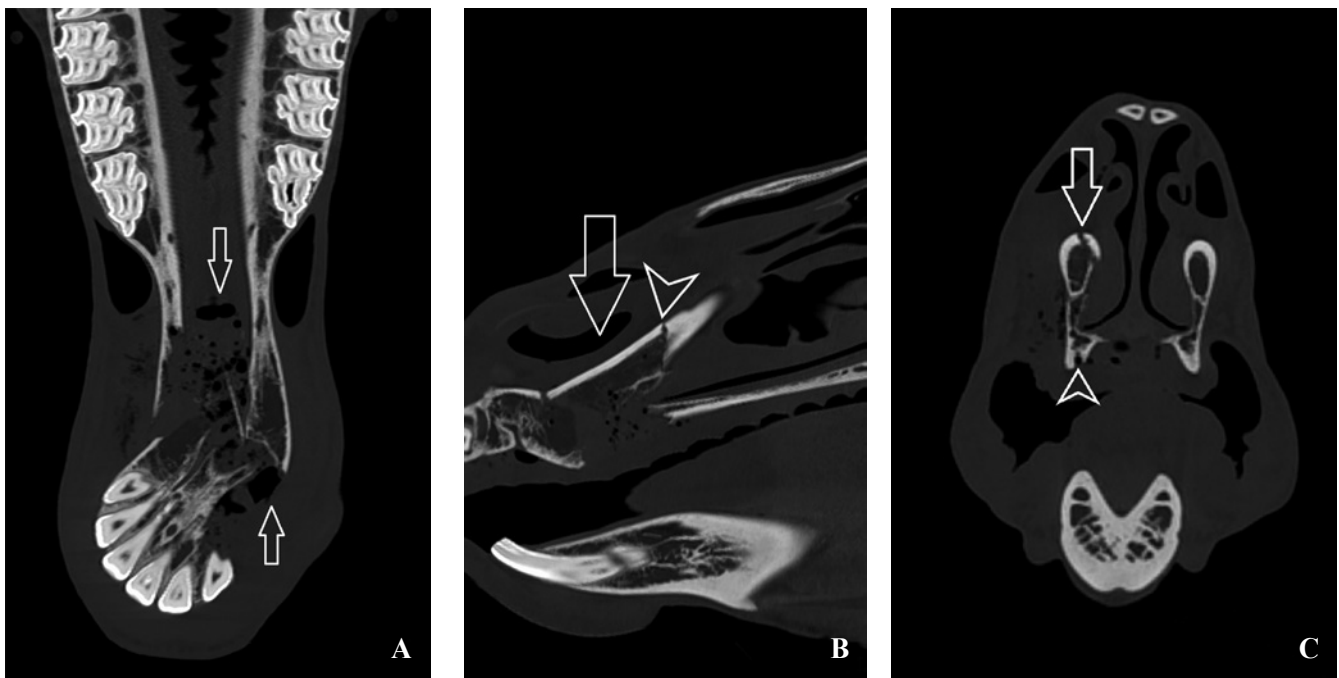


Figure 3. Computed tomographic images of the mare's head at the level of the fracture presented in a bone window. A. Dorsal reconstructed CT image shows the severely displaced fracture with multiple gas attenuations and fracture fragments in the fracture gap (arrows). B. Sagittal reconstructed CT image of the right nasal process of the incisive bone showing the dorsally displaced fragment (arrow) and the additional fracture line (arrowhead) and C. transverse reconstructed CT image showing caudally to the main fracture (arrowhead) the additional fracture line in the right nasal process of the incisive bone (arrow).

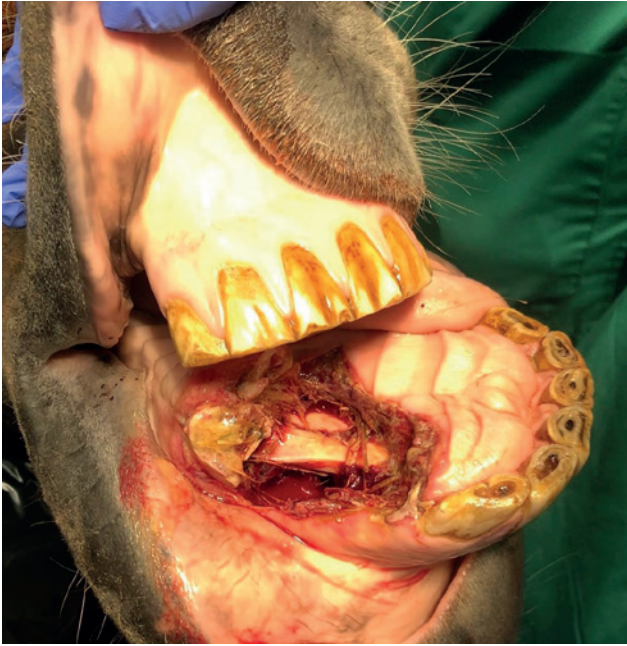

Figure 4. The horse is positioned in dorsal recumbency. The maxilla is at the bottom of the picture. Intraoral picture before aseptic preparation and curettage of the fracture site through the oral cavity. Severe contamination with food material is visible.

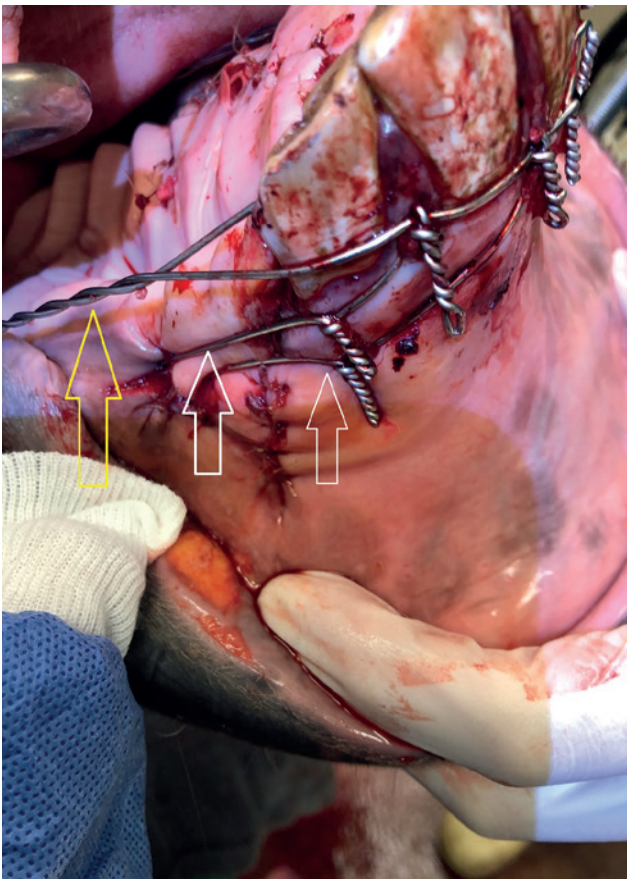


Figure 5. Two intraoral cerclage (white arrows) and the Obwegeser cerclage (yellow arrow) are shown.

2.2 mg/kg IV) and midazolam (Dechra, UK; 0.6 mg/kg IV) using rope assistance. General anesthesia was maintained with isoflurane, romifidine (Dechra, UK, at 0.2ml/h) and dobutamine (Mylan, United States, at 0.05 mL/h IV). The horse was positioned in dorsal recumbency.

The mouth was fixated in an open position by introducing a rubber wedge shaped unilateral mouth gag placed between maxillary and mandibular cheek teeth on the left side of the mouth to allow access to the intraoral fracture site (Figure 4). Food, debris, necrotic mucosa and loose bone fragments were debrided from the intraoral aspect of the fracture, exposing the palatal process of the incisive bone. The intraoral fracture site was then thoroughly curetted and flushed using a 0.05% diluted chlorhexidine solution.

The fracture was reduced by careful manipulation of the maxillary incisor part until complete reduction was achieved. After removal of the rubber wedge, reduction was maintained temporarily using cerclage wire (1.5 mm) to fixate the upper to the lower jaw. This was achieved by threading the wire through the opposing and ipsilateral left and right interdental spaces 01-02.

The left side of the fracture was fixated with two intraoral cerclage loops. The first loop was threaded through interdental space 201-202 and a 3.5 mm hole drilled in the nasal process of the incisive bone. A similar cerclage loop was placed from interdental space 203-204 to a second hole drilled 1 cm rostrally to the first one.

The head of the mare was then rotated clockwise to allow access to the dorso-lateral aspect of the incisive bone. The skin was aseptically prepared in a routine fashion. A 12 cm skin incision was made centered over the fracture line alongside the right incisive bone. Metzenbaum scissors were used for blunt dissection through the subcutaneous tissues. The levator naso-labialis muscle was elevated and the lateral nasal muscle was dissected until the fracture line was visible. The bone was exposed sufficiently to allow the application of a 7-hole 3.5 mm narrow locking compression plate.

The plate was contoured to fit the right nasal process of the incisive bone curvature and placed to accommodate three holes at each side of the fracture line. Two 3.5 mm cortical screws were placed in load position to achieve compression of the fracture. The remaining holes were filled with 3.5 mm locking head screws. After thorough lavage of the surgical site with sterile physiological fluids, the surgical incision was sutured in three layers: the nasal lateral muscle was sutured in an interrupted cruciate pattern using polyglactin 910 (Vicryl USP 2-0), the subcutaneous tissues with a simple continuous pattern using polyglactin 910 (Vicryl USP2-0) and the skin with a simple continuous pattern using polyglyconate (Maxon USP2-0). A stent bandage was placed to cover and protect the skin incision.

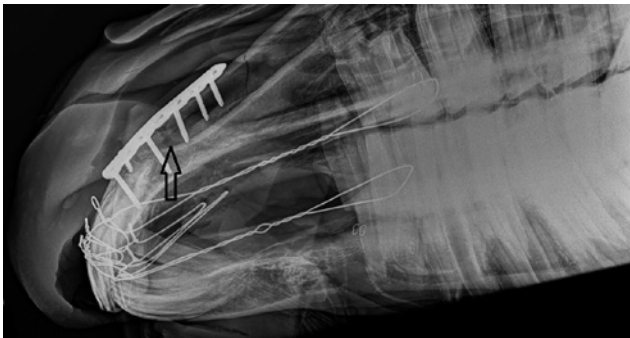


Figure 6. Postoperative radiographs taken two days after surgery: right ventral to left dorsal oblique projection of the rostral aspect of mare's head showing a good apposition of the fracture fragments, and no signs of implant failure. The arrow indicates the fracture line.

The temporary cerclage to appose the incisors was removed and a bilateral Obwegeser brace cerclage (1.5 mm), anchored around maxillary cheek teeth 106 and 206, was placed to increase the stiffness of the fracture repair (Figure 5). Then the palatal and labial mucosa was sutured as good as possible using polyglyconate (Maxon USP 2-0) in a simple interrupted pattern. The clinical crowns of the upper and lower incisors were subsequently reduced by 2 mm on each arcade using a motorized dental rasp to reduce postoperative pressure on the maxillary incisive bone. The total surgery time was 220 minutes. The assisted recovery was uneventful.

After recovery, the tracheotomy tube was removed and the tracheotomy incision was left to heal by second intention. Systemic antibiotic therapy was continued and included sodium penicillin 22000IU/kg QID (Kela, Belgium) for seven days and gentamycin 6.6 mg/kg SID (Franklin Pharmaceuticals Limited, Ireland) for five days. Postoperative pain relief was achieved using flunixin meglumine 1.1 mg/kg BID IV (Emdoka, Belgium) for the first five days then continued SID for another four days, and Morphine 0.1 mg/kg QID IM for three days. The mare was put on a short-fiber and soft feed diet for one week. Afterwards, hay was reintroduced progressively. The mare immediately showed good appetite and great overall comfort.

Immediate postoperative swelling occurred on the right side and the mare developed a mild right facial nerve paralysis, with the upper lip pointing towards the left. The facial nerve paralysis and facial swelling resolved after five days and the mare was discharged two weeks after surgery.

Postoperative radiographic images taken two days after surgery showed good apposition of the fracture and no sign of implant failure (Figure 6).

OUTCOME

Eight weeks after discharge from the hospital, the mare was presented for a check-up to assess fracture

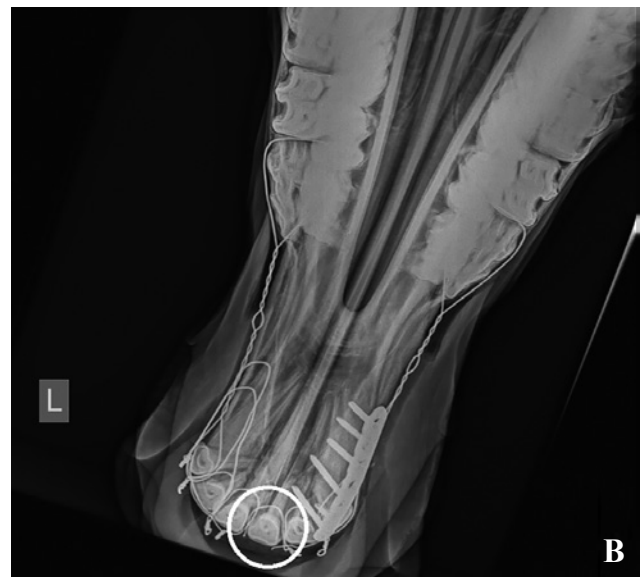
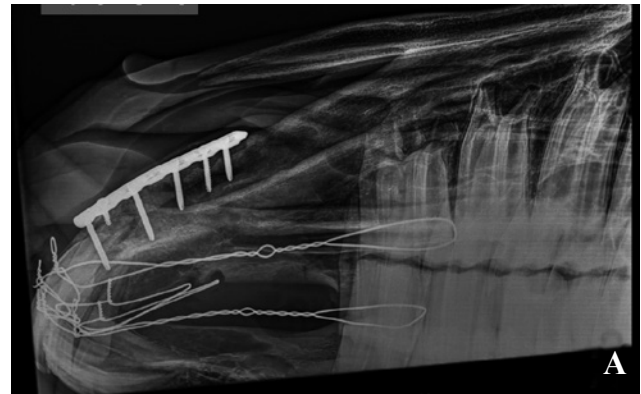
Figure 7. Postoperative radiographs taken eight weeks after fracture repair. A. Right ventral to left dorsal oblique projection depicting the well-apposed rostral fracture supported by the LCP and cerclage wiring. B. Dorso-ventral projection showing that the cerclage wire at the level of the tooth 201 is broken (encircled).

healing. The surgical incision had healed by primary intention. Radiography (right ventral to left dorsal oblique and dorso-ventral projections) showed increased bone opacity within the previously described fracture of the incisive bone and smoother cortical contour compared to immediate postoperative radiographs. The short minimal displaced oblique incomplete fracture line of the dorso-caudal aspect of the right nasal process of the incisive bone was no longer visible. The Obwegeser cerclage wire was broken between 101 and 201 (Figure 7).

Based on clinical presentation and radiographic signs, it was decided to schedule removal of all cerclage wires twelve weeks postoperatively while leaving the plate in situ. A month after cerclage removal, the owners started to ride the mare again. Long-term follow-up via telephone was available at nine months after surgery and the owners reported excellent cosmetic outcome and return of the mare to her intended use.

DISCUSSION

Fractures of the mandible and maxillary bone are common in horses (Beard 2009; Nixon, 2020). Although mandibular fractures are the most common fracture of the head, fractures involving other facial and skull bones of the horse have been frequently reported in the literature (Henninger et al., 1999; Nixon, 2020; Schaaf et al., 2008). Reports on maxillary, especially incisive bone, fractures however are scarce. In this case report, successful repair of an incisive bone fracture using a combination of LCP and intraoral cerclage wiring is described.

Facial skull fractures can often be identified upon clinical examination. However, fracture confirmation and extent vary among cases and should be further diagnosed with radiographs and, if available, CT (Nixon, 2020). Crijns et al. (2019) found that in 93% of the cases of horses with head fractures, radiographs underestimated the number of fragments. In 46% of the cases, radiographs underestimated the extent of the fractures. This was especially true for fractures in anatomically complicated regions (Crijns et al., 2019). In the present case, the fracture was obvious on clinical examination. Standing head CT was chosen over radiographs as imaging modality due to its superiority in the identification of the degree of extent of the fracture line, number of fragments, type of fracture, temporo-mandibular joint involvement and soft tissue involvement (Crijns et al., 2019). As there were no preoperative radiographs taken, it is impossible to say whether the fracture could have been sufficiently assessed on radiographs only. Furthermore, 3D reconstruction of the skull was used to facilitate presurgical planning.

In recent years, the options for surgical treatment of mandibular fractures have multiplied with various implants becoming widely available. Intraoral wiring is the simplest fixation modality but only provides sufficient stability for specific rostral fractures where the fragment can be fixed to parent teeth (Naddaf et al., 2015; Rizk and Hamed, 2018). For more unstable and caudal fractures involving the interdental space, other fixation methods are needed. Previously, external fixators have been described as preferred treatment especially for contaminated or infected fractures such as open intraoral fractures (Bible and Mir 2015; Mahlmann, et al. 2021). Disadvantages include the bulk of material on the outside of the head that can hinder the horse as well as the risk of pin tract infection. In a recent study by Mahlmann et al. (2021), the use of a LCP as external fixator for mandibular fractures, which minimized the size and amount of material on the outside of the horse's jaw has been described. Mandibular fractures can also be stabilized using internal fixation with plates and screws. With the introduction of the locking compression plate, the formerly used dynamic compression plate fell out of favor in equine fracture repair (Durket et al., 2019).

Multiple studies have shown the superior strength of the locking screw plate interface compared to cortical screw plate interface. One disadvantage of the locking compression screws is that the screw must be inserted perpendicular to the plate in order for the head of the screw to rigidly lock into the plate (Nelson et al., 2021; Nixon, 2020). Polyaxial pedicle screws provide a similarly rigid stability to locking screws, but have the advantage that orthogonal placement to the plate is no longer necessary. In a case series by Nelson et al. (2021), polyaxial pedicle screws were used in combination with an external fixator to successfully treat oblique mandibular fractures. Despite the magnitude of reports in the literature about mandibular fractures, there is little information about the options in maxillary incisive bone fracture repair. Based on the comparable anatomy of the incisive part of the mandible and the incisive bone of the maxilla, findings in the mandible can be extrapolated to the incisive bone. In the present case, a combination of an internal locking compression plate and intraoral wiring was chosen to provide optimal stability.

Bone plates are used to redistribute load across the bone and the most stable repair is obtained when the plate is applied to the tensile surface of the bone (Nixon, 2020). In jaw fractures, the tensile surface of the bone is intraorally, and plate insertion at this position is rendered impossible by the teeth (Dixon et al., 2008; Durket et al., 2019). In order to increase the stiffness of the fracture repair, a cerclage, e.g. using the Obwegeser technique, must be placed at the tension side of the fracture (Auer, 2019). In mandibular fractures, the plates are typically placed either laterally, ventrally or ventro-laterally (Dixon et al., 2008; Durket et al., 2019). In a study by Durket et al. (2019), placement of a LCP at the ventrolateral aspect of the mandible was found to provide greater resistance to bending forces than ventral and lateral placements (Durket et al., 2019). Due to similar loading forces on the rostral part of the maxilla, these findings can be extrapolated to maxillary fractures and thus the plate was applied on the latero-dorsal aspect of the nasal process of the incisive bone in the present case. Another advantage to the dorsolateral plate placement is the ability to avoid the roots of the incisors. Even though short-term complication rates following inadvertent opening of pulp cavities while placing implants seem low, there are no long-term studies available proving the safety of this procedure (Maehlmann et al., 2021).

One of the challenges of internal fixation is infection, which can lead to implant loosening and thus instability causing delayed fracture healing or non-union (Dixon et al., 2008). The present fracture was open in the mouth and despite good intraoral debridement and flushing, the fracture and surgical field should still be considered as contaminated. This seriously increases the risk of postoperative infection when internal fixation is used. In the human medicine literature, the infection rate of internal fixation

of mandibular fractures ranges between 6% and 32% (Schaefer and Caterson, 2013). In a study by Kuemmerle et al. (2009) however, a significantly higher infection rate in horses has been suggested, with 50% of their cases showing signs of implant infection after surgery. Unlike in a mandibula, where ventrolateral or ventral plate placement is needed, in a maxilla, the dorsolateral placement of the plate allows fluid to drain away from the plate, following gravity. This and the fact that the plate was relatively far away from the bacteria rich oral cavity, may have been contributing factors to prevent an infection in the present case.

One of the short-term complications faced in this case was a transient facial nerve paralysis that the mare developed 24 hours after surgery. It was assumed to be originating from compression of the facial nerve from the edema surrounding the skin incision. Facial nerve branches were not visible at the moment of dissection, but damage to the nervous tissue during manipulation and dissection of the soft tissues cannot be excluded. In a study by Boorman et al. (2020), horses with an acute onset of clinical signs of facial nerve paralysis were shown to be more likely to have full resolution of clinical signs. In the present case, the facial nerve paralysis had resolved without further treatment.

The second fracture in the right maxilla was not fixated in this case despite minimal displacement of the fracture ends. Surrounding tissues provided enough stability to the fracture line. During follow-up, complete healing of the fracture was visible, and no adverse events occurred.

In conclusion, incisive bone fractures are not a common pathology compared to mandibula fractures in horses. CT is an excellent modality to gain full insight into fracture configuration, and allows for detailed presurgical planning. Fracture repair with LCP plates and cerclage wire yields an excellent cosmetic and functional outcome.

LITERATURE

- Auer, J. A., Stick, J. A., Kümmerle, J. M., Prange, T. (2019). *Equine Surgery*. Fifth edition, W.B. Saunders, Philadelphia, p. 1794-1829.
- Beard, W. (2009). Fracture repair techniques for the equine mandible and maxilla. *Equine Veterinary Education* 21(7), 352-357.
- Bible, J. E., Mir, H. R. (2015) External fixation: Principles and applications. *Journal of the American Academy of Orthopaedic Surgeons* 23(11), 683-690.
- Boorman, S., Scherrer, N. M., Stefanovski, D., Johnson, A.L. (2020). Facial nerve paralysis in 64 equids: Clinical variables, diagnosis, and outcome. *Journal of Veterinary Internal Medicine* 34(3), 1308-1320.
- Crijns, C. P., Weller, R., Vlamincx, L., Verschooten, F., Schauvliege, S., Powell, S. E., van Bree, H. J. J., Gielen, I. M. V. L. (2019). Comparison between radiography and computed tomography for diagnosis of equine skull fractures. *Equine Veterinary Education* 31(10), 543-550.
- Dixon, P. M., Hawkes C., Townsend N. (2008). Complications of equine oral surgery. *Veterinary Clinics of North America-Equine Practice* 24(3), 499.
- Durket, E., Kersh, K., Dembek, K., Riedesel, E., Silverstone, A., Kraus, K., H. (2019). Influence of plate type and placement on the immobilization of bilateral equine mandibular osteotomies: Ex vivo study. *Veterinary Surgery* 48(8), 1450-1455.
- Henninger, R. W., Beard, W. L., Schneider, R. K., Bramlage, L. R., Burkhardt, H. A. (1999). Fractures of the rostral portion of the mandible and maxilla in horses: 89 cases (1979-1997). *Journal of the American Veterinary Medical Association* 214(11), 1648-1652.
- Kuemmerle, J. M., Kummer, M., Auer, J. A., Nitzl, D., Fürst, A. E. (2009). Locking compression plate osteosynthesis of complicated mandibular fractures in six horses. *Veterinary and Comparative Orthopaedics and Traumatology* 22(1), 54-58.
- Mählmann, K., Noguera Cender, A., Ehrle, A., Lischer, C. J. (2021). Application of locking compression plates as type 1 external fixators to treat unilateral mandibular fractures in four equids and one dromedary. *Veterinary Surgery*, 1- 12.
- Naddaf, H., Sabiza, S., Kavosi, N. (2015). Surgical treatment and a unique management of rostral mandibular fracture with cerclage wire in a horse. *Veterinary Research Forum* 6(2), 181-183.
- Nelson, B. B., Easley, J., Steward, S. K. T., Smanik, L. E., Koch D. W., Rawlinson J. E., Easley, J. T. (2021). Polyaxial pedicle screw external fixation to stabilize oblique mandibular fractures in three standing, sedated horses. *Veterinary Surgery* 50(3), 659-667.
- Nixon, Alan J. (2020). *Equine Fracture Repair*. Second edition, Wiley-Blackwell, Hoboken p. 20, p. 721.
- Rizk, A., Hamed, M. (2018). The use of cerclage wire for surgical repair of unilateral rostral mandibular fracture in horses. *Iranian Journal of Veterinary Research* 19(2), 123-127.
- Schaaf, K. L., Kannegieter, N. J., Lovell, D. K. (2008). Management of equine skull fractures using fixation with polydioxanone sutures. *Australian Veterinary Journal* 86(12), 481-485.
- Schaefer, E. H., Caterson, E. J. (2013). Antibiotic selection for open reduction internal fixation of mandible fractures. *Journal of Craniofacial Surgery* 24(1), 85-88.
- Staszuk, C., Bienert, A., Bäumer, W., Feige, K., Gasse, H. (2008). Simulation of local anaesthetic nerve block of the infraorbital nerve within the pterygopalatine fossa: Anatomical landmarks defined by computed tomography. *Research in Veterinary Science* 85(3), 399-406.

