

Excess leukocytosis (leukemoid reaction) associated with feline non-flea, non-food hypersensitivity dermatitis in a young cat

Overmatige leukocytose (leukemoïde reactie) bij een jonge kat met een niet-vlooien- en niet-voedselgerelateerde overgevoeligheidsdermatitis

¹J. H. Kim, ¹H. J. Sung, ²C. Park

¹Department of Veterinary Internal Medicine, College of Veterinary Medicine, Konkuk University, 120, Neungdong-ro, Gwangjin-gu, Seoul, Republic of Korea, 05029

²Department of Veterinary Internal Medicine, College of Veterinary Medicine, Chonbuk National University, Iksan, Jeonbuk, South Korea, 570-752

chulpark0409@jbnu.ac.kr

ABSTRACT

A one and a half-year-old, male, castrated, domestic short-haired cat was presented with a six-month history of depression, anorexia, skin lesions, excessive itching and systemic lymphadenopathy. Complete blood count revealed severe leukocytosis (114,700 cells/ μ l), and peripheral blood films were characterized by marked lymphocytosis. Lymph nodes examinations and bone marrow aspirate were not suggestive of neoplastic changes. Histopathologic examination of skin lesions revealed allergic dermatitis. Based on the anamnesis and histopathologic features, non-flea, non-food hypersensitivity dermatitis (NFNFD) was diagnosed. Treatment was initiated with prednisolone and cyclosporine. During the treatment, the cat fully recovered from the skin lesions. Leukocytosis was reduced to 18,940/ μ l six months after initiation of medication. To the authors' knowledge, this is the first report describing a case of a leukemoid reaction secondary to feline NFNFD.

SAMENVATTING

Een anderhalf jaar oude, mannelijke, gecastreerde korthaar werd aangeboden met klachten van depressie, anorexie, huidlaesies en overmatige jeuk die reeds zes maanden aanwezig waren. Hematologisch onderzoek toonde ernstige leukocytose (114.700 cellen/ μ l) en via een bloeduitstrijkje werd duidelijke lymfocytose aangetoond. Beenmergaspiraats was niet suggestief voor leukemie. Histopathologisch onderzoek van de huidlaesies toonde allergische dermatitis aan. Gebaseerd op de anamnese en de histopathologische bevindingen, werd een niet-vlooien- en niet-voedselgerelateerde overgevoeligheidsdermatitis (NFNFD) gediagnosticeerd en een behandeling werd gestart met prednisolone en cyclosporine. Tijdens de behandeling herstelde de kat volledig van de huidlaesies. De leukocytose werd teruggebracht tot 18,940/ μ l zes maanden na het begin van de medicatie. Volgens de auteurs is dit het eerste beschreven geval van een leukemoïde reactie secundair aan feline NFNFD.

INTRODUCTION

A leukemoid reaction is defined as a white blood cell (WBC) count over 50,000/ μ l without evidence of leukemia or infection in both humans and other animals (Jain, 1993; McKee, 1985). Leukemoid reactions are a potential cause of leukocytosis, especially in cases of predominantly mature granulocytic leuko-

cytosis (McKee, 1985). Leukemoid reactions are caused by exaggerated myeloid production, and have been associated with allergies, burns, intoxication, acute hemorrhage, malignant neoplasms and several other stimuli (Abramson and Melton, 2000; Stav et al., 2002). However, they have not been reported to be associated with feline non-flea, non-food hypersensitivity dermatitis (NFNFD). In this case report, the

Table 1. Hematologic results.

Parameter	Value	Reference interval	Unit
WBC	65,200	2,8–17,0	/ μ l
RBC	8,200	6,5–12,2	10^3 / μ l
HGB	11.4	9.8–16.2	g/dl
HCT	35.9	30.3–52.3	%
MCV	43.3	35.9–53.1	fl
MCH	13.8	11.8–17.3	pg
MCHC	31.8	28.1–35.8	g/dl
PLT	540	151–600	10^3 / μ l
NEUT	20,700	1,400–10,200	/ μ l
LYMPH	36,800	900–6,800	/ μ l
MONO	1,600	0–600	/ μ l
EO	4,500	100–1,500	/ μ l
BASO	200	0–260	/ μ l

WBC white blood cell, RBC red blood cell, HGB hemoglobin, HCT hematocrit, MCV mean corpuscular volume, MCH mean corpuscular hemoglobin, MCHC mean corpuscular hemoglobin concentration, PLT platelet, NEUT neutrophil, LYMPH lymphocyte, MONO monocyte, EO eosinophil, BASO basophils

authors describe a case of extreme leukocytosis involving a WBC count of over 100,000/ μ l in a cat, and discuss its association with a feline NFNFDH induced leukemoid reaction.

CASE REPORT

Medical history and clinical sign

A one and a half-year-old male, castrated, domestic short-haired cat was presented with a six-month history of anorexia, crusted skin lesions, severe itching and systemic lymphadenopathy. The cat was managed with ectoparasite preventatives (Panacur® 250mg Tablet; MSD Animal Health, Seoul, Korea) monthly, and was strictly fed an elimination diet (feline Hypoallergenic™ diet; Royal Canin®, Aimagues, France) for a period of eight weeks. The cat had not been on corticosteroids during the past months. The patient had first been admitted to a local hospital, where hematologic examination revealed marked lymphocytic leukocytosis. Despite the patient being empirically treated with amoxicillin-clavulanate (12.5 mg/kg PO twice daily, Amocla®; Gunil Pharm, Seoul, Korea) and itraconazole (5mg/kg PO twice daily,

Sporanox Cap®; Janssen Pharm, Seoul, Korea) for bacterial and fungal dermatitis, there was no significant improvement of the skin or hematologic symptoms. Pruritus and crusted dry skin lesions worsened progressively over the six-month period, and concurrently, leukocytosis increased to > 100,000/ μ l (with 66% lymphocytes) while hematocrit, hemoglobin and platelets remained within the normal range. Examinations for the evaluation of systemic lymphadenopathy were performed including fine-needle aspiration biopsies (FNAB) and PCR for antigen receptor rearrangements (PARR assay) of multiple peripheral lymph nodes and were submitted to the Clinical Immunopathology Laboratory at Colorado State University. The results were negative for lymphoma. At that time, the cat had been diagnosed tentatively with lymphocytic leukemia and referred to Konkuk University Veterinary Medical Teaching Hospital (KU-VMTH).

At initial presentation at KU-VMTH, the rectal temperature was 38.9°C, the respiratory rate was 24 breaths/min, and the heart rate was 162 beats/min. On initial physical examination, symmetrical self-induced alopecia, crusted papules and excoriations were noted on the extremities and the neck, abdomen and inguinal regions (Figure 1).

Table 2. Hematologic results obtained by a manual 500-cell differential count.

Parameter	Value	Reference interval	Unit
NEUT	19	35–75	%
BANDS	0	0–3	%
LYMPH	72	20–55	%
MONO	2	1–4	%
EO	7	2–12	%
BASO	0	0–3	%

NEUT neutrophil, BANDS band neutrophils, LYMPH lymphocyte, MONO monocyte, EO eosinophil, BASO basophil

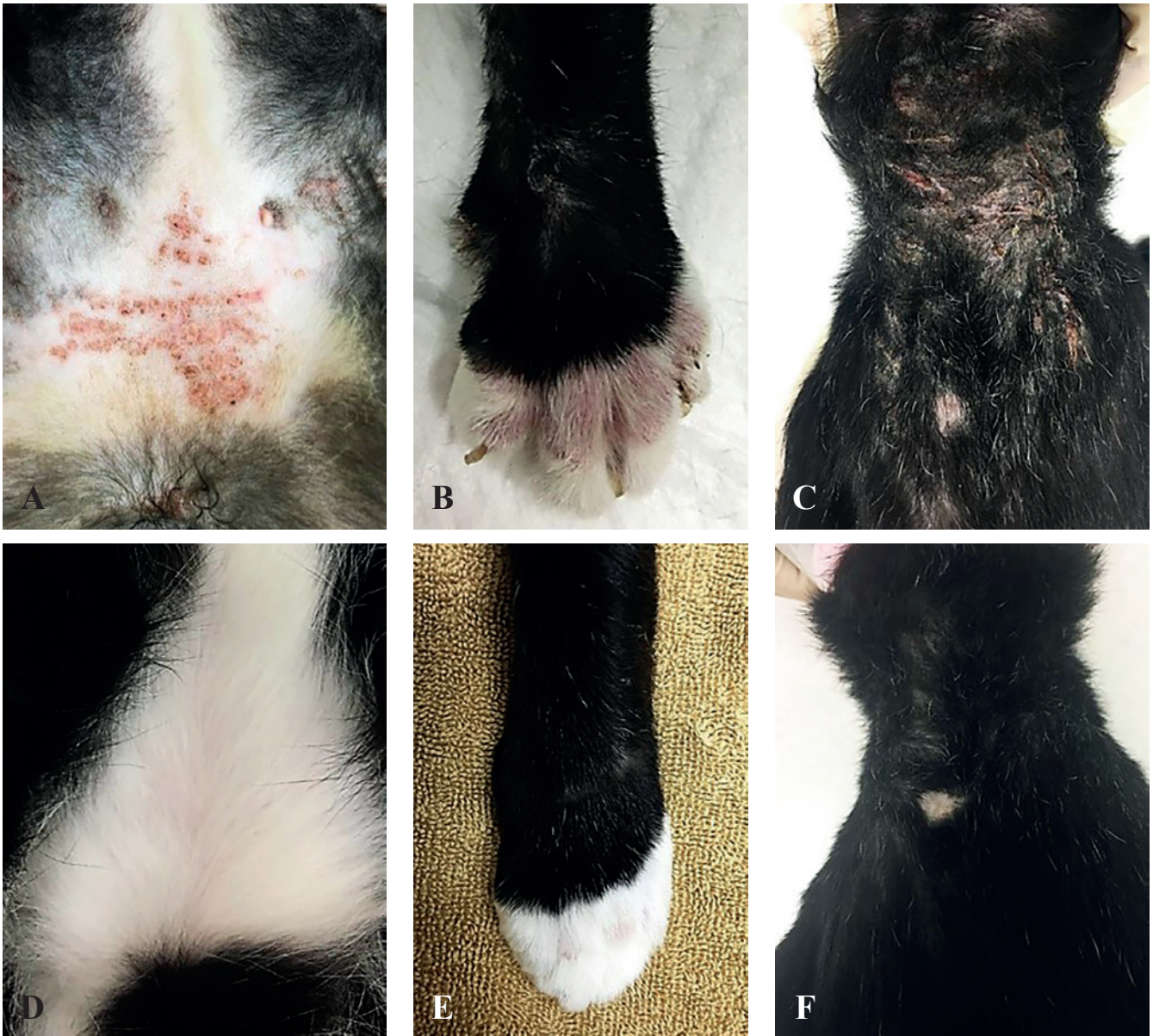


Figure 1. Gross lesions in a cat with feline atopic dermatitis. At presentation, alopecia, erythema, crust and dry scales with self-excoriation were noted on A. inguinal regions, B. extremities, and C. dorsal neck. Six months after presentation, these skin lesions had resolved (D, E, F) with prednisolone and cyclosporine in the same regions shown in A, B and C.

Laboratory tests

A complete blood count (CBC) revealed marked leukocytosis with lymphocytosis, neutrophilia, monocytosis, and eosinophilia. The hematologic results are shown in Table 1. Blood smear microscopy evaluation and a manual 500-cell differential count were performed, and the lymphocytic percentage was markedly increased (Table 2). The lymphocytes were mostly small and had condensed chromatin; there were no immature or neoplastic cells. Serum chemistry yielded no remarkable findings. Urine (obtained via cystocentesis) had a specific gravity of 1.030 and a pH of 7. Whole-body radiographs and ultrasonography were unremarkable. The results derived from

a kit to test for antigens of feline leukemia (FeLV) and feline immunodeficiency virus (FIV) were negative; and ELISA for feline herpes virus and feline corona virus did not detect the presence of those antibodies. To rule out systemic infections, PCR for *Mycoplasma felis*, *Blastomyces*, *Coccidioides* spp., *Cryptococcus* spp. and *Histoplasma capsulatum* was conducted on whole blood and fecal samples, yielding negative results.

Bone marrow biopsy and histopathology

To identify bone marrow disorders, such as chronic lymphocytic leukemia or small cell lymphoma, as the cause of the excessive leukocytosis, bone marrow

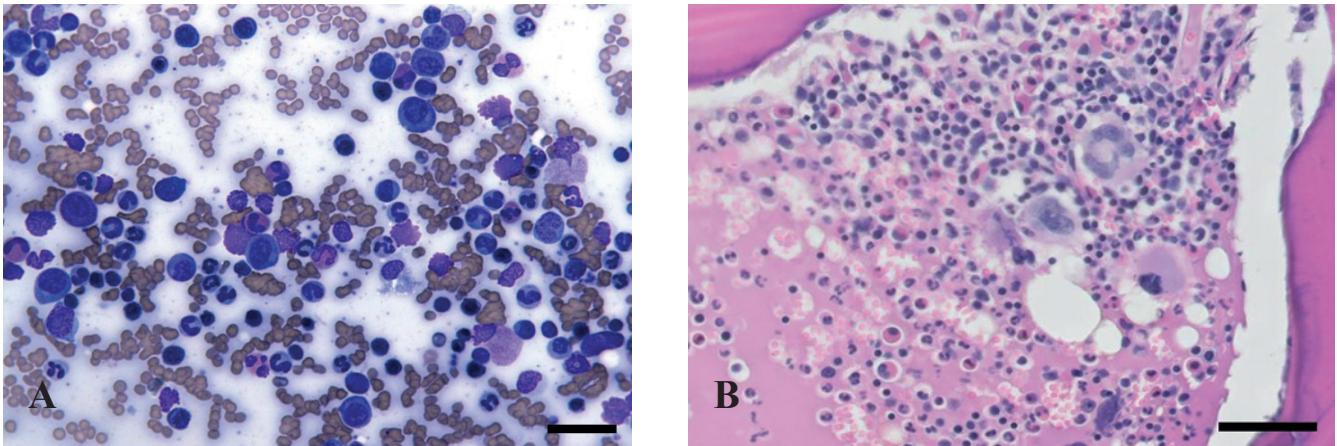


Figure 2. Histopathology of A. the bone marrow aspiration and B. core biopsy. The bone marrow exhibited predominantly mature lymphocytes with myeloid hyperplasia (increased M:E ratio) apparently associated with a chronic infectious or reactive process (hematoxylin and eosin stain, scale bar = 50 μ m).

aspiration and core biopsy were performed. The bone marrow aspirate exhibited moderate cellularity with an adequate number of spicules. Many of the hematopoietic precursor cells were predominantly myeloid in type, and some of the cells were eosinophilic precursors. Relatively few erythroid precursors were noted. The M:E ratio appeared to be moderately to markedly increased. The myeloid cell line appeared complete and relatively orderly, although there was a left shift in maturation. Although erythroid cells were relatively sparse, this series also appeared complete and exhibited orderly maturation. Small lymphocytes were found that accounted for approximately 10% of the cells, and low numbers of plasma cells were also observed. Blast cells accounted for less than 3% of the nucleated cells (Figure 2A). Moreover, the microscopy findings of bone marrow core sampling indicated no evidence of myelofibrosis, myelonecrosis, osteomyelitis or metastatic neoplasia (Figure 2B). The bone marrow findings suggested increased myelopoiesis and decreased erythropoiesis. Additionally, a bone marrow immunofluorescent antibody test for FeLV was negative, and aerobic and anaerobic cultures of the bone marrow yielded no growth. PARR assay was also negative. Based on these findings, a preliminary diagnosis of lymphoproliferative disease related to antigenic stimulation was made.

Skin biopsy and histopathology

To further characterize a possible well-differentiated lymphoproliferative disorder, a skin lesion biopsy was performed. It revealed that the epidermis was multifocally ulcerated and covered with necrotic debris. Epithelial cells were also expanded by clear spaces. Multiple hair follicles contained keratin and cellular debris. The underlying dermis was expanded by small to moderate numbers of mast cells, lymphocytes, plasma cells and eosinophils, and clear spaces with dilated lymphatics. Blood vessels were reactive with peripheral lymphocytes, plasma cells, few neu-

trophils and rare mast cells. These skin lesions were consistent with allergic skin disease, although they are not indicative of a specific allergic cause. No causative organisms including bacteria, ectoparasites and fungi were identified (Figure 3). Based on the history, blood work, bone marrow biopsy and skin biopsy, the cat was diagnosed with feline NFNFD and leukemoid reaction.

Treatment and outcome

During the first two months, until all diagnostic results were available, previous antibiotic and antifungal medications were continued. On month 3, prednisolone (1 mg/kg PO twice daily, Solondo®; Yahan Co., Seoul, Korea) was initiated for feline NFNFD. One month later, a CBC revealed marked reduction in the total leukocyte count, to 37,800/ μ l. On month 5, transient steroid-associated mild hyperglycemia (172 mg/dl; reference interval 74-159 mg/dl) occurred without glucosuria or elevated fructosamine. The dose of steroid was gradually tapered and cyclosporine (5 mg/kg PO twice daily, Sandimmun Neural®; Novartis, Seoul, Korea) was added to the treatment regimen and hyperglycemia was resolved. The patient's WBC counts and lymphocytes were monitored closely, and gradual reduction was observed. Serial WBC and lymphocyte counts following the administration of medications are shown in Figure 4.

The prednisolone was tapered and finally stopped three months after the prednisolone therapy start. The cat adapted well to the cyclosporine with steroid tapering. During the following three months, the dose of cyclosporine was tapered to 5 mg/kg on each alternate day because of soft feces. During the three following years, there were no complications or relapses. The owner was satisfied that the pruritus improved significantly with the cyclosporine monotherapy. On follow-up examinations, the cat was asymptomatic with adequate weight gain, and exhibited WBC counts within the normal range.

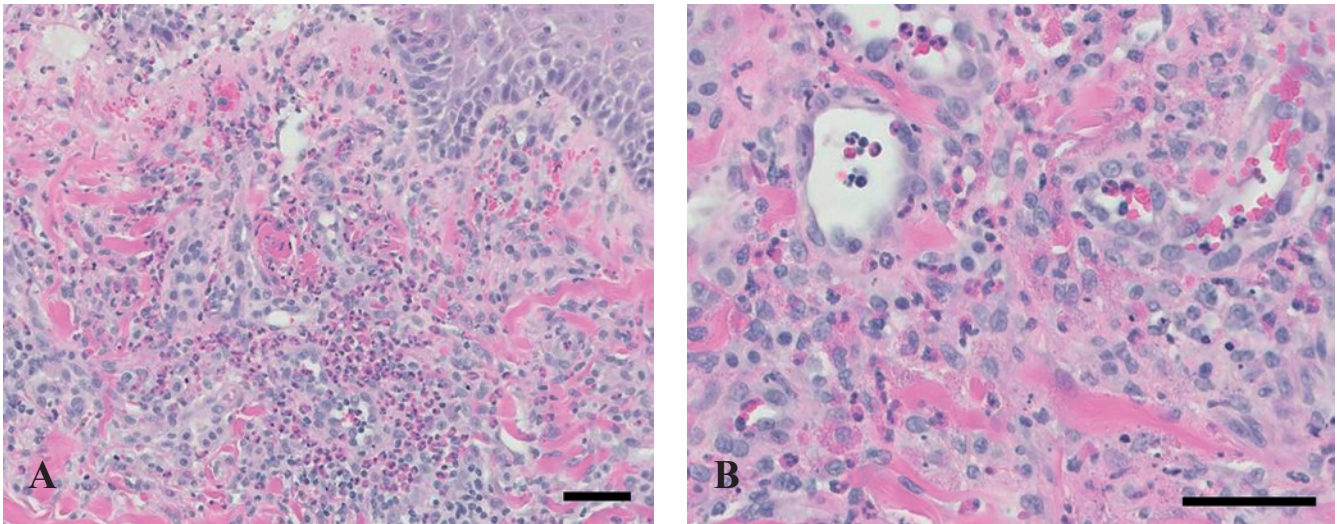


Figure 3. Histopathology of the skin biopsy. The skin lesions supported allergic dermatitis, and the epidermis was multi-focally ulcerated with cellular debris and neutrophils. Note the large numbers of lymphocytes, eosinophils, mast cells and histiocytes in the dermis (hematoxylin and eosin stain, scale bar = 50 μm).

DISCUSSION

In this case report, feline NFNFD with leukemoid reaction is described. Bone marrow aspiration revealed no evidence of leukemic infiltration, but predominantly, mature lymphocytes with myeloid hyperplasia potentially associated with a chronic reactive process were apparent. The case fit the definition of a leukemoid reaction response, in that the cat exhibited a markedly elevated WBC count in peripheral blood and there was an absence of evidence of leukemia in bone marrow. The possible cause of the leukemoid

reaction was feline NFNFD and the leukogram response improved with NFNFD therapy. The owner reported this cat to be in good health two years after discharge from the hospital.

Feline hypersensitivity dermatitis (HD) commonly occurs and it includes flea bite hypersensitivity dermatitis, cutaneous adverse food reactions, angioedema, urticaria and atopic dermatitis (AD) (Hobi et al., 2011). However, the use of the term ‘feline AD’ remains debatable, because of the lack of conclusively demonstrated influence of immunoglobulin E on disease pathogenesis in cats (Reinero 2009). There-

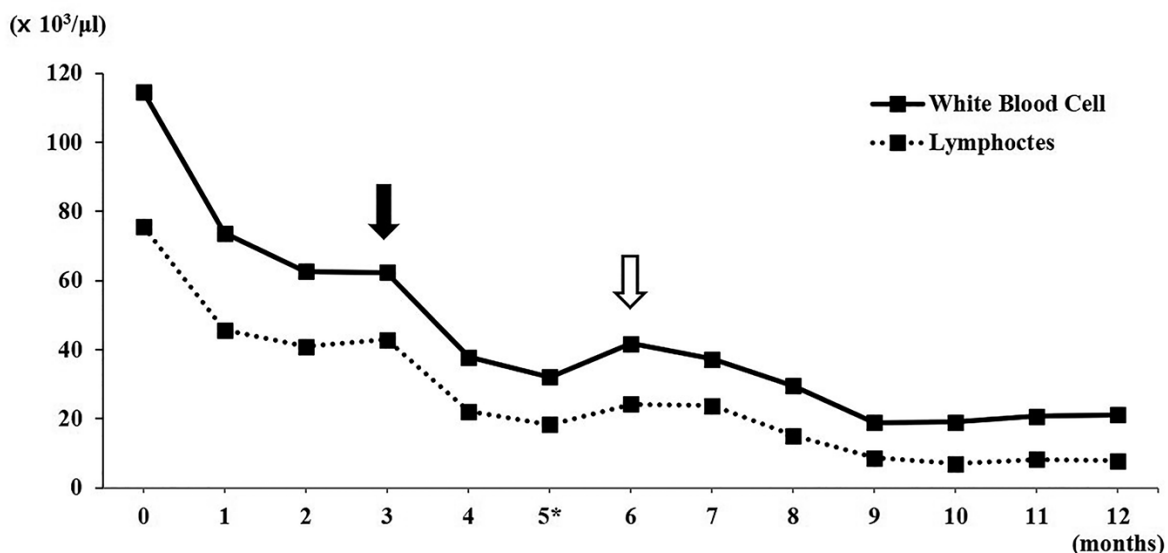


Figure 4. Sequential white blood cell and lymphocyte counts following the administration of medication. For the first three months, there was a gradual decrease in white blood cell count, but it remained high despite the administration of antibiotic and antifungal medications. On month 3, oral prednisolone (black arrow) was administered and the lymphocytic leukocytosis improved significantly from severe to moderate. For the long-term management of the atopic dermatitis, cyclosporine was added to the medication regimen on month 5 (asterisk). On month 6, the lymphocytosis was mildly increased and oral prednisolone was stopped (open arrow) due to a concern of steroid-induced leukocytosis. Thereafter, the lymphocytosis was remarkably improved and remained mild under the administration of cyclosporine monotherapy.

fore, the term 'NFNFD' is preferred when referring to 'feline atopic syndrome' (Hobi, et al., 2011). The diagnosis of feline non-flea HD is based on the exclusion of all other pruritic conditions including ectoparasites, fungal infections or bacterial infections; and the presence of compatible clinical signs (head or neck excoriations, symmetrical self-induced alopecia, eosinophilic diseases or military dermatitis) with a positive response to glucocorticoids, cyclosporine or type 1 antihistamines (Hobi, et al., 2011). Furthermore, as in the present case, pruritic cats with non-flea HD having no conclusive response to a restriction-provocation test (6-8 week restriction diet followed by a two-week challenge with the previous diet) are given the diagnosis of non-flea, non-food HD and they are suspected to have an HD associated with environmental allergens (Hobi, et al., 2011). Causes of non-neoplastic lymphocytosis include diseases that result in immune stimulation, such as Ehrlichia canis infections in dogs and FeLV, FIV infection and Mycoplasma felis infection in cats (Lobetti 1995; Avery and Avery, 2007). Although lymphocytosis associated with antigenic stimulation is generally mild (< 20,000/ μ l) in cats (Valenciano et al., 2010), in the present case report, severe lymphocytosis (> 40,000/ μ l) with feline NFNFD is described. As leukemia and metastatic neoplasia were excluded, this mature leukocytosis of an extreme degree was diagnosed as leukemia-like appearance of the leukogram which is a leukemoid reaction associated with feline NFNFD. In the present case, the NFNFD was long-term managed with oral prednisolone and cyclosporine, which contributed to a reduction in WBCs.

Various therapeutic entities are available for managing feline NFNFD (Hobi et al., 2011). Cyclosporine has been used in human AD, and more recently, in canine AD and feline NFNFD in combination with glucocorticoids (Knottenbelt and Blackwood, 2008). It inhibits T-cell activation and the synthesis of various cytokines, particularly interleukin-2, which inhibits T-cell proliferation and the formation of cytotoxic lymphocytes (Knottenbelt and Blackwood, 2008). In the skin of allergic cats, increased proportion of CD4+ T cells have been demonstrated and T cell involvement appears to be part of the immunopathogenesis of feline NFNFD (Roosje et al., 1998). The drug is available as an emulsion formulation or a capsule; an appropriate dose in cats with NFNFD is 7.5–10.0 mg/kg per day (Knottenbelt and Blackwood, 2008). In the present cat, lymphocytic leukocytosis and skin manifestations associated with NFNFD were successfully managed with cyclosporine in addition to prednisolone.

In the present case, extreme leukocytosis with severe itching prompted the referring veterinarian to consider the possibility of leukemia. However, the absence of blasts in both the peripheral smear and the bone marrow, and a normal mature lymphocytes account in the bone marrow helped to exclude it. The

extreme leukocytosis seen in the present case was probably due to a leukemoid reaction secondary to NFNFD, which is an inflammatory allergic dermatitis. Further, the WBC counts promptly normalized in response to appropriate atopic dermatitis therapy. However, the authors emphasize that a thorough work-up and regular follow-up to rule out the possibility of leukemia are indicated in all cases of extreme leukocytosis. Severe lymphocytosis may be associated with feline NFNFD, and in such cases, a good response to combination treatment with prednisolone and cyclosporine is possible.

REFERENCES

- Abramson N., Melton B. (2000). Leukocytosis: basics of clinical assessment. *American Family Physician* 62, 2053–2060.
- Avery A. C., Avery P. R. (2007). Determining the significance of the persistent lymphocytosis. *Veterinary Clinics of North America. Small Animal Practice* 37, 267–282.
- Campbell M. W., Hess P. R., Williams L. E. (2013). Chronic lymphocytic leukaemia in the cat: 18 cases (2000–2010). *Veterinary and Comparative Oncology* 11, 256–264.
- Dole R. S., MacPhail C. M., Lappin M. R. (2004). Paraneoplastic leukocytosis with mature neutrophilia in a cat with pulmonary squamous cell carcinoma. *Journal of Feline and Medicine Surgery* 6, 391–395.
- Foster A. P. (2008). The Skin. In: Chandler E. A., Gaskell C. J., Gaskell R. M. (editors). *Feline Medicine and Therapeutics*. Third edition, Blackwell, Ames, p. 73–123.
- Gardner F. H., Mettier S. R. (1949). Lymphocytic leukemoid reaction of the blood associated with miliary tuberculosis. *Blood* 4, 767–775.
- Gustafson T. L., Villamil A., Taylor B. E., Flory A. (2014). A retrospective study of feline gastric lymphoma in 16 chemotherapy-treated cats. *Journal of the American Animal Hospital Association* 50, 46–52.
- Harvey J. W. (2001). Leukocytes. In: Harvey J. W. (editor). *Atlas of Veterinary Hematology*. First edition, Philadelphia, p. 45–74.
- Heinrich N. A., McKeever P. J., Eisenschenk M. C. (2011). Adverse events in 50 cats with allergic dermatitis receiving ciclosporin. *Veterinary Dermatology* 22, 511–520.
- Hobi S., Linek M., Maignac G., Olivry T., Beco L., Nett C., Fontaine J., Roosje P., Bergvall K., Belova S., Koebrich S., Pin D., Kovalik M., Meury S., Wilhelm S., Favrot C. (2011). Clinical characteristics and causes of pruritus in cats: a multicentre study on feline hypersensitivity-associated dermatoses. *Veterinary Dermatology* 22, 406–413.
- Irving K. G., Kemp E., Olivier B. J., Mendelow B. V. (1987). Unusual presentation of malaria as a leukaemoid reaction. A case report. *South African Medical Journal* 71, 597–598.
- Jain N. C. (1993). The leukocytes: structure, kinetics. In: Jain N. C (editor). *Essentials of Veterinary Hematology*. First edition, Lea and Febiger, Philadelphia, p. 76–250.
- Knottenbelt C. M., Blackwood L. (2008). The blood. In: Chandler E. A., Gaskell C. J., Gaskell R. M. (editors). *Feline Medicine and Therapeutics*. Third edition, Blackwell, Ames, p. 235–280.
- Lappin M. R., Latimer K. S. (1988). Hematuria and ex-

- treme neutrophilic leukocytosis in a dog with renal tubular carcinoma. *Journal of the American Veterinary Medical Association* 192, 1289–1292.
- Lobetti R. G. (1995). Leukaemoid response in two dogs with Babesia canis infection. *Journal of the South African Veterinary Association* 66, 182–184.
- McKee L. (1985). Excess leukocytosis (leukemoid reactions) associated with malignant diseases. *Southern Medical Journal* 78, 1475–1482.
- Reinero C. R. (2009). Feline immunoglobulin E: Historical perspective, diagnostics and clinical relevance. *Veterinary Immunology and Immunopathology* 132, 13–20.
- Roosje P. J., van Kooten, P. J., Thepen, T., Bihari, I. C., Rutten, V. P., Koeman, J. P. Willemsse, T. (1998). Increased numbers of CD4+ and CD8+ T cells in lesional skin of cats with allergic dermatitis. *Veterinary Pathology* 35, 268–273.
- Stav K., Leibovici D., Siegel Y. I., Lindner A. (2002). Leukemoid reaction associated with transitional cell carcinoma. *Israel Medical Association Journal* 4, 223–224.
- Valenciano A. C., Decker L. S., Cowell R. L. (2010). Interpretation of canine leukocyte responses. In: Weiss D. J., Wardrop K. J., Schalm O. W. (editors). *Schalm's Veterinary Hematology*. Sixth edition, Blackwell, Ames, p. 321–335.
- Valli V. E., Jacobs R. M., Norris A., Couto C. G., Morrison W. B., McCaw D., Cotter S., Ogilvie G., Moore A. (2000). The histologic classification of 602 cases of feline lymphoproliferative disease using the National Cancer Institute working formulation. *Journal of Veterinary Diagnostic Investigation* 12, 295–306.



www.dierenhospitaal-visdonk.nl



Dierenhospitaal Visdonk is een dierenartsenpraktijk waar we met 9 dierenartsen sterk diersoort specifiek werken, zowel op eerste- als tweedelijns niveau. Hiervoor hebben we de beschikking over een uitstekend ingerichte kliniek waar we met een enthousiast team van dierenartsen en

paraveterinair streven naar optimale zorg en kwaliteit voor de dieren. Vanwege de snelle groei van onze praktijk zijn wij op korte termijn op zoek naar een fulltime

ERVAREN DIERENARTS GEZELSCHAPSDIEREN M/V

Wij vragen een collega die:

- aantoonbare werkervaring heeft;
- kwaliteitsbewust is;
- klantgericht is en teamgeest hoog in het vaandel heeft staan;
- een uitdrukkelijke bijdrage wil leveren aan nieuwe ontwikkelingen;
- bereid is te participeren in de diersoort specifieke avond-, nacht- en weekenddiensten (1/7);

Wij bieden uitstekende ontplooiings- en toekomstmogelijkheden.

Schriftelijke sollicitaties met CV, kunt u binnen 10 dagen richten aan Dierenhospitaal Visdonk, t.a.v. mevrouw G. van Staaij, Visdonkseweg 2a, 4707 PE Roosendaal.

Of per e-mail g.vanstaaij@visdonk.nl

LOCATIE VISDONK 📍 Dierenhospitaal Visdonk (hoofdvestiging) Visdonkseweg 2a, 4707 PE Roosendaal 📞 0165 583750 📠 0165 583755

LOCATIE TOLBERG 📍 Dierenkliniek Tolberg (alleen gezelschapsdieren) Tolbergcentrum 53, 4708 GB Roosendaal 📞 0165 533508

1.301116484103386