

## Therapeutic complications and follow-up in a dog with atopic dermatitis

### *Therapeutische complicaties en opvolging bij een hond met atopische dermatitis*

C. Meere, S. Vandenabeele

Small Animal Department,  
Faculty of Veterinary Medicine, Ghent University, Salisburylaan 133, B-9820 Merelbeke

S.Vandenabeele@ugent.be

## ABSTRACT

**In this case report, the therapeutic follow-up of a four-year-old, male, castrated Shih Tzu with atopic dermatitis is described. The treatment first consisted of prednisolone (Prednisolone®), followed by oclacitinib (Apoquel®) and afterwards lokivetmab (Cytopoint®). Furthermore, the diagnosis of AD and the different treatment options are discussed. In addition, more information is given about lokivetmab (Cytopoint®), a new therapeutic agent.**

## SAMENVATTING

In deze casereport wordt de therapeutische opvolging van een vier jaar oude, mannelijke, gecastreerde shih tzu met atopische dermatitis (AD) beschreven. De hond werd behandeld met prednisolone (Prednisolone®), vervolgens met oclacitinib (Apoquel®) en daarna met lokivetmab (Cytopoint®). In de discussie worden de diagnostische aanpak en de verschillende types van behandeling kritisch besproken. Verder wordt ingegaan op de recente therapie met lokivetmab (Cytopoint®).

## INTRODUCTION

Canine atopic dermatitis (AD) has been recognized for a long time. In 1941, the first detailed case report of 'spontaneous allergy', i.e. atopy in a dog with conjunctivitis, urticaria and rhiitis was published. An allergic sensitization to ragweed pollen and a response to allergen-specific immunotherapy (ASIT) were observed (Wittisch, 1941). AD can be defined as a genetically predisposed, commonly seen, pruritic and inflammatory skin disease. In most cases, IgE antibodies are produced to environmental allergens and typical clinical features are seen (Halliwell, 2006). Initially, non-lesional pruritus is seen (Favrot et al., 2010). These symptoms can be seasonal or non-seasonal depending on the type of allergen. Most plant-based, environmental allergens give seasonal pruritus, whereas house dust mites give non-seasonal pruritus (Zur et al., 2002). Primary skin lesions, such as erythema and macular papular rash, are seen on specific body areas, i. e. face, concave aspect of the ear pinnae, ventrally, axillae, inguinal area, distal extremities (Griffin and DeBoer, 2001) (Figure 1). Chronic atopic dermatitis can give secondary skin lesions due to secondary infections, self-trauma and chronic inflammation (Griffin and DeBoer, 2001).

Up to 10% of the dogs worldwide suffer from AD, and therefore, practical guidelines are important to diagnose the disease properly (Scott et al., 2001; Lund et al., 2009). Certain breeds are more predisposed to AD than others suggesting a genetically mediated, familial condition (Nutall et al., 2013). Breed prevalence can vary between geographical areas, and mixed-breed dogs have a lower expected prevalence. (Zur et al., 2002).

In 2015, a set of practical guidelines was published to diagnose AD by a subgroup of the International Committee for Allergic Animals (ICADA). First, other skin conditions with identical or resembling clinical features need to be ruled out. Important differential diagnoses are ectoparasites (*Fleas*, *Scabies*, *Demodicosis*, *Cheyletiellose*, *Pediculosis*, *Otocariasis*, *Trombiculiasis* and *Nasal mites*), microbial skin infections (*Staphylococcal pyoderma*, *Malassezia dermatitis*), other allergic skin diseases (flea allergy dermatitis, food intolerance/allergy, insect bite hypersensitivity, contact dermatitis) and neoplastic skin disease (cutaneous lymphoma). They need to be excluded based on the history, dermatologic examination and diagnostic tests (skin scraping, hair plucking, cytological examination of the skin and ear samples) and the response to treatment. To exclude a cutaneous

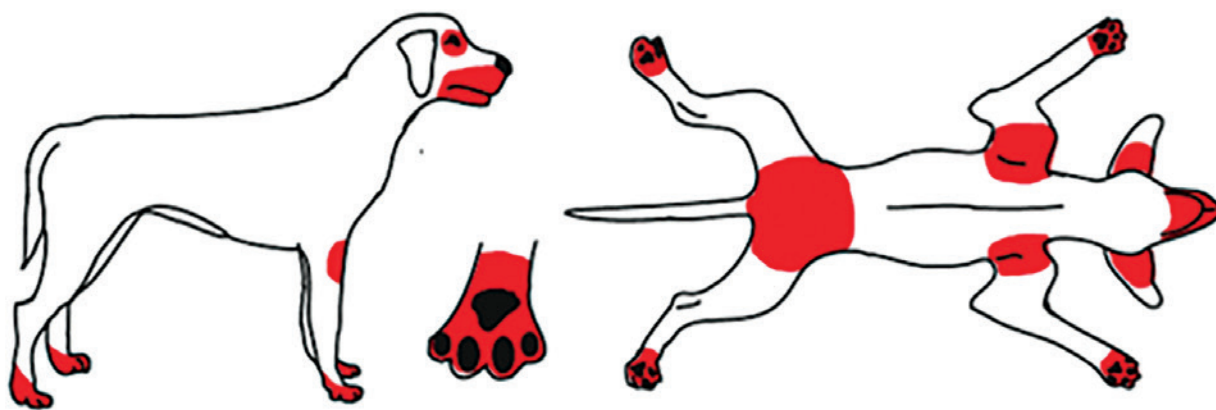


Figure 1. Atopic dermatitis distribution (Griffin and DeBoer, 2001).

adverse food reaction (CAFR), an elimination diet trial is required (Hensel et al., 2015). Secondly, Favrot et al. (2010) created ‘Favrot’s clinical criteria sets’ to help with the detailed interpretation of the historical and clinical features of the patient (Table 1). Finally, once the clinical diagnosis has been made, an allergy test can be performed to identify potential causative allergens for allergen-specific immunotherapy (ASIT) (Hensel et al., 2015).

The therapeutic strategy should focus on AD and complicating skin conditions that may contribute to the cutaneous inflammation and pruritus. Fleas, the most common ectoparasites, are a confounding factor, which provoke pruritus as well. Preventive measurements need to be taken to exclude them. Yeast and bacterial infections are often simultaneously present with AD and also need to be treated. Initially, system-

ic and/or topical treatment should be started, followed by preventive topical treatment measurements. Afterwards, CAFR should also be excluded or diagnosed before the specific treatment of AD can be started. Treatment of AD can be divided into symptomatic and etiologic. Symptomatic treatment includes glucocorticoids (systemically or topically), oclacitinib, ciclosporin and lokivetmab. The etiologic treatment includes allergen avoidance and/or ASIT (Olivry et al., 2010; Saridomichelakis and Olivry, 2016).

### CASE REPORT

On day 0, a four-year-old, male, castrated Shih Tzu was presented at the Dermatology Department of the Small Animal Department of Ghent University with

Table 1. Favrot’s clinical criteria sets (Favrot et al., 2010).

	Use	Reliability	
<b>Set 1:</b>	<ul style="list-style-type: none"> <li>• Use for clinical studies and adapted required criteria based on the goal of the study</li> <li>• If higher specificity is required, 6 criteria should be fulfilled (e.g., drug trials with potential side effects)</li> <li>• If higher sensitivity is required, 5 criteria should be fulfilled (e.g. epidemiological studies)</li> </ul>	• 5 criteria:	
1. Age at onset < 3 years		Sens. 85.4/	
2. Mostly in/oor		Spec. 79.1%	
3. Corticosteroid-responsive pruritus		• 6 criteria:	
4. Chronic or recurrent yeast infections			Sens. 58.2%
5. Affected front feet			Spec. 88.5%
6. Affected ear pinnae			
7. Non-affected ear margins			
8. Non-affected dorso-lumbar area			
<b>Set 2:</b>	<ul style="list-style-type: none"> <li>• Use to evaluate the probability of the diagnosis of canine AD</li> <li>• 5 criteria should be fulfilled</li> <li>• Do not use alone for diagnosis of canine AD, and rule out resembling diseases</li> </ul>	>• 5 criteria:	
1. Age at onset < 3 years		Sens. 77.2%	
2. Mostly indoor		Spec. 83%	
3. “Alesional” pruritus at onset		• 6 criteria:	
4. Affected front feet		Sens. 42%	
5. Affected ear pinnae		Sens. 93.7%	
6. Non-affected ear margins			
7. Non-affected dorso-lumber area			

the complaint of non-steroid responsive atopic dermatitis (pruritus score 10/10). The dog had a chronic history of non-seasonal waxing-and-waning pruritus since the age of two. The pruritus had always been well-controlled with a daily 0.33 mg/kg prednisolone administration. Approximately two months ago, the dog underwent surgical closure of a portosystemic shunt with an ameroid constrictor, and therefore, the dog was still receiving a liver diet (Hill's L/D®, Hill's Pet products, Brussels, Belgium). Since the surgery, the AD was less controlled, and therefore, the dosage of the prednisolone treatment was increased from 0.33 mg/kg daily to alternating 0.5 and 0.33 mg/kg daily. The dog needed a daily therapy with prednisolone to control the AD. Dermatological examination revealed erythematous skin ventrally, scales and greasiness on the dorsum. The differential diagnosis for these symptoms included ectoparasites, microbial skin infections and uncontrolled allergic skin disease. Further diagnostic tests were performed: a tapestrip colored with methylene blue revealed massive *Malassezia* dermatitis on the abdomen and a trichogram from the scaly dorsal skin revealed the presence of numerous demodex mites. The demodicosis was treated with oral afoxolaner (Nexgard, Merial, Toulouse, France) according to the instructions of the manufacturer. The *Malassezia* dermatitis was treated with shampoo containing chlorhexidinegluconate and miconazolnitate (Malaseb, Dechra Veterinary Products A/S, Uldum, Denmark) three times a week, and the AD was treated with the same dose of prednisolone. A re-examination within four weeks was planned to check if the dosage of the prednisolone could be decreased by then.

On day 26, the dog was presented again at the Dermatology Department for recheck. The pruritus was well-controlled and dermatological examination revealed a strongly decreased *Malassezia* infection and well-controlled demodicosis. It was advised to decrease the use of the shampoo to once a week, to continue afoxolaner once a month and change from prednisolone to oral oclacitinib (Apoquel, Zoetis, Zaventem, Belgium,) at 0.5 mg/kg twice daily for fourteen days and then once daily.

On day 43, the dog was presented again at the Dermatology Department for recheck. The pruritus showed a slight increase (pruritus score 7/10), the prescribed use of shampoo was reduced to once a month instead of once a week and afoxolaner was still to be administered monthly. Furthermore, the dog showed signs of lower urinary tract disease (hematuria, strangury and dysuria). The local veterinarian sent urine taken by cystocentesis for culture to the laboratory and diagnosed bacterial cystitis sensible to amoxicillin-clavulanate. Therefore, the dog was treated with oral amoxicillin-clavulanate (Clavaseptin, Vétoquinol, 's Hertogenbosch, the Netherlands) at 12.5 mg/kg twice daily for fourteen days and oral meloxicam (Metacam, Boehringer, Brussels, Belgium, ) at 0.1 mg/kg once daily for ten days. Dermatological examination revealed erythema at the lips, ventral neck, axillae

and at the right inguinal area. Interdigital examination revealed erythema, hyperpigmentation, scaling and a bad odor. The ears also had a bad smell. Bilateral erythema and scales were present at the pinna. A tape strip colored with methylene blue from the interdigital area revealed large numbers of *Malassezia* organisms. *Malassezia* was also present on cytologic ear samples with three organisms/high power field (hpf). The *Malassezia* pododermatitis remained despite of the topical treatment with the shampoo; therefore, oral treatment was started with ketoconazole (Ketofungol, Eli Lilly, Brussels, Belgium) at 6.67 mg/kg once daily for 24 days. The demodicosis was well-controlled, and therefore, the administration of afoxolaner was stopped. The bilateral *Malassezia* otitis was treated locally with ear medication containing orbifloxacin, mometasone furoate and posaconazole (Posatex, Intervet International, Boxmeer, the Netherlands) once daily, and also oclacitinib was maintained once daily.

On day 78, the dog was presented again at the Dermatology Department for re-examination. The pruritus was well-controlled. For one week, the ketoconazole administration was stopped; at that time, the dog still received the prescribed ear medication. The patient again showed signs of lower urinary tract disease (hematuria, strangury and dysuria). Again, urine examination was performed after cystocentesis and an active sediment was seen. Again, the urine was sent for culture and revealed an infection with *E. coli*, which was responsive to amoxicillin clavulanate. Abdominal ultrasound of the bladder was unremarkable. Treatment of the cystitis was repeated. On dermatological examination, the *Malassezia* dermatitis infection and demodicosis were well-controlled. The advice of the Dermatology Department was to continue only oclacitinib, but to stop the medication if the bacterial cystitis would relapse. In that case, ciclosporin (Cyclavance, Virbac, Carros, France) at 5 mg/kg once daily would be a potential replacement therapy for oclacitinib.

On day 141, the dog was presented again at the Dermatology Department for re-examination. Again, the pruritus had increased (pruritus score 7/10) and was localized at the feet, inguinal area and ventrum. The dog still showed symptoms of lower urinary tract disease (hematuria, strangury and dysuria) and was presented to the local veterinarian for this problem. Therapy was changed to nitrofurantoin (Nitrofurantoin, MC Mylan, Bunschoten, the Netherlands) at 4 mg/kg three times daily for fourteen days and meloxicam (Metacam, Boehringer, Germany) at the same dosage for ten days. It was unclear if urine analysis had been performed. Moreover, the dog's diet had changed to Hill's C/D® (and the pruritus score had already increased before the change of diet). On dermatological examination, erythematous skin was present at both ears, thorax, axillae and the inguinal area. On the flank, some crusts were observed. The colored tape strip revealed cocci on the interdigital area and fagocytized cocci on the skin. The dermatologic diag-

nosis was bacterial pyoderma. The advice of the Dermatology Department was to use fusidic acid and betamethasone gel (Isaderm, Dechra, Uldum, Denmark) twice daily, prednisolone (Prednisolone, Kela, Hoogstraten, Belgium) at 0.66 mg/kg once daily for fourteen days and to continue the oclacitinib administration. A subcutaneous injection every thirty days of lokivetmab (Cytopoint, Zoetis, Louvain-la-Neuve, Belgium) at 1 mg/kg, another treatment for atopic dermatitis, was to consider for the next check-up.

On day 181, the dog was presented again at the Dermatology Department for a first injection with lokivetmab. The pruritus was decreased (pruritus score 6/10). According to the owner, the dog urinated less. The diet still included Hill's C/D® and Hill's I/D low fat® as a treat. On dermatological examination, erythema was seen at the axillae, medial side of the front paws, inguinal area and interdigitally. *Malassezia* was present on cytologic examination of the feet (6/HPF). The advice of the Dermatology Department was to treat the AD with lokivetmab instead of oclacitinib and the *Malassezia* pododermatitis with shampoo (chlorhexidinegluconate and miconazolnitate and ketoconazole) three times a week and ketoconazole (Ketofungol, Eli Lilly, Brussels, Belgium) at 6.67 mg/kg once daily for 24 days.

On day 208, the dog was re-presented at the Dermatology Department. There were no signs of cystitis and therefore, urine analysis was not performed. Three weeks after the first injection, the pruritus returned at the paws. The dog's diet remained the same. On dermatological examination, the erythematous skin was not present anymore, but saliva staining of the hairs was still present on the cranial axillae and feet. The advice of the Dermatology Department was to treat the AD with a second injection of lokivetmab. With the lokivetmab injections, the pruritus was well-controlled. Moreover, it was advised to continue the ketoconazole administration during the weekends to treat the *Malassezia* pododermatitis.

On day 236, the dog was presented again at the Dermatology Department for. The pruritus had significantly decreased (pruritus score 1-2/10). Urinating was normal. On dermatological examination, no abnormalities were seen. The advice of the Dermatology Department was to give the third lokivetmab injection to treat the AD and to repeat the injection in five weeks. To treat the *Malassezia* pododermatitis, the advice was to continue the ketoconazole administration in the weekend. From then on, the local veterinarian could give the injections monthly.

## DISCUSSION

In this case report, the diagnosis of AD was based on the history, clinical features and the positive reaction to glucocorticoids. As stated in the introduction, the diagnosis is made by exclusion of other skin conditions with identical or resembling clinical features.

Normally, clinical features start under three years of age and in indoor dogs (Favrot et al., 2010). This dog was a pure bred Shih Tzu, living indoors, and the pruritus started around the age of three. The exact onset of the pruritus was not known since the dog was presented at the Dermatology Department for the first time at the age of four. Normally, the pruritus is glucocorticoid responsive (Favrot et al., 2010). However, the dog in this case report was presented with non-steroid responsive atopic dermatitis. The prednisolone treatment had been successful in the past, but at the first consultation at the Dermatology Department, the dog was also suffering from concomitant *Malassezia* dermatitis and demodicosis. These infections were responsible for the shift from glucocorticoid responsive to non-steroid responsive AD (pruritus score 10/10).

Bowden et al. (2018) reported the presence of AD as a concomitant disease for dogs with demodicosis. Furthermore, they suggested that the Shih Tzu breed might be predisposed to develop demodicosis as well as *Malassezia* dermatitis (Bajwa, 2017).

The *Malassezia* dermatitis in the dog of the present case was initially treated three times a week with a shampoo containing chlorhexidinegluconate and miconazolnitate (Malaseb, Dechra Veterinary Products A/S, Uldum, Denmark). At that point in time, systemic use of ketoconazole was not a good option to treat the *Malassezia* dermatitis, because the dog had recently undergone surgery for an extra hepatic portosystemic shunt (EHPSS). Hepatic injury due to ketoconazole has been known for a long time (Lewis et al., 1984) and severe liver injury due to ketoconazole has been reported (Greenblatt and Greenblatt, 2014).

It is difficult to determine the actual prevalence of liver injury during the clinical use of ketoconazole as an antifungal agent. In this case report, the *Malassezia* dermatitis could not be controlled with the shampoo, and therefore, the therapy was changed to systemic treatment with ketoconazole. Since the EHPSS was closed, this therapy was a good option. In the literature, it has not been described which type of treatment (shampoo or systemic treatment) is the best to use to treat *Malassezia* dermatitis. Negre et al. (2009) recommended both the use of the shampoo (chlorhexidinegluconate 2% and miconazolnitate 2%; twice a week for three weeks) and systemic treatment (ketoconazole 10 mg/kg and itraconazole 5 mg/kg a day for three weeks) for *Malassezia* dermatitis. The systemic treatment with ketoconazole during the weekend was given to decrease the risk of recurrence of the *Malassezia* dermatitis. In this case, a dose of 6.7 mg/kg of ketoconazole was administered to the dog. In a study by Bensignor (2009), there was no significant difference between 5 and 10 mg kg<sup>-1</sup> day<sup>-1</sup> of ketoconazole administered once daily for three weeks (Negre et al., 2009); with a history of a portosystemic shunt, the lower dosage regimen was chosen in the patient of that study (Bensignor, 2009).

Diagnostic tests to exclude or diagnose CAFR were not performed. On the other hand, the dog of

the present case had no gastro-intestinal symptoms, nor did it show progressive pruritus, which made the presence of CAFR less likely (Hensel et al., 2015). Another important factor was the EHPSS, for which the dog needed a liver diet. Therefore, an elimination diet was not performed in this dog. Atopic dermatitis with food allergens as flare factors can thus not be completely excluded, but given the fact that the pruritus and infections in the dog of the present case were well-controlled with the monthly lokivetmab injections, a food allergy component was considered unlikely; hence, further work-up was not pursued.

For therapy optimization, the dog was frequently presented at the Dermatology Department. Dogs with AD need to be followed up at regular intervals, and a multimodal approach is usually beneficial to optimize treatment results with minimal side effects (Olivry et al., 2010; Saridomichelakis and Olivry, 2016).

Glucocorticoids were the first type of medication used to treat the AD in this case report. Prednisolone (0.33 mg/kg daily) had already been administered at the first consultation and the dose was increased to alternating 0.5 and 0.33 mg/kg daily. According to Olivry et al. (2015), a dosage of 0.25 – 0.50 mg/kg every other day corresponds to a normal maintenance dose in most of the AD patients. In this case report, the daily dosage of prednisolone was considered inappropriate for long-term therapy of atopic dermatitis. Due to the long-term use of prednisolone, the dog developed demodicosis and potentially, *Malassezia* dermatitis. However, the *Malassezia* dermatitis might also have been (part of) the primary flare factor of the AD, since this organism can act as an allergen for AD. Other side effects of prednisolone, such as polyuria, polydipsia, polyphagia, behavior changes, lethargy, vomiting, panting, diarrhea and hepatotoxic side effects, were not present in this dog (Olivry et al., 2015).

Although daily treatment with prednisolone leads to unwanted side effects, in the present case, it was necessary to control the allergic pruritus. Once the skin infections were treated, prednisolone was replaced by oclacitinib at the prescribed dose of one tablet of 3.6 mg once a day. The skin infection remained well-controlled, but a recurrent bacterial cystitis occurred. Cystitis has been described as a side effect of oclacitinib in more than 1% of the dogs after sixteen days of therapy (Cosgrove et al., 2015). Oclacitinib is a Janus Kinase inhibitor (JAK), possibly inhibiting other cytokines than the pro-inflammatory cytokines for pruritus/allergic reactions. Urinary tract infection/cystitis, vomiting, otitis, pyoderma and diarrhea are the most frequently reported side effects (Cosgrove et al., 2015).

Because of the recurrent bacterial cystitis in this case report, oclacitinib was changed to lokivetmab, and shortly thereafter, the bacterial cystitis was well-controlled and did not recur. Ciclosporin was also suggested as a potential replacement therapy, but long-term use of ciclosporin (Peterson et al., 2012) (and

glucocorticoids (Torres et al., 2005)) may also cause an increased risk for developing a urine tract infection (UTI). Therefore, it is recommended to perform a bacterial urine culture in dogs with pruritic disorders who receive long-term ciclosporin at least yearly (Peterson et al., 2012) or glucocorticoids (Torres et al., 2005). The incidence of subclinical bacteriuria in these dogs is respectively 8-30% and 18-39% (Torres et al., 2005; Peterson et al., 2012). On the other hand, Simpson et al. (2017) have recently described that oclacitinib does not lead to bacteriuria in dogs without a previous history of UTI or in dogs without other predisposing conditions for UTI. In contrast to glucocorticoids and ciclosporin, a bacterial urine culture at regular intervals is not recommended for dogs without clinical signs of UTI or abnormal urinalysis.

Lokivetmab contains a specific caninized monoclonal antibody against interleukin-31 (IL-31) and inhibits the IL-31 mediated signal transduction pathway that is part of the pathogenesis of atopic dermatitis. In AD skin, T helper 2 (T<sub>H</sub>2)-deviated immune reactions occur and IL-31 is produced by the T<sub>H</sub>2 cells (Furie et al., 2017). IL-31 is therefore seen as a pruritogenic cytokine (Gonzales et al., 2013; Furie et al., 2017). Due to the specific mode of action of lokivetmab, side effects are very rare; also hypersensitivity reactions are very rare. Lokivetmab is a safe product to use among AD dogs (Michels et al., 2016b; Moyaert et al., 2017). Michels et al. (2016b) found no immediate hypersensitivity reactions and only a very small percentage (2.5%) of treatment-induced immuno-genicity has been described. The dog in this case report received lokivetmab at the prescribed dose (1 mg/kg) and (approximately) frequency (30 days) (Moyaert et al., 2017). The dog was comfortable with this therapy (pruritus score of 1-2/10). Very mild pruritus (itching score 1-2/10) started approximately two to three weeks after the administration of the injections. Actually, it has been described that lokivetmab (0.5 and 2.0 mg/kg) reduces pruritus for at least one month. However, patients who are treated with higher doses of lokivetmab may respond at a higher level and for a longer period (Michels et al., 2016a). Furthermore, after a minimum dose of 1 mg/kg, the product has a quick onset of action (within one day) (Moyaert et al., 2017).

The dog in this case report was treated only symptomatically. Allergen avoidance is very difficult and often, it is impossible to eliminate all allergens. On the other hand, a reduction of some allergens may be beneficial to reduce the required amount of symptomatic treatment (Scott et al., 2001). For ASIT, patient-specific allergens are injected to reduce the clinical signs of AD (Keppel et al., 2008). The main drawbacks of this treatment are the success rate, the time period before the effect can be assessed and the costs. ASIT has a success rate (50% improvement in clinical signs) of 60 to 70% (DeBoer, 2017) and it should be administered at least six months before the effect

can be assessed. The costs are relatively high compared to the classic symptomatic treatment with prednisolone (Saridomichelakis and Olivry, 2016). On the other hand, ASIT therapy is safe to use for a long-term period (Kovse et al., 2012), and etiologic treatment has the potential to influence the course of the disease. When positive results are obtained, generally, lifelong treatment will be necessary (Griffin and Hillier, 2001).

The dog in this case report was treated symptomatically and finally, with lokivetmab, a good control of the AD was achieved. Another option would have been a combination of lokivetmab and ASIT. Symptomatic and etiologic treatments of AD can be combined and the use of both can be beneficial.

## CONCLUSION

In this case report, the different ways to treat AD are discussed with the therapeutic advantages and disadvantages. A dog is described with AD, which was first steroid responsive but became non-steroid responsive due to *Malassezia* dermatitis and demodicosis. The therapy was changed from prednisolone to oclacitinib; however, this therapy could not prevent recurrence of cystitis. Finally, the therapy was changed to lokivetmab with good results. The AD was well-controlled without any side effects.

In conclusion, there is no superior therapy for AD, because the therapy is case-dependent and therefore, every patient should have its own work-up. Furthermore, follow-up is important to diagnose problems in an early stage and to keep the level of pruritus low. Lokivetmab, a new product, induces very few side effects and gives good therapeutic results.

## REFERENCES

- Bajwa J. (2017). Canine *Malassezia* dermatitis. *The Canadian Veterinary Journal* 58, 1119-1121.
- Bensignor E. (2001). An open trial to compare two dosages of ketoconazole in the treatment of *Malassezia* dermatitis in dogs. *Annales de Médecine Vétérinaire* 145, 311-315.
- Blaskovic M., Rosenkrantz W., Neuber A., Sauter-Louis C., Mueller R.S. (2014). The effect of a spot-on formulation containing polyunsaturated fatty acids and essential oils on dogs with atopic dermatitis. *The Veterinary Journal* 199, 19-43.
- Bowden D.G., Outerbridge C.A., Kissel M.B., Baron J.N., White S.D. (2018). Canine demodicosis: a retrospective study of a veterinary hospital population in California, USA (2000-2016). *Veterinary Dermatology* 29, 19-29.
- Cosgrove S.B., Cleaver D.M., King V.L., Gilmer A.R., Daniels A.E., Wren J.A., Stegemann M.R. (2015). Long-term compassionate use of oclacitinib in dogs with atopic and allergic skin disease: safety, efficacy and quality of life. *Veterinary Dermatology* 26, 171-179.
- DeBoer D.J. (2017). The future of immunotherapy for canine atopic dermatitis: a review. *Veterinary Dermatology* 28, 25-31.
- Favrot C., Stefan J., Seewald W., Picco F. (2010). A prospective study on the clinical features of chronic canine atopic dermatitis and its diagnosis. *Veterinary Dermatology* 21, 23-30.
- Furue M., Yamamura K., Kido-Nakahara M., Nakahara T., Fukui Y. (2017). Emerging role of interleukin-31 and interleukin-31 receptor in pruritus in atopic dermatitis. *Allergy* 73 (1), 29-36.
- Gonzales A.J., Humphrey W.R., Messamore J.E., Fleck T.J., Fici G.J., Shelly J.A., Teel J.F., Bammert G.F., Dunham S.A., Fuller T.E., McCall R.B. (2013). Interleukin-31: its role in canine pruritus and naturally occurring canine atopic dermatitis. *Veterinary Dermatology* 24, 48-53.
- Greenblatt H.K., Greenblatt D.J. (2014). Liver injury associated with ketoconazole: Review of the Published Evidence. *The Journal of Clinical Pharmacology* 54 (12), 1321-1329.
- Griffin C.E., DeBoer D.J. (2001). The ACVD task force on canine atopic dermatitis (XIV): clinical manifestations of canine atopic dermatitis. *Veterinary Immunology and Immunopathology* 81(3-4), 255-269.
- Griffin C.E., Hillier A. (2001). The ACVD task force on canine atopic dermatitis (XXIV): Clinical manifestations of canine atopic dermatitis. *Veterinary Immunology and Immunopathology* 81, 255-269.
- Halliwell R. (2006). Revised nomenclature for veterinary allergy. *Veterinary Immunology and Immunopathology* 114(3-4) 207-208.
- Hensel P., Santoro D., Favrot C., Hill P., Griffin C. (2015). Canine atopic dermatitis: detailed guidelines for diagnosis and allergen identification. *BMC Veterinary Research* 11, 196-209.
- Keppel K.E., Campbell K.L., Zuckermann F.A., Greeley E.A., Schaffler D.J., Husmann R.J. (2008). Quantitation of canine regulatory T cell populations, serum interleukin-10 and allergen-specific IgE concentrations in healthy control dogs and canine atopic dermatitis patients receiving allergen-specific immunotherapy. *Veterinary Immunology and Immunopathology* 123, 337-344.
- Kovse M., Zrimsek P., Kotnik T. (2012). Evaluation of the effect of allergen-specific immunotherapy in atopic dogs using the CADESI-03 scoring system: a methylprednisolone controlled clinical study. *Veterinarski Arhiv* 82 (2), 251-264.
- Lewis J.H., Zimmerman H.J., Benson G.D., Ishak K.G. (1984). Hepatic injury associated with ketoconazole therapy. Analysis of 33 cases. *Gastroenterology* 86 (3), 503-513.
- Lund E.M., Armstrong P.J., Kirk C.A., Kolar L.M., Klausner J.S. (1999). Health status and population characteristics of dogs and cats examined at private veterinary practices in the United States. *Journal of the American Veterinary Medical Association* 214, 1336-1341.
- Marsella R., Olivry T., Carlotti D.N. (2011). Current evidence of skin barrier dysfunction in human and canine atopic dermatitis. *Veterinary Dermatology* 22, 239-248.
- Michels G.M., Ramsey D.S., Walsh K.F., Martinon O.M., Mahabir S.P., Hoevers J.D., Walters R.R., Dunham S.A. (2016a). A blinded, randomized, placebo-controlled, dose determination trial of lokivetmab (ZTS-00103289), a canonized, anti-canine IL-31 monoclonal antibody in client owned dogs with atopic dermatitis. *Veterinary Dermatology* 27(6), 478-485.
- Michels G.M., Walsh K.F., Kryda K.A., Mahabir S.P., Walters R.R., Hoevers J.D., Martinon O.M. (2016b). A blind-

- ed, randomized, placebo-controlled trial of the safety of lokivetmab (ZTS-00103289), a caninized anti-canine IL-31 monoclonal antibody in client-owned dogs with atopic dermatitis. *Veterinary Dermatology* 28 (6), 505-515.
- Moyaert H., Van Brussel L., Borowski S., Escalada M., Mahabir S.P., Walters R.R., Stegemann M.R. (2017). A blinded, randomized clinical trial evaluating the efficacy and safety of lokivetmab compared to ciclosporin in client-owned dogs with atopic dermatitis. *Veterinary Dermatology* 28 (6), 593-597.
- Negre A., Bensignor E., Guillot J. (2009). Evidence-based veterinary dermatology: a systemic review of interventions for *Malassezia* dermatitis in dogs. *Veterinary Dermatology* 20, 1-12.
- Nutall T.J., Halliwell R.E.W. (2001). Serum antibodies to *Malassezia* yeasts in canine atopic dermatitis. *Veterinary Dermatology* 12, 327-332.
- Nuttall T.J., Uri M., Halliwell R. (2013). Canine atopic dermatitis – what have we learned? *Veterinary Record* 23, 201-207. 247-251.
- Olivry T., Deboer D.J., Favrot C., Jackson H.A., Mueller R.S., Nutall T., Prélaud P. (2010). Treatment of canine atopic dermatitis: 2010 clinical practice guidelines from the International Task Force on Canine Atopic Dermatitis. *Veterinary Dermatology* 21, 233-248.
- Olivry T., Deboer D.J., Favrot C., Jackson H.A., Mueller R.S., Nutall T., Prélaud P. (2015). Treatment of canine atopic dermatitis: 2015 updated guidelines from the International Committee on Allergic Diseases of Animals (ICADA). *Veterinary Research* 11, 1-15.
- Peterson A.L., Torres S.M.F., Rendahl A., Koch S.N. (2012). Frequency of urinary tract infection in dogs with inflammatory skin disorders treated with ciclosporin alone or in combination with glucocorticoid therapy: a retrospective study. *Veterinary Dermatology* 23, 201-205.
- Saridomichelakis M.N., Olivry T. (2016) An update on the treatment of canine atopic dermatitis. *The Veterinary Journal* 207, 29-37.
- Scott D.W., Miller W.H., Griffin C.E. (2001). Canine atopic disease. In: Muller & Kirk's Small Animal Dermatology. Sixth edition. W.B. Saunders. Philadelphia. PA. USA, 574-601. Quoted by: Saridomichelakis M.N., Olivry T. (2016). An update on the treatment of canine atopic dermatitis. *The Veterinary Journal* 207, 29-37.
- Simpson A.C., Schissler J.R., Rosychuk R.A.W., Moore A.R. (2017). The frequency of urinary tract infection and subclinical bacteriuria in dogs with allergic dermatitis treated with oclacitinib: a prospective study. *Veterinary Dermatology* 28, 485-492.
- Torres S.M.; Diaz S.F.; Noguiera S.A., Jessen C., Polzin D.J., Gilbert S.M., Horne K.L. (2005). Frequency of urinary tract infection among dogs with pruritic disorders receiving long-term glucocorticoid treatment. *Journal of the American Veterinary Medical Association* 227 (2), 239-243.
- Zur G., Ihrke P.J., White S.D., Kass P.H. (2002). Canine atopic dermatitis: a retrospective study of 266 cases examined at the University of California, Davis, 1992-1998. Part I. Clinical features and allergy testing results. *Veterinary Dermatology* 13(2), 89-102.