

General anesthesia for surgical treatment of urethral obstruction in nine goats

Algemene anesthesie voor de chirurgische behandeling van urinewegobstructie bij negen geiten

¹A.J.H.C Michielsens, ¹K. Proost, ²B. Pardon, ²L. De Cremer, ¹S. Schauvliege

¹Department of Surgery and Anesthesiology of Domestic Animals

²Department of Internal Medicine and Clinical Biology of Large Animals

Faculty of Veterinary Medicine, Ghent University, Salisburylaan 133, B-9820 Merelbeke, België

anneleen.michielsen@ugent.be
stijn.schauvliege@ugent.be

ABSTRACT

Nine pygmy goats underwent surgical treatment for obstructive urolithiasis in a period of six months. In two cases, (second) revision surgery was necessary resulting in a total of twelve procedures under general anesthesia. Different anesthetic protocols were applied: analgesia was provided by an opioid (12/12) combined with either benzodiazepine (10/12) or an alpha-2 agonist (2/12). Anesthesia was induced with propofol (10/12) or ketamine (2/12) and maintained with isoflurane (8/12) or sevoflurane (4/12) in oxygen in a semi-closed circle system with continuous monitoring during anesthesia. Minor complications were mild bradycardia (4/12), hypotension (3/12), metabolic acidosis (1/12) and hypothermia (12/12). In four cases, epidural anesthesia was performed; in one of those four cases, severe complications developed (paralysis, 1/4). The goat was euthanized later. Although urethral obstruction increases the risk of general anesthesia, the selection of an appropriate anesthetic protocol, adequate preoperative examination/ preparation and detailed monitoring throughout anesthesia reduced the incidence of severe complications in this case series.

SAMENVATTING

Over een periode van zes maanden werden negen dwerggeiten chirurgisch behandeld voor obstructie van de urinewegen. In twee gevallen was een (tweede) revisie-operatie nodig, wat resulteerde in twaalf procedures onder algemene anesthesie. Verschillende anesthesieprotocollen werden toegepast. Analgesie werd voorzien door middel van een opioïd in combinatie met ofwel benzodiazepine (10/12) of met een alfa-2 agonist (2/12). De anesthesie werd geïnduceerd met propofol (10/12) of ketamine (2/12), waarna deze werd onderhouden met isofluraan (8/12) of sevofluraan (4/12) in zuurstof in een semigesloten cirkelsysteem en onder continue monitoring. Geregistreerde complicaties waren milde bradycardie (4/12), hypotensie (3/12), metabole acidose (1/12) en hypothermie (12/12). In vier gevallen werd door middel van een epidurale anesthesie bijkomende analgesie voorzien, waarbij er zich bij één geit een ernstige complicatie (paralyse, 1/4) ontwikkelde met euthanasie tot gevolg. Hoewel een obstructie van de urinewegen het anesthesierisico verhoogt, werd de kans op ernstige complicaties in de voorliggende casussen vermeden door de keuze van een adequaat anesthesieprotocol, een goed(e) preoperatief (-ve) onderzoek/ voorbereiding en een nauwgezette perioperatieve monitoring.

INTRODUCTION

Urolithiasis, resulting in urethral obstruction, is commonly seen in male small ruminants (Fortier et al., 2004; Kinsley et al., 2013; Hunter et al., 2012; Gazi et al., 2014). The etiology is multifactorial (Gugjoo et al., 2013) and involves both anatomic and dietary factors (Ewoldt et al., 2008). Uroliths are frequently observed in the processus urethralis or in the distal sigmoid flexure, due to the narrow urethral diameter in these areas (Ewoldt et al., 2008). During the formation of uroliths, debris in the urinary tract, mucoproteins and cells form a nidus, which serves as a basis for later precipitation of crystals (Gazi et al., 2014; Videla and van Amstel, 2016). Calcium carbonate, calcium phosphate, struvite or calcium oxalate stones are the most common types in small ruminants (Kinsley et al., 2013; Videla and van Amstel, 2016). Depending on the number and size of the uroliths, (partial) obstruction of the urinary tract can occur (Gazi et al., 2014).

Signs of discomfort, such as abnormal stance, failure to urinate or strangury, vocalization, anorexia, teeth grinding, ventral edema at the level of the abdomen and kicking the abdomen, can be seen, as well as tachycardia and tachypnea (Ermilio and Smith, 2011; Videla and van Amstel, 2016). Deep abdominal palpation of the distended bladder in the caudal abdomen, transabdominal ultrasonography or plain radiography can contribute to achieve a diagnosis (Ermilio and Smith, 2011; Gazi et al., 2014; Videla and van Amstel, 2016).

In an early stage, conservative treatment can be attempted with spasmolytic agents, fluid therapy, medical dissolution of the uroliths by acidification of the urine, cystocentesis, retrograde catheterization and flushing (Hunter et al., 2012; Gazi et al., 2014; Videla and van Amstel, 2016). However, surgical treatment is necessary when medical management is unsuccessful (Ermilio and Smith, 2011). Several surgical procedures have been described (Gugjoo et al., 2013; Kinsley et al., 2013; Gazi et al., 2014; Videla and van Amstel, 2016), either under general anesthesia or under sedation, in combination with a local and/or epidural block (Kinsley et al., 2013; Gazi et al., 2014; Videla and van Amstel, 2016). Typical concerns in (small) ruminant anesthesia are tympany, profuse salivation, regurgitation and aspiration pneumonia. In addition, anesthesia of a patient with urolithiasis can be quite challenging due to the impact on the cardiovascular and respiratory function but also due to electrolyte and acid-base disbalances (George et al., 2007; Freitas et al., 2012). The objective of this retrospective case series was to describe different anesthetic protocols and the occurrence of possible minor and major complications during anesthesia of pygmy goats for obstructive urolithiasis.

Twelve procedures under general anesthesia

In a period of six months (August 2016 – March 2017), nine (pet) goats were admitted to the clinic of the Faculty of Veterinary Medicine (UGhent) with a similar history of abdominal discomfort, apathy and unsuccessful attempts to urinate. After a general clinical examination, venous blood gas analysis, biochemistry, ultrasonographic and radiographic examination, all cases were referred for surgical treatment of urinary tract obstruction (without bladder rupture) under general anesthesia (Tables 1 and 2). Goat 1 underwent three different surgical procedures on separate occasions and goat 8 was operated twice. The surgical procedures included tube cystotomy (Silcoat Foley Catheter, Servoprax GmbH, Wesel, Germany) (three cases) or cystotomy (one case), marsupialization of the bladder (three cases), urethrostomy (two cases), amputation of the processus urethralis (one case), transposition of the penis (one case) and vesiculopreputial anastomosis (one case). The type of surgery was determined depending on the presence or absence of ventral edema at the level of the abdomen, the condition of the urethra and bladder and the preference of the individual surgeon in each case. Two weeks after the initial surgery, the tube cystotomy of patient 1 was obstructed and the decision was made to perform a urethrostomy instead (1B). Three months later, the same goat (1C) (weight loss from 31kg to 21kg over a period of three months) was re-presented at the clinic for persistent urinary problems. A rupture of the urethra was diagnosed, and a third revision surgery (vesiculopreputial anastomosis) was performed. Patient 8 was referred for recurrent symptoms of urinary obstruction eleven days after the initial surgery (urethrostomy (8A)) and a marsupialization of the bladder (8B) was performed during the second surgery.

In all goats, a catheter (Venocan™ Plus IV Catheter, 14G, 2.1 x 50mm, Kruuse, Langeskov, Denmark) was placed in the jugular vein, and antibiotics and nonsteroidal anti-inflammatory drugs (NSAIDs) were administered before anesthesia, except in case 1C, where NSAIDs and antibiotics were administered during surgery (Table 3). Different anesthesia protocols were applied, depending on the individual anesthetist's preference and the patient's condition (Table 3). In all cases, premedication consisted of an opioid, methadone (Comfortan 10 mg mL⁻¹, Eurovet Animal Health BV, AE Bladel, the Netherlands) or morphine (Morfine HCL 10 mg mL⁻¹, Laboratoires Sterop NV, Brussels, Belgium), combined with either midazolam (Midazolam B Braun 5 mg mL⁻¹, Braun, Meslunger, Germany) (seven cases), diazepam (Ziapam 5 mg mL⁻¹, Ecuphar, Oostkamp, Belgium) (three cases) or xylazine (Xyl-M 2%, VMD, Arendonk, Belgium) (goats 3 and 7). Induction of anesthesia was performed with

Table 1. Preoperative venous blood values in nine goats undergoing surgical treatment of urolithiasis under general anesthesia (Jackson and Cockcroft, 2002).

	Reference	Goat 1A	Goat 1B	Goat 1C	Goat 2	Goat 3	Goat 4	Goat 5	Goat 6	Goat 7	Goat 8A	Goat 8B	Goat 9
Glucose (g dL ⁻¹)	<i>40-60</i>	149	x	x	259	129	107	x	97	160	263	208	101
pH (mmHg)	<i>7.35-7.45</i>	7.49	x	x	7.389	7.45	7.428	x	7.54	7.515	7.35	7.435	7.165
pCO ₂ (mmHg)	<i>35-45</i>	32.4	x	x	42.2	31.1	34	x	38.2	26.8	33.4	34.7	33.2
HCO ₃ ⁻ (mmol L ⁻¹)	<i>25-30</i>	24	x	x	24.9	20.9	22	x	31.9	21.1	18.2	22.8	11.7
Packed cell volume (%)	<i>25-35</i>	40	x	x	37	35	25	x	35	44	43	36	42
B.E. (mEq L ⁻¹)	<i>-5 +5</i>	1.2	x	x	-0.1	-2.3	-2.0	x	8.8	-0.5	-6.3	-1	-15.8
Na ⁺ (mmol L ⁻¹)	<i>135-156</i>	142	x	x	142.5	143.6	152.3	x	140.2	143	133.1	145.4	142.6
K ⁺ (mmol L ⁻¹)	<i>3.4-6.1</i>	4.38	x	x	3.92	4.61	3.19	x	4.41	4.06	4.22	3.63	4.61
Ca ²⁺ (mmol L ⁻¹)	<i>2.3-2.9</i>	1.08	x	x	1.1	0.96	0.93	x	0.96	1.08	0.97	1.15	1.04
Cl ⁻ (mmol L ⁻¹)	<i>98-110</i>	104	x	x	98	107	112	x	96	103	89	104	107
Urea (mmol L ⁻¹)	<i>4-8.6</i>	6.9	13.1	x	41.1	18.3	22.1	38.8	19.3	x	46	13.3	3.5
Creatinine (μmol L ⁻¹)	<i>54-123</i>	89	382	x	820	210	183	571	298	x	x	98	68

X= not performed or saved. The different patients are referred by number (1 to 9). The letters A to C refer to the different times the same patient underwent surgical treatment under general anesthesia. Aberration from the reference values are clarified in bolt. Reference values are clarified in italics.

propofol administered intravenously (IV) (Propo Vet Multidose 10 mg mL⁻¹, Zoetis Belgium SA, Louvain-La-Neuve, Belgium) (ten cases) or ketamine administered IV (Ketamidol 100 mg mL⁻¹, Richter Pharma AG, Wels, Austria) (goats 6 and 7) (Table 3). With the aid of a laryngoscope, endotracheal intubation was performed in each case with the animal in a sternal position. Intubation was smooth in all but one case (case 6), where several attempts were needed, due to poor visualization of the larynx and swallowing attempts. The diameter of the endotracheal tube (Kendal Curity, Minneapolis, USA) depended on the size of the patient. In 4/12 patients, an epidural injection was performed in sternal recumbency, with 0.1 mg kg⁻¹ morphine and 0.5 mg kg⁻¹ bupivacaine hydrochloride (Marcaïne 0.5%, Aspen Pharma Trading Limited, Dublin, Ireland) (Spinal needle Quicke, 22G/0.7 mm x 65 mm, Temena SAS, France). Anesthesia was maintained with isoflurane (IsoFlo, Aesica Queenborough Limited, Kent, UK) (eight cases) or sevoflurane (SevoFlo, Zoetis Belgium SA, Louvain-la-Neuve, Belgium) (four cases) in oxygen in a semi-closed circle system (Dräger-AV 1, Drägerwerk AG Lübeck, Germany). The animals breathed spontaneously (7/12) or were mechanically (5/12) ventilated, depending on the spontaneous respiratory rate and results of the arterial blood gas analysis during anesthesia (Table 2). Lactated Ringer's solution (Vetivex 5000 mL, Dechra Limited, North Yorkshire, UK) was administered at a low rate (1 mL kg⁻¹ h⁻¹) until urine could be drained from the bladder. Patients were monitored thoroughly during anesthesia using standard monitoring equipment (Table 2; Figures 1, 2 and 3). Monitoring of the patients included electrocardiography (ECG), pulse oximetry, measurement of the body temperature and monitoring of invasive blood pressure obtained through the placement of a catheter (Venocan™ Plus IV Catheter, 22G, 0.9 x 25mm, Langeskov, Denmark) in the auricular artery (Datex-Ohmeda S/5, Helsinki,

Finland) that was used in addition to collect arterial blood samples (Radiometer ABL5, Denmark, Copenhagen) (Table 2). Furthermore, inspired and expired concentrations of oxygen, carbon dioxide (CO₂) and the volatile anesthetic agent (sevo- or isoflurane) were recorded (Datex-Ohmeda DivGE Healthcare Finland OY, Helsinki, Finland).

Only minor complications were noted during maintenance of anesthesia (Table 4). In case 1B, metabolic acidosis was diagnosed in an arterial blood sample taken 15 minutes after induction of anesthesia, which was treated with 8.4 g of sodium bicarbonate over 30 minutes (Bicarbonate de Sodium 8.4% B521, Melsungen, Germany) (Table 2).

Slight bradycardia was observed in cases 1C, 2 and 9, but the arterial blood pressure remained stable (Figures 1 and 2). In case 7, more pronounced bradycardia was noted: the heart rate in this goat varied around 60 beats per minute (bpm) throughout the anesthesia, but dropped to 42 bpm 30 minutes after induction of anesthesia (Figure 2). Simultaneously, the mean arterial pressure (MAP) abruptly decreased from 60 to 30 mmHg (Figure 1). The end-tidal concentration of sevoflurane was decreased to 1.3%, a bolus of 10 mL kg⁻¹ Lactated Ringer's solution (Baxter, Lessines, Belgium) was administered over 10 minutes (Baxter Colleague, Baxter Healthcare SA, Zürich, Switzerland) and a constant rate infusion (CRI) of dobutamine hydrochloride (Dobutrexmylan, Synthon BV, Nijmegen, the Netherlands) was started at a rate of 0.5 μg kg⁻¹ minute⁻¹. The MAP increased from 30 to 70 mmHg and the heart rate from 45 to 60 bpm (Figures 1 and 2). Fifteen minutes later, slight swallowing and positive palpebral reflexes were noted. The end-tidal sevoflurane concentration was again increased and adjusted according to the responses in arterial blood pressure and heart rate. In goat 3, hypotension (MAP 45 mmHg) was observed at the start of anesthesia, with a normal heart rate of 85 beats per minute (Figures 1

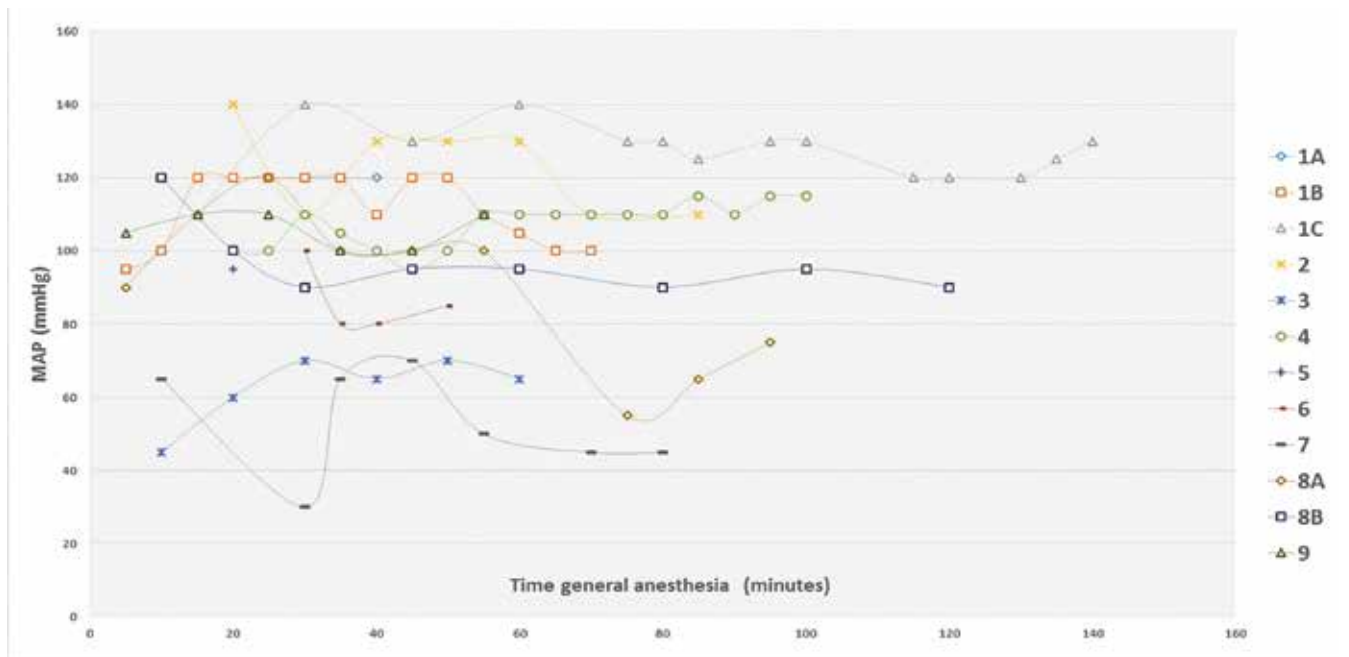


Figure 1. Mean arterial blood pressure (MAP) in mmHg of the patients during anesthesia for surgical treatment of urolithiasis. Hypotension (MAP < 65 mmHg) was observed in three cases (3, 7, 8A) during the anesthesia.

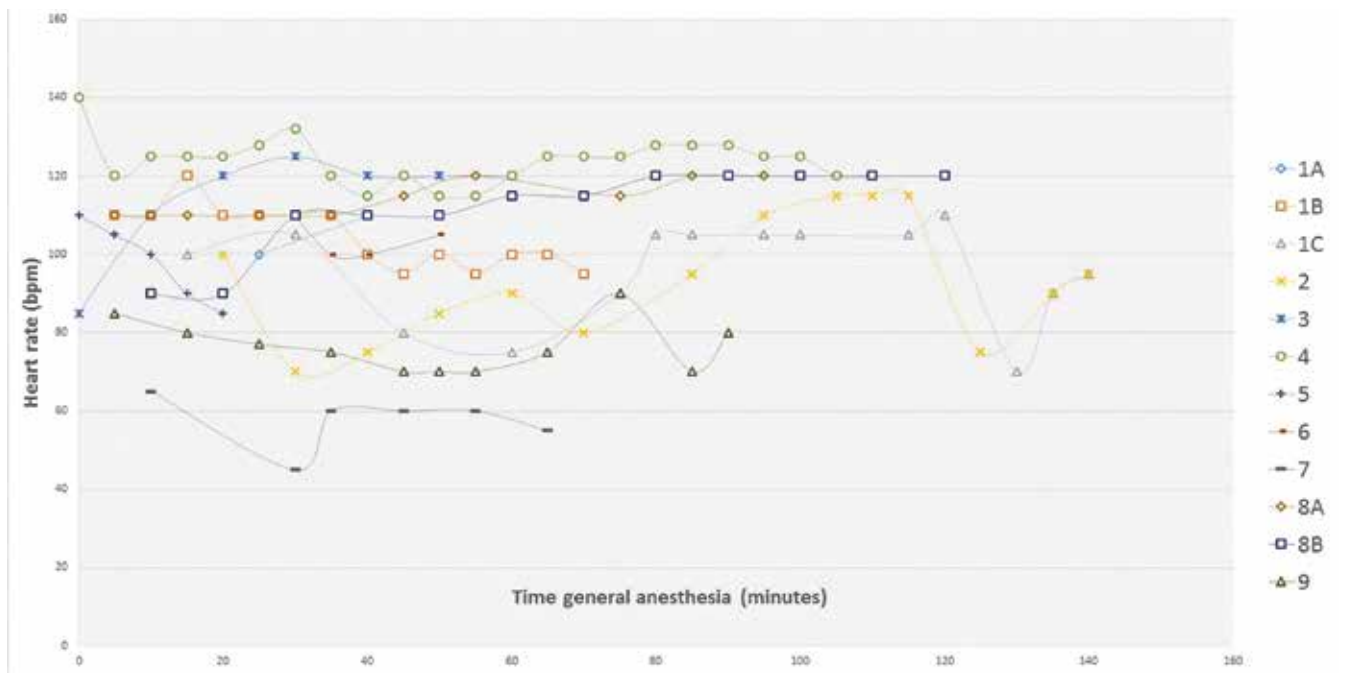


Figure 2. Graphic presentation of the heart rate (beats per minute, bpm) of patients during anesthesia for surgical treatment of urolithiasis. Mild bradycardia (heart rate < 70 to 90 bpm) was observed in three cases (1C, 2 and 9) and more pronounced bradycardia was noted in case 7.

and 2). A bolus of 10 mL kg⁻¹ Lactated Ringer’s solution was administered over 10 minutes (Baxter Colleague, Baxter Healthcare SA, Zürich, Switzerland), and a CRI of dobutamine hydrochloride was started at a rate of 2 µg kg minute⁻¹. The MAP increased to 70 mmHg and the pulse rate increased to 120 beats per minute (Figure 1). Administration of dobutamine was discontinued after 20 minutes. Heart rate and arterial blood pressure remained stable during the remaining time of the anesthesia (Figures 1 and 2). In case 8A,

a bolus of 1 mg kg⁻¹ ketamine was administered IV because of movement of the patient at the start of the surgery. Immediately thereafter, a drop in mean arterial pressure (MAP) from 100 to 55 mmHg was noted, which spontaneously increased again to 65 and 70 mmHg, respectively 5 and 10 minutes later (Figure 1).

After extubation, the animals were placed in a clean stable with a heating lamp until normothermia was reached (all goats had developed hypothermia during anesthesia) (Table 4). The recovery of the pa-

Table 2. Arterial blood gas values from an arterial blood sample taken from the auricular artery (Radiometer ABL 5, Denmark, Copenhagen) analysis per-operative of goats undergoing surgical treatment of urolithiasis in general anesthesia. In case 1B samples were taken at 15, 35 and 50 minutes after the start of anesthesia. During anesthesia, a correction for the low pH and bicarbonate was performed by administrating sodium bicarbonate (Bicarbonate de Sodium 8.4% B521, Germany, Meslungen). Body temperature (°C) at the end of anesthesia and the total anesthesia time in minutes.

	1A	1B (#=3)			1C (#=2)		2 3 (#=1)	4 (#=2)		5	6	7	8A	8B	9 (#=1)
Time of sample after induction (minutes)		15'	35'	50'	45'	105'		25'	46'	81'					
pH (mmHg)	x	7.27	7.33	7.35	7.38	7.36	x	7.31	7.21	7.26	7.38	x	x	x	x
pCO ₂ (mmHg)	x	37	39	37	47	28	x	50	50	50	35	x	x	x	x
pO ₂ (mmHg)	x	421	440	443	434	216	x	98	241	158	364	x	x	x	x
Saturation (%)	x	100	100	100	100	100	x	97	100	99	100	x	x	x	x
HCO ₃ ⁻ (mmol L ⁻¹)	x	17	20	20	27	20	x	25	22	22	20	x	x	x	x
SBC (mmol L ⁻¹)	x	17	20	21	26	14	x	23	20	20	21	x	x	x	x
tCO ₂ (Vol%)	x	40	47	48	64	23	x	59	52	52	47	x	x	x	x
ABE (mmol L ⁻¹)	x	-9	-5	-4	2	-14	x	-2	-5	-6	-4	x	x	x	x
SBE (mmol L ⁻¹)	x	-9	-5	-4	3	-15	x	-1	-4	-4	-4	x	x	x	x
Packed cell volume (%)	x	17	x	x	x	25	x	30	16	18	32	x	x	x	x
Ventilation?	No	No			Yes		Yes	No	No		No	Yes	Yes	No	No
Duration of anesthesia (minutes)	90	70			140		150	70	110		25	50	100	110	125
Rectale temperature (°C)	x	35.5			x		x	37	35.9		38	37.3	37.5	x	37.3
															34

X = not performed; # = total amount of blood gases analysed. The different patients are referred by number (1 to 9). The letters A to C refer to the different times the same patient underwent surgical treatment under general anesthesia. Aberration from the reference values are clarified in bolt.

tients was generally smooth, although after the first surgical procedure, goat 1 was not able to stand during the first six hours after epidural injection. After the surgery, case 8B was unable to stand. A supportive treatment was started, consisting of an infusion of crystalloids, administration of meloxicam (0.5 mg kg⁻¹ subcutaneously (S.C.)) on day 0, 2 and 4 and a single dose of 0.1 mg kg⁻¹ morphine intramuscularly (IM) on the first postoperative day. Because the animal was still unable to stand with signs of complete paralysis and absence of pain sensation on the second postoperative day, a single dose of 0.5 mg kg⁻¹ of dexamethasone was administered IV. From the third postoperative day onwards, a treatment with vitamin B1 (10 mg kg⁻¹) was started and physiotherapy was applied at four-hour intervals. Because no signs of improvement were seen after nine days, further examinations were performed (radiography, myelography and computed tomography (CT)). On radiography of the abdomen (right-left and ventral-dorsal view), mineral opacities caudal to the urinary bladder and cranial to the pubis were observed. On myelography, no anomalies were seen. On CT, a bony defect with mild displacement of a fragment was visible centrally at the caudo-dorsal endplate of L7, suggestive for osteochondrosis dissecans. In the caudal abdomen and in the surroundings of the penis, reactive tissue was seen, probably due to inflammation from the surgery. In the cranial mediastinum, a cystic lesion was noted. Bilaterally in the adductor muscles, more pronounced right than left, some irregular hypo-attenuated lesions were visible ventrally to the ischium. This was proba-

bly due to myositis, edema or contusion. The presence of uroliths in the bladder and in the penile urethra, already observed on radiography, were also confirmed. No abnormalities were found at the level of the spinal cord and due to the lack of improvement, after consideration with the owners, the decision was made to euthanize the goat, using 60 mg kg⁻¹ sodium-pentobarbital IV. (Release, Garbsen, Germany). No autopsy was performed, according to the owner's wishes.

After surgery, the goats remained hospitalized and the treatment with antibiotics and NSAIDs was continued (Table 3). The choice of antibiotics depended on the type of surgery. Meloxicam 0.5 mg kg⁻¹ (Rheumocam 20mg mL⁻¹, Boehringer Ingelheim, Ingelheim, Germany), flunixin meglumine 1.1 mg kg⁻¹ (Emdofluxin 50, Emdoka BVBA, Sint-Niklaas, Belgium) or ketoprofen 2 mg kg⁻¹ (Ketofen 10%, Merial Belgium NV, Diegem, Belgium) were used as NSAIDs, the choice depending on the clinician's preference. Morphine 0.1 mg kg⁻¹ was administered intramuscularly when the patient showed symptoms of pain (4 out of 12). The scoring of pain was done subjectively without the use of a pain scale by the treating veterinarian. All patients received 1 g kg⁻¹ ammonium chloride (NH₄⁺) orally once a day (magisterial preparation). Propylene glycol 0.5 mL kg⁻¹ (Propylenglycol, Fraver Laboratoria, Belgium) was administered orally once a day in obese patients, to reduce the risk for Fatty Liver Syndrome. In 6/12 cases, vitamin B1 (Thiamine B1, magisterial preparation) 10 mg kg⁻¹ was given orally twice a day to support the nervous system and in case the patients were

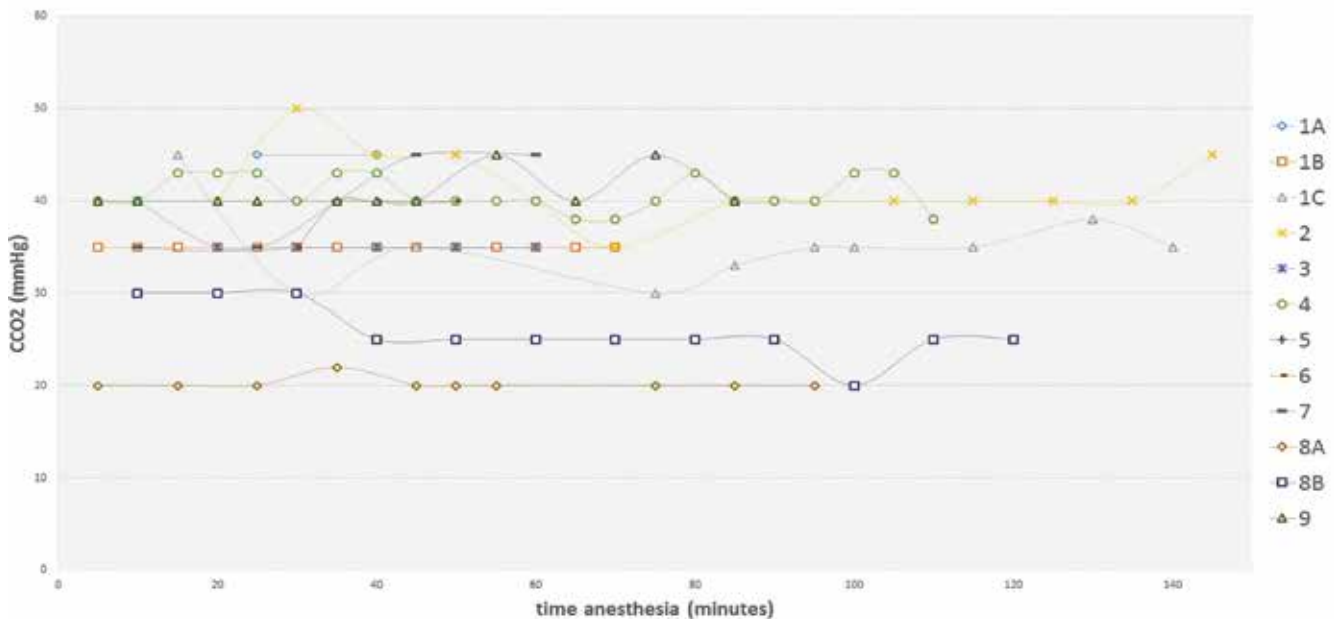


Figure 3. End tidal CO₂ monitoring (mmHg) of the patients undergoing surgical treatment for urolithiasis. The end tidal CO₂ concentration was used to determine the decision-making in the adaptation of the patient's (mechanical) ventilation.

not eating. The length of treatment with vitamin B1 and propylene glycol depended on the clinical improvement of the patient. During the first days after surgery, intravenous crystalloids were administered for general support and adjusted as needed based on measurement of the packed cell volume, kidney values and electrolyte concentrations in venous blood samples. Bethanecholchloride (Myocholin-Glenwood 10 mg, Glenwood GmbH, München, Germany) was administered orally at 0.29 mg kg⁻¹ in case 7 due to bladder atony postoperatively. In case 3, furosemide 0.5 mg kg⁻¹ (Dimazon 5%, Intervet International BV, Boxmeer, the Netherlands) was administered once because of a high urea (24 mmol L⁻¹) and creatinin (435 µmol L⁻¹) concentration.

DISCUSSION

General anesthesia of (small) ruminants can be challenging because of the anatomical and physiological differences compared to other species (Taylor, 1991; Lin, 2015; Riebold, 2015). Tympany, profuse salivation, regurgitation and aspiration pneumonia are some typical concerns in animals with multiple stomachs (Taylor, 1991). Preanesthetic starvation (12 to 24 hours) and water restriction (6 to 12 hours) can reduce the risk of ruminal tympany, regurgitation and aspiration during anesthesia (Ewing, 1990; Taylor, 1991; Galatos, 2011; Dziki, 2013; Lin, 2015). Unfortunately, starvation prior to anesthesia is not an option in case of emergency procedures (Carroll and Hartsfield, 1996; Riebold, 2015). Endotracheal intubation with sufficient cuffing of the tube is essential

to avoid (aspiration)pneumonia in ruminants when regurgitation or salivation would occur (Galatos, 2011; Taylor, 1991). The placement of a stomach tube could be useful in cases with long anesthetic procedures to release ruminal gas (Ewing, 1990; Taylor, 1991) and avoid a tympanic patient, which might compromise the cardiovascular and respiratory systems (Taylor, 1991). The risk of anesthesia is further increased in patients suffering from urolithiasis with obstruction of the urinary tract (Freitas et al., 2012).

In case of urinary tract obstruction, electrolyte imbalances can rapidly occur (Freitas et al., 2012; Ermilio and Smith, 2011) and progress to severe acid-base disbalances (George et al., 2007; Freitas et al., 2012). These abnormalities include metabolic acidosis, hyponatremia, hyperkalemia, azotemia and hyperphosphatemia (George et al., 2007; Ermilio and Smith, 2011; Videla and van Amstel, 2016). Electrolyte imbalances must be corrected before anesthesia (Ermilio and Smith, 2011), e.g. hyperkalemia (> 6 mmol L⁻¹) has important effects on the cardiac function, with the risk of fatal arrhythmias during anesthesia (Ewoldt et al., 2006; Videla and van Amstel, 2016). However, in contrast to other species, the concentrations of potassium and phosphate can remain within normal values in ruminants with urinary tract obstruction (Ewoldt et al., 2006; George et al., 2007). All the goats in the present case series were normokalemic before the induction of anesthesia (Table 1). The best-known biochemical parameter for goats with urolithiasis is azotemia (George et al., 2007). Blood urea nitrogen and creatinin levels should therefore always be assessed (Videla and van Amstel, 2016). In all patients, urea and creatinin values were indeed in-

Table 3. Anesthesia protocols used in nine goats undergoing surgical treatment of urolithiasis under general anesthesia.

	Surgery	Position	Premedication (IV)	Induction (IV)	ETT	Epidural	Ventilation	NSAID and antibiotics	Remarks
Goat 1A 33 kg 4y MC	Tube cystotomy	Dorsal	0.1 mg kg ⁻¹ Methadone 0.3 mg kg ⁻¹ Midazolam	3 mg kg ⁻¹ Propofol	8	Yes	S	0.5 mg kg ⁻¹ Meloxicam 45 mg kg ⁻¹ Neomycin	<i>Postoperative</i> Prolonged recovery + unable to stand for several hours (6 hours). Ammonium chloride 1 g 10 kg ⁻¹ PO
Goat 1B 31 kg 4 Y MC	Urethrostomy	Sternal	0.4 mg kg ⁻¹ Midazolam 0.1 mg kg ⁻¹ Morphine	4 mg kg ⁻¹ Propofol	8	No	S	0.5 mg kg ⁻¹ Meloxicam 45 mg kg ⁻¹ Neomycin	<i>Anesthesia</i> Correction pH with sodium bicarbonate <i>Postoperative</i> 0.11 mg kg ⁻¹ Ketamine during surgery Ammonium chloride 1 g 10 kg ⁻¹ PO
Goat 1C 21 kg 4 Y MC	Vesiculopreputial anastomosis	Dorsal	0.2 mg kg ⁻¹ Morphine 0.2 mg kg ⁻¹ Diazepam	3.8 mg kg ⁻¹ Propofol	8	No	AC TV = 200 mL PIP: 6-8 F: 14-26 PEEP: 1-8	0.5 mg kg ⁻¹ Meloxicam 1.1 mg kg ⁻¹ Sodium-ceftiofur during surgery 45 mg kg ⁻¹ Neomycin postoperative	<i>Postoperative</i> Ammonium chloride 1 g 10 kg ⁻¹ PO 0.1 mg kg ⁻¹ Morphine (I.M. Day 1)
Goat 2 40 kg 6 Y MC	Tube cystotomy	Dorsal	0.1 mg kg ⁻¹ Methadone 0.3 mg kg ⁻¹ Midazolam	2.6 mg kg ⁻¹ Propofol	7	Yes	C	1.1 mg kg ⁻¹ Flunixin meglumine 13.4 mg kg ⁻¹ Sulfadoxine + 2.7 mg kg ⁻¹ Trimethoprim	<i>Postoperative</i> 0.1 mg kg ⁻¹ Morphine (I.M. Day 1) Ammonium chloride 1 g 10 kg ⁻¹ PO 5d Propylene glycol PO 5d 0.5 mL kg ⁻¹ Infusion 4d
Goat 3 25 kg 4 Y MC	Right sided para-median marsupialization	Dorsal	0.06 mg kg ⁻¹ Xylazine 0.1 mg kg ⁻¹ Morphine	4 mg kg ⁻¹ Propofol	5.5	Yes	S	0.5 mg kg ⁻¹ Meloxicam 45 mg kg ⁻¹ Neomycin	<i>Anesthesia</i> 12 mgh ⁻¹ Dobutamine + bolus fluids 10 mL kg ⁻¹ due to hypotension <i>Postoperative</i> Furosemide 0.5 mg kg ⁻¹ Ammonium chloride 1 g 10 kg ⁻¹ P.O.
Goat 4 13 kg ? Y M	Cystotomy	Dorsal	0.1 mg kg ⁻¹ Midazolam 0.1 mg kg ⁻¹ Methadone	3 mg kg ⁻¹ Propofol	6	No	S	1.1 mg kg ⁻¹ Flunixin meglumine 7 mg kg ⁻¹ Amoxicilline	<i>Postoperative</i> Ammonium chloride 1 g 10 kg ⁻¹ PO 5d Propylene glycol PO 0.5 mL kg ⁻¹ Vitamine B1 PO 1 gram 100 kg ⁻¹
Goat 5 43 kg ? Y M	Amputation processus urethralis	Dorsal	0.1 mg kg ⁻¹ Morphine 0.3 mg kg ⁻¹ Diazepam	5 mg kg ⁻¹ P Propofol	8	No	S	1.1 mg kg ⁻¹ Flunixin meglumine 13.4 mg kg ⁻¹ Sulfadiazine + 2.7 mg kg ⁻¹ trimethoprim	<i>Postoperative</i> Ammonium chloride 1 g 10 kg ⁻¹ PO 3d
Goat 6 40 kg 3 Y MC	Transposition of the penis	Dorsal	0.2 mg kg ⁻¹ Diazepam 0.1 mg kg ⁻¹ Methadone	1.75 mg kg ⁻¹ Ketamine + 2x 0.87 mg kg ⁻¹ Ketamine	8	No	AC TV= 350 PIP= 19-21 Freq= 8-10	2 mg kg ⁻¹ Ketoprofen 45 mg kg ⁻¹ Neomycin	<i>Anesthesia</i> Difficult intubation <i>Postoperative</i> Ammonium chloride 1 g 10 kg ⁻¹ PO 5d 0.1 mg kg ⁻¹ Morphine (I.M. Day 1 + 2) Propylene glycol PO 0.5mL kg ⁻¹ Vitamine B1 PO 1 g 100 kg ⁻¹
Goat 7 35 kg 4 Y MC	Tube cystotomy	Dorsal	0.1 mg kg ⁻¹ Methadone 0.06 mg kg ⁻¹ Xylazine	1.7 mg kg ⁻¹ Ketamine	8	No	AC TV= 250 PIP= 17-20 Freq= 17	Preoperative 2 mg kg ⁻¹ Ketoprofen Postoperative 1.1 mg kg ⁻¹ Flunixin meglumine 45 mg kg ⁻¹ Neomycin 3 days after change to 13.4 mg kg ⁻¹ Sulfadiazine + 2.7 mg kg ⁻¹ Trimethoprim	<i>Postoperative</i> Ammonium chloride 1 g 10 kg ⁻¹ PO Propylene glycol P.O. 0.5mL kg ⁻¹ Vitamine B1 PO 1 g 100 kg ⁻¹ Myocholine 0.29 mg kg ⁻¹ P.O.
Goat 8A 40 kg 11 Y MC	Urethrostomy	Dorsal	0.3 mg kg ⁻¹ Midazolam 0.1 mg kg ⁻¹ Morphine	3 mg kg ⁻¹ Propofol	10	No	S	0.5 mg kg ⁻¹ Meloxicam 7 mg kg ⁻¹ Amoxicillin	<i>Anesthesia</i> Local infusion of procaine without adrenaline 1 mg kg ⁻¹ ketamine IV <i>Postoperative</i> Ammonium chloride 1 g 10 kg ⁻¹ PO Propylene glycol PO 0.5 mL kg ⁻¹ Vitamin B1 PO 1 g 100 kg ⁻¹
Goat 8B 36 kg 11 Y MC	Marsupialization	Dorsal	0.2 mg kg ⁻¹ Midazolam 0.1 mg kg ⁻¹ Methadone	2.5 mg kg ⁻¹ Propofol	10	Yes	S	0.5 mg kg ⁻¹ Meloxicam 2 days postoperative 45 mg kg ⁻¹ Neomycin 0.5 mg kg ⁻¹ Dexamethasone IV Day 2 postoperative	<i>Postoperative</i> Unable to stand after epidurale: further examination RX, myelogram and CT followed by euthanasia. Morphine 0,1 mg kg ⁻¹ IM day 1+ 2 postoperative Ammonium chloride 1 g 10 kg ⁻¹ PO Propylene glycol PO 0.5 mL kg Vitamin B1 PO 1 g 100 kg ⁻¹
Case 9 34 kg 4 Y MC	Marsupialization	Dorsal	0.3 mg kg ⁻¹ Midazolam 0.1 mg kg ⁻¹ Morphine	2.75 mg kg ⁻¹ Propofol	7.5	No	AC TV= 400 PIP= 11-15 Freq=10-15	0.5 mg kg ⁻¹ Meloxicam 45 mg kg ⁻¹ Neomycin	<i>Postoperative</i> Ammonium chloride 1 g 10 kg ⁻¹ PO Vitamin B1 PO 1 g 100 kg ⁻¹

Abbreviations: PO = per os, IM = intramuscular, TV= tidal volume (mL), PIP= peak inspiratory pressure (cmH₂O), PEEP= positive end expiratory pressure (cmH₂O), F= frequency (breaths per minute), S= spontaneously, AC= assisted-controlled ventilation, C= controlled ventilation, ETT = endotracheal tube (internal diameter in mm), kg= kilograms, Y= years, MC= male castrated.

creased before surgery and gradually decreased in the postoperative period (Table 1).

After thorough examination and correction of electrolyte disorders, an anesthetic protocol may be chosen (Riebold, 2015). In food producing animals, national legislation must be taken into account when choosing the anesthetic protocol. Although minor surgery in goats can often be performed under sedation, usually combined with loco-regional or epidural anesthesia (Galatos, 2011; Taylor, 1991), more invasive surgery warrants the use of general anesthesia. The choice of anesthetic drugs must be well considered, since the excretion of drugs may occur through the kidneys, both directly and indirectly (Freitas et al., 2012). Most goats (10 out of 12) in this case series were premedicated with an opioid, methadone (6/12) or morphine (5/12) in combination with a benzodiazepine, diazepam (3/10) or midazolam (7/10) (Table 2). The choice between morphine or methadone and diazepam or midazolam was made on the preference of the anesthesiologist or medication available in stock. Opioids are metabolized by the liver while their metabolites, which are water soluble, are mostly excreted by urine and partially in the feces by biliary secretion (Kukanich and Wiese, 2015). Benzodiazepines are metabolized in the liver by reduction or glucuronide conjugation and later excreted by the urine (Posner and Burns, 2009). Benzodiazepines are mild sedatives, with anxiolytic but no analgesic effects (Galatos, 2011). For this reason, they are often combined with opioids during premedication. Their effects on the cardiovascular and respiratory systems are minimal compared to xylazine and are therefore the choice of preference in cases with urethral obstruction (Valverde and Doherty, 2008; Galatos, 2011). Although it has been stated that hypoxemia may occur due to a decrease in ventilation, this was not observed in this case series (Galatos, 2011). Diazepam has more tissue irritating properties and it is therefore not advised to administer the drug intramuscularly, in contrast to midazolam, which is water soluble (Galatos, 2011). Injection of benzodiazepines IV should be performed slowly to avoid excitation (Valverde and Doherty, 2008; Galatos, 2011). In this case series, no excitation was noticed after administration of benzodiazepines IV. Two goats however were premedicated with xylazine, a frequently used α_2 -adrenoreceptor agonist, with potent sedative and some analgesic and muscle relaxant effects (Galatos, 2011; Lin, 2015). The response to the α_2 -adrenoreceptor agonists is very variable between breeds and even differs individually (Valverde and Doherty, 2008; Riebold, 2015). Side effects seen after administration of an α_2 -adrenoreceptor agonist are marked salivation (Kokkonen and Eriksson, 1987), respiratory depression, hypercapnia, hypoxemia, bradycardia, initial hypertension followed by hypotension and an increase in urine production in combination with hyperglycemia and hypoin-

linemia (Ewing, 1990; Ermilio and Smith, 2011; Galatos, 2011; Riebold, 2015). Therefore, the use of α_2 -adrenoreceptor agonists in animals with cardiopulmonary disease, hypovolemia or urinary tract obstruction must be avoided if possible (Ewing, 1990; Galatos, 2011). Nevertheless, in this cases series, xylazine was used in the premedication of cases 3 and 7, because there was only a partial obstruction of the urethra, with suspicion of bladder atony in case 3. In the authors' opinion, avoiding the use of α_2 -agonists would have been more appropriate. Indeed, during anesthesia of both cases, marked salivation, hypotension, as well as bradycardia and hypoventilation (necessitating mechanical ventilation) were observed (Figure 1). Finally, the use of acepromazine ($0.05 - 0.1 \text{ mg kg}^{-1}$) could have been considered (Taylor, 1991; Carroll and Hartsfield, 1996; Riebold, 2015), but this drug is not frequently used in small ruminants (Galatos, 2011). The onset of action is quite slow, and the level of sedation is less profound (Valverde and Doherty, 2008), while the vasodilatory effect may result in hypotension and hypothermia. For these reasons, acepromazine was not used during premedication in the present case series.

Induction of anesthesia was either performed with propofol or ketamine. In one of the goats, in which ketamine had been used, endotracheal intubation was quite challenging. This goat had been premedicated with a combination of diazepam and methadone. Prassinis et al. (2005) studied the comparison of propofol, ketamine and thiopental as induction agent in goats and reported difficult intubation in some goats receiving ketamine as induction agent. In the authors' experience, endotracheal intubation of small ruminants is indeed more difficult after induction with ketamine. These observations about the difficulties to intubate can be explained by the fact that laryngeal and pharyngeal reflexes may still be present after an induction with ketamine (Clarke et al., 2014).

During maintenance of anesthesia, hypotension, MAP below 65 mmHg, was noted in three cases (Clarke et al., 2014) (Table 4). In two of these (case 3 and 7), xylazine had been administered during premedication. One of the potential side effects of an α_2 -agonist is indeed hypotension (Ewing, 1990; Ermilio and Smith, 2011; Galatos, 2011; Riebold, 2015). Hypotension can also appear as a consequence of epidural anesthesia (Borer-Weir K., 2014), which could also explain the hypotension noted in case 3. This can be explained by either sympathetic blockage or cardiovascular depression caused by the local anesthetic, or by the increase in epidural pressure during the injection. Therefore, epidural injections should be avoided in cardiovascular instable patients (Borer-Weir, 2014). To address the hypotension, in both cases, the concentration of the inhalation agent was reduced, since volatile anesthetics cause a dose-dependent decrease in blood pressure (Clarke et al., 2014, Steffey

Table 4. Frequency of complications during general anesthesia of goats undergoing surgery for urolithiasis.

Complication	Frequency (%)
Hypothermia	100% (12/12)
Bradycardia	33% (4/12)
Complications after epidural	25% (1/4)
Hypotension	25% (3/12)
Metabolic acidosis	8% (1/12)

et al., 2015; Riebold, 2015). Further treatment may include a bolus of crystalloids or the administration of inotropes or vasopressors. In this case series, a bolus of crystalloids was administered over 10 minutes, and dobutamine hydrochloride was infused at a constant rate of $2 \mu\text{g kg minute}^{-1}$ (case 3) and $0.5 \mu\text{g kg minute}^{-1}$ (case 7). In both cases, a significant improvement of the MAP was obtained. Clarke et al. (2014) described a constant rate infusion of $5\text{--}7 \mu\text{g kg minute}^{-1}$ of dobutamine or dopamine. Ephedrine ($0.02\text{--}0.06 \text{ mg kg}^{-1}$ I.V.) could have been used as an alternative for dobutamine to increase cardiac contractility and systemic vascular resistance (Riebold, 2015). Calcium-borogluconate can be useful in cases with hyperkalemia and increase cardiac contractility, but can cause bradycardia (Riebold, 2015) and was therefore not the preferred choice in this case series.

The normal heart rate in goats varies from 70 to 90 beats per minute (Jackson and Cockcroft, 2002). Bradycardia was observed in four cases (Table 4). In case 7, xylazine, which is known to cause bradycardia, had been administered during premedication. During the period of the pronounced bradycardia, the plane of anesthesia was considered deep, which is known to contribute to bradycardia (Galatos, 2011). In the other three cases, the arterial blood pressure remained stable and above 70 mmHg, so no interventions were undertaken.

Hypoventilation, hypercapnia and hypoxemia are commonly seen during anesthesia of ruminants (Tagawa et al., 1994; Carroll and Hartsfield, 1996) and are often caused by anesthetic agents (Lin, 2015). Orotracheal intubation is advised to protect the airways and to allow proper ventilation and supplementation of additional oxygen (Carroll and Hartsfield, 1996). Arterial blood gas analysis was not performed in all cases, but in case 3, a relatively pronounced difference between paCO_2 (50 mmHg) and end tidal CO_2 (average 39 mmHg) was found (Figure 3). In case 3, the patient was kept in spontaneous ventilation during the entire procedure. The difference in PaO_2 and end tidal CO_2 was caused by alveolar dead space. In case 1B, the first arterial blood sample during anesthesia revealed a low pH, Base Excess (BE) and bicarbonate concentration, suggesting metabolic acidosis. These values were corrected by administration of sodium bicarbonate. Although salivation causes large losses of bicarbonate in ruminants, bicarbonate rarely needs

to be administered during anesthesia (Riebold, 2015). Also, metabolic acidosis is rarely seen in case of obstructive urolithiasis. The most common causes are the absorption of D-lactate from the gastrointestinal tract and sodium loss in case of secretory diarrhea. Sepsis or other causes of systemic shock can also lead to metabolic acidosis due to lactate accumulation, as a result of poor tissue perfusion. This last cause may be the reason for the metabolic acidosis seen in this case due to revision a few days after the first surgery (Walz and Taylor, 2012). However, lactate was not determined and other venous blood values were not recorded before the revision surgery (Table 1).

During recovery, all patients suffered from hypothermia (Table 4). The normal body temperature of goats varies between 39 and 40°C (Jackson and Cockcroft, 2002). During anesthesia of newborns or long procedures (Taylor, 1991), monitoring of the body temperature is important as hypothermia commonly occurs (Lin, 2015; Riebold, 2015). In the present case series, a warming device could have been used to avoid the development of hypothermia. This is usually highly effective, but not all types of warming device are without risk in their use, since burns can occur if excessive heat is applied on the skin depending on the type of device used (Dunlop et al., 1989; Chung et al., 2012).

Analgesia is an important part of anesthesia and more effective when administered before the initial pain stimulus (Galatos, 2011; Riebold, 2015). The use of nonsteroidal anti-inflammatory drugs (NSAIDs) is important to alleviate pain and may provide postoperative analgesia (Anderson and Muir, 2005). In addition, inflammatory reactions, and in this case, the risk of stenosis at the level of the urinary tract can be reduced. In humans, dogs and cats, the use of NSAIDs has been reported to cause an increased risk of acute kidney injury (Paliainen, 2015). The National Institute for Health and Clinical Excellence guidelines 2008 state the nephrotoxicity of NSAIDs and recommend to avoid them in patients with chronic kidney disease until their renal function is evaluated (Nderitu, 2013). In the occurrence of hypotension, the administration of NSAIDs can further decrease the renal function (Garcia, 2016). However, in case of severe kidney dysfunction, caution should be taken to avoid further damage (Videla and van Amstel, 2016). In Iranian Cashmere (Rayeni) goats, the effects of NSAIDs, more specifically flunixin meglumine, ketoprofen and phenylbutazone, were evaluated in a study of Mozafari and Derakhshanfar (2012). Adverse effects were noted on gastrointestinal and myocardial tissues. Flunixin meglumine was the least toxic while phenylbutazone caused the worst side effects as evidence was shown on necropsy at the end of the study. Patients in this case report were treated with flunixin or meloxicam. Visceral analgesia can indeed be achieved with flunixin (Anderson and Muir, 2005). In these case series, NSAIDs were administered in the clinic before

transfer to the surgery department. Alpha-2 agonists, like xylazine or detomidine, provide dose-dependent analgesia, but their use is limited by the sedative and cardiovascular effects (Carroll and Hartsfield, 1997). Opioids, such as morphine ($0.05 - 0.1 \text{ mg kg}^{-1}$) or butorphanol ($0.05 - 0.2 \text{ mg kg}^{-1}$), are also proven to provide good analgesia in ruminants (Riebold, 2015). In addition, Riebold (2015) described constant rate infusions of ketamine (bolus of 0.5 mg kg^{-1} , CRI of $10 \mu\text{g kg min}^{-1}$) or lidocaine (loading dosage of $2.5 - 5 \text{ mg kg}^{-1}$, CRI of $50 - 100 \mu\text{g kg}^{-1} \text{ min}^{-1}$) to provide analgesia in goats, but these were not applied in this case series.

Reduction of the amount of anesthetics and analgesia per- and postoperatively can be achieved by the use of an epidural (Anderson and Muir, 2005). Epidural anesthesia achieved with local anesthetics and opioids has been described to provide analgesia (dos Santos Silva et al., 2017). A lumbosacral epidural anesthesia was performed in four out of twelve procedures using morphine and bupivacaine hydrochloride with the patient placed in a sternal position. The epidural space was entered as described by Skarda (1996) at the lumbosacral intervertebral joint, after surgical preparation of the skin in the region of L6-S1. Neurological anomalies caused by hematoma formation, infection or nerve injury may be associated with epidural anesthesia with occurring symptoms of pain, numbness or paraplegia (Sawai et al., 2016). Injuries of the spinal cord or nerve root can occur with or without the presence of a hematoma due to spinal compression (Kane, 1981; Sawai et al., 2016). Irritation of the nerves by the local anesthetic caused by direct toxicity of the agents (Kane, 1981; Sawai et al., 2016; Kobayashi et al., 2017) or by their osmotic effect can occur (Sawai et al., 2016). Spinal cord ischemia and thrombosis of the spinal arteries caused by hypotension can be considered as main cause of paraplegia in terms of anesthetic management related factors (Kane, 1981; Auroey et al., 1997; Sawai et al., 2016; Kobayashi et al., 2017). Hypotension can also occur as a result of epidural anesthesia (Kane, 1981). Lastly, lumbar puncture can aggravate venous engorgement causing neurological compression (Sawai et al., 2016). Patient 8B was unable to stand after the epidural with loss of deep pain sensation. Possibly, the spinal cord or meninges had been traumatized, since no hypotension occurred during the anesthetic procedure (Skarda, 1996). Nevertheless, the identification of the cause of paraplegia is essential (Sawai et al., 2016). Dexamethasone was administered once at a dosage of 0.5 mg kg^{-1} . Since there was no improvement of the patient's condition, further medical imaging examination was performed, including radiography, myelography and CT scans. On CT, no obvious spinal abnormalities were discovered that could have explained the condition, but a bony defect with mild displacement of a fragment was visible centrally

at the caudodorsal endplate of L7, suggestive for osteochondrosis dissecans. Komasa et al. (2016) described paraplegia of a man due to compression of the spinal cord by bone wax. The fragment at the level of L7 revealed at CT might therefore provide a possible explanation for the condition of the goat. However, in human medicine, magnetic resonance imaging (MRI) has been advised in several case reports to evaluate the spinal cord and determine the cause of paraplegia (Komasa et al., 2016; Sawai et al., 2016). In this case, MRI was not performed but could have provided additional information. The owners opted the goat to be euthanized and did not wish to have a necropsy performed. One other case (1A) was unable to stand during several hours after surgery; however, this was not unexpected, since the inability to stand after epidural injection of bupivacaine for up to 11 hours, given its long duration of action has been reported (Skarda, 1996; Skarda and Tranquilli, 2007).

CONCLUSIONS

Special considerations must be made when ruminants are placed under general anesthesia due to their anatomical and physiological properties which may lead to tympany, regurgitation and salivation. The use of an endotracheal tube is important to avoid (aspiration) pneumonia.

In case of obstructive urolithiasis, a good physical evaluation and assessment of the bloodwork should be performed prior to surgery. Electrolyte imbalances must be corrected before anesthesia. In one case of this case series, metabolic acidosis was present, which needed correction with bicarbonate during anesthesia.

The choice of anesthetics must be well considered due to the possible side effects of the drugs. Xylazine is not recommended because of an increased urinary production in combination with hyperglycemia and hypoinsulinemia. In addition, cardiovascular side effects (hypotension and bradycardia) can be observed, which was seen in the cases (2/12) which received xylazine.

Fluids should be given initially in a conservative way until the obstruction is relieved.

Epidural anesthesia (4/12) can be a good way to provide additional analgesia; however, in this case series, it resulted in a complication with paralysis in one case.

REFERENCES

- Anderson D.E., Muir W.W. (2005). Pain management in ruminants. *Veterinary Clinics: Food Animal Practice* 21(1), 19-31.
- Auroey Y., Narchi P., Messiah A., Litt L., Rouvier B., Samii K. (1997). Serious complications related to regional an-

- aesthesia: results of a prospective survey in France, Spinal cord infarction following epidural and general anaesthesia. *Anesthesiology* 87, 479-486.
- Borer-Weir K. (2014). Analgesia. In: Clarke K.W., Trim C.M., Hall L.W. (editors). *Veterinary Anaesthesia*. Eleventh edition, Saunders Elsevier, London, U.K., 101-133.
- Carroll G.L., Hartsfield S.M. (1996). General anaesthetic techniques in ruminants. *Veterinary Clinics of North America: Food Animal Practice* 12(3), 627-661.
- Chung K., Lee S., Oh S. Choi J., Cho H. (2012). Thermal burn injury associated with forced-air warming device. *Korean Society of Anaesthesiologist*, 64(4), 391-392.
- Clarke K.W., Trim C.M., Hall L.W. (2014). General pharmacology of the injectable agents, and principles of premedication, In: Clarke K.W., Trim C.M., Hall L.W. (editors). *Veterinary Anaesthesia*. Eleventh edition, Saunders Elsevier, London, U.K., 135-153.
- Clarke K.W., Trim C.M., Hall L.W. (2014). Anaesthesia of goats and sheeps, In: Clarke K.W., Trim C.M., Hall L.W. (editors). *Veterinary Anaesthesia*. Eleventh edition, Saunders Elsevier, London, U.K., 341-366.
- Dos Santos Silva P. Fantinato-Neto P., Silva A.N.E., Birgel E.H.J., Carregaro A.B. (2017). Thoracolumbar epidural anesthesia with 0,5% bupivacaine with or without methadone in goats. *Irish Veterinary Journal* 70(1), 1-7.
- Dunlop C.I., Daunt D.A., Haskins S.C. (1989). Thermal burns in four dogs during anesthesia, *Veterinary Surgery* 18(3), 242-246.
- Dzikiti T.B. (2013). Intravenous anaesthesia in goats. *Journal of the South African Veterinary Association* 84(1), 499-507.
- Ermilio E.M. and Smith M.C. (2011). Treatment of emergency conditions in sheep and goats. *Veterinary Clinics of North America: Food Animal Practice* 27(1), 33-45.
- Ewing K.K. (1990). Anaesthesia techniques in sheep and goat. *Veterinary Clinics of North America: Food Animal Practice* 6 (3), 759-778.
- Ewoldt J.M., Anderson D.E., Miesner M.D., Saville W.J. (2006). Short-and long term outcome and factors predicting survival after surgical tube cystostomy for treatment of obstructive urolithiasis in small ruminants. *Veterinary Surgery* 35, 417-422.
- Ewoldt J.M., Jones M.L., Miesner M.D. (2008). Surgery of obstructive urolithiasis in ruminants. *Veterinary Clinics of North America: Food Animal Practice* 24(3), 455-465.
- Fortier L.A., Gregg A.J., Hollis N., Fubini S.L. (2004). Caprine obstructive urolithiasis: Requirement for second surgical intervention and mortality after percutaneous tube cystostomy, surgical tube cystostomy, or urinary bladder marsupialization. *Veterinary Surgery* 33, 661-667.
- Freitas G.C., Monteiro Carvalho Mori da Cunha M.G., Gomes K., Monteiro Carvalho Mori da Cunha J.P., Tohni M., Pippi N.L., Carregaro A.B. (2012). Acid-base and biochemical stabilization and quality of recovery in male cats with urethral obstruction and anesthetized with propofol or a combination of ketamine and diazepam. *The Canadian Journal of Veterinary Research* 76, 201-208.
- Galatos A.D. (2011). Anaesthesia and analgesia in sheep and goat, *Veterinary Clinics of North America: Food Animal Practice* 27, 47-59.
- Garcia E.R. (2015). Urogenital disease. In: Duke-Novakovski T., de Vries M., Seymour C. (editors). *BSAVA Manual of Canine and Feline Anesthesia and Analgesia*. Third edition, British Small Animal Association, Gloucester, U.K., 356-365.
- Gazi M.A., Makhdoomi D.M., Parrah J.D., Ganai A.M., Shiekh G.N., Mir S.A. (2014). Recent advances in surgical management of urolithiasis in sheep and goat. *African Journal of Agriculture Research* 29(26), 2055-2061.
- George J.W., Hird D.W., George L.W. (2007). Serum biochemical abnormalities in goats with uroliths: 107 cases (1992-2003). *Journal of American Veterinary Medical Association* 230(1), p101-106.
- Gugjoo M.B., Zama M.M.S., Amarpal A, Mohsina A., Saxena A.C., Sarode I.P. (2013). Obstructive urolithiasis in buffalo calves and goats: incidence and management, *Journal of Advanced Veterinary Research* 3, 109-113.
- Hunter B.G., Huber M.J., Riddick L. (2012). Laparoscopic-assisted urinary bladder marsupialization in a goat that developed recurrent urethral obstruction following perineal urethrostomy. *Journal of the American Veterinary Medical Association* 241(6), 778-781.
- Jackson P.G.G, Cockcrof P.D. (2002). Laboratory reference values: biochemistry. In: Jackson P.G.G., Crocker P.D. (editors). *Clinical Examination of Farm Animals*. Blackwell Science Ltd, 303-305.
- Kane R.E. (1981). Neurologic deficits following epidural or spinal anaesthesia, *Anaesthesia and Analgesia* 60(3), 150-161.
- Kinsley M.A., Semevolos S., Parker J.E., Duesterdieck-Zellmer K., Huber M. (2013). Use of plain radiography in the diagnosis, surgical management, and postoperative treatment of obstructive urolithiasis in 25 goats and 2 sheeps. *Veterinary Surgery* 42, 663-668.
- Kobayashi K., Narimatsu N., Oyoshi T., Ikeda T., Tohya T. (2017). Spinal cord infarction following epidural and general anaesthesia: a case report. *Journal of Anesthesia Clinical Reports*, 42, 1-6.
- Kokkonen U.M., Eriksson L. (1987). Cardiovascular and allied actions of xylazine and atropine in the unanaesthetized goat. *Journal of Veterinary Pharmacological Therapy* 10, 11-16.
- Komasawa N., Yamasaki T., Matsunami S., Minami T. (2016). A rare cause of lower limb paralysis after epidural anaesthesia, *Journal of Clinical Anaesthesia* 33, 166-167.
- Kukanich B., Wiese A.J. (2015). Opioids. In: Grimm K.A., Lamont L.A., Tranquilli W.J., Greene S.A., Robertson S.A. (editors). *Veterinary Anaesthesia and Analgesia*. Fifth edition, Wiley Blackwell, 207-226.
- Lin H. (2015). Comparative anaesthesia and analgesia of ruminants and swine In: Grimm K.A., Lamont L.A., Tranquilli W.J., Greene S.A., Robertson S.A., *Veterinary Anaesthesia and Analgesia*. Fifth edition, 2015, Wiley Blackwell, 743-753.
- Mozaffari A.A., Derakhshanfar A. (2012). The gastrointestinal and myocardial adverse effect of flunixin meglumine, ketoprofen and phenylbutazone in Iranian Cashmere (Rayeni) goats: clinical, haematological, biochemical and pathological findings. *Comparative Clinical Pathology* 21(1), 49-53.
- Nderitu P., Doos L., Jones P.W., Davies S.J., Kadem U.T. (2013). Non-steroidal anti-inflammatory drugs and chronic kidney disease progression: a systematic review, *Family Practice* 30(3), 247-255.
- Palviainen M.J., Junnikkala S., Raekallio M., Meri S., Vainio O. (2015). Activation of complement system in kidney after ketoprofen-induced kidney injury in sheep. *Acta Veterinaria Scandinavica* 57, 1-6.
- Posner L.P., Burns P. (2009). Sedative agents: tranquilizers,

- alfa-2 agonists and related agents, In: Rock A.H. (editor). *Veterinary Pharmacology and therapeutics*. Ninth edition, Wiley Blackwell, 337-380.
- Prassinos N.N., Galatos A.D., Raptopoulos D. (2005). A comparison of propofol, thiopental or ketamine as induction agents in goats. *Veterinary Anaesthesia and analgesia* 32(5), 289-296.
- Riebold T.W. (2015). Anaesthesia and Analgesia for domestic species. Ruminants. In: Grimm K.A., Lamont L.A., Tranquilli W.J., Greene S.A., Robertson S.A. (editors). *Veterinary Anaesthesia and Analgesia*. Fifth Edition, Wiley Blackwell, 912-927.
- Sawai T., Nakahira J., Minami T. (2016). Paraplegia caused by giant intradural herniation of a lumbar disk after combined spinal-epidural anaesthesia in total hip arthroplasty. *Journal of Clinical Anaesthesia* 32, 169-171.
- Skarda R.T. (1996). Local and regional anaesthesia in ruminants and swine. *Veterinary Clinics of North America: Food Animal Practice* 12 (3), 579-626.
- Steffey E.P., Mama K.R., Brosnan R.J. (2015). Inhalation anaesthetics. In: Grimm K.A., Lamont L.A., Tranquilli W.J., Greene S.A., Robertson S.A. (editors). *Veterinary Anaesthesia and Analgesia*. Fifth Edition, Wiley Blackwell, 912-927.
- Tagawa M., Okano S., Sako T., Orima H., Steffey E.P. (1994). Effect of change in body position on cardiopulmonary function and plasma cortisol in cattle. *Journal of veterinary medicine science* 53(1), 131-134.
- Taylor P.M. (1991). Anaesthesia in sheep and goats. In *Practice*, 31-36.
- Taylor P.M., Clarke K.W. (2007). Inhalation anaesthesia. In Taylor P.M. and Clarke K.W. (editors). *Handbook of Equine Anesthesia*. Second edition, Saunders Elsevier, 54-84.
- Valverde A., Doherty T.J. (2008). Anaesthesia and analgesia in ruminants. In: Valverde A. and Doherty T.J. (editors). *Anaesthesia and Analgesia in Laboratory Animals*. Second edition, Academic Press, 385-411.
- Videla R. and Van Amstel S. (2016). Urolithiasis. *Veterinary Clinics of North America: Food Animal Practice* 32(3), 687-700.
- Walz P.H., Taylor D. (2012). Fluid therapy and nutritional support. In: Pugh D.G. and Baird A.N. (editors). *Goat and Sheep Medicine*. Second Edition, Elsevier, 50-59.

Uit het verleden



Gent : Een gespan werd door een tram aangereden : het paard gedood.