

## Latex-casting of vessels relevant during vaginectomy in bitches

*Latex-opspuitingen van bloedvaten die relevant zijn tijdens vaginectomie bij de teef*

M. De Vlam, S. Pil, A. Schlake, H. de Rooster

Small Animal Department, Faculty of Veterinary Medicine,  
Ghent University, Salisburylaan 133, 9820 Merelbeke, Belgium

matthias.de.vlam@hotmail.com

### ABSTRACT

Vaginectomy is an infrequently performed invasive surgery to control vaginal disorders in bitches. Indications for vaginectomy include vaginal tumors (leiomyoma, fibroleiomyoma and leiomyosarcoma), polyps and vaginal prolapse. The surgical technique is a two-step procedure and consists of an extended laparotomy approach with caudal ovariohysterectomy followed by an episiotomy approach with removal and reconstruction of the vaginal wall. Although the surgery itself is invasive, the combined approach results in a favorable outcome with an apparently low risk of intra- and postoperative complications. During vaginectomy, traction is placed on the vagina and its supplying blood vessels via the episiotomy site. By means of a post-mortem study of five dogs, it was investigated if this traction resulted in damage or rupture of the supplying vessels. In this study, it was demonstrated that the uterine branch of the vaginal artery and the caudal vesical artery rupture during the traction phase of a vaginectomy via the episiotomy site. Rupture of these vessels might result in insufficient perfusion of the bladder and extensive intra-abdominal and -pelvic bleeding.

### SAMENVATTING

Vaginectomie is een weinig frequent uitgevoerde invasieve chirurgische ingreep voor de behandeling van vaginale aandoeningen bij de teef. Indicaties voor vaginectomie omvatten vaginale tumoren (leiomyomen, fibroleiomyomen en leiomyosarcomen), poliepen en vaginale prolaps. De chirurgische techniek is tweeledig en bestaat uit een uitgebreide celiotomiebenadering met caudale ovariohysterectomie, gevolgd door een episiotomiebenadering met verwijdering en reconstructie van de vaginale wand. Hoewel de chirurgische ingreep zeer invasief is, resulteert de gecombineerde benadering in een gunstige uitkomst met -volgens literatuurgegevens- een laag risico op intra- en postoperatieve complicaties. Tijdens vaginectomie wordt via de episiotomiebenadering tractie geplaatst op de vagina en de aanvoerende bloedvaten. Aan de hand van een postmortemstudie van vijf honden werd onderzocht of deze manuele tractie al dan niet resulteert in een beschadiging of het doorscheuren van deze aanvoerende bloedvaten. In de studie werd aangetoond dat de uteriene tak van de vaginale arterie en de caudale vesicale arterie scheuren tijdens de tractiefase van een vaginectomie via de episiotomiebenadering. Ruptuur van deze relatief grote bloedvaten zou tot hypoperfusie van de blaas en uitgebreide intra-abdominale en -pelvische bloeding kunnen leiden.

### INTRODUCTION

Over 80% of the reported vaginal tumors are benign smooth muscle tumors (Brodey and Roszel, 1967; Herron, 1983; Thacher and Bradley, 1983; Kydd and Burnie, 1986). Most are leiomyomas and fibroleiomyomas, but also fibromas and polyp formations may occur (Brodey and Roszel, 1967; Thacher and

Bradley, 1983). Benign vaginal tumors are most often intraluminal and pedunculated, originating from the vaginal wall (Nelissen and White, 2012). Malignant tumors are less frequently observed and include leiomyosarcomas, carcinomas and transmissible venereal tumors (Hill et al., 2000; Nelissen and White, 2012). Transmissible venereal tumors occur worldwide but are mostly diagnosed in tropic and subtropical regions

where they represent 37 to 60% of the malignant tumors (Brodey and Roszel, 1967; Thacher and Bradley, 1983). In Western Europe, leiomyosarcoma is the most common malignant vaginal neoplasia (Hill et al., 2000; Chiers, 2017). Most malignant tumors have, in contrast to benign tumors, a rather broad base and show an infiltrative growth (Farese et al., 2008; Tivers and Baines, 2010; Nelissen and White, 2012).

The treatment of non-pedunculated vaginal neoplasia consists of a (sub)total vaginectomy (Hill et al., 2000; Salomon et al., 2004; Tivers and Baines, 2012). This technique includes the removal of the complete vagina or the part of the vaginal wall surrounding the vaginal mass. In the intact bitch, a complete removal of the female genital tract is performed prior to vaginectomy (Nelissen and White, 2012). This additional surgical intervention is advised due to the oestrogen-dependent characteristics of vaginal leiomyomas (Brodey and Roszel, 1967; Thacher and Bradley, 1983; Kydd and Burnie, 1986). Compared to the 15%-recurrence rate in intact bitches, a zero-recurrence rate of leiomyomas has been observed when ovariohysterectomy is simultaneously performed at the time of the tumor removal (Nelissen and White, 2012; Saba and Lawrence, 2012; Weissman et al., 2013). Most benign tumors are good candidates for local resection via episiotomy given their biological behavior and because they are mostly pedunculated (Thacher and Bradley, 1983; Nelissen and White, 2012). Malignant tumors on the other hand require a more extensive surgical resection as a consequence of their broad base and strong infiltrative nature (Kapatkin et al., 1992; Nelissen and White, 2012). The treatment of malignant vaginal neoplasia requires total vaginectomy techniques combining an episiotomy approach with laparotomy. If necessary, these techniques can be further augmented by ostectomy or pubic osteotomy (Igna et al., 2016).

Vaginectomy performed through laparotomy combined with episiotomy results in few intra- and postoperative complications (Kyles et al., 1996; Gower et al., 2008; Nelissen and White, 2012; Alonge et al., 2015; Igna et al., 2016). As for intraoperative complications, hemorrhage is most frequent and might result in substantial blood loss (Prassinis et al., 2010). However, this complication is most of the time promptly managed and resolved by coagulation of the damaged vessel through the episiotomy approach (Nelissen and White, 2012). The most frequently observed postoperative complication is serohemorrhagic discharge, presumably originating from minor residual vascular supply to the vaginal wall (Nelissen and White, 2012). Furthermore, incontinence is possible when the neurovascular supply to the bladder, urethra and/or rectum is compromised by not carefully dissecting the vagina (Salomon et al., 2004). Other possible postoperative complications include bacterial infection, perineal swelling, irritation of the episiotomy incision, bleeding, dysuria, stranguria, pollakisuria, hematuria and perineal hernia formation (Viehoff and Sjollem, 2003; Salomon et al., 2004; Connery and

Spotswood, 2012).

Although vaginectomy involves infrequently performed invasive surgery for a mostly benign process, intra- and postoperative complications seem rare (Viehoff and Sjollem, 2003; Salomon et al., 2004; Connery and Spotswood, 2012; Nelissen and White, 2012). The surgical technique combining a laparotomy and episiotomy approach yields a favorable outcome (Nelissen and White, 2012). However, while performing the vaginectomy technique on the dogs of the present study, the question arose whether more severe complications due to the rough nature of the procedure through the episiotomy site are to be expected. The goal of this study was therefore to visualize the intrapelvic course of the blood vessels supplying the vaginal wall and to evaluate their state during (and after) the vaginectomy procedure.

## MATERIAL AND METHODS

Five cadavers of different dog breeds, age and neuter status were used. All animals had been euthanized for reasons unrelated to this study. Latex injection with minimal vessel dissection was performed in all dogs.

### Abdominal procedure

The dogs were positioned in dorsal recumbency and the abdominal cavity was opened by performing a caudal ventral midline celiotomy approach. Careful dissection and organ displacement were performed to visualize the abdominal aorta just caudal to the origin of the renal arteries. Through a small incision in the aortic wall, a feeding-tube (6F Nutrisafe Sterile Feeding Tube 10 mL Syringe, Abnoba Pet Store, Brierley Hill West Midlands, United Kingdom) was placed in the abdominal aorta just caudal to the renal arteries and secured by an encircling ligature (polydioxanone) (Figure 1). To reduce the total amount of latex needed to achieve the filling of the vascular structures of interest, both femoral arteries were ligated through a small skin incision at the location of the femoral triangle, bounded by the sartorius and pectineus muscles (Figure 1). A 20-mL syringe was used to inject an aqueous latex solution (V-Sure Eco Latex Natuurrubber, Vosschemie Benelux, Lier, Belgium) mixed with methylene blue (Methyleenblauw 25 mL, Euro-mex, Edegem, Belgium) as a coloring agent into the abdominal aorta. Adequate contrast was achieved by mixing 5 mL methylene blue per 100 mL latex. The total amount injected into the feeding tube was deemed sufficient when counterpressure on the 20-mL syringe plunger was felt. After curing of the latex for at least 12 hours, the celiotomy incision was enlarged until it reached from the xiphoid cartilage to the pecten of the pubic bone.

In the intact dogs of the present study, the ovarian pedicles were double ligated (polydioxanone) and

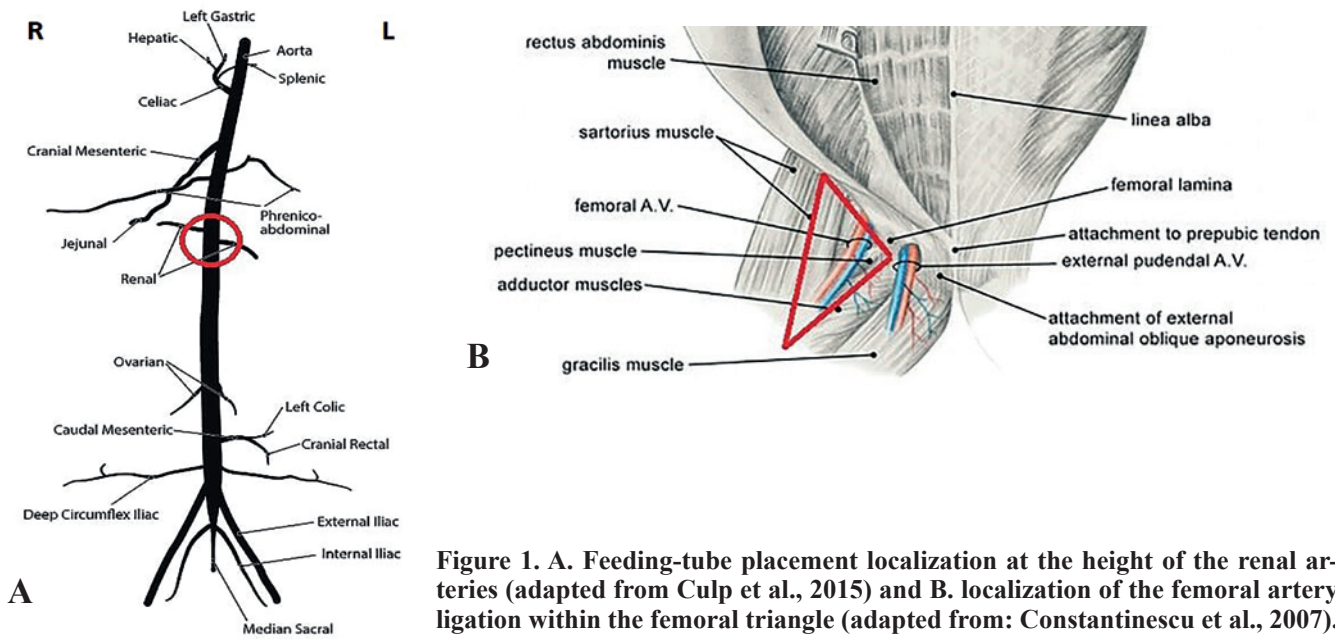


Figure 1. A. Feeding-tube placement localization at the height of the renal arteries (adapted from Culp et al., 2015) and B. localization of the femoral artery ligation within the femoral triangle (adapted from: Constantinescu et al., 2007).

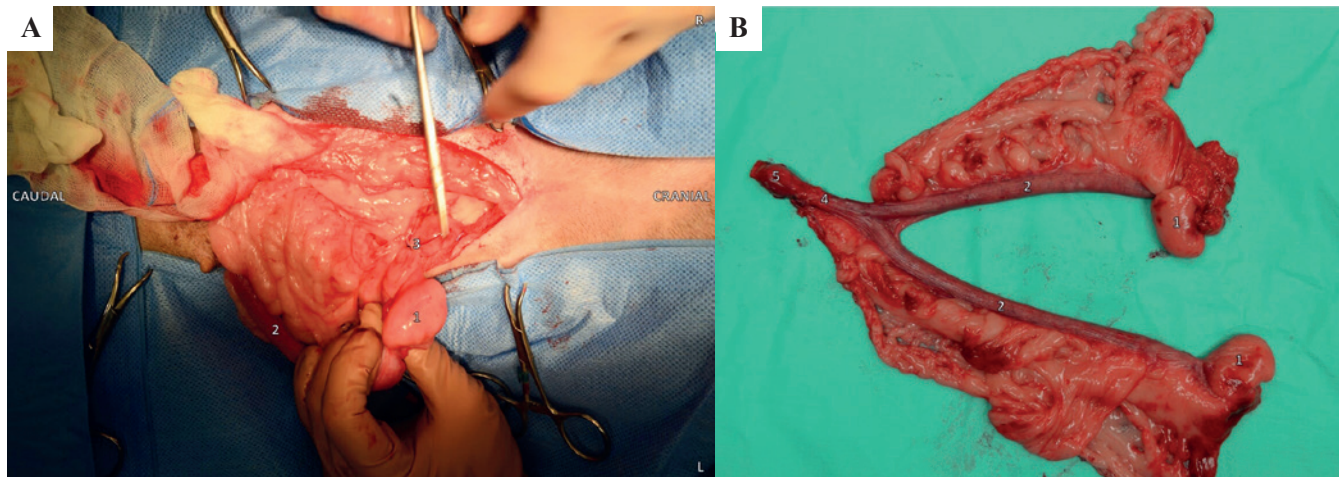


Figure 2. Caudal ovariohysterectomy. The picture was taken in a live patient during surgery. A. Abdominal presentation and ligation of the female reproductive tract after ventral median celiotomy approach. B. Female genital tract, including cervix, post caudal ovariohysterectomy. 1. Ovarian bursa 2. Uterine horn 3. Ovarian pedicle 4. Uterine body 5. Cervix.

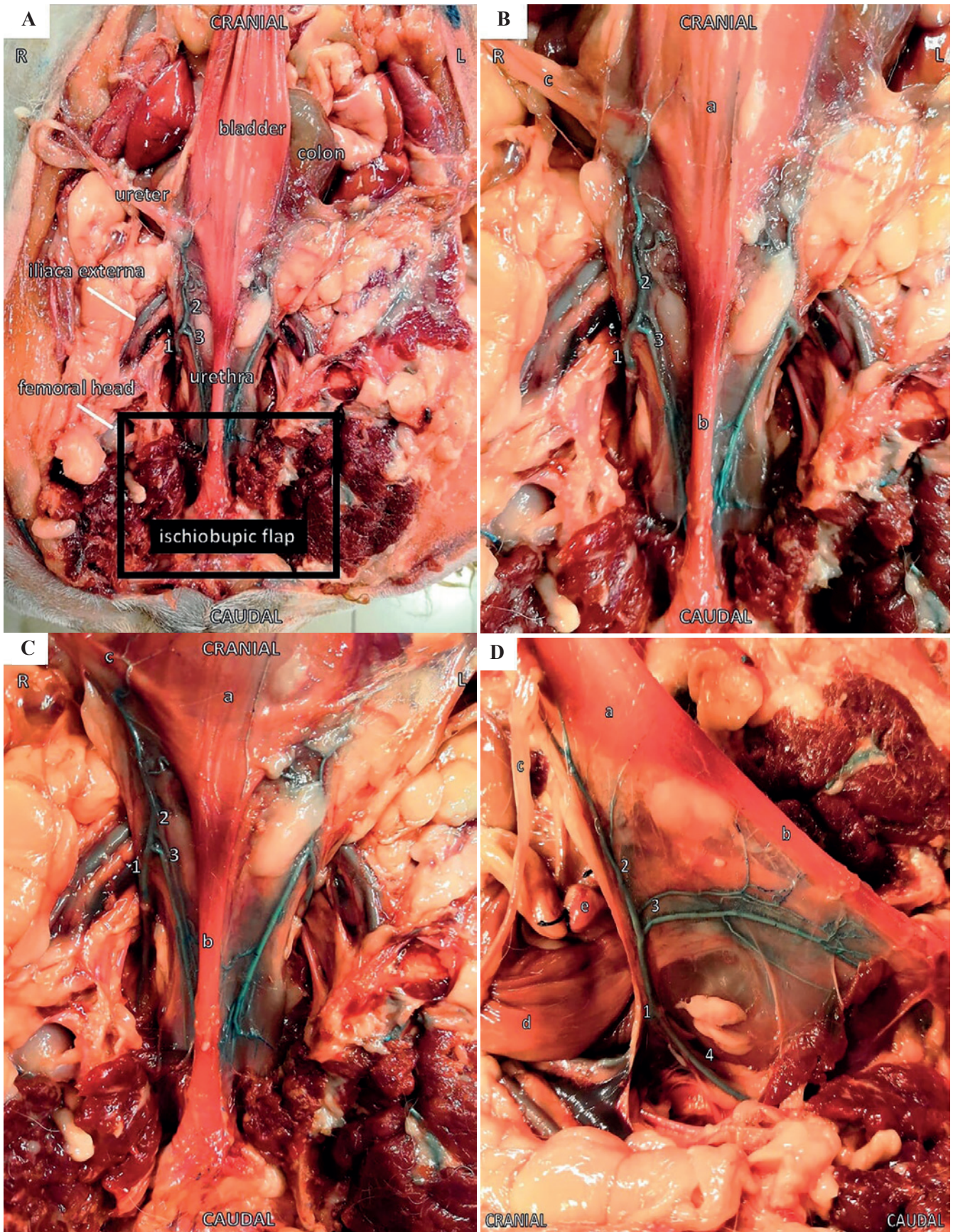
transsected as during a standard ovariohysterectomy (Figure 2A). The bladder was retroflexed to gain exposure to the vagina and the surrounding vessels leading to the female genital tract (vaginal artery, internal pudendal artery, caudal vesical artery, uterine branch of the vaginal artery, etc). A double encircling ligature (polydioxanone) was placed just caudal to the cervix that was subsequently transsected cranial to those ligatures. The female genital tract was then removed (Figure 2B).

Next, the muscles located on the ventral aspect of the ischiatic spine and pubic ramen were removed. A handsaw was used to remove an ischiopubic flap which allowed maximal intrapelvic visibility and accessibility of the female genital tract (Figure 3). Hereupon, the dogs were repositioned and placed in a perineal position in order to perform a standard total vaginectomy.

### Vaginal procedure

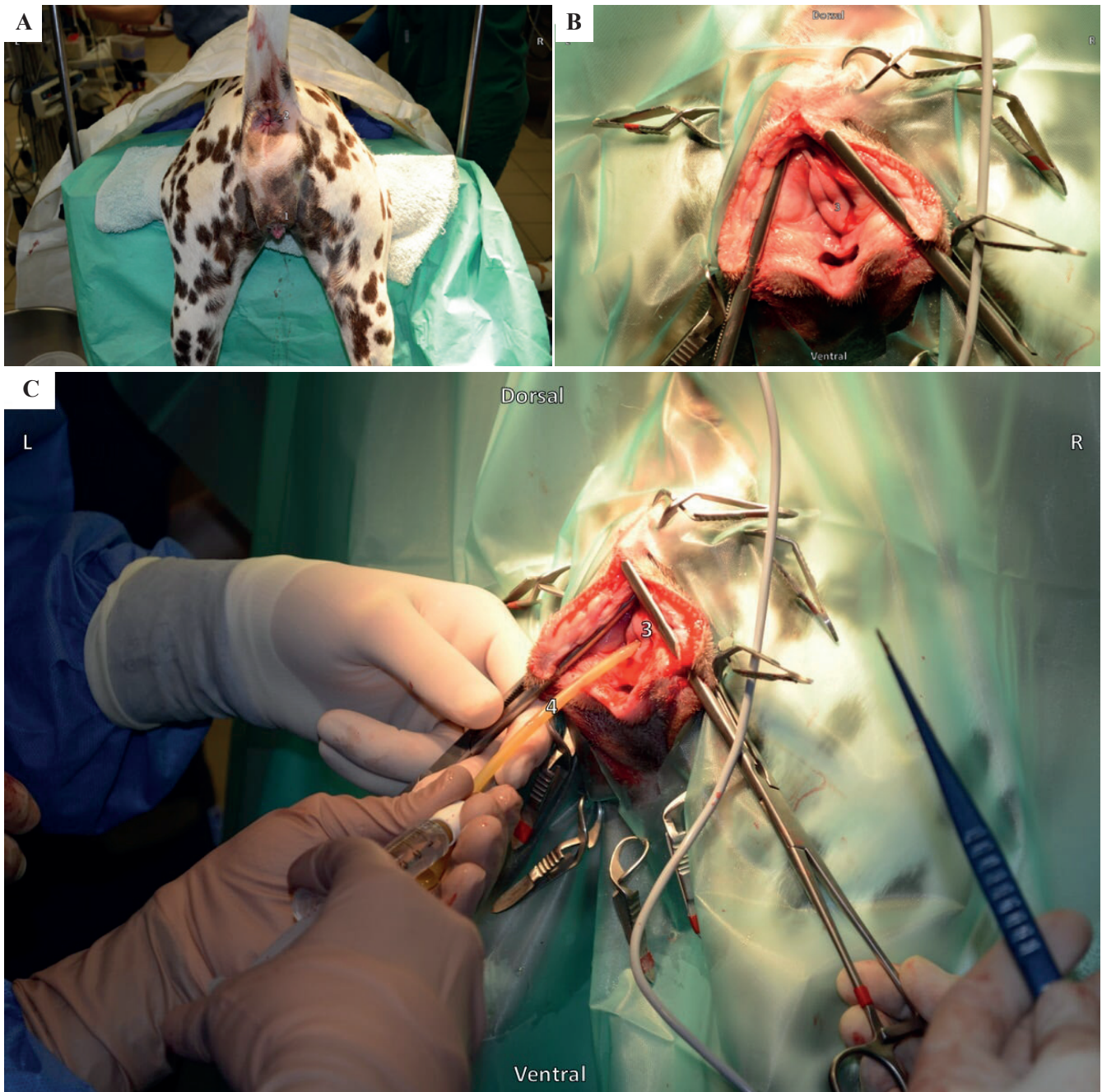
The dogs were positioned in sternal recumbency with the hindquarters slightly elevated (Trendelenburg position) and the pelvic limbs extended caudally over the edge of the surgical table (Figure 4A). The tail was restrained cranially in the dorsal midline and a purse string suture was placed around the anus. Doyen clamps were positioned with one blade in the vestibular lumen and the other blade on the skin surface. A midline episiotomy incision was made until visibility of the urinary papilla was achieved (Figure 4B). As soon as the urinary papilla was visible, a urinary catheter (Foley catheter, Pediatric (2-way), 5 cc balloon, A.M. Bickford, New York, United States) was placed to highlight the papilla (Figure 4C) as to prevent damage during surgery. Immediately cranial to the urinary papilla, a full thickness circular incision





**Figure 3.** Ventrodorsal and lateral view of the abdomen of a spayed, female dog one day after latex injection. An ischiobupic flap has been removed. The picture was taken post mortem. **A.** Ventral view of the pelvic cavity after ischiobupic flap removal. **B.** Ventral view of the vaginal artery and its target organs. **C.** Ventral view of the vaginal artery and its target organs. **D.** Lateral view of the vaginal artery and its target organs. 1. Vaginal artery 2. Caudal vesical artery 3. Urethral branch of the vaginal artery 4. Internal pudendal artery a. Bladder, b. Urethra, c. Ureter and ureteral branch of the vaginal artery, d. Descending colon, e. Uterine stump.





**Figure 4. Vaginal procedure: Positioning, episiotomy and placement of a urinary catheter. The picture was taken in a live patient during surgery. A. Positioning of the dog for episiotomy. B. Midline episiotomy incision with urinary papilla visualization. C. Urinary catheter insertion. 1. Vulva, 2. Anus purse string, 3. Urinary papilla, 4. Urinary catheter.**

of the vaginal wall was made. The vagina was then, by a combination of blunt and sharp dissection, lifted from its intrapelvic attachments. The combination of dissection and manual traction on the vagina resulted in the total removal of the vagina (total vaginectomy) (Figure 5).

### Postvaginectomy

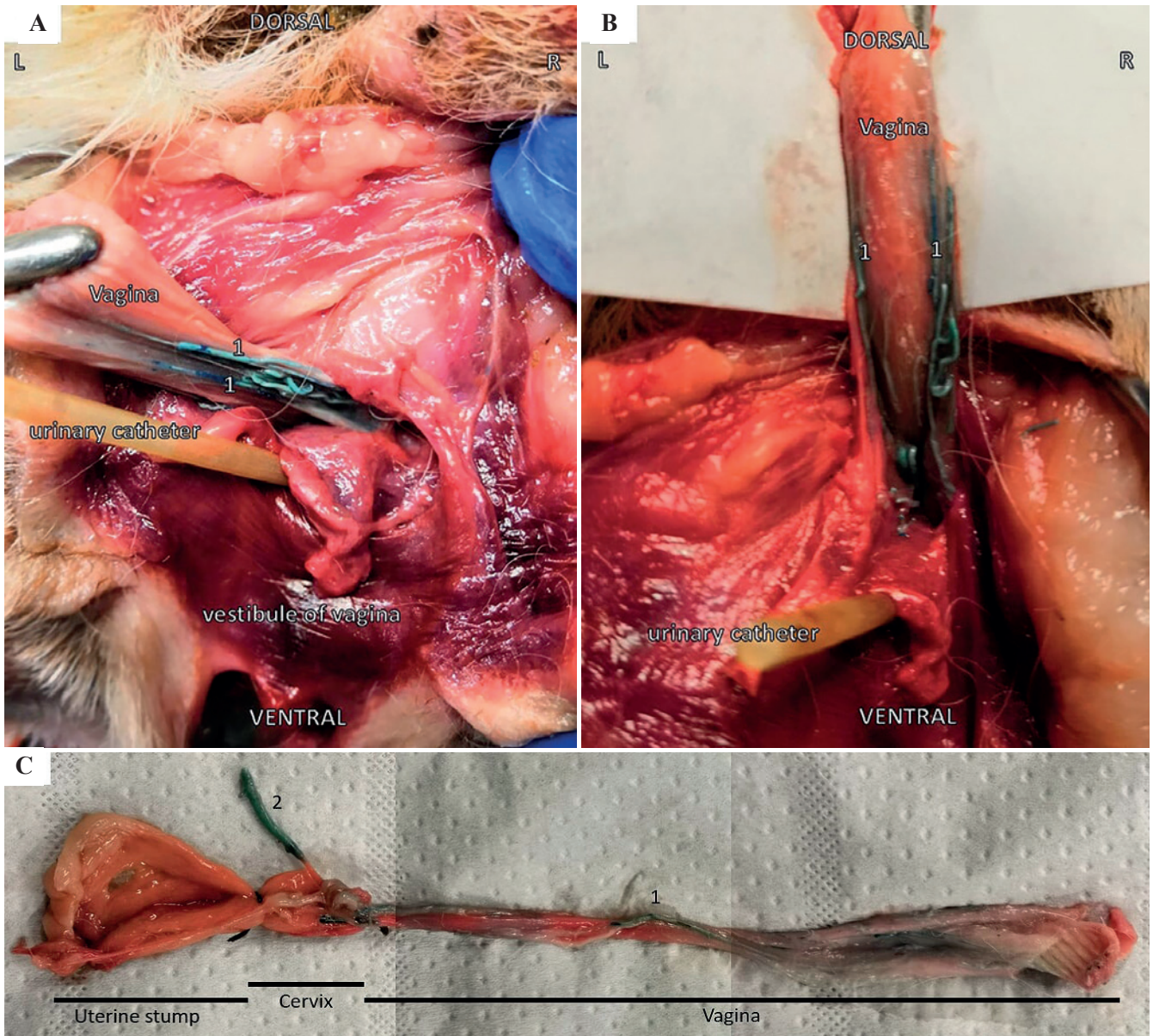
After the total vaginectomy, the dogs were again positioned in dorsal recumbency and intra-abdominal and intrapelvic damage to supplying blood vessels was mapped by taking pictures and comparing these

to descriptions in a leading textbook of veterinary anatomy (Barone, 2001). Vessel damage was then compared to pictures taken before the vaginectomy.

### RESULTS AND DISCUSSION

The size of the cadavers ranged from a small Yorkshire terrier to a large Great Dane. Other breeds used included a rough haired Teckel, a Labrador Retriever and a Boxer. Both the Great Dane and the rough haired Teckel were female and intact. The other dogs had already been ovariectomized. Age and clinical





**Figure 5.** Images obtained during and post vaginectomy via episiotomy in a dog that had already been spayed before the post-mortem study. **A.** Caudal traction on the caudal aspect of the vagina after circular dissection cranial to the urethral orifice. **B.** Dorsal traction on the vagina and vaginal artery during vaginectomy. **C.** Specimen consisting of vagina, cervix and uterine stump post vaginectomy. 1. Vaginal artery, 2. Uterine branch of the vaginal artery.

history were not available for any of the cadavers.

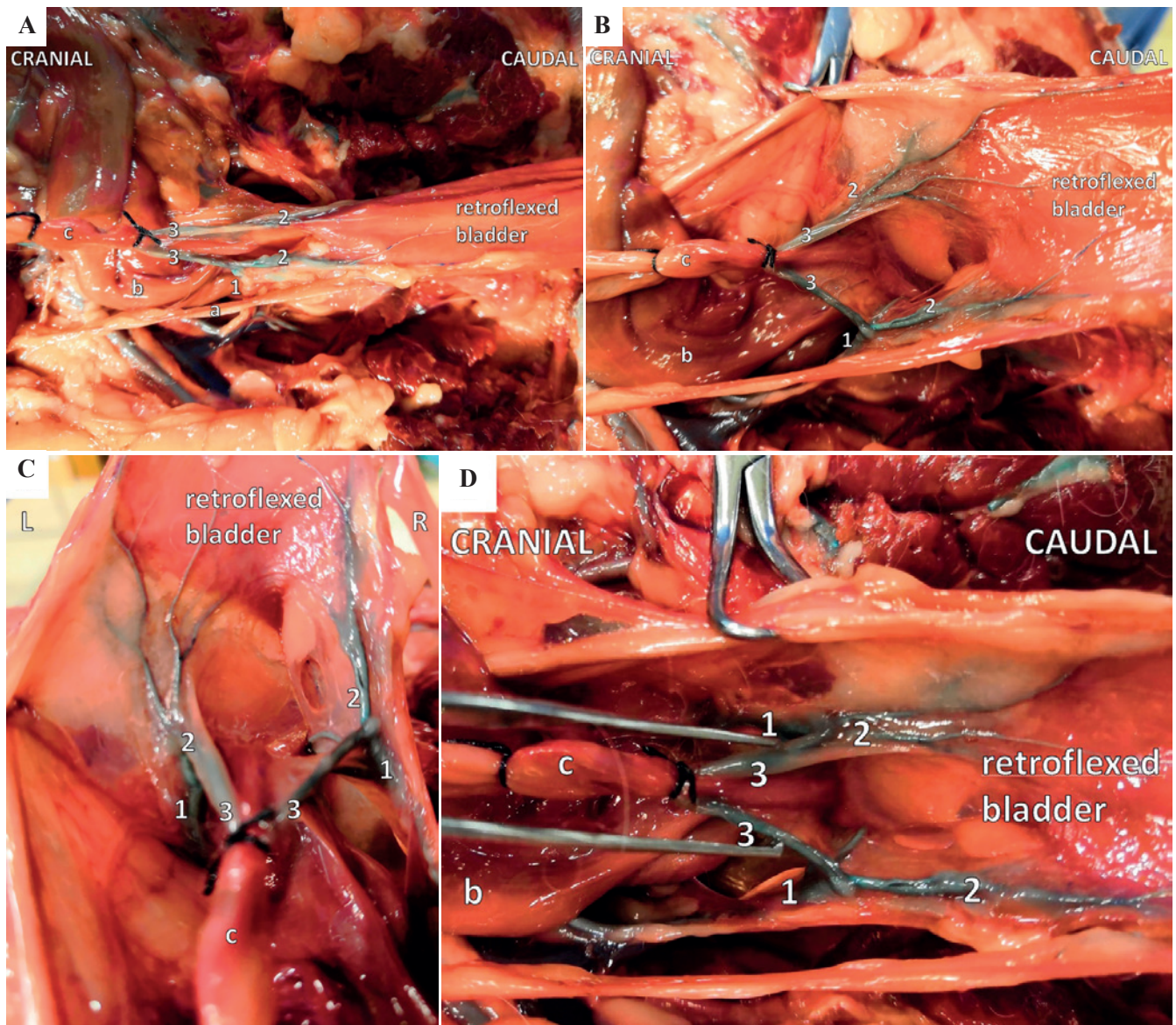
Although larger dogs are easier to be visualized, sufficient visualization of the vaginal supplying vessels could be achieved by combining a caudal laparotomy approach, ischiopubic flap removal and retroflexion of the bladder of all five dogs (Figures 4, 5 and 6). The removal of an ischiopubic flap was crucial to achieve visualization of the supplying vessels located deeply within the pelvic cavity. Visualization of the supplying blood vessels was further improved by vascular casting with latex mixed with methylene blue as a coloring agent. Curing of the latex for 12-24 hours resulted in strong and firm colored vessels. The latex solution could even reach the smallest vesical vessels. Ligation of the abdominal aorta at the height of the

renal arteries and at both femoral arteries at the height of the trigonum femorale mediale (Scarpa's triangle) resulted in an adequate filling of the supplying female genital tract vessels (Figure 1).

The major blood supply of the female genital tract is derived from the vaginal artery. Other supplying vessels include the ovarian artery and the internal pudendal artery. The vaginal artery continues as the uterine branch of the vaginal artery, the median rectal artery and the caudal vesical artery (Barone, 2001).

Caudal traction on the vagina and its supplying blood vessels (vaginal artery, caudal vesical artery, uterine branch of the vaginal artery, etc.) via the episiotomy site resulted in ruptured vessels at the abdominal site. In particular the caudal vesical artery and the





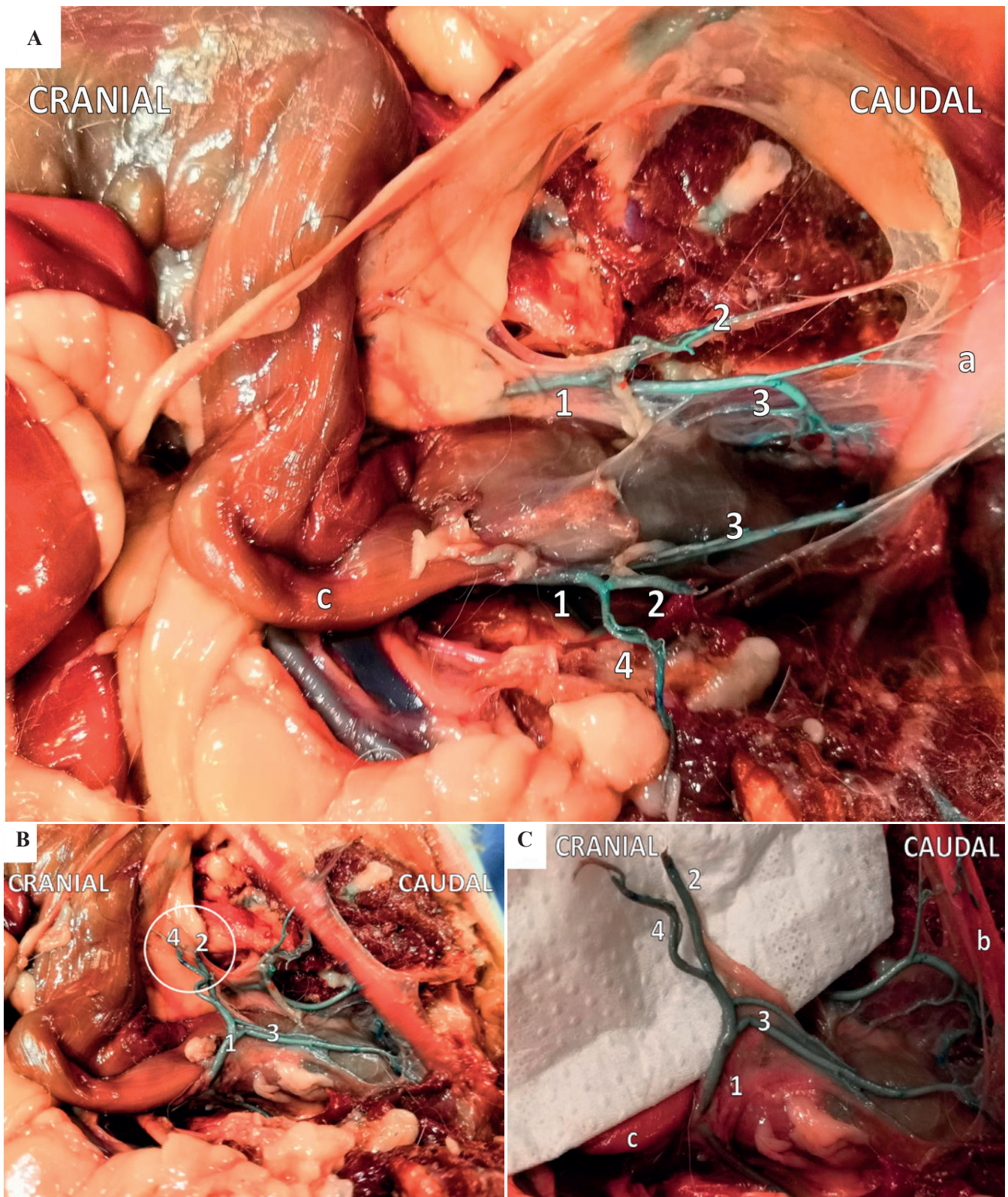
**Figure 6.** Blood vessel distribution between vagina, bladder and urethra visualized by latex injection. **A.** Ventral view of the vaginal artery with retroflexed bladder. **B.** Ventral view of the caudal vesical arteries with retroflexed bladder. **C.** Cranial view of the caudal vesical arteries with retroflexed bladder. **D.** Ventral view of the vaginal artery and its target organs. 1. Vaginal artery, 2. Caudal vesical artery, 3. Uterine branch of the vaginal artery, a. Ureter and ureteral branch of the vaginal artery, b. Descending colon, c. Uterine stump.

uterine branch of the vaginal artery ruptured during the vaginectomy via episiotomy. No damage was observed to other blood vessels (Figure 7). The vessel damage consistently occurred in all cadavers when following the adapted vaginectomy procedure via episiotomy (Nelissen and White, 2012). Although neutered, female dogs had a less prominent genital tract vascularization, vessel damage to the caudal vesical artery and the uterine branch of the vaginal artery was comparable to that found in intact, female dogs.

Despite ample documentation that vaginectomy only rarely results in intra- and postoperative complications (Kyles et al., 1996; Gower et al., 2008; Nelissen and White, 2012; Alonge et al., 2015; Igna et al., 2016), it stands to reason how this is possible.

In the post-mortem study, both the uterine branch of the vaginal artery and the caudal vesical artery were demonstrated to rupture during the episiotomy approach of the vaginectomy procedure (Figure 7). After damage, the affected vessel will spasm, a platelet plug will be formed, the complex cascade of coagulation will be activated, and a fibrin plug will be formed (LaPelusa and Dave, 2019). These consecutive steps efficiently stop blood loss whenever small vessels are damaged but trauma to those decently sized vessels should normally result in extensive intra-abdominal and -pelvic bleeding. These vessels cannot be reached for ligation during the laparotomy approach due to their localization deeply within the pelvis (Barone, 2001).





**Figure 7.** View of the latex-casted vaginal, urethral and vesical blood vessels post vaginectomy. Visualization of surgery-related damage to the caudal vesical artery and uterine branch of the vaginal artery. **A.** Ventral view of the vaginal artery with retroflexed bladder post vaginectomy. **B.** Lateral view of the vaginal artery post vaginectomy. **C.** Detailed lateral view of damaged blood vessels (caudal vesical artery and uterine branch of the vaginal artery) post vaginectomy. 1. Vaginal artery, 2. Caudal vesical artery, 3. Urethral branch of the vaginal artery, 4. Uterine branch of the vaginal artery, a. Bladder, b. Urethra, c. Descending colon.



During surgery, it is common to use an electrocautery device to control intraoperative bleeding during the episiotomy part of the surgery (Nelissen and White, 2012). However, it seems unlikely that the uterine branch of the vaginal artery and the caudal vesical artery can be reached with the electrocautery device during the vaginectomy via episiotomy. Rupture of the caudal vesical artery may also lead to insufficient perfusion of the bladder since the cranial vesical artery is often rudimentary or not present in dogs (Barone 2001). It therefore remains to be elucidated why these theoretical major postoperative complications do not seem to occur in dogs treated by vaginectomy in clinical practice.

## LITERATURE

- Alonge, S., Romussi, S., Grieco, V., Luvoni, G.C. (2015). Congenital abnormality of the vagina complicated by haemato-pyocolpos in a 1-year Labrador Retriever. *Reproduction in Domestic Animals* 50, 514-516.
- Bacci, B., Vignoli, M., Rossi, F., Gallorini, F., Terragni, R., Laddaga, E.L., Sarli, G. (2010). Primary prostatic leiomyosarcoma with pulmonary metastases in a dog. *Journal of the American Animal Hospital Association* 46, 103-106.
- Baioni, E., Scanziani, E., Vincenti, M.C., Leschiera, M., Bozzetta, E., Pezzolato, M., Desiato, R., Bertolini, S., Maurella, C., Ru, G. (2017). Estimating canine cancer incidence: findings from a population-based tumour registry in northwestern Italy. *BMC Veterinary Research* 13, 203.
- Barone, R. (2001). Intestin. In: Barone R. (editors). *Anatomie Comparée des Mammifères Domestiques; Tome 3 – Splanchnologie*. Vigot Freres, Paris, 485-498.
- Barone, R. (2001). Appareil génital femelle. In: Barone R. (editors). *Anatomie Comparée des Mammifères Domestiques; Tome 4 – Splanchnologie II*. Vigot Freres, Paris, 291-407.
- Brodey, R.S., Roszel, J.F. (1967). Neoplasms of the canine uterus, vagina, and vulva: a clinicopathologic survey of 90 cases. *Journal of the American Veterinary Medical Association* 151, 1294-1307.
- Chiers, K. (2017). Uterus, cervix, vagina, vulva. In: *Bijzondere Pathologie van de Kleine Huisdieren*. University Press, Zelzate, België, 53-58.
- Connery, N.A., Spotswood, T. (2012). An unusual case of urinary incontinence in an intersex West Highland white terrier. *Canadian Veterinary Journal* 53, 1195-1198.
- Constantinescu, G.M., Beittenmiller, M.R., Mann, F.A., Constantinescu, I. (2007). Clinical anatomy of the prepubic tendon in the dog and a comparison with the cat. *Cercetari Experimentale & Medico-Chirurgicale Anul XIV* 2-3, 81-85.
- Crawford, J.T., Adams, W.M. (2002). Influence of vestibulovaginal stenosis, pelvic bladder, and recessed vulva on response to treatment for clinical signs of lower urinary tract disease in dogs: 38 cases (1990-1999). *Journal of the American Veterinary Medical Association* 221, 995-999.
- Culp, W.T.N., Mayhew, P.D., Pascoe, P.J., Zwingerberger, A. (2015). Angiographic anatomy of the major abdominal arterial blood supply in the dog. *Veterinary Radiology & Ultrasound* 56, 474-485.
- Dobson, J.M., Samuel, S., Milstein, H., Rogers, K., Wood, J.L. (2002). Canine neoplasia in the UK: estimates of incidence rates from a population of insured dogs. *Journal of Small Animal Practice* 43, 240-246.
- Farese, J.P., Bacon, N.J., Ehrhart, N.P., Bush, J., Ehrhart, E.J., Withrow, S.J. (2008). Oesophageal leiomyosarcoma in dogs: surgical management and clinical outcome of four cases. *Veterinary Comparative Oncology* 6, 31-38.
- Gower, J.A., Schoeniger, S.J., Gregory, S.P. (2008). Persistent vaginal hemorrhage caused by vaginal vascular ectasia in a dog. *Journal of the American Veterinary Medical Association* 233, 945-949.
- Gruntzig, K., Graf, R., Hassig, M., Welle, M., Meier, D., Lott, G., Erni, D., Schenker, N.S., Guscetti, F., Boo, G., Axhausen, K., Fabrikant, S., Folkers, G., Pospischil, A. (2015). The Swiss canine cancer registry: a retrospective study on the occurrence of tumours in dogs in Switzerland from 1955 to 2008. *Journal of Comparative Pathology* 152, 161-171.
- Herron, M.A. (1983). Tumors of the canine genital system. *Journal of the American Animal Hospital Association* 19, 981-994.
- Hill, T.P., Lobetti, R.G., Schulman, M.L. (2000). Vulvovaginectomy and neo-urethrostomy for treatment of haemangiosarcoma of the vulva and vagina. *Journal of the South African Veterinary Association* 71, 256-259.
- Igna, C., Bumb, D., Proteasa, A., Dascalu, R., Schuszler, L., Igna, V., Brezovan, D. (2016). Subtotal vaginectomy as a treatment for vaginal tumours in two bitches. *Bulletin of University of Agricultural Sciences and Veterinary Medicine* 73, 1.
- Kapatkin, A.S., Mullen, H.S., Matthiesen, D.T., Patnaik, A.K. (1992). Leiomyosarcoma in dogs: 44 cases (1983-1988). *Journal of the American Veterinary Medical Association* 201, 1077-1079.
- Kyles, A.E., Vaden, S., Hardie, E.M., Stone, E.A. (1996). Vestibulovaginal stenosis in dogs: 18 cases (1987-1995). *Journal of the American Veterinary Medical Association* 209, 1889-1893.
- Kydd, D.M., Burnie, A.G. (1986). Vaginal neoplasia in the bitch: a review of forty clinical cases. *Journal of Small Animal Practice* 27, 255-263.
- LaPelusa, A., Dave, H.D. (2019). *Physiology, Hemostasis*. StatPearls Publishing January, Treasure Island, Florida, USA, <https://www.ncbi.nlm.nih.gov/books/NBK545263/>
- Liptak, J.M., Forrest, L.J. (2012). Soft tissue sarcomas. In: *Withrow & MacEwen's Small Animal Clinical Oncology*. Fifth edition, Elsevier Inc., St. Louis, MO, USA, pp. 356-380.
- Mathews, G.K. (2001). Surgery of the canine vagina and vulva. *Clinical Theriogenology* 31, 271-290.
- Nelissen, P., White, R.A.S. (2012). Subtotal vaginectomy for management of extensive vaginal disease in 11 dogs. *Veterinary Surgery* 41, 495-500.
- Nelson, B. (2014). In dogged pursuit of cancer's genetic origins: researchers are using the increased cancer susceptibility within specific dog breeds to benefit both canines and humans. *Cancer Cytopathology* 122, 313-314.
- Prassinis, N.N., Adamama-Moraitou, K.K., Ververidis, H.N., Anagnostou, T.L., Kladakis, S.E. (2010). Vaginal rupture and evisceration in a dog. *Acta Veterinaria Hungarica* 58, 309-315.



- Purswell, B.J. (2010). Vaginal disorders. In: Ettinger S.J. and Feldman E.C. (editors). *Textbook of Veterinary Internal Medicine: Diseases of the Dog and Cat (Volume 2)*. Seventh edition, Elsevier Saunders, St. Louis, MO, USA, pp. 1929-1933.
- Saba, C.F., Lawrence, J.A. (2012). Tumors of the female reproductive system. In: (editors!!) *Withrow & MacEwen's Small Animal Clinical Oncology*. Fifth Edition, Elsevier Inc., St. Louis, MO, USA, pp. 532-537.
- Salomon, J.F., Deneuche, A., Viguier, E. (2004). Vaginectomy and urethroplasty as a treatment for non-pedunculated vaginal tumours in four bitches. *Journal of Small Animal Practice* 45, 157-161.
- Thacher, C., Bradley, R.L. (1983). Vulvar and vaginal tumors in the dog: a retrospective study. *Journal of the American Veterinary Medical Association* 183, 690-692.
- Tivers, M., Baines, S. (2010). Surgical diseases of the female genital tract 2. Vagina and external genitalia. *In Practice* 32, 362-369.
- Tsioli, V.G., Gouletsou, P.G., Loukopoulos, P., Zavlaris, M., Galatos, A.D. (2011). Uterine leiomyosarcoma and pyometra in a dog. *Journal of Small Animal Practice* 52, 121-124.
- Venkateswaran, I. (2008). Cytology of soft tissue tumors: Benign soft tissue tumors including reactive, nonneoplastic lesions. *Journal of Cytology* 25, 81-86.
- Viehoff, F.W., Sjollem, B.E. (2003). Hydrocolpos in dogs: surgical treatment in two cases. *Journal of Small Animal Practice* 44, 404-407.
- Weissman, A., Jimenez, D., Torres, B., Cornell, K., Holmes, S.P. (2013). Canine vaginal leiomyoma diagnosed by CT vaginourethrography. *Journal of the American Animal Hospital Association* 49, 394-397.
- Yap, F.W., Huizing, X.B., Rasotto, R., Bowlt-Blacklock, K.L. (2017). Primary ureteral leiomyosarcoma in a dog. *Australian Veterinary Journal* 95, 68-71.

Uit het verleden

### LEUVENS STADSBESTUUR WAAKT OVER VLEESKWALITEIT (1467)

In de middeleeuwse steden was de verkoop van vlees strak gereguleerd. Verkoop was enkel toegelaten in de vleeshallen (vleeshuizen) door (mannelijke) leden van het vleeshouwersambacht. Maar daarnaast bestond er ook een informeel verkoopcircuit voor minderwaardige vleesproducten in penshuisjes en in achterstraatjes in open lucht of in publieke gelegenheden. De verkoop gebeurde er zowel door de leden van het ambacht als door hun vrouwen. Blijkbaar kon er daar wel een en ander mislopen. Bedenk ook dat er geen koeling bestond. Daarom verbood bijvoorbeeld de Leuvense stadsraad in 1467 aan de vleeshouwers en hun gezinnen vlees dat na drie dagen niet verkocht was in de vleeshalle, te koop aan te bieden in de achterstraatjes rond de vleeshalle, in herbergen en tavernen.

‘Op die manier vermeed de stadsraad dat vlees van mindere kwaliteit tegen een dump prijs werd verkocht en bewaakte ze de hygiëne in de stad.’ Zo lezen we bij Haemers, J., Bardyn, A., Delameilleure, Ch. (2019). *Wijvenwereld. Vrouwen in de middeleeuwse stad*, Vrijdag, Antwerpen, p. 139.

Luc Devriese