

## Concurrent squamous cell carcinoma and hemangiosarcoma in the cornea of a cat

*Het gelijktijdig voorkomen van een plaveiselcelcarcinoom en hemangiosarcoom in de cornea bij een kat*

<sup>1</sup>G. Storms, <sup>2</sup>C. Naranjo, <sup>1</sup>M. Grauwels

<sup>1</sup>Department of Clinical Sciences, Ophthalmology, Veterinary Teaching Hospital, University of Liège, Quartier Vallée 2, Avenue de Cureghem 3, B-4000 Liège, Belgium

<sup>2</sup>Hospital Clinico Veterinario, Universidad Complutense de Madrid, Avda. Puerta del Hierro s/n, Madrid, Spain

goedelestorms@gmail.com

### ABSTRACT

A 14-year-old, female, spayed Domestic Shorthair cat was presented for evaluation of a dark red mass occupying about 75% of the cornea of the left eye. Furthermore, the eye presented upper eyelid trichiasis, lower eyelid entropion and a marked symblepharon. The fellow eye presented upper eyelid trichiasis, lower eyelid entropion, extensive symblepharon and chronic stromal ulcerative keratitis. Based on the results of a corneal biopsy of the left eye, a corneal squamous cell carcinoma was diagnosed and an enucleation was performed subsequently. Histopathology of the globe revealed the presence of variably sized, vascular-like, blood-filled channels in the superficial corneal stroma, lined by spindle cells. In the central cornea, a markedly hyperplastic epithelium was noticed with infiltration of atypical corneal epithelial cells into the superficial stroma. A primary corneal hemangiosarcoma associated with a primary corneal squamous cell carcinoma was diagnosed. In this case report, the rare presence of multiple primary neoplasms within the same anatomical structure is described.

### SAMENVATTING

Een veertien jaar oude, vrouwelijke, gesteriliseerde huiskat werd aangeboden omwille van een uitgesproken donker roodverkleuring van de cornea van het linkeroog. Het oog vertoonde eveneens trichiasis van het bovenooglid, entropion van het onderooglid en een uitgesproken symblefaron. Het rechteroog vertoonde trichiasis van het bovenooglid, entropion van het onderooglid, een uitgesproken symblefaron en chronische stromale en ulceratieve keratitis. Aan de hand van een biopsie van de cornea van het linkeroog werd een plaveiselcelcarcinoom gediagnosticeerd en het linkeroog werd vervolgens weggenomen. Histologisch onderzoek van de cornea toonde met bloed gevulde kanaalvormige structuren van verschillende grootte, die op bloedvaten geleken en afgelijnd waren door spindelvormige cellen. In het centrale deel van de cornea was een uitgesproken hyperplastisch epitheel aanwezig met infiltratie van atypische cornea-epitheelcellen in het oppervlakkige stroma. Zowel een primair hemangiosarcoom als een primair plaveiselcelcarcinoom in de cornea werd gediagnosticeerd. In deze casuïstiek wordt het zeldzame voorkomen van meerdere primaire tumoren in dezelfde anatomische structuur beschreven.

### INTRODUCTION

Neoplasms affecting the cornea are rare in dogs and cats, and usually occur secondary to extension of a conjunctival, limbal or intraocular tumor (Fischer et al., 2002).

Squamous cell carcinoma (SCC) is a malignant neoplasm, locally invasive with metastasis occurring

late in the disease. In cats, ocular SCC involves most commonly the eyelids and the conjunctiva with secondary involvement of the cornea. White cats are predisposed, likely due to the effects of solar radiation (Stiles, 2013).

Ocular tumors of vascular origin are rarely described in cats. Hemangiomas and hemangiosarcomas have been reported on the eyelids, conjunctiva, nictitating

membrane and cornea (Multari et al., 2002; Pirie and Dubielzig, 2006; Hartley et al., 2007; Perlmann et al., 2010; Cazalot et al., 2011).

The presence of multiple primary neoplasms within the same anatomical structure is rare. At the level of the eye and periocular structures, two cases of multiple primary neoplasms have been reported. In a domestic short-haired cat, a co-existing SCC and hemangioma affecting the ocular surface have been described (Perlmann et al., 2010) and Gearhart et al. (2007) reported the concurrent presence of a SCC and hemangiosarcoma in the third eyelid of a Belgian draft horse.

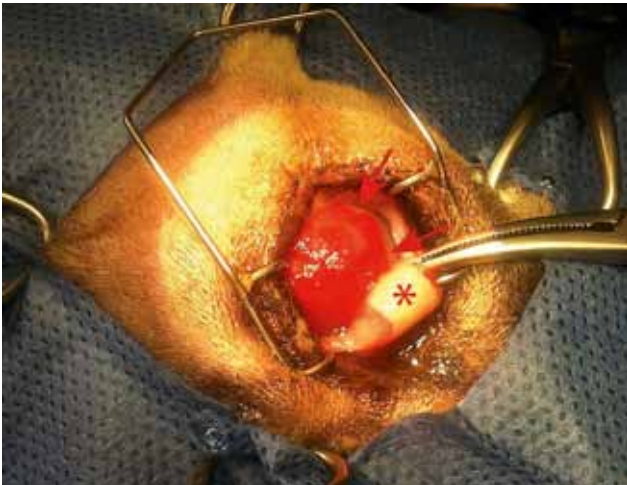
## CASE REPORT

A 14-year-old, female spayed, grey-colored Domestic Shorthair cat (DSH) was presented for a red mass on the cornea of the left eye. Five years ago, the cornea started to become whitish, changing to red

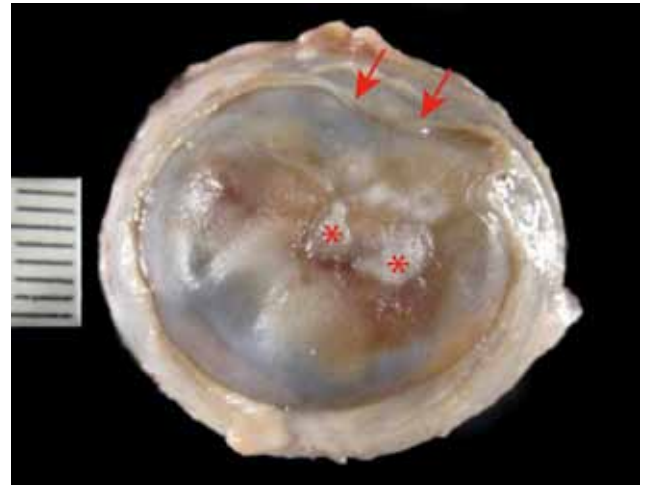
over the past two years. Since two weeks, the right eye had started to show a discrete white corneal coloration as well. The owner reported no signs of ocular discomfort. However, he noticed marked visual impairment. The cat had a lifelong history of chronic respiratory problems and bilateral ocular discharge. The cat was living outdoors in a multi-cat household and had been vaccinated up to the age of five years.

Physical examination revealed a mild inspiratory stridor. In both eyes, the menace response was absent, dazzle and oculopalpebral reflexes were normal. Direct and consensual pupillary light reflexes were hardly assessable because of the corneal lesions.

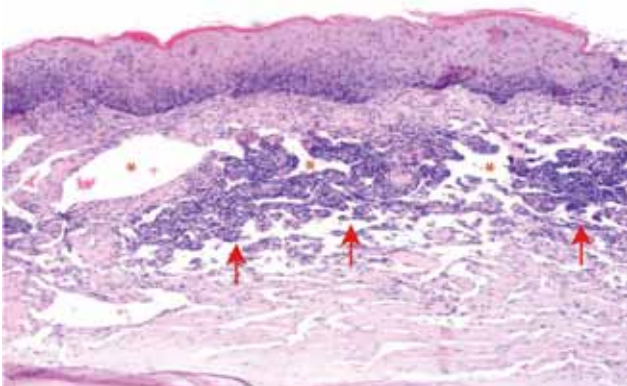
The left eye showed blepharospasm, mucopurulent ocular discharge, upper eyelid trichiasis and lower eyelid entropion. The Schirmer tear test I (STT, Standardized Sterile Strips, Intervet, Summit, NJ, USA) was 9 mm/min. Slit lamp biomicroscopy (SL-15 portable slit lamp, Kowa company Ltd., Düsseldorf, Germany) revealed conjunctival hyperemia, extensive symblepharon and lymphoid follicles on



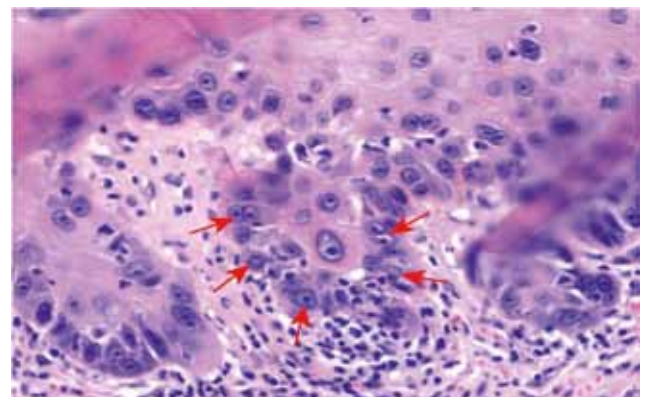
**Figure 1.** Red corneal mass (arrows) with superficial peripheral neovascularization. Notice the iatrogenic folded cartilage of the nictitating membrane (asterisk) as a result of positioning the eye for surgery and the eyelid sutures of the previous entropion correction.



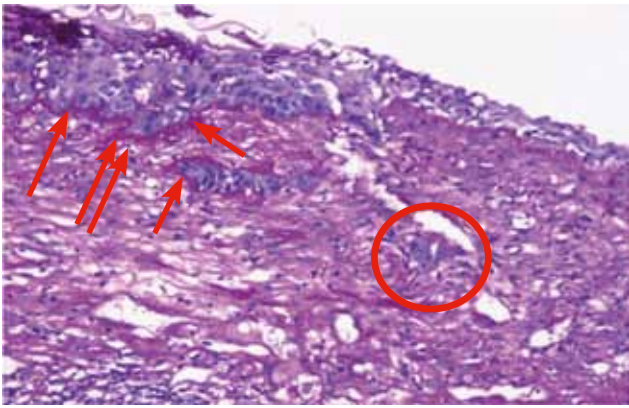
**Figure 2.** Gross section of the left globe. There is a slightly umbilicated, roughened region in the (para)central cornea (asterisks) with a halo of dark brown pigment surrounding it. Notice the adhesion of the dorsal bulbar conjunctiva to the peripheral cornea (arrows).



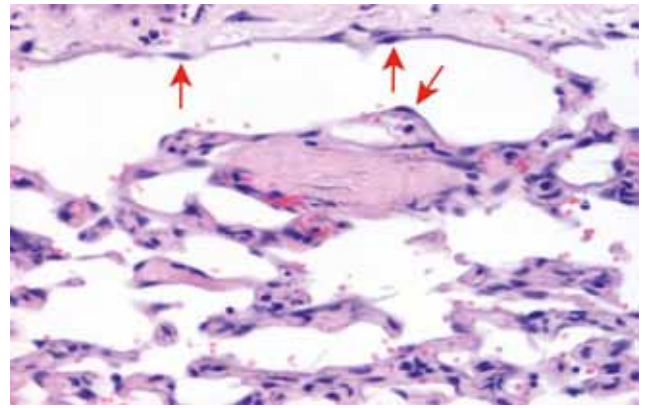
**Figure 3.** Hyperplastic and dysplastic epithelium of the axial cornea with keratinization. Stroma contains hemangiosarcoma (asterisks) and lymphoplasmacytic infiltrates (arrows) and fibrosis. (H&E, x 4)



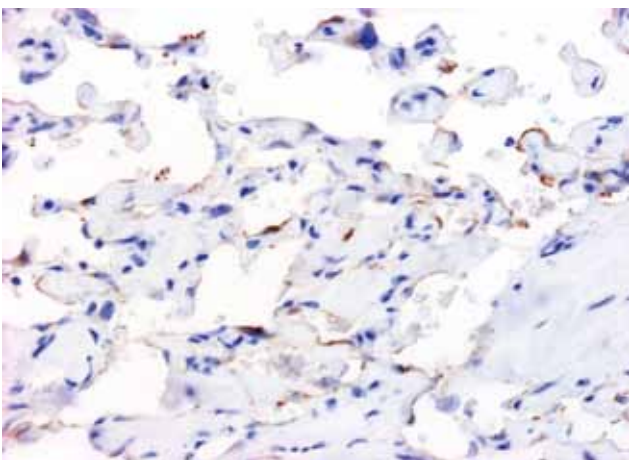
**Figure 4.** Higher magnification of the axial cornea: areas of epithelium with robust rete ridges and prominent dysplastic features (arrows). (H&E, x 20)



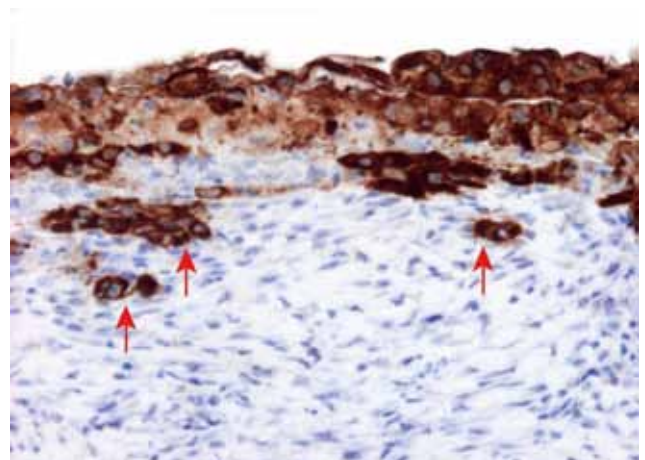
**Figure 5.** The epithelial basement membrane was thickened throughout the central cornea. Aggregates of atypical epithelial cells (circle) have broken through the basement membrane (arrows). (PAS, x 10)



**Figure 6.** Hemangiosarcoma in the intermediate third of the axial stroma, consisting of vascular-like, blood-filled channels lined by a single layer of spindle cells (arrows). (H&E, x 10)



**Figure 7.** Spindle cells lining the vascular-like channels in the corneal stroma stained for factor VIII. (Factor VIII immunohistochemistry, x 200)



**Figure 8.** Pancytokeratin immunohistochemistry revealed individual and small aggregates of cytokeratin-positive cells that had broken through the basement membrane with invasion of the superficial corneal stroma (arrows). (Pancytokeratin immunohistochemistry, x 200)

the inner face of the nictitating membrane. The symblepharon involved the third eyelid and both the palpebral and bulbar conjunctiva, as well as adhesion of the bulbar conjunctiva on the superior peripheral corneal surface. A smooth, red, raised mass occupied at least 75% of the central cornea with superficial peripheral corneal neovascularization (Figure 1). The intraocular structures were not interpretable because of the corneal lesions.

The right eye showed upper eyelid trichiasis, lower eyelid entropion, conjunctival hyperemia, extensive symblepharon and chronic stromal ulcerative keratitis with a STT I of 8 mm/min.

Diffuse punctate fluorescein uptake was present on both corneal surfaces. Differential diagnosis for the red corneal mass included hemangioma, hemangiosarcoma, SCC, inflammatory granuloma, foreign body granuloma and non-specific chronic keratitis.

Hematology and complete blood count revealed a slight neutrophilia and slight increase in urea. PCR for feline herpes virus type I, *Chlamydomphila felis*, feline calicivirus and *Mycoplasma* species as well as ocular ultrasound, thorax radiographs and nasal endo-

scopy were declined by the owner because of financial limitations.

Under general anesthesia, a 3 mm-punch biopsy was taken of the red mass together with entropion correction using the Celsus-Hotz procedure and electrolysis of the eyelid trichiasis.

The biopsy was fixed in 10% formalin, routinely processed and paraffin-embedded. Sections were stained with hematoxylin and eosin (H&E). Histopathological examination revealed pleomorphic polygonal cells with prominent and irregular nucleoli and anisokaryosis. The epithelial basement membrane was thickened and the corneal stroma showed neovascularization and infiltration by neutrophils, lymphocytes and plasma cells. Corneal SCC was diagnosed.

Based on these results, a transpalpebral enucleation was performed. The eye was routinely fixed and processed (Figure 2).

Microscopically, the corneal epithelium was markedly hyperplastic in the axial region with prominent keratinization (Figures 3 and 4). On deeper sections,

dysplastic corneal epithelial cells were noted infiltrating the superficial stroma beyond the basement membrane (Figure 5). These cells showed atypical cytological features, including hypereosinophilic cytoplasm, binucleation and a prominent, round, magenta nucleolus.

The intermediate third of the axial stroma contained variably sized, anastomosing, vascular-like, blood-filled channels lined by a single layer of spindle cells with moderately atypical features (Figures 3 and 6). Anisocytosis and anisokaryosis were moderate and no mitotic figures were noted in ten high power fields.

In the paracentral aspect of the cornea, adjacent to the hyperplastic/dysplastic epithelium, there was a focal area of stroma that was not covered by epithelium (ulcer). The peripheral cornea showed a markedly attenuated epithelium and the superficial stroma showed neovascularization with reactive (not atypical) blood vessels, fibrosis and a moderate lymphoplasmacytic and neutrophilic infiltrate. The mid and deep peripheral corneal stroma showed no significant microscopic changes.

No significant microscopic changes were noticed in the remaining ocular structures. Immunohistochemistry for factor VIII and pancytokeratin was performed (Figures 7 and 8).

Based on histology, corneal hemangiosarcoma and incipient SCC of the left eye were diagnosed, as well as a severe, chronic, ulcerative keratitis.

Six months postoperatively, the cat was euthanized by the referring veterinarian because of a suspicion of corneal perforation of the right eye. No systemic clinical signs had been noticed by the owner and no necropsy or histological examination of the right eye was performed.

## DISCUSSION

The presence of two different neoplastic processes within the same tissue and without invasion of adjacent ocular structures is rare. Perlmann (2010) reported a hemangioma and SCC on the ocular surface in a cat; however, the primary tumor origin was unknown. This is in contrast to the present case report, where both tumors were malignant and of corneal origin.

To the authors' knowledge, only one case of feline primary corneal hemangiosarcoma has been reported (Cazalot et al., 2011). Similar to the current case, a very longstanding corneal inflammation was described. Cazalot (2011) suggested that the newly formed corneal blood vessels present during inflammation provided the endothelial cells that were at the origin of this tumor. It has been shown that damage to vascular endothelial cells may lead to dysregulation of angiogenesis and erythropoiesis with release of angiogenic growth factors and cytokines. This may lead to proliferation of endothelial cells and development

of hemangiosarcoma (Moyer et al., 2004; Cohen et al., 2009). In the present case report, reactive blood vessels were found in the peripheral cornea blending in with the hemangiosarcoma, suggesting that these may have been at the origin of this neoplasm.

Feline corneolimbic squamous cell carcinoma associated with intraocular invasion has been reported in two cats (Scurrall et al., 2013). Scurrall et al. suggested that the limbus was the most likely origin of the SCC in both cats since the limbus is rich in stem cells and these cells are considered to be the source of most neoplasms (Scurrall et al., 2013). This is in contrast to the present case report, where no limbal or intraocular invasion of the SCC was found on histopathology.

The cat in the current case report was a 14-year-old, female, spayed, grey-colored DSH. The average age of cats with conjunctival hemangiomas and hemangiosarcomas is 10.6 years, and the DSH and neutered males are over-represented (Pirie and Dubielzig, 2006). SCC is mostly seen in older cats (10-12 years) and although any breed and sex can be affected, white cats are at greatest risk (Murphy, 2013).

The cat in the study of Perlmann (2010), which presented with a hemangioma and SCC on the ocular surface, was an indoor cat with minimal sun exposure, whereas the cat of this case report was an outdoor cat. UV radiation has been proposed as a risk factor for the development of both hemangiosarcoma and SCC (Dorn et al., 1971; Murphy, 2013). DNA damage may be produced by UV radiation either directly or through reactive oxygen species (Rodust et al., 2009). Both in SCC and hemangiosarcoma, mutations caused by UV radiation may lead to neoplastic development due to the activation of oncogenes and inactivation of tumor suppressor genes including p53 (Matsumura and Ananthaswamy, 2002; Rodust et al., 2009). Because chronic sun exposure is an important risk factor, hemangiosarcomas occur most often at the nonpigmented leading edge of the nictitating membrane and on sites of the conjunctiva with the greatest exposure to UV radiation (Pirie and Dubielzig, 2006). Similarly for SCC, this lesion is mainly seen in white cats or on the non-pigmented skin and conjunctiva in colored cats (Murphy, 2013).

Chronic keratoconjunctivitis was histologically confirmed in this cat without identification of the exact etiology. Causes of keratoconjunctivitis in cats include eyelid abnormalities (eyelid agenesis, entropion, trichiasis), infectious causes (feline herpes virus I, *Chlamyodphila felis*, feline calicivirus, *Mycoplasma* species), neoplasia, eosinophilic keratoconjunctivitis and less frequently keratoconjunctivitis sicca (Stiles, 2013).

In dogs, chronic inflammatory conditions of the cornea and chronic topical immunosuppressive therapy have been reported as risk factors for the development of primary corneal SCC (Dreyfus et al., 2011). An increase in cellular proliferation and inflammatory

signals was proposed to increase the likelihood of SCC (Dreyfus et al., 2011). In human medicine, chronic inflammation has been well identified as an important driving force for the development of neoplasia through multiple mechanisms including induction of genomic instability, inappropriate gene expression, enhanced proliferation of initiated cells, resistance to apoptosis, aggressive tumor neovascularization and damage to DNA, proteins and lipids by inflammation-induced reactive oxygen and nitrogen species (Kundu and Surh, 2008).

The presence of metastasis was unknown in this case. No signs of local recurrence or metastasis were reported in both case reports on corneal hemangioma and hemangiosarcoma, eight and 18 months following enucleation, respectively (Perlmann et al., 2010; Cazalot et al., 2011).

In conclusion, SCC involving the cornea without conjunctival or eyelid invasion is rare and should be included in the differential diagnosis for chronic keratitis not responding to symptomatic treatment. The possibility of multiple tumors should be taken into account when interpreting superficial corneal biopsies.

## REFERENCES

- Cazalot G., Regnier A., Deviers A., Serra F., Lucas M.N., Etienne C.L., Letron I.R. (2011). Corneal hemangiosarcoma in a cat. *Veterinary Ophthalmology 14 (Suppl 1)*, 117-1121.
- Cohen S.M., Storer R.D., Criswell K.A., Doerrer N.G., Dellarco V.L., Pegg D.G., Wojcinski Z.W., Malarkey D.E., Jacobs A.C., Klaunig J.E., Swenberg J.A., Cook J.C. (2009). Hemangiosarcoma in rodents: mode-of-action evaluation and human relevance. *Toxicological Sciences 111*, 4-18.
- Dorn C.R., Taylor D.O., Schneider R. (1971). Sunlight exposure and risk of developing cutaneous and oral squamous cell carcinoma in white cats. *Journal of the National Cancer Institute 46*, 1073-1078.
- Dreyfus J., Schobert C.S., Dubielzig R.R. (2011). Superficial corneal squamous cell carcinoma occurring in dogs with chronic keratitis. *Veterinary Ophthalmology 14*, 161-168.
- Gearhart P.M., Steficek B.A., Petersen-Jones S.M. (2007). Hemangiosarcoma and squamous cell carcinoma in the third eyelid of a horse. *Veterinary Ophthalmology 10*, 121-126.
- Hartley C., Ladlow J., Smith K.C. (2007). Cutaneous haemangiosarcoma of the lower eyelid in an elderly white cat. *Journal of Feline Medicine and Surgery 9*, 78-81.
- Kundu J.K., Surh Y.J. (2008). Inflammation: gearing the journey to cancer. *Mutation Research 659*, 15-30.
- Matsumura Y., Ananthaswamy H.N. (2002). Molecular mechanisms of photocarcinogenesis. *Frontiers in Bioscience 7*, 765-783.
- Moyer C., Allen D., Basabe A., Maronpot R.R., Nyska A. (2004). Analysis of vascular endothelial growth factor (VEGF) and a receptor subtype (KDR/flk-1) in the liver of rats exposed to riddelliine: a potential role in the development of hemangiosarcoma. *Experimental and Toxicological Pathology 55*, 455-465.
- Multari D., Vascellari M., Mutinelli F. (2002). Hemangiosarcoma of the third eyelid in a cat. *Veterinary Ophthalmology 5*, 273-276.
- Murphy S. (2013). Cutaneous squamous cell carcinoma in the cat: current understanding and treatment approaches. *Journal of Feline Medicine and Surgery 15*, 401-407.
- Fischer C.A., Lindley D.M., Carlton W.C., Van Hecke H. (2002). Tumors of the Cornea and Sclera. In: Peiffer R.L.Jr., Simons K.B. (editors). *Ocular tumors in Animals and Humans*. First edition, Iowa State Press, Iowa, p. 149-202.
- Perlmann E., Da Silva E.G., Guedes P.M., Barros P.S. (2010). Co-existing squamous cell carcinoma and hemangioma on the ocular surface of a cat. *Veterinary Ophthalmology 13*, 63-66.
- Pirie C.G., Dubielzig R.R. (2006). Feline conjunctival hemangioma and hemangiosarcoma: a retrospective evaluation of eight cases (1993-2004). *Veterinary Ophthalmology 9*, 227-231.
- Rodust P.M., Stockfleth E., Ulrich C., Leverkus M., Eberle J. (2009). UV-induced squamous cell carcinoma - a role for antiapoptotic signalling pathways. *The British Journal of Dermatology 161 (Suppl 3)*, 107-115.
- Scurrill E.J., Lewin G., Solomons M., Rozmanec M., Belford C.J. (2013). Corneolimbic squamous cell carcinoma with intraocular invasion in two cats. *Veterinary Ophthalmology 16 (Suppl 1)*, 151-154.
- Stiles J. (2013). Feline ophthalmology. In: Gelatt K.N., Gilger B.G., Kern T.J. (editors). *Veterinary Ophthalmology*. Fifth edition, Wiley-Blackwell, Iowa, p. 1477-1559.