

## Cutaneous neosporosis in an adult dog in Belgium

### *Cutane neosporose bij een volwassen hond in België*

<sup>1</sup>T. De Schuyter, <sup>2</sup>H.E.V. De Cock, <sup>1</sup>P. Lemmens

<sup>1</sup>Dierenartsenpraktijk Plantijn, Bosduifstraat 18-20, 2018 Antwerpen, Belgium

<sup>2</sup>Medvet, Emiel Vloorsstraat 9, 2020 Antwerpen, Belgium

info@dap-plantijn.be

## ABSTRACT

A twelve-year-old female spayed Greyhound was presented with ulcerative nodular lesions, generalized weakness and pain. At the time of presentation, the dog was receiving prednisolone for a presumptive diagnosis of cervical discus hernia. Fine needle aspiration of the nodular lesions demonstrated protozoal tachyzoites. Immunohistochemistry confirmed the diagnosis of *Neospora caninum* infection. Clindamycin therapy, together with the withdrawal of immunosuppressive medication, resulted in complete remission. This report documents the first case of cutaneous neosporosis in Belgium.

## SAMENVATTING

Een twaalf jaar oude, vrouwelijke, gesteriliseerde greyhound werd aangeboden met ulceratieve nodulaire letsels, algemene zwakte en pijn. De hond werd op dat moment behandeld met prednisolone voor een vermoedelijke diagnose van cervicale discus hernia. Op het microscopisch onderzoek van een fijne naaldaspiratie-biopt van de nodulaire letsels werden protozoaire tachyzoïeten gezien. Het immunohistochemisch onderzoek bevestigde de diagnose van *Neospora caninum*-infectie. Een behandeling met clindamycine en de stopzetting van een immunosuppressieve behandeling leidden tot volledig herstel. Dit artikel beschrijft het eerste geval van cutane neosporose in België.

## INTRODUCTION

*Neospora caninum* is a protozoan of the phylum Apicomplexa first described in 1988 (Dubey et al., 1988). The dog has been identified as both an intermediate and definitive host to the parasite, and sheds oocysts in the faeces following the ingestion of *N. caninum*-infected tissues. Although dogs can be infected by the ingestion of contaminated tissues, the predominant route of transmission is considered to be transplacental. Herbivores are intermediate hosts, and likely become infected by ingesting oocysts shed by the definitive host or by subclinical congenital infection. *Neospora* infection is an important cause of abortion and infertility in cattle (Dubey and Lappin, 2006).

Naturally infected dogs have been reported worldwide (Dubey and Lappin, 2006). In a Belgian survey, 11 % of the dogs were seropositive, at titers of 1:50 to 1:800, with increasing seropositivity with age (Barber et al., 1997).

Dogs of any age can be infected, but the most severe and most frequent infections occur in young dogs (under six months of age). These puppies

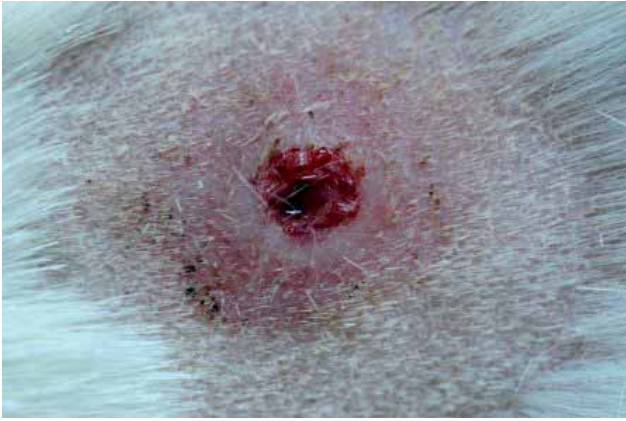show neurological signs characterized by ascending paralysis of the limbs, with the pelvic limbs more affected than the thoracic limbs (Lavelly, 2006). Older dogs most likely become ill from reactivation of a chronic subclinical infection. They often have signs of multifocal central nervous system involvement with or without polymyositis. Less common manifestations are myocarditis, dermatitis, pneumonia, hepatitis or multifocal dissemination (Scott et al., 2001; Dubey and Lappin, 2006).

Infection of *Neospora* restricted to the skin is rare (Dubey et al., 1988; Dubey et al., 1995; Fritz et al., 1997; Perl et al., 1998; Poli et al., 1998; La Perle et al., 2001; Tarantino et al., 2001; Ordeix et al., 2002; Boyd et al., 2005; Gupta et al., 2011).

This article describes nodular dermatitis caused by a *Neospora caninum* infection in an adult Greyhound.

## CASE REPORT

An approximately twelve-year old, female, spayed Greyhound was presented with symptoms of acute neck pain. The dog was imported from Spain to Bel-



**Figure 1. Nodular skin lesion secondary to *Neospora caninum* infection in the dorsal neck of the dog.**

gium seven years ago. One hour before presentation, the owner noticed that the dog started shaking, had difficulties in walking and keeping her balance. The physical examination was normal except for severe pain while moving the head. The neurological examination was normal. A presumptive diagnosis of cervical discus hernia was made, and treatment with prednisolone (Prednisolone, Kela) (1mg/kg/day) and tramadol (Contramal Retard 50 mg, Grünenthal) (2 mg/kg bid) was started.

Three weeks later, the owner returned to the clinic because the dog showed no significant improvement, lost weight and showed skin lesions. On physical examination, the dog had weight loss, generalized muscle atrophy and a stiff gait. Pain was noted on palpation of the muscles in the cervical and shoulder region. Two ulcerated cutaneous nodules were visible: one in the dorsal neck (Figure 1) and one on the lateral side of the right stifle.

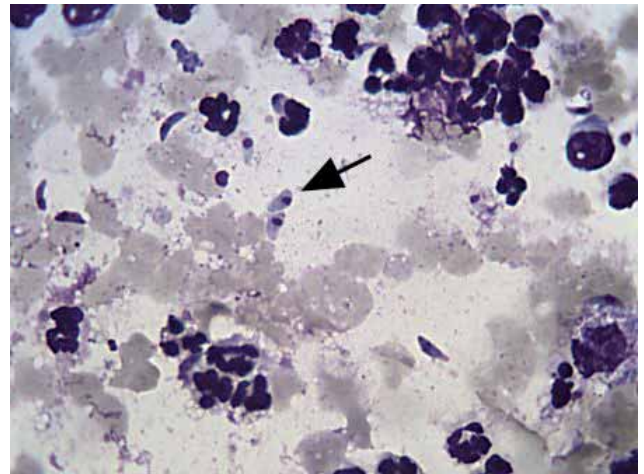
Blood samples for a complete blood count (CBC) were analyzed with an automated hematology analyzer (Sysmex pocH-100iV Diff), and the biochemical profile was analyzed with a Fuji Dry Chem clinical chemistry analyzer (Fuji Dri-Chem 3500i). The CBC was within limits. Biochemistry revealed a marked elevation of the alanine aminotransferase (ALT) (800 U/liter, reference range 17 to 78 U/liter) and aspartate aminotransferase (AST) (373 U/liter, reference range 17 to 44 U/liter), a mild elevation of gamma-glutamyltransferase (GGT) (45 U/liter, reference range 5 to 14 U/liter) and a highly elevated creatinine kinase (CK) (> 2000 U/liter, reference range 49 to 166 U/liter). No other abnormalities were found.

The direct agglutination assay for *Leishmania spp.* was negative. The indirect fluorescent antibody test (IFAT) was positive for *Neospora* at a dilution of 1/80 (reference range: negative at < 1/50 screening dilution) (MegaScreen® Fluoneospora c. ad us. vet.; Diagnostik Megacor, Austria).

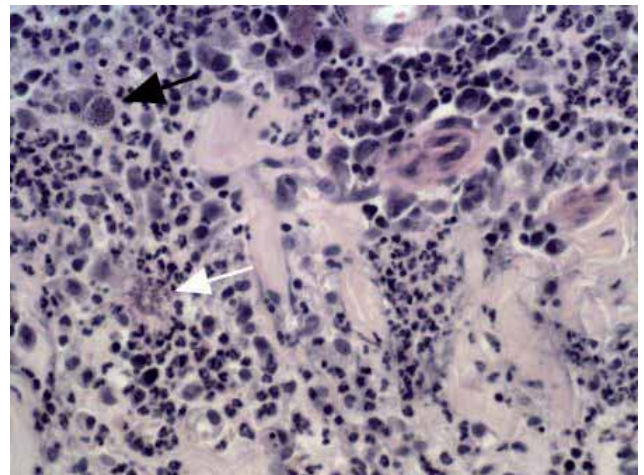
No significant abnormalities were found on ultrasonographic examination of the abdomen. The radiographs of the thorax and abdomen were normal. A fine needle aspiration of the cutaneous nodule in

the dorsal neck was performed, and revealed a mainly neutrophilic inflammation with multiple extracellular curvilinear tachyzoites with an apical nucleus (Figure 2). This nodule was surgically removed, fixed in 10 % buffered formalin solution and routinely processed for microscopic examination with hematoxylin and eosin stain (H&E).

Histopathologic diagnosis of the skin lesion revealed locally extensive pyogranulomatous dermatitis and panniculitis with intralesional tachyzoites and tissue cysts compatible with an apicomplexan protozoal parasite (Figure 3). Immunohistochemical staining with anti-*Toxoplasma* antibodies remained negative (Veterinary Medical Teaching Hospital (VMTH) of the University of Davis, USA), and cysts stained positive with anti-*Neospora* antibodies (VMTH, Davis, USA).



**Figure 2. Cytology of the nodular skin lesion in the dorsal neck of the dog. Mixed inflammatory infiltrate admixed with numerous extracellular curvilinear tachyzoites with an apical nucleus (arrow); Diff Quick stain, 100x.**



**Figure 3. Histopathology of the nodular skin lesion. Pyogranulomatous inflammation of dermis with intralesional tachyzoites (white arrow) and tissue cysts (black arrow); H&E, 1000x.**

The prednisolone and tramadol therapy were discontinued. Therapy with clindamycin hydrochloride (Clindabuc, CEVA) (20 mg/kg bid) was started. Carprofen (Rimadyl, Pfizer) (4 mg/kg/day) was added to treat the generalized pain and inflammation. Two weeks later, the owner noticed a marked improvement: the dog had a normal posture and gait. The nodule on the right stifle had disappeared. There was a significant decrease in ALT (328 U/liter), AST (96 U/liter) and CK (1106 U/liter). The physical examination was normal, and no pain reaction could be elicited. Another two weeks later, the liver enzymes normalized, but the CK activity (213 U/liter) was still marginally elevated. Therapy with clindamycin was continued for another two weeks, and then stopped. Four months later, the Greyhound was still in good health. Liver enzymes and CK were within normal limits.

## DISCUSSION

Cutaneous neosporosis has been reported in eleven dogs which resided in the United States, France, Israel, Italy, Spain and the United Kingdom. To the authors' knowledge, this is the first report of cutaneous neosporosis in Belgium. The age of the eleven affected dogs ranged from sixteen weeks to fifteen years. Only two of these dogs were younger than four years of age. Most of them had concurrent disease or were treated with immunosuppressive drugs (Dubey et al., 1988; Dubey et al., 1995; Fritz et al., 1997; Perl et al., 1998; Poli et al., 1998; La Perle et al., 2001; Tarantino et al., 2001; Ordeix et al., 2002; Boyd et al., 2005; Gupta et al., 2011). Likewise, the dog reported here was on immunosuppressive therapy before the development of cutaneous neosporosis.

Tachyzoites can be found in aspirates or smears from any parasitized tissue or body fluid (Dubey and Lappin, 2006). The differential diagnosis for protozoal dermatitis in dogs include *Leishmania infantum*, *Caryospora spp.*, *Neospora caninum*, *Toxoplasma gondii* and *Sarcocystis spp.* infections (Dubey et al., 1995). Due to the similar morphology in cytopathological smears and H&E stained sections, *N. caninum* must be distinguished from *T. gondii* by immunohistochemical staining or electron microscopy (Dubey and Lappin, 2006). In the present case, the diagnosis was initially made on cytological examination of lesional aspirates, and confirmed by histopathology and immunohistochemistry.

Demonstrating serum antibodies to *N. caninum* may help to confirm the diagnosis of neosporosis (Dubey and Lappin, 2006). In most cases, clinical neosporosis produces IFAT titers higher than or equal to 1:800 (Barber and Trees, 1996). Previously exposed dogs that may be infected, but that remain asymptomatic, may have similar titers for several years (Dubey and Lappin, 2006). The IFAT titers in reported dogs with cutaneous neosporosis ranged from 1:640 to 1:12800 (Fritz et al., 1997; Poli et al., 1998). The

immunofluorescent antibody test for *Neospora* in the dog of the present case was positive at a relative low dilution of 1:80. Occasionally, animals with histologically verified infections have low titer results (Dubey and Lappin, 2006).

Predominant increases in the activities of the hepatocellular leakage enzymes ALT and AST occur with circulatory disturbances, hepatotoxicities, infectious diseases, hepatitis and neoplasia. ALT is primarily found in the cytosol of hepatocytes, and is released into the circulation after hepatocellular membrane disruption. AST is found in the cytosol and mitochondria of hepatocytes and myocytes, and therefore, an increase in AST activity can be caused by hepatic and/or muscle damage. The activities of the membrane-bound enzymes GGT and ALP (alkaline phosphatase) are increased with intra- and extra-hepatic cholestasis (Alvarez and Whittemore, 2009). The activity of the muscle enzyme CK is increased to varying degrees with muscle necrosis secondary to inflammatory myopathies (Podell, 2002).

In the present case, there was a ten-fold increase of the AST and ALT activity. There was no increase of the ALP activity and only a mild increase of the GGT activity. This liver enzyme pattern indicates hepatocellular damage or necrosis. There was also a more than ten-fold increase of the CK activity. All abnormalities returned to normal after therapy with clindamycin. Although there were no muscle or liver biopsies taken, it is very likely that both liver and muscles were involved in a systemic infection with *N. caninum*.

Although CK has a shorter half-life (two to three hours) (Podell, 2002) than the half-life of ALT (two to three days) (Alvarez and Whittemore, 2009), it took longer for the CK activity to normalize than the ALT activity in the dog of the present case. A possible explanation could be that the inflammation of the muscles was more extensive than the inflammation of the liver.

Clindamycin, sulfadiazine and pyrimethamine alone or in combination are used to treat canine neosporosis. Dermatitis and myositis respond well to clindamycin. Clindamycin is effective in suppressing the replication and dissemination of tachyzoites but does not appear to be effective against encysted bradyzoites (Dubey and Lappin, 2006). Eight of the eleven dogs previously reported with cutaneous neosporosis either died or were euthanized, but five of the eleven dogs showed clinical improvement or had resolution of the cutaneous lesions with clindamycin therapy (Dubey et al., 1988; Dubey et al., 1995; Fritz et al., 1997; Perl et al., 1998; Poli et al., 1998; La Perle et al. 2001; Tarantino et al., 2001; Ordeix et al., 2002; Boyd et al., 2005; Gupta et al., 2011). The dog of the present case was treated with clindamycin for six weeks, and recovered completely.

To prevent infection, dogs should not be fed raw meat (especially beef) or be allowed to feed on aborted

materials. Breeding with *Neospora*-infected bitches should be avoided (Dubey and Lappin, 2006).

## CONCLUSION

In summary, this report describes a case of cutaneous neosporosis diagnosed by means of cytological examination of lesional aspirates and confirmed by histopathology and immunohistochemistry. The dog responded well to therapy with clindamycin, and remained healthy after the treatment was stopped.

## ACKNOWLEDGEMENTS

The authors would like to thank the staff of the AML-Medvet Pathology Laboratory in Antwerp for the analysis of the samples and the staff of the Veterinary Medical Teaching Hospital of the University of Davis, California for the immunohistochemical analysis.

## REFERENCES

- Alvarez, L., Whittemore, J.C. (2009). Liver enzyme elevations in dogs: physiology and pathophysiology. *Compendium: Continuing Education for Veterinarians* 31, 408-414.
- Barber, J.S., Trees, A.J. (1996). Clinical aspects of 27 cases of neosporosis in dogs. *Veterinary Record* 139, 439-443.
- Barber, J.S., Van Ham, L., Polis, I., Trees, A.J. (1997). Seroprevalence of antibodies to *Neospora caninum* in Belgian dogs. *Journal of Small Animal Practice* 38, 15-16.
- Boyd, S.P., Barr, P.A., Brooks, H.W., Orr, J.P. (2005). Neosporosis in a young dog presenting with dermatitis and neuromuscular signs. *Journal of Small Animal Practice* 46, 85-88.
- Dubey, J.P., Carpenter, J.L., Speer, C.A., Topper, M.J., Uggla, A. (1988). Newly recognized fatal protozoan disease of dogs. *Journal of the American Veterinary Medical Association* 192, 1269-1285.
- Dubey, J.P., Metzger JR, F.L., Hattel, A.L., Lindsay, D.S., Fritz, D.L. (1995). Canine Cutaneous Neosporosis: clinical improvement with clindamycin. *Veterinary Dermatology* 6, 37-43.
- Dubey, J.P., Lappin, M.R. (2006). Toxoplasmosis and Neosporosis. In: Greene C.E. (editor). *Infectious Diseases of the Dog and Cat*. Third edition, W.B. Saunders, Philadelphia. 768-774.
- Fritz, D., George, C., Dubey, J.P., Trees, A.J., Barber J.S., Hopfner, C.L., Mehaut, S., Le Net, J.L., Longeart, L. (1997). *Neospora caninum*: associated nodular dermatitis in a middle-aged dog. *Canine Practice* 22, 21-24.
- Gupta, A., Stroup, S., Dedeaux, A., Bauer, R.W., Gaunt, S.D. (2011). What is your diagnosis? Fine-needle aspirate of ulcerative skin lesions in a dog. *Veterinary Clinical Pathology* 40, 401-402.
- La Perle, K.M.D., Del Piero, F., Carr, R.F., Harris, C., Stromberg, P.C. (2001). Cutaneous neosporosis in two adult dogs on chronic immunosuppressive therapy. *Journal of Veterinary Diagnostic Investigation* 13, 252-255.
- Lavelly, J.A. (2006). Pediatric neurology of the dog and cat. *Veterinary Clinics of North America. Small Animal Practice* 36, 475-501.
- Ordeix, L., Lloret, A., Fondevila, D., Dubey, J.P., Ferrer, L., Fondati, A. (2002). Cutaneous neosporosis during treatment of Pemphigus foliaceus in a dog. *Journal of the American Animal Hospital Association* 38, 415-419.
- Perl, S., Harrus, S., Satuchne, C., Yakobson, B., Haines, D. (1998). Cutaneous neosporosis in a dog in Israël. *Veterinary Parasitology* 79, 257-261.
- Podell, M. (2002). Inflammatory myopathies. *Veterinary Clinics of North America. Small Animal Practice* 32, 147-167.
- Poli, A., Mancianti, F., Carli, M.A., Stroschio, M.C., Kramer, L. (1998). *Neospora caninum* infection in a Bernese cattle dog from Italy. *Veterinary Parasitology* 78, 79-85.
- Scott, D.W., Miller, W.H., Griffin, C.E. (2001). Viral, Rickettsial, and Protozoal skin diseases. In: Scott, D.W., Miller, W.H. and Griffin, C.E. (editors). *Muller & Kirk's Small Animal Dermatology*. 6th Edition, W.B. Saunders, Philadelphia, 517-542.
- Tarantino, C., Rossi, G., Kramer, L.H., Perucci, S., Cringoli, G., Macchioni, G. (2001). *Leishmania infantum* and *Neospora caninum* simultaneous skin infection in a young dog in Italy. *Veterinary Parasitology* 102, 77-83.