

## Ventral rhinotomy to remove a nasopharyngeal polyp that invaded the frontal sinus in a cat

*Ventrale rinotomie ter verwijdering van een nasofaryngeale poliep met extensie in de frontale sinus bij een kat*

<sup>1</sup>R. Jacobs, <sup>1</sup>B. Van Goethem, <sup>2</sup>E. Stock, <sup>3</sup>H. De Cock, <sup>1</sup>T. Bosmans, <sup>1</sup>H. de Rooster

<sup>1</sup>Small Animal Department, Faculty of Veterinary Medicine, Ghent University, Salisburylaan 133, 9820 Merelbeke, Belgium

<sup>2</sup>Department of Medical Imaging of Domestic Animals, Faculty of Veterinary Medicine, Ghent University, Salisburylaan 133, 9820 Merelbeke, Belgium

<sup>3</sup>AML/Veterinary Pathology Services, Emiel Vloorsstraat 9, 2020 Antwerpen, Belgium

bart.vangoethem@ugent.be

### ABSTRACT

A six-year-old, male, castrated European shorthair cat was presented due to a lifelong history of sneezing, nasal discharge, open-mouth breathing, stertor and vestibular problems. Clinical examination showed absence of airflow through the nostrils. Computed tomography of the head revealed an infiltrative soft tissue attenuating mass in the left nasal cavity, nasopharynx and the left frontal sinus. All of these locations could be successfully accessed through ventral rhinotomy and the mass was completely removed. Histological examination identified it as an inflammatory polyp. All respiratory and neurological symptoms disappeared, and two-and-a-half years after surgery, the cat was still without complaints.

### SAMENVATTING

Een zes jaar oude, mannelijke, gecastreerde Europese korthaar werd aangeboden wegens een levenslange voorgeschiedenis van niezen, neusvloeï, open-mondademen, stertor en vestibulaire problemen. Klinisch onderzoek toonde de afwezigheid van luchtstroom aan doorheen de neusgaten. Computertomografie van het hoofd onthulde een infiltratieve wekedelenmassa in de linkerneusholte, nasofarynx en de linker frontale sinus. Deze drie locaties konden succesvol worden bereikt door middel van ventrale rinotomie en de massa werd volledig verwijderd. Via histologisch onderzoek werd de massa geïdentificeerd als een inflammatoire poliep. Alle respiratoire en neurologische symptomen verdwenen en tweeënhalf jaar na de operatie was de kat nog steeds vrij van klachten.

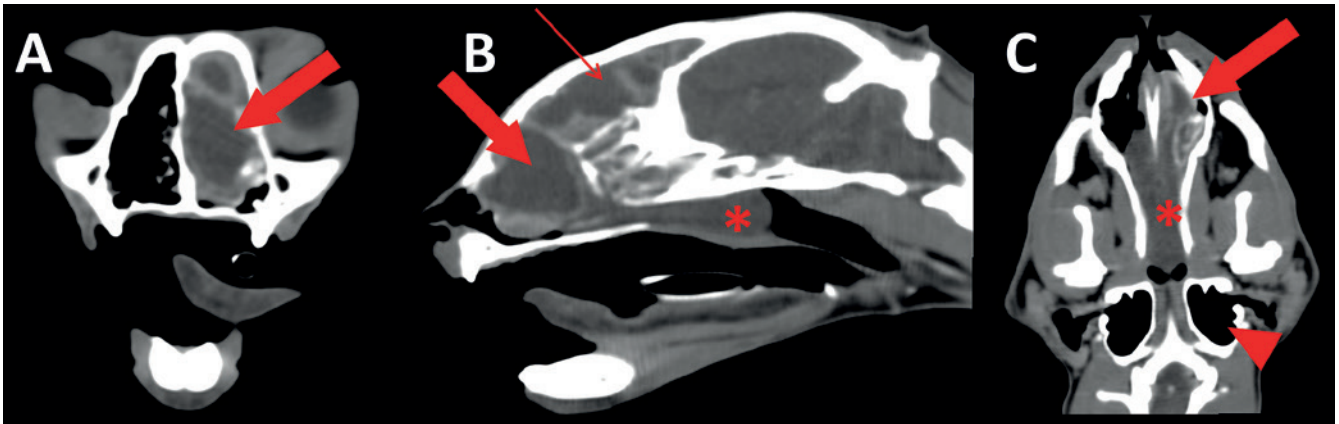
### INTRODUCTION

In cats younger than two years of age, a mass in the nasopharynx is most commonly an inflammatory polyp (Allen et al., 1999). These non-neoplastic growths arise from the lining of the auditory tube or the middle ear (Reed and Gunn-Moore, 2012). They either grow into the tympanic cavity, potentially extending into the ear canal (middle ear polyps) or they grow towards the nasopharynx (nasopharyngeal polyps) (Mullenburg and Fry, 2002; Reed and Gunn-Moore, 2012). Polyps most commonly occur unilaterally, but bilateral nasopharyngeal polyps as well as the combination of a na-

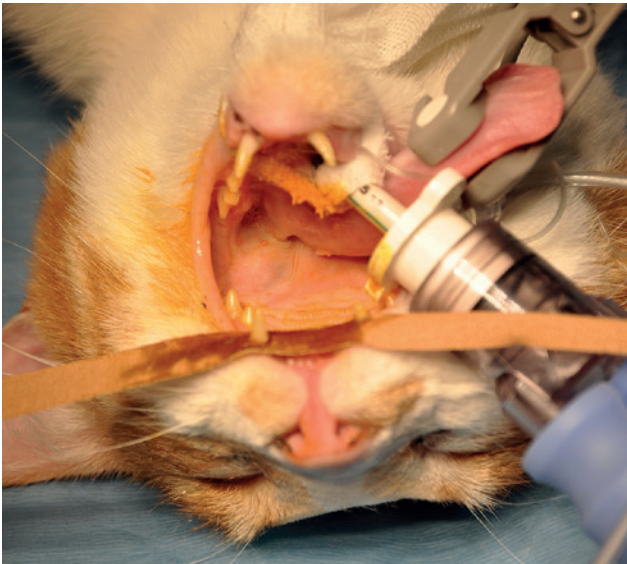
sopharyngeal and an aural polyp have been reported (Mullenburg and Fry, 2002; MacPhail et al., 2007).

Treatment of a nasopharyngeal polyp includes traction avulsion of the polyp from an oral approach, followed by anti-inflammatory medication to decrease mucosal swelling and resolve auditory tube obstruction (Anderson et al., 2000). In rare cases, it is necessary to incise the soft palate for additional surgical exposure (Kudnig, 2002).

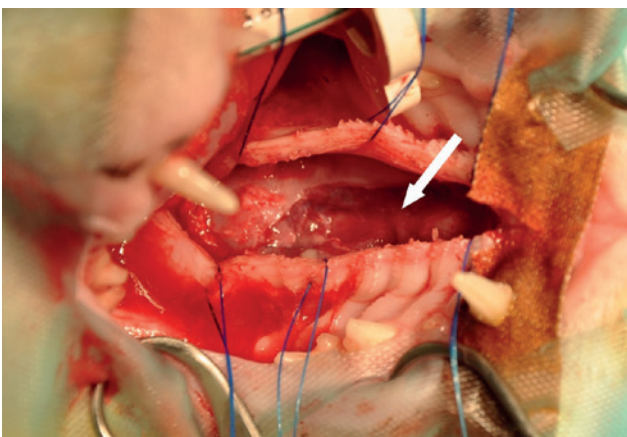
In this case report, a ventral rhinotomy approach is described for a large nasopharyngeal polyp that also filled the left nasal conchae and even extended into the left frontal sinus.



**Figure 1.** CT images of the head. A. Transverse view showing the polyp in the left nasal cavity (large arrow). B. Sagittal view showing the polyp in the left nasal cavity (large arrow), the frontal sinus (small arrow) and the oropharynx (asterisk). C. Dorsal view showing the polyp in the left nasal cavity (large arrow) and the oropharynx (asterisk). Also note the normal air-containing bulla (arrowhead).



**Figure 2.** Patient in dorsal recumbency with the tongue and endotracheal tube lateralized to the right. Submaximal opening of the mouth allowed sufficient access to perform a ventral rhinotomy.



**Figure 3.** After incising the hard palate mucosa in the midline and retracting it with stay sutures, the left palatal bone was partially removed to allow access to the left nasal cavity. This easily revealed the intranasal part of the polyp (arrow).

### CASE HISTORY

A six-year-old, male, castrated European short-hair cat was presented because of a lifelong history of sneezing, chronic intermittent purulent nasal discharge, open-mouth breathing, stertor and partial anorexia. In the past, antibiotics and corticosteroids provided temporary improvement, but recently the anorexia had become problematic.

At general examination, open-mouth breathing and the absence of airflow through the nostrils were obvious. All other clinical parameters were normal. There were no neurological signs and CBC and biochemistry were unremarkable. FIV/FelV testing was negative. Likewise, radiographs of the thoracic cavity and abdomen, abdominal ultrasonography and urine analysis, all performed to identify the cause of the partial anorexia, failed to disclose any pathology. A CT scan of the head was performed and revealed a soft tissue attenuating mass in the nasopharynx. The mass was ill-defined rostrally and extended into the left nasal passage, with destruction of the turbinates, and also grew into the left frontal sinus (Figure 1). There was moderate peripheral ring-like contrast enhancement. A minimal amount of non-contrast enhancing soft tissue attenuating material was present in the left tympanic bulla, the bulla wall was within normal limits. There was no invasion of the cribriform bone and no regional lymphadenopathy.

Rhinoscopic biopsies consisted of a core of loosely fibrovascular tissue bordered by ciliated and partially stratified epithelium, propria edema and neovascularization associated with a diffuse inflammatory cell infiltrate, all indicative of an inflammatory polyp.

After institution of general anesthesia and adequate multimodal analgesia, the cat was positioned in dorsal recumbency with the tongue and endotracheal tube lateralized to the right side and the mouth opened with a non-spring-loaded mouth gag (Figure 2). A midline incision was made in the mucosa overlying the hard palate continuing halfway the soft



palate. With a periosteal elevator, the mucosa was released from the underlying bone and several stay sutures were placed at the mucosal borders. Hemostasis was achieved with counter pressure and judicious use of bipolar electrocoagulation forceps. Using a 5 mm neurosurgical drill, a 15x40 mm hole was made in the hard palate overlying the left nasal cavity (Figure 3).

After removal of copious amounts of mucus from the left nasal cavity, the visible part of the polyp was gently lifted. Further traction also freed the part in the frontal sinus (Figure 4). The polyp appeared to be only attached in the region of the auditory tube; yet, after extraction, no visible stalk could be recognized. The mucosa surrounding the auditory tube exit was therefore curetted. The frontal sinus was abundantly flushed by passing a tube through the enlarged sino-nasal foramen. Any damaged nasal turbinates were removed and patency of the nasal cavity was confirmed by passing a feeding tube through the left nostril. No attempt was made to close the bony defect in the palate. The oral mucosa was closed with simple interrupted 5/0 polyglecaprone (Monocryl, Ethicon, Diegem) sutures (Figure 5).

Histological examination of the mass was in accordance with the previous biopsy results and confirmed the presence of an inflammatory polyp.

The cat was hospitalized for two days during which he made an uncomplicated recovery. The cat was reluctant to eat the first day but was eagerly eating on the second day. Postoperative analgesia consisted of opioids for two days and NSAIDs for seven days. Broad-spectrum antibiotics were also given for seven days.

At the time of the follow-up visit fourteen days later, both nasal passages were patent. Oral inspection confirmed uncomplicated healing of the palatal mucosa. The owner reported that the cat's appetite had completely normalized and that he was enthusiastically smelling again his surroundings. The cat was examined again ten months postoperatively and the owner was contacted by telephone two and a half years after the procedure. No recurrence of any upper respiratory symptoms was ever observed.

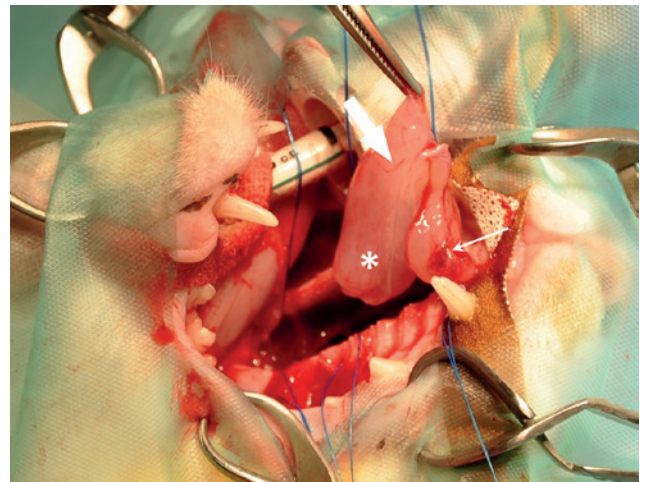
## DISCUSSION

A nasopharyngeal polyp that extended in the nasal cavity and frontal sinus could be successfully removed using a ventral rhinotomy approach. Ventral rhinotomy in cats has only been sparsely reported (Holmberg et al., 1989; Holmberg, 1996). Nevertheless, it is a very useful approach to the nasal cavity since it allows direct access to the ventral nasal cavity and the nasopharynx. Postoperatively, there is no visible scar and no risk for development of subcutaneous emphysema, which is common after dorsal rhinotomy (Weeden and Degner, 2016). An uncommon complication after ventral rhinotomy might be the development of an oronasal fistula, leading to chronic nasal

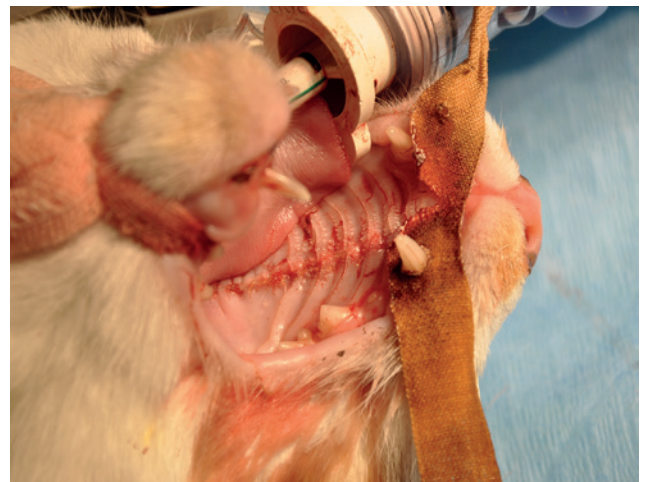infection and subsequent nasal discharge (Holmberg, 1996).

The standard treatment of an oropharyngeal polyp is traction avulsion from an oral approach with forces directed towards the oral cavity (Anderson et al., 2000). This technique is successful in removing not only the polyp but also often its originating stalk (Anderson et al., 2000; Lanz and Wood, 2004). Based on the CT images, it was deemed highly unlikely that this technique would be successful in the present case. The dimensions of the parts of the polyp present in the nasal cavity and frontal sinus prevented its passage through the nasopharynx.

Generally, a ventral rhinotomy does not allow access to the frontal sinuses (Weeden and Degner, 2016). However, based on the amount of ethmoturbinate destruction and bony lysis at the sino-nasal junction seen on the preoperative CT images, it was assumed that a ventral rhinotomy would actually grant access to both



**Figure 4.** Gentle traction avulsion resulted in removal of all parts of the polyp: the ventral part present in the nasal cavity (large arrow) and the oropharynx (asterisk) and the dorsal part present in the frontal sinus (small arrow).



**Figure 5.** The oral mucosa was closed with simple interrupted sutures polyglecaprone 5/0. No attempt was made to first close the underlying bony defect.

the nasal and frontal sinus in this particular case. Intraoperatively, the frontal sinus could be adequately visualized to confirm complete removal of the polyp, while, at the same time, the pharyngeal orifice of the auditory tube could be reached.

The ventral rhinotomy approach necessitates adequate opening of the mouth for visualization and access for a prolonged period. This can have grave consequences since the maxillary artery in cats is the sole artery responsible for cerebral perfusion and could become compressed between the tympanic bulla and the angular process of the mandibula (Barton-Lamb et al., 2013). The resulting cerebral hypoxia leads to neurologic signs, such as cortical blindness, motoric impairment or even respiratory and cardiac arrest (Hartman, 2017). It is therefore essential not to open the mouth maximally, nor to use spring-loaded mouth gags. The latter can unwillingly achieve maximal mouth opening during the procedure (Martin-Flores et al., 2014).

For various reasons including advanced age, extension into the frontal sinus and destruction of turbinates, a nasopharyngeal polyp was not the most likely tentative diagnosis in the cat of the present case (Reed and Gunn-Moore, 2012). The most common cause of nasopharyngeal disease in older cats is neoplasia, with lymphoma (29-70%) and adenocarcinoma (13-15%) being the most common tumors. Benign nasopharyngeal polyps are considered uncommon (Henderson, 2004; Worley, 2016). Yet, age is not a reliable parameter to differentiate since nasal tumors have been reported in cats ranging between three and seventeen years and, for nasopharyngeal polyps, three months to fifteen years has been recorded (Reed and Gunn-Moore, 2012).

Inflammatory polyps of the nasal turbinates, currently referred to as nasal chondromesenchymal hamartoma, were an important differential in this case. They arise from the nasal turbinates themselves and therefore have a more rostral location than nasopharyngeal polyps (Grecci et al., 2011). Radiographic studies typically demonstrate soft tissue opacification of the nasal cavity, turbinate lysis and radiolucent areas, corresponding to cystic spaces within the lesion (Grecci and Montellaro, 2016). In addition, their histological appearance is very distinct, characterized by fibrovascular tissue lined by a stratified squamous or ciliated columnar epithelium and bony cartilage structures without signs of atypia and erythrocyte-filled spaces (Grecci et al., 2011). Because of their location in the rostral nasal cavity surgical removal necessitates rhinotomy (Weeden and Degner, 2016).

It can be concluded that ventral rhinotomy in this cat resulted in adequate access to successfully remove a sizeable nasopharyngeal polyp that caused turbinate destruction and extended into the frontal sinus.

## REFERENCES

- Allen H.S., Broussard J., Noone, K. (1999). Nasopharyngeal diseases in cats: a retrospective study of 53 cases. *Journal of the American Veterinary Medical Association* 35, 457-461.
- Anderson D.M., Robinson R.K., White R.A.S. (2000). Management of inflammatory polyps in 37 cats. *Veterinary Record* 147, 684-687.
- Barton-Lamb A.L., Martin-Flores M., Scrivani P.V., Bezuidenhout A.J., Loew E., Erb H.N., Ludders J.W. (2013). Evaluation of maxillary arterial blood flow in anesthetized cats with the mouth closed and open. *Veterinary Journal* 196, 325-331.
- Grecci V., Mortellaro C.M., Olivero D., Cocci A., Hawkins E.C. (2011). Inflammatory polyps of the nasal turbinates of cats: an argument for designation as feline mesenchymal nasal hamartoma. *Journal of Feline Medicine and Surgery* 13, 213-219.
- Grecci V., Mortellaro C.M. (2016). Management of otic and nasopharyngeal, and nasal polyps in cats and dogs. *Veterinary Clinics of North America: Small Animal Practice* 46, 643-661.
- Hartman E.A., McCarthy R.J., Labato M.A. (2017). Global cerebral ischemia with subsequent respiratory arrest in a cat after repeated use of a spring-loaded mouth gag. *Journal of Feline Medicine and Surgery Open Reports* 27, 2055116917739126.
- Henderson S.M., Bradley K., Day M.J., Tasker S., Caney S.M., Hotston Moore A., Gruffydd-Jones T.J. (2004). Investigation of nasal disease in the cat-a retrospective study of 77 cases. *Journal of Feline Medicine and Surgery* 6, 245-257.
- Holmberg D.L. (1996). Sequelae of ventral rhinotomy in dogs and cats with inflammatory and neoplastic nasal pathology: A retrospective study. *The Canadian Veterinary Journal* 37, 483-485.
- Holmberg D.L., Fries C., Cockshutt J., Van Pelt D. (1989). Ventral rhinotomy in the dog and cat. *Veterinary Surgery* 18, 446-449.
- Kudnig S.T. (2002). Nasopharyngeal polyps in cats. *Clinical Techniques in Small Animal Practice* 17, 174-177.
- Lanz O.I., Wood B.C. (2004). Surgery of the ear and pinna. *Veterinary Clinics: Small Animal Practice* 34, 567-599.
- MacPhail C.M., Innocenti C.M., Kudnig S.T., Veir J.K., Lappin M.R. (2007). Atypical manifestations of feline inflammatory polyps in three cats. *Journal of Feline Medicine and Surgery* 9, 219-225.
- Martin-Flores M., Scrivani P.V., Loew E., Gleed C.A., Ludders J.W. (2014). Maximal and submaximal mouth opening with mouth gags in cats: implications for maxillary artery blood flow. *Veterinary Journal* 200, 60-64.
- Muilenburg R.K., Fry T.R. (2002). Feline nasopharyngeal polyps. *Veterinary Clinics of North America: Small Animal Practice* 32, 839-849.
- Reed N., Gunn-Moore D. (2012). Nasopharyngeal disease in cats: 1. Diagnostic investigation. *Journal of Feline Medicine and Surgery* 14, 306-315.
- Reed N., Gunn-Moore D. (2012). Nasopharyngeal disease in cats: 2. Specific conditions and their management. *Journal of Feline Medicine and Surgery* 14, 317-326.
- Weeden A.M., Degner D.A. (2016). Surgical approaches to the nasal cavity and sinuses. *Veterinary Clinics of North America: Small Animal Practice* 46(4), 719-733.
- Worley D.R. (2016). Nose and nasal planum neoplasia, reconstruction. *Veterinary Clinics of North America: Small Animal Practice* 46, 735-750.