

## Coinfection with *Mycoplasma haemofelis* and 'Candidatus *Mycoplasma haemominutum*' in a cat with immune-mediated hemolytic anemia in Belgium

*Co-infectie met Mycoplasma haemofelis en 'Candidatus Mycoplasma haemominutum' bij een kat met immuungemedieerde hemolytische anemie in België*

C. van Geffen

Algemene Dierenkliniek Randstad  
Frans Beirenslaan 155, B-2150 Borsbeek

cindyvangeffen.adr@telenet.be

### ABSTRACT

A young male domestic Shorthair was presented with weakness and anorexia of two days' duration. Physical examination showed pale mucous membranes, caused by severe, regenerative, Coombs' positive, hemolytic anemia. A blood smear revealed epicellular organisms compatible with *Mycoplasma* spp. Real-time polymerase chain reaction (RT-PCR) on EDTA blood identified these organisms as *Mycoplasma haemofelis* and 'Candidatus *Mycoplasma haemominutum*'. Despite the lack of clearance of the organism from the blood, the cat responded well to antibiotic treatment with doxycycline, together with immunosuppressive doses of corticosteroids.

### SAMENVATTING

Een jonge, mannelijke huiskat werd aangeboden voor zwakte en anorexia die reeds twee dagen aanhielden. Op klinisch onderzoek werden bleke slijmvliezen gezien, veroorzaakt door erge, regeneratieve, Coombs' positieve, hemolytische anemie. Een bloeditstrijkje toonde epicellulaire organismen aan, compatibel met *Mycoplasma* (vroeger bekend als *Haemobartonella felis*). Real-time polymerase chain reaction (RT-PCR) op EDTA-bloed identificeerde deze organismen als *Mycoplasma haemofelis* en 'Candidatus *Mycoplasma haemominutum*'. Ondanks de blijvende aanwezigheid van de organismen in het bloed, reageerde de kat goed op antibioticatherapie met doxycycline, samen met een immunosuppressieve dosis corticosteroïden.

### INTRODUCTION

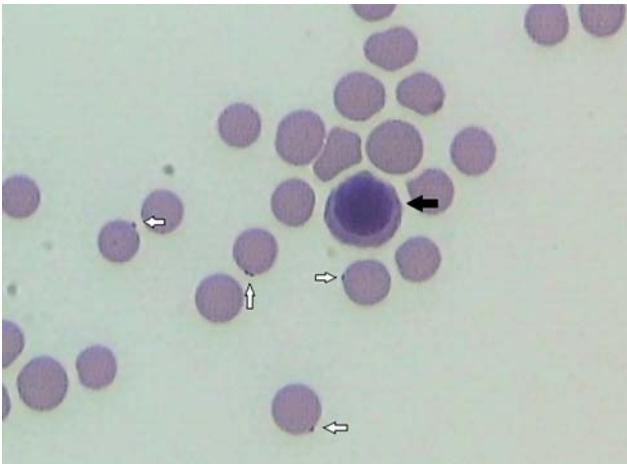
Hemobartonellosis or feline infectious anemia is caused by gram-negative bacteria that attach to the outer surface of host erythrocytes. Previously, they were classified into genus *Haemobartonella*, family *Anaplasmataceae*, order *Rickettsiales*. Recently, molecular techniques have resulted in a reclassification of these organisms. Phylogenetically, they seem to be more closely related to organisms of the genus *Mycoplasma*. Two closely related species have been detected, and they have recently been renamed again. *Haemobartonella felis* 'Ohio strain' or 'large form' is currently called *Mycoplasma haemofelis* (Neimark et al., 2001). *Haemobartonella felis* 'California strain' or 'small form', which seems to be a low-virulence bacterium, has been given a candidate species name 'Candidatus *Mycoplasma haemominutum*' (Foley and Pedersen, 2001). Some years ago, a third feline hemoplasma species was identified in Switzerland, and was named *Candidatus Mycoplasma turicensis* (Willi et al., 2005). Recent studies have documented

this infection to be present in cats worldwide (Duin et al., 2009, Fujihara et al., 2007; Gentilini et al., 2009; Willi et al., 2006).

The incubation period after infection with *Mycoplasma haemofelis* varies from weeks to months, and is followed by cycles of bacteremia which may last for months. Infected erythrocytes are less deformable in circulation and elicit an immune response with subsequent phagocytosis in lymphoid organs. Massive infection or severe anemia may result in death. Other animals will recover but remain carriers despite their immune response to the organism (Giger, 2005). Treatment includes antibiotics, such as doxycycline, supportive treatment with blood products in severely anemic animals, and possibly corticosteroids to halt immune-mediated destruction of erythrocytes (Harvey, 2006).

### CASE REPORT

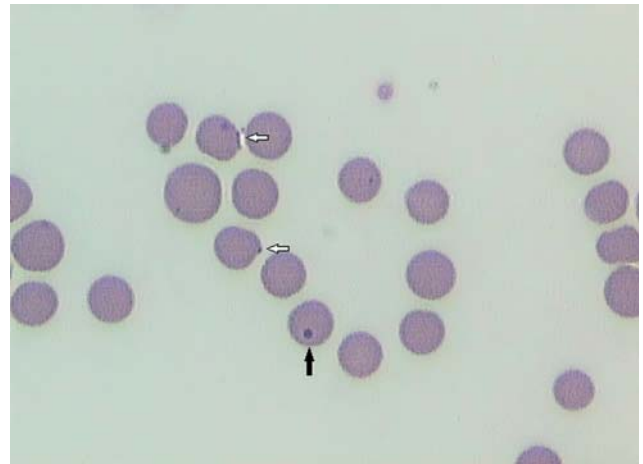
A 1.5-year-old, male, castrated domestic Shorthair was presented with weakness and anorexia of 2 days'



**Figure 1.** Blood smear from a cat infected with *Mycoplasma* organisms (Diff-Quick, magnification 1000 x). Several *Mycoplasma* organisms are attached in an epicellular location on erythrocytes (white arrows). A nucleated red blood cell or normoblast (black arrow) is also present.

duration. The cat was mainly kept indoors and was currently on vaccinations. There was no history of recent drug administration or ectoparasite control. Recently, a young stray cat has also been adopted in the household. Physical examination revealed a lethargic cat with pale and mildly icteric mucous membranes, mild tachycardia (180 beats/minute) and a low-grade systolic murmur. Femoral pulses were bounding. Respiratory rate and rectal temperature were normal (36 breaths/minute and 38.6°C, respectively). The right prescapular lymph node was mildly enlarged. Abdominal palpation was unremarkable.

A complete blood count (CBC) revealed a severe normochromic (mean corpuscular hemoglobin concentration / MCHC 36.0 g/dL [reference 30-36 g/dL]), macrocytic (mean corpuscular volume / MCV 62 fl [reference 37-55 fl]), regenerative anemia (hematocrit 8.1% [reference 24-45%]) with an absolute reticulocyte count of 338000/ $\mu$ L [reference < 40000/ $\mu$ L]). Leukocytes were within normal limits. The biochemistry profile showed normal total protein (7.5 g/L [reference 5.4-8.2 g/L]) and albumin concentrations (3.6 g/L [reference 2.7-4.5 g/L]), as well as normal renal parameters, liver enzymes and electrolytes. However, the bilirubin concentration was increased (2.8 mg/dL [reference 0.1-0.6 mg/dL]). Urinalysis was normal except for bilirubinuria. A direct polyvalent Coombs' test (Nordic, Tilburg, the Netherlands) was found strongly positive (titer 1:4096). A fresh blood smear was stained with Diff-Quick. A regenerative response was clearly demonstrated by the presence of polychromasia, anisocytosis and a moderate number of normoblasts and Howell-Jolly bodies (Figures 1 and 2). Heinz bodies were absent. Several erythrocytes showed one or more epicellular organisms resembling *Mycoplasma* spp. (Figures 1 and 2). An EDTA-blood sample was sent by regular mail to a veterinary laboratory specialized in molecular diagnostics for confirmation, characterization and quantification of the organisms by real-time



**Figure 2.** Blood smear from a cat infected with *Mycoplasma* organisms (Diff-Quick, magnification 1000x). Howell-Jolly bodies (black arrow), nuclear remnants, should not be confused with red blood cell parasites. Epicellular *Mycoplasma* organisms are indicated by white arrows.

PCR, and revealed the presence of both *Mycoplasma haemofelis* (organism load of  $2.4 \times 10^6$ /mL of blood) and '*Candidatus Mycoplasma haemominutum*' (organism load of  $1.5 \times 10^6$ /mL of blood).

The cat tested negative for feline leukemia virus (FeLV) antigen (ELISA) and feline immunodeficiency virus (FIV) antibodies (immunofluorescence antibody test). Lateral and ventrodorsal chest radiographs were within normal limits. Abdominal ultrasound revealed mild diffuse splenomegaly with normal echogenicity. Fine needle aspirates of the right prescapular lymph node had a normal cellular distribution with the predominance of small lymphocytes.

Intravenous fluid therapy (Hartmann®) was given at maintenance rate. A fresh blood transfusion was considered but postponed until absolutely necessary, because of financial concerns of the owner. Despite the severe anemia, the clinical and cardiorespiratory parameters remained stable during the following days. Medical treatment included doxycycline (Vibramycine® 5 mg/kg twice daily) combined with an immunosuppressive dose of parenteral dexamethasone (Rapidexon® 0.4 mg/kg once daily) initially, and oral prednisolone (Prednisolone® 1 mg/kg twice daily) after the cat regained his appetite. A repeat blood smear on the second day of hospitalization no longer revealed *Mycoplasma* organisms. Signs of regeneration became more prominent (polychromasia, anisocytosis together with the presence of many normoblasts). A CBC on the 6<sup>th</sup> day revealed a rising hematocrit (22.9%), with a MCV of 76.6 fl, the latter indicating the presence of larger sized reticulocytes and thus an ongoing regenerative response. At that time, the systolic murmur was no longer audible, suggesting that it was most likely caused by altered blood viscosity during the severely anemic state.

The cat was sent home with oral doxycycline (Vibramycine®) 5 mg/kg twice daily for three weeks and tapering doses of oral prednisolone (Prednisolone®, 1

mg/kg twice daily starting dose). Furthermore, a monthly flea prevention with fipronil (Frontline®) was prescribed. Four weeks later (and five days after discontinuation of prednisolone), the physical examination, blood work, fresh blood smear, Coombs' test and PCR for both *Mycoplasma* organisms were repeated. According to the owner, the cat made full recovery and was again alert and playful. The mucous membranes were pink and the cardiac auscultation was normal, as was the rest of the physical examination. The hematocrit and red cell indices had returned within reference limits (hematocrit 30%, MCV 45 fl, MCHC 36 g/dL). The bilirubin level was normalized (0,2 mg/dL) and bilirubinuria was no longer present. Other parameters were still within normal limits. The blood smear revealed normal red cell morphology and the absence of visible epicellular organisms. The Coombs' test resulted in a titer of 1:32. Real-time PCR revealed the persistence of *Mycoplasma haemofelis* (hemoplasma load of  $3.6 \times 10^5$ /mL of blood) and 'Candidatus *Mycoplasma haemominutum*' (hemoplasma load of  $3.2 \times 10^6$ /mL of blood). Another three weeks of doxycycline were advised but declined by the owner because the cat had been clinically healthy since discontinuation and remained so during the following months.

## DISCUSSION

Anemia is a commonly encountered laboratory abnormality in cats. It can be broadly classified into (1) reduced hematopoiesis, such as anemia of inflammatory disease, most FeLV infections and due to chronic renal failure, (2) external blood loss due to ectoparasites, tumors and hemostatic defects and (3) hemolysis. In the present case, the macrocytic regenerative anemia, supportive of the increased presence of larger sized reticulocytes in the peripheral circulation), together with the normal serum protein concentration, hyperbilirubinemia and bilirubinuria, which is always an abnormal finding in cats, were indicative of hemolysis.

Hemolytic anemia in this species is mostly caused by acquired disorders, such as hemobartonellosis, feline infectious peritonitis (FIP), and other infections (e.g. FeLV subtype A), hypophosphatemia, oxidative agents (e.g. onions, zinc and drugs) and primary and secondary immune-mediated processes (Adams et al., 1993; Robertson et al., 1998; Sykes, 2003; Norris et al., 2005; Kohn et al., 2006). Less often, hemolysis is a consequence of certain hereditary defects (Giger, 2005).

Immune-mediated hemolytic anemia is considered to occur relatively rarely in cats compared to dogs, and is more often associated with secondary causes (Giger, 2005; Kohn et al., 2006). In the present case, the direct Coombs' test was positive, indicating the presence of erythrocyte-bound antibodies and thus an immune-mediated component to the hemolysis. Usually, most damage to the red blood cell is not directly caused by the parasite but rather because of immune-mediated injury, especially in the acute phase of infection. The attachment of the organisms to erythrocytes is thought to

result in exposure of hidden antigens or changes in existing antigens, thereby activating the production of host anti-erythrocyte antibodies. The anemia mostly results from extravascular erythrophagocytosis by macrophages in the spleen, liver, lungs and bone marrow (Harvey, 2006). Other conditions, such as inflammatory, infectious and neoplastic diseases, may result in the immune-mediated destruction of erythrocytes in circulation or lymphoid organs. A thorough work-up, including retroviral testing, chest radiographs and abdominal ultrasound, revealed no significant abnormalities in the present case. The mild uniform splenomegaly at initial presentation was believed to result from sequestration of parasitized erythrocytes or from extramedullary hematopoiesis. However, no further tests (fine-needle aspiration) were performed to confirm this.

There is still debate on the exact natural route of transmission of *Mycoplasma* spp. A role of *Ctenocephalides felis* has been proposed but is still unclear. Recently, DNA of *Mycoplasma haemofelis* and 'Candidatus *Mycoplasma haemominutum*' has been amplified from blood of infected cats and from fleas collected from client-owned cats by PCR (Lappin et al., 2006). Woods et al. (2005) assessed the ability of fleas to transmit *Mycoplasma* spp. through hematophagous activity and found that both species were ingested by *C. felis* when allowed to feed on experimentally infected cats. Only *Mycoplasma haemofelis* was found to be transmitted from *C. felis* to cats by hematogenous route. However, the efficiency of infection was poor and clinical or hematological signs of anemia did not develop. Another study failed to detect the transmission of *Mycoplasma* spp. by oral ingestion of infected fleas or flea by-products (Woods et al., 2006). Recent studies also failed to show the successful transmission of 'Candidatus *Mycoplasma turicensis*' infection between cats by the oral or subcutaneous inoculation of 'Candidatus *Mycoplasma turicensis*'-infected saliva (Museux et al., 2009). Aggressive cat interaction could however result in transmission if a recipient cat is exposed to blood of an infected cat (Museux et al., 2009).

Despite the fact that many questions remain unanswered, most reports as well as the present case support the recommendation to maintain flea control.

In the present case, it was not possible to determine which of the two organisms was responsible for the clinical signs. Experimental infection with the large variant, *Mycoplasma haemofelis*, resulted in more severe clinical signs than with the small variant, 'Candidatus *Mycoplasma haemominutum*' (Westfall et al., 2001). The same observations were made in client-owned cats with naturally occurring hemobartonellosis (Jensen et al., 2001). In the study of Westfall et al. (2001), cats with dual infections had the most severe clinical abnormalities. Proposed explanations included dose-dependent effects or predisposition to immune-mediated disease in 'Candidatus *Mycoplasma haemominutum*'-infected cats that were subsequently exposed to the more pathogenic *Mycoplasma haemofelis*.

In the present case, the clinical course was rapid, with only a two-day history of clinical signs before admission with severe anemia. Another (retrospective) study suggested that ‘*Candidatus Mycoplasma haemominutum*’ might be a primary pathogen in some naturally infected, immunocompetent cats (Reynolds and Lappin, 2007). Concurrent diseases may predispose cats to develop more severe signs of anemia, as for example the presence of lymphoma (de Lorimier and Messick, 2004). Pre-existing FeLV infection or FeLV-FIV co-infection also seems to potentiate the severity of anemia caused by *Mycoplasma haemofelis* (George et al., 2002). However, the cat in this report tested negative for both retroviruses.

The diagnosis is based on the detection of the organism in an epicellular location on feline erythrocytes on a fresh blood smear. However, this technique has low sensitivity, especially in chronically infected animals, in cats with low parasite burden, or because of the cyclical parasitemia (Harvey, 2006; Tasker, 2006). Organisms rapidly detach from red blood cells in vitro, probably reflecting organism death a few hours after blood collection (Tasker, 2006). Specificity may also be low, as organisms may be confused with Howell-Jolly bodies or staining artefacts, and it is not possible to distinguish the two forms morphologically based on light microscopy alone (Jensen et al., 2001) (Figure 2). Molecular techniques have greatly improved the ability to diagnose infections. The use of real-time PCR offers several advantages over conventional PCR because it may both diagnose *Mycoplasma* spp. and quantify infectious burden (Tasker et al., 2003). This is important for determining the significance of a positive PCR result in infections with *Mycoplasma haemofelis* and ‘*Candidatus Mycoplasma haemominutum*’, the latter not always resulting in clinical disease in the host (Tasker et al., 2003). Furthermore, quantification can help monitor the response to treatment (Tasker et al., 2003). On the other hand, a positive cytology or PCR does not necessarily correlate with clinical illness, as clinically normal cats can have positive test results (Jensen et al., 2001). However, the more pathogenic form (*Mycoplasma haemofelis*) is rarely detected in cats without anemia (Jensen et al., 2001).

In the present case, the combination of doxycycline and prednisolone resulted in rapid clinical and hematological recovery, despite the lack of clearance of microorganisms as shown by the follow-up real-time PCR. Total clearance of organisms, as confirmed by PCR, seems to be rare, and most animals remain carriers (Dowers et al., 2002). Despite the persistence of both organisms after antibiotic treatment in the present case, a tenfold decrease in *Mycoplasma haemofelis* load was found by RT-PCR, and there was no longer evidence of ongoing hemolysis (normal hematocrit, MCV and bilirubin level). This may indicate that *Mycoplasma haemofelis* was responsible for the hemolytic anemia. After treatment, only the Coombs’ test was still borderline positive. The question remains whether longer courses of doxycycline or an alternative antibiotic (e.g. en-

rifloxacin or marbofloxacin) would have resulted in decreasing numbers of detectable microorganisms (Dowers et al., 2002; Ishak et al., 2008). Cats may become PCR-positive again once the antibiotic treatment is stopped, or they can remain PCR-positive for months or years following infection, especially in the case of ‘*Candidatus Mycoplasma haemominutum*’ infection (Tasker, 2006). Complete recovery with negative PCR results has recently been described in a *Mycoplasma haemofelis* infected cat, after a 6-week course of doxycycline (Braddock et al., 2004). Alternatively, in a study by Dowers et al. (2009), treatment with pradofloxacin resulted in a more effective clearance of organisms than with doxycycline. Another hypothesis for the persistent high bacterial load may be the concurrent use of prednisolone, which might cause immunosuppression with subsequent persistence of the organism. However, in a study by Dowers et al. (2002), treatment with immunosuppressive doses of methylprednisolone acetate did not result in the recurrence of organisms in three cats after the successful treatment with doxycycline or enrofloxacin.

In this case, immunosuppressive doses of corticosteroids were added to the treatment protocol because the positive Coombs’ test strongly suggested an immune-mediated component to the hemolysis (Harvey, 2006). This may indicate that one or both *Mycoplasma* species may have acted as haptens and triggered an immune-mediated destruction of affected erythrocytes.

In conclusion, this case documents that cats in Belgium may be co-infected with *Mycoplasma haemofelis* and ‘*Candidatus Mycoplasma haemominutum*’, and that these organisms should be considered as possible causes of hemolytic anemia.

## REFERENCES

- Adams L.G., Hardy R.M., Weiss D.J., Bartges J.W. (1993). Hypophosphatemia and hemolytic anemia associated with diabetes mellitus and hepatic lipidosis in cats. *Journal of Veterinary Internal Medicine* 7, 266-271.
- Braddock J.A., Tasker S., Malik R. (2004). The use of real-time PCR in the diagnosis and monitoring of *Mycoplasma haemofelis* copy number in a naturally infected cat. *Journal of Feline Medicine and Surgery* 6, 161-165.
- de Lorimier L.-P., Messick J.B. (2004). Anemia associated with ‘*Candidatus Mycoplasma haemominutum*’ in a feline leukemia virus-negative cat with lymphoma. *Journal of the American Animal Hospital Association* 40, 423-427.
- Dowers K.L., Olver C., Radecki S.V., Lappin M.R. (2002). Use of enrofloxacin for treatment of large-form *Haemobartonella felis* in experimentally infected cats. *Journal of the American Veterinary Medical Association* 2, 250-253.
- Dowers K.L., Tasker S., Radecki S.V., Lappin M.R. (2009). Use of pradofloxacin to treat experimentally induced *Mycoplasma haemofelis* infection in cats. *American Journal of Veterinary Research* 70, 105-111.
- Duin M.B., Moyaert H., Pasmans F., Boyen F. (2009). Hemotrofe mycoplasmen bij katten. Deel 1: literatuuroverzicht. *Vlaams Diergeneeskundig Tijdschrift* 78, 143-154.
- Foley J.E., Pedersen N.C. (2001). ‘*Candidatus Mycoplasma haemominutum*’, a low-virulence epierthrocytic para-

- site of cats. *International Journal of Systematic and Evolutionary Microbiology* 51, 815-817.
- Fujihara M., Watanabe M., Yamada T., Harasawa R. (2007). Occurrence of 'Candidatus Mycoplasma turicensis' infection in domestic cats in Japan. *Journal of Veterinary Medical Science* 69, 1061-1063.
- Gentilini F., Novacco M., Turba M.E., Willi B., Bacci M.L., Hofmann-Lehmann R. (2009). Use of combined conventional and real-time PCR to determine the epidemiology of feline haemoplasma infections in northern Italy. *Journal of Feline Medicine and Surgery* 11, 277-285.
- George J.W., Rideout B.A., Griffey S.M., Pedersen N.C. (2002). Effect of preexisting FeLV or FeLV and feline immunodeficiency virus coinfection on pathogenicity of the small variant of *Haemobartonella felis* in cats. *American Journal of Veterinary Research* 63, 1172-1178.
- Giger U. (2005). Regenerative anemias caused by blood loss or hemolysis. In: Ettinger S.J., Feldman E.C. (editors). *Textbook of Veterinary Internal Medicine – Diseases of the Dog and Cat*. 6th Edition, Elsevier Saunders, Philadelphia, p. 1886-1907.
- Harvey J.W. (2006). Hemotropic Mycoplasmosis (Hemobartonellosis). In: Greene C.E. (editor). *Infectious Diseases of the Dog and Cat*. 3rd Edition. Elsevier Saunders, Missouri, p. 252-260.
- Ishak A.M., Dowers K.L., Cavanaugh M.T., Powell C.C., Hawley J.R., Radecki S.V., Lappin M.R. (2008). Marbofloxacin for the treatment of experimentally induced *Mycoplasma haemofelis* infection in cats. *Journal of Veterinary Internal Medicine* 22, 288-292.
- Jensen W.A., Lappin M.R., Kamkar S., Reagan W.J. (2001). Use of a polymerase chain reaction assay to detect and differentiate two strains of *Haemobartonella felis* in naturally infected cats. *American Journal of Veterinary Research* 62, 604-608.
- Kohn B., Weingart C., Eckmann V., Ottenjann M., Leibold W. (2006). Primary immune-mediated hemolytic anemia in 19 cats. *Journal of Veterinary Internal Medicine* 20, 159-166.
- Lappin M.R., Griffin B., Brunt J., Riley A., Burney D., Hawley J., Brewer M.M., Jensen W.A. (2006). Prevalence of *Bartonella* species, haemoplasma species, *Ehrlichia* species, *Anaplasma phagocytophilum*, and *Neorickettsia risticii* DNA in the blood of cats and their fleas in the United States. *Journal of Feline Medicine and Surgery* 8, 85-90.
- Museux K., Boretti F.S., Willi B., Riond B., Hoelzle L.E., Wittenbrink M.M., Tasker S., Wengi N., Reusch C.E., Lutz H., Hofmann-Lehmann R. (2009). In vivo transmission studies of 'Candidatus Mycoplasma turicensis' in a domestic cat. *Veterinary Research* 40, 45.
- Neimark H., Johansson K.E., Rikihisa Y., Tully J.G. (2001). Proposal to transfer some members of the genera *Haemobartonella* and *Eperythrozoon* to the genus *Mycoplasma* with descriptions of 'Candidatus Mycoplasma haemofelis', 'Candidatus Mycoplasma haemomuris', 'Candidatus Mycoplasma haemosuis' and 'Candidatus Mycoplasma wenyonii'. *International Journal of Systematic and Evolutionary Microbiology* 51, 891-899.
- Norris J.M., Bosward K.L., White J.D., Baral R.M., Catt M.J., Malik R. (2005). Clinicopathological findings associated with feline infectious peritonitis in Sydney, Australia: 42 cases (1990-2002). *Australian Veterinary Journal* 83, 666-673.
- Reynolds C.A., Lappin M.R. (2007). 'Candidatus Mycoplasma haemominutum' infections in 21 client-owned cats. *Journal of the American Animal Hospital Association* 43, 249-257.
- Robertson J.E., Christopher M.M., Rogers Q.R. (1998). Heinz body formation in cats fed baby food containing onion powder. *Journal of the American Veterinary Medical Association* 212, 1260-1266.
- Sykes J.E. (2003). Feline hemotropic mycoplasmosis (feline hemobartonellosis). *Veterinary Clinics of North America: Small Animal Practice* 33, 773-789.
- Tasker S., Helps C.R., Day M.J., Gruffydd-Jones T.J., Harbour D.A. (2003). Use of Real-Time PCR to detect and quantify *Mycoplasma haemofelis* and 'Candidatus Mycoplasma haemominutum' DNA. *Journal of Clinical Microbiology* 41, 439-441.
- Tasker S. (2006). Current concepts in feline hemobartonellosis. *Companion Animal Practice* 28, 136-141.
- Westfall D.S., Jensen W.A., Reagan W.J., Radecki S.V., Lappin M.R. (2001). Inoculation of two genotypes of *Haemobartonella felis* (California and Ohio variants) to induce infection in cats and the response to treatment with azithromycin. *American Journal of Veterinary Research* 62, 687-691.
- Willi B., Boretti F.S., Cattori V., Tasker S., Meli M.L., Reusch C., Lutz H., Hofmann-Lehmann R. (2005). Identification, molecular characterization, and experimental transmission of a new hemoplasma isolate from a cat with hemolytic anemia in Switzerland. *Journal of Clinical Microbiology* 43, 2581-2585.
- Willi B., Tasker S., Boretti F.S., Doherr M.G., Cattori V., Meli M.L., Lobetti R.G., Malik R., Reusch C.E., Lutz H., Hofmann-Lehmann R. (2006). Phylogenetic analysis of 'Candidatus Mycoplasma turicensis' isolates from pet cats in the United Kingdom, Australia, and South Africa, with analysis of risk factors for infection. *Journal of Clinical Microbiology* 44, 4430-4435.
- Woods J.E., Brewer M.M., Hawley J.R., Wisniewski N., Lappin M.R. (2005). Evaluation of experimental transmission of 'Candidatus Mycoplasma haemominutum' and *Mycoplasma haemofelis* by *Ctenocephalides felis* to cats. *American Journal of Veterinary Research* 66, 1008-1012.
- Woods J.E., Wisniewski N., Lappin M.R. (2006). Attempted transmission of 'Candidatus Mycoplasma haemominutum' and *Mycoplasma haemofelis* by feeding cats infected *Ctenocephalides felis*. *American Journal of Veterinary Research* 67, 494-497.